

Transcatheter embolization of pancreatic arteriovenous malformation associated with recurrent acute pancreatitis

S Rajesh, Amar Mukund, Vikram Bhatia¹, Ankur Arora²

Departments of Interventional Radiology, ¹Hepatology and ²Radiology, Institute of Liver and Biliary Sciences, New Delhi, India

Correspondence: Dr. S Rajesh, Department of Interventional Radiology, Institute of Liver and Biliary Sciences, D-1, Vasant Kunj, Off Abdul Gaffar Khan Marg, New Delhi - 110 070, India. E-mail: rajesh387@gmail.com

Abstract

Pancreatic arteriovenous malformation (PAVM) is extremely rare; even rarer is its association with pancreatitis. The authors report a case of PAVM causing recurrent episodes of acute pancreatitis in a 46-year-old male. Patient refused surgery and was treated with transcatheter arterial embolization using liquid embolic agent (mixture of *n*-butyl-2-cyanoacrylate glue and lipiodol), which resulted in a significant decrease in the size of the PAVM.

Key words: Embolization; lipiodol; pancreatic arteriovenous malformation; pancreatitis

Introduction

Pancreatic arteriovenous malformation (PAVM) is a very rare vascular anomaly in which blood flows from the arterial system directly into the portal venous system without passing through the capillaries in the pancreas.^[1,2] With the advances in imaging technology, it is being increasingly detected; however, it still accounts for only about 5% of all arteriovenous malformations (AVMs) found in the gastrointestinal tract.^[3] Though it may be asymptomatic, majority of the cases present with a variety of symptoms including epigastric pain, abdominal distension, and gastrointestinal bleeding.^[2-6] Surgery is considered to be the definitive treatment by many,^[2,3,7-9] but there are no universally accepted guidelines and other therapies like transcatheter arterial embolization^[10-15] and

irradiation^[16,17] have been explored. In asymptomatic patients, a conservative approach has also been tried for a good result.^[18,19] The purpose of the present report is to describe our clinical experience with transcatheter embolization of PAVM causing recurrent episodes of acute pancreatitis in a middle-aged male.

Case Report

A 46-year-old non-alcoholic male presented to our out-patient department with complaints of intermittent epigastric pain. He had an episode of severe upper abdominal pain 4 months back when he was evaluated outside and found to have acute pancreatitis based on laboratory investigations and imaging. His prior imaging records were not available for review. He denied any history of jaundice, fever, or gastrointestinal blood loss. At presentation to us, his physical examination and laboratory investigations including serum amylase and lipase were within normal limits. Contrast-enhanced computed tomographic (CECT) scan of the abdomen performed on a Discovery 750HD 64-row spectral CT scanner (General Electric, Wisconsin, USA) revealed mild peripancreatic fat stranding with a small pseudocyst involving the head and body of pancreas [Figure 1A and B], suggesting acute

Access this article online

Quick Response Code:



Website:
www.ijri.org

DOI:
10.4103/0971-3026.178352

pancreatitis. In addition, there was evidence of a network of multiple tortuous arterial channels involving the body of pancreas with early opacification of the splenic and portal vein [Figure 1], consistent with a PAVM. The patient was initially managed conservatively for pancreatitis and had an uneventful course in the hospital, and was thus discharged in a couple of days. Etiological work-up for pancreatitis was non-contributory. However, he presented to the emergency room 3 months later with the same complaint. During this presentation, his blood work up revealed significantly raised serum amylase (432 U/l; normal value 25-125 U/l) and lipase (1615 U/l; normal value 73-393 U/l). Rest of the laboratory investigations showed normal values. CECT was repeated which showed changes of pancreatitis with persistence of the PAVM. In view of recurrent attacks of pancreatitis and associated PAVM, therapy for the malformation was considered. After a multidisciplinary team discussion, the options of surgery and transcatheter arterial embolization were offered to the patient. The patient refused surgery and was taken for transarterial embolization with the objective to occlude as many of the shunts in the PAVM as possible, so as to reduce the risk of recurrent pancreatitis and development of portal hypertension.

Through the right femoral approach, a 6F vascular access sheath (Cook, Bloomington, IN, USA) was placed using standard angiographic technique. A 5F guiding catheter (C2; Cook) was used to cannulate the celiac artery and angiogram was done which revealed an interlacing network of arterial channels in the region of pancreas with early opacification of the portal vein [Figure 2A and B]. Using a 2.7F microcatheter (Progreat, Terumo, Japan), the branches of celiac artery [common hepatic including the gastroduodenal artery, dorsal pancreatic artery (DPA), splenic artery, and left gastric artery (LGA)] were sequentially cannulated and angiograms were done which revealed that the PAVM was supplied by branches from the LGA and DPA [Figure 2C and E]. The major feeding artery arising from the LGA was first embolized using a 2 ml mixture of *n*-butyl-2-cyanoacrylate glue (Gesika; Medicon, Chennai, India) and lipiodol (Guerbet, Aulnay-sous-Bois, France) combined in a 1:1 ratio. Subsequent check angiogram revealed complete embolization of the concerned branch, without any significant opacification of the portal vein [Figure 2D]. The DPA was then partially embolized using 1 ml of the same mixture [Figure 2E and F]. Complete embolization was not attempted for fear of major ischemic injury to the pancreatic head and duodenum. The superior mesenteric artery (SMA) angiogram was normal, except for the incidental finding of a replaced right hepatic artery arising from the SMA. The procedure was uneventful with no immediate procedure-related complications. A follow-up CECT scan done 3 days later revealed significant decrease in the size of the PAVM compared to the pre-procedural scan, with patchy deposition of the liquid embolic material within it [Figure 3A and B]. Hospital stay was uneventful and the patient was discharged 4 days after the procedure. Follow-up

CECT scans at 1 and 8 months interval demonstrated progressive decrease in the size of the PAVM and portal venous filling [Figure 3C and D]. At the time of writing this manuscript, the patient had completed 18 months of follow-up and had not suffered any more episodes of pancreatitis or significant abdominal pain.

Discussion

Since its first description by Halpern *et al.* in a patient with Osler-Weber-Rendu disease in 1968,^[20] less than 100 cases of PAVM have been reported in the English language medical literature.^[1,18] Majority of the cases (approximately 90%) are congenital and arise from an anomalous differentiation in the rudimentary plexus of primordial blood vessels;^[7,11] the acquired form is seen secondary to local inflammation, tumor, or trauma.^[7] PAVM tends to occur more commonly in males (85%) at the median age of 50 years.^[1] The most frequently involved portion of the pancreas appears to be the head, followed by the body and tail.^[1] While it may be asymptomatic, majority (>95%) of the patients present with a wide range of symptoms including upper abdominal pain, epigastric fullness, signs of recurrent pancreatitis, and complications of portal hypertension including catastrophic gastrointestinal bleeding.^[6,7] In a recent study analyzing the 89 cases reported in literature,^[1] it was noted that the most common symptom of PAVM was gastrointestinal bleed (47%), followed by epigastric pain (46%). It was also seen that in the pancreatic head AVM group, bleeding was the most common complication, while in the pancreatic body-tail AVM group, pancreatitis was more common, as in the present case.

Association of pancreatitis with PAVM is extremely rare with only a handful of reported cases.^[5,9,13,21-23] The mechanisms by which PAVM can cause pancreatitis may be classified into three types: (i) By bleeding from PAVM extending into the pancreatic duct,^[21] (ii) ischemic injury due to the PAVM *stealing* flow from normal surrounding pancreatic parenchyma,^[5] and (iii) pancreatic ductal compression caused by PAVM.^[9] Cases of pancreatitis causing PAVM have also been reported and have been proposed to be due to the vascular damage caused by the

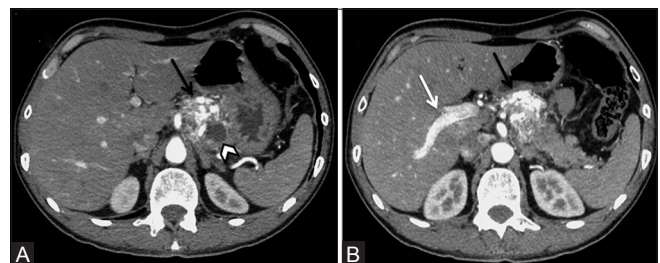


Figure 1 (A and B): Axial CECT scan images demonstrating multiple tortuous arterial channels forming a racemose network in the pancreatic body (black arrows) with opacification of the portal vein (white arrow in B) in the early arterial phase. Note is also made of small pseudocyst in the vicinity of the PAVM (arrowhead in A)

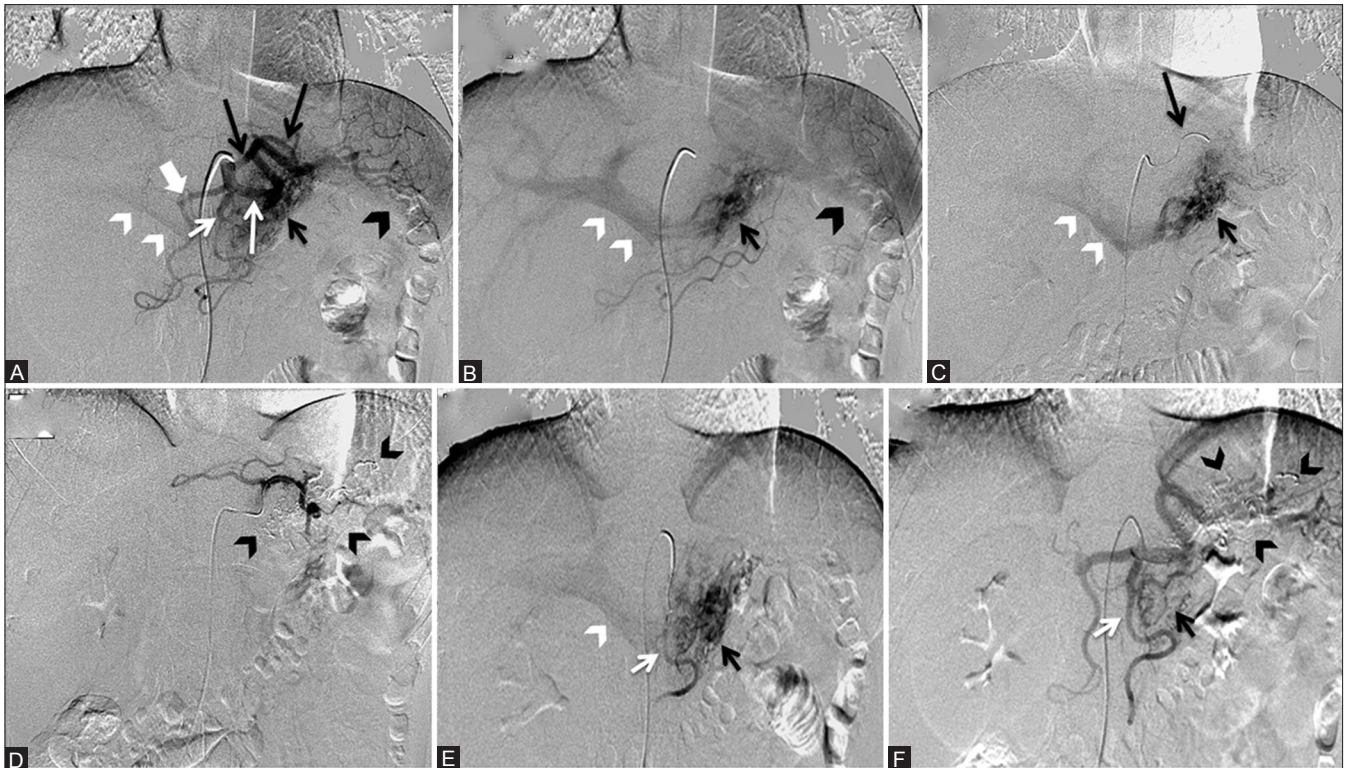


Figure 2 (A-F): (A and B) Celiac artery angiogram demonstrating the common hepatic (thick white arrow), dorsal pancreatic (short thin white arrow), splenic (long white arrow) and the LGA (long black arrows). PAVM is also seen (short black arrow) with early opacification of the portal vein (PV) (white arrowheads) and splenic parenchymal enhancement (black arrowheads). (C) LGA angiogram (black arrow) showing the PAVM. (D) Post embolization angiogram shows occlusion of the concerned artery and the embolic material (black arrowheads). (E) DPA (short white arrow) angiogram (F) Post embolization image shows minimal residual staining of the pancreas (short black arrow)

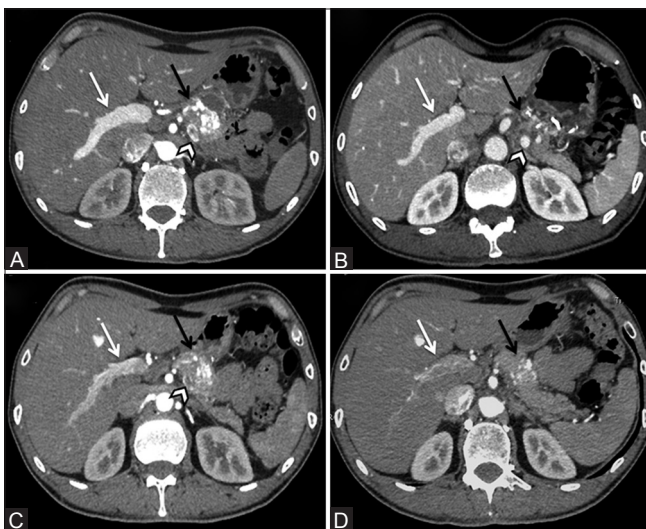


Figure 3 (A-D): Images from the pre intervention (A) and post intervention (B, C and D) CECT scans of the patient demonstrating deposition of embolic material on the 3-day follow-up image (black arrow in B) with a progressive regression in the size of the PAVM (black arrows in C and D) as well as a decrease in the opacification of portal vein (white arrows) and splenic vein (arrowheads) on the 3-month (C) and 8- month's follow-up image (D)

direct effect of pancreatic enzymes.^[9,23] In the present case, like in most of the other cases previously reported, PAVM and pancreatitis were detected simultaneously with no past

history of trauma or tumor in the patient, suggesting that the PAVM was probably congenital.^[5,9,22,23]

Diagnosis is usually made by imaging including ultrasound and color Doppler, CECT, magnetic resonance imaging, and catheter angiography. On ultrasonography, PAVM is delineated as a hypoechoic area with vessels appearing as feeding arteries or drainage veins around the lesion.^[24] A color display of reticulated or mosaic-like structure can be demonstrated at the site of the malformation by Doppler.^[24] Color Doppler imaging also helps in follow-up after vascular embolization.^[7] The angiographic features of a PAVM consist of dilated and tortuous feeding arteries, complex *racemose* intra-pancreatic vascular network, transient dense pancreatic stain with early filling of draining veins (portal and splenic veins), and early disappearance of the pancreatic stain.^[3,25] The vessels most commonly affected by a PAVM are the splenic artery (42%), gastroduodenal artery (22%), and small pancreatic arteries (25%).^[3] In the present case, the PAVM was supplied by the LGA and DPA.

PAVM has to be differentiated from other hypervascular neoplasms such as cystadenoma, cystadenocarcinoma, angiosarcoma, and islet cell tumor. However, in typical cases, differentiation by angiography is not difficult, because most of the other aforementioned hypervascular neoplasms frequently enhance in the venous phase.

Owing to the rarity of this disease, there are no standard management protocols and a wide range of strategies including both surgical and non-invasive therapies (including arterial embolization, irradiation, and porto-venous shunt) have been employed in the treatment of symptomatic patients. Nishiyama *et al.* suggested that complete cure is accomplished only by total extirpation of the affected organ or at least its involved part.^[7] Koito *et al.* recommended that PAVMs should be treated with surgical resection whenever possible due to the potential risk of portal hypertension.^[6] In cases where surgery has a limited role due mainly to the lack of expertise, poor accessibility, extensive surgery involved, and patient refusal, transcatheter arterial embolization has been effectively used.^[10-15] There have been concerns about recurrence of the lesion after arterial embolization due to the rich vascular supply of pancreatic bed and the propensity for growth of new collateral vessels, leading to repeated hemorrhage and the progressive development of portal hypertension.^[15] Therefore, it has been suggested that permanent embolic agents should be used and every effort should be made to extinguish the hemangiomatic portion of the PAVM while preserving the normal surrounding parenchyma. However, the embolization of multiple vessels is quite difficult, and the risk of enteric necrosis is significant. Recent reports, including the present one, demonstrate that even a partial embolization can produce acceptable results in the long term.^[10-12] Recently, radiation therapy has shown satisfactory results in the management of these patients.^[16,17] However, as far as asymptomatic patients are concerned, conservative “wait and watch” approach has also been tried.^[18,19] In summary, the available literature suggests that management should be individualized according to the size, location, and extent of the lesion and the possible risks involved in the available management strategies.

References

- Chou SC, Shyr YM, Wang SE. Pancreatic arteriovenous malformation. *J Gastrointest Surg* 2013;17:1240-6.
- Song KB, Kim SC, Park JB, Kim YH, Jung YS, Kim MH, *et al.* Surgical outcomes of pancreatic arteriovenous malformation in a single center and review of literature. *Pancreas* 2012;41:388-96.
- Rezende MB, Bramhall S, Hayes T, Olliff S, Buckels JA, Candinas D, *et al.* Pancreatic arteriovenous malformation. *Dig Surg* 2003;20:65-9.
- Ogawa H, Itoh S, Mori Y, Suzuki K, Ota T, Naganawa S. Arteriovenous malformation of the pancreas: Assessment of clinical and multislice CT features. *Abdom Imaging* 2009;34:743-52.
- Kanno A, Satoh K, Kimura K, Masamune A, Asakura T, Egawa S, *et al.* Acute pancreatitis due to pancreatic arteriovenous malformation: 2 case reports and review of the literature. *Pancreas* 2006;32:422-5.
- Koito K, Namieno T, Nagakawa T, Morita K. Diagnosis of arteriovenous malformation of the pancreas by color Doppler ultrasonography. *Abdom Imaging* 1998;23:84-6.
- Nishiyama R, Kawanishi Y, Mitsuhashi H, Kanai T, Ohba K, Mori T, *et al.* Management of pancreatic arteriovenous malformation. *J Hepatobiliary Pancreat Surg* 2000;7:438-42.
- Yamabuki T, Ohara M, Kimura N, Okamura K, Kuroda A, Takahashi R, *et al.* Pancreatic arteriovenous malformation. *Case Rep Gastroenterol* 2014;8:26-31.
- Choi JK, Lee SH, Kwak MS, Kim JH, Jang ES, Hwang SW, *et al.* A case of recurrent acute pancreatitis due to pancreatic arteriovenous malformation. *Gut Liver* 2010;4:135-9.
- Grasso RF, Cazzato RL, Luppi G, Faiella E, Del Vescovo R, Giurazza F, *et al.* Pancreatic arteriovenous malformation involving the duodenum embolized with ethylene-vinyl alcohol copolymer (Onyx). *Cardiovasc Intervent Radiol* 2012; 35:958-62.
- Charalabopoulos A, Macheras N, Krivan S, Petropoulos K, Misiakos E, Macheras A. Arteriovenous malformation of the pancreas. *Case Rep Med* 2011;2011:612657.
- Iwashita Y, Kawano T, Maeda T, Nagasaki S, Kitano S. Pancreatic arteriovenous malformation treated by transcatheter embolization. *Hepatogastroenterology* 2002;49:1722-3.
- Gomes AS, Mali WP, Oppenheim WL. Embolization therapy in the management of congenital arteriovenous malformations. *Radiology* 1982;144:41-9.
- Gincul R, Dumortier J, Ciocirlan M, Adham M, Queneau PE, Ponchon T, *et al.* Treatment of arteriovenous malformation of the pancreas: A case report. *Eur J Gastroenterol Hepatol* 2010;22:116-20.
- Boudghène F, L'Herminé C, Bigot JM. Arterial complication of pancreatitis: Diagnostic and therapeutic aspects in 104 cases. *J Vasc Interv Radiol* 1993;4:551-8.
- Shimizu K, Sunagawa Y, Ouchi K, Mogami T, Harada J, Fukuda K. External beam radiotherapy for angiographically diagnosed arteriovenous malformation involving the entire pancreas. *Jpn J Radiol* 2013;31:760-5.
- Kishi K, Shirai S, Sato M, Sonomura T. Role of external beam radiotherapy for arteriovenous malformation of the pancreas. *Jpn J Radiol* 2011;29:517-20.
- Shearer DD, Demos TC, Sichlau MJ. Pancreatic arteriovenous malformation: A case report and literature review. *J Radiol Case Rep* 2011;5:8-13.
- Endo K, Sata N, Shimura K, Yasuda Y. Pancreatic arteriovenous malformation: A case report of hemodynamic and three-dimensional morphological analysis using multi-detector row computed tomography and post-processing methods. *JOP* 2009;10:59-63.
- Halpern M, Turner AF, Citron BP. Angiodysplasias of the abdominal viscera associated with hereditary hemorrhagic telangiectasia. *Am J Roentgenol Radium Ther Nucl Med* 1968;102:783-9.
- Ohtani N, Kimoto K, Yoshida S, Tanaka T, Inokuchi H, Kawai K. Pancreatic arteriovenous malformation with pancreatitis involving a pancreatico-venous fistula. *Gastroenterol Jpn* 1992;27:115-20.
- Aida K, Nakamura H, Kihara Y, Abe S, Okamoto K, Otsuki M. Duodenal ulcer and pancreatitis associated with pancreatic arteriovenous malformation. *Eur J Gastroenterol Hepatol* 2002;14:551-4.
- Trapp RG, Breuer RI, Crampton AR, Davis JH, Derman RE, Larson RH, *et al.* Pancreatic duct arteriovenous fistula and the metastatic fat necrosis syndrome. *Dig Dis Sci* 1979;24:403-8.
- Yoon JH, Han SS, Cha SS, Lee SJ. Color doppler ultrasonography of a pancreatic arteriovenous malformation. *J Ultrasound Med* 2005;24:113-7.
- Chuang VP, Pulmano CM, Walter JF, Cho KJ. Angiography of pancreatic arteriovenous malformation. *AJR Am J Roentgenol* 1977;129:1015-8.

Cite this article as: Rajesh S, Mukund A, Bhatia V, Arora A. Transcatheter embolization of pancreatic arteriovenous malformation associated with recurrent acute pancreatitis. *Indian J Radiol Imaging* 2016;26:95-8.

Source of Support: Nil, **Conflict of Interest:** None declared.