

ST-segment elevation myocardial infarction with plaque erosion, to stent or not to stent: utility of intracoronary optical coherence tomography (OCT) imaging—a case report

Kumail Abbas Khan ^{1*}, Mohammed Osheiba ^{1,2}, Anthony Mechery¹, and Sohail Q. Khan ^{1,3}

¹Department of Interventional Cardiology, Queen Elizabeth Hospital, University Hospitals Birmingham NHS Foundation Trust, Mindelsohn Way, Edgbaston, Birmingham B15 2TH, UK; ²Cardiology Department, Faculty of Medicine, Tanta University, Tanta, Egypt; and ³Institute of Cardiovascular Sciences, University of Birmingham, Birmingham B15 2TT, UK

Received 20 August 2021; first decision 27 September 2021; accepted 1 February 2022; online publish-ahead-of-print 15 February 2022

Background

Treating acute myocardial infarction in the setting of insignificant coronary obstruction is an emerging challenge especially with the application of intracoronary imaging like intravascular ultrasound and optical coherence tomography (OCT). The cardiologists dealing with such patients may consider not to stent if there is intracoronary imaging evidence of minimal thrombus without plaque rupture and the vessel appears patent with settling of chest pain and electrocardiogram (ECG) changes.

Case summary

A 47-year-old gentleman presented direct to the emergency department after experiencing retrosternal chest pain with an ECG showing hyperacute anterior T waves. He had ongoing chest pain and was therefore brought to the cardiac cath lab on the primary percutaneous coronary intervention (PCI) pathway. The first picture showed that the proximal left anterior descending (LAD) was occluded (TIMI 0 flow) with evidence of large thrombus burden. Pre-dilating with a 2.5 × 15 mm balloon did not change flow. Aspiration with an Export catheter was carried out for several runs. Most of the thrombus was successfully removed; however, some of it did go into the distal LAD but was successfully retrieved with aspiration catheter. The diagonal branch was occluded with thrombus which was wired followed by thrombus aspiration establishing TIMI II flow. The procedure was covered with Eptifibatide boluses and heparin. After thrombectomy, angiographically there was no obvious lesion present within the LAD. Optical coherence tomography confirmed only mild atheroma with a small amount of plaque and minimal thrombus. There was OCT evidence of plaque erosion without any plaque rupture. The area was above 9 mm² and we decided not to treat that with a stent. The right coronary artery had an anterior take-off and was unobstructed. In conclusion, the patient had successful primary PCI to LAD with thrombus aspiration and balloon angioplasty only. He was placed on 12 months of dual antiplatelets therapy with Aspirin and Prasugrel.

Discussion

This case highlights the rare presentation of patients with acute myocardial infarction with plaque erosion and the usefulness of OCT in formulating a management plan.

Keywords

Case report • Acute myocardial infarction • Primary percutaneous coronary intervention • Plaque erosion • Optical coherence tomography • Dual antiplatelet therapy

ESC Curriculum

3.2 Acute coronary syndrome • 3.4 Coronary angiography

* Corresponding author. Tel: +44 1213714722, Email: sohail.khan@uhb.nhs.uk

Handling Editor: Aref Bin Abdulhak

Peer-reviewers: Constantinos Bakogiannis; Magdy Abdelhamid

Compliance Editor: Oliver Ian Brown

Supplementary Material Editor: Ayse Djahit

© The Author(s) 2022. Published by Oxford University Press on behalf of the European Society of Cardiology.

This is an Open Access article distributed under the terms of the Creative Commons Attribution-NonCommercial License (<https://creativecommons.org/licenses/by-nc/4.0/>), which permits non-commercial re-use, distribution, and reproduction in any medium, provided the original work is properly cited. For commercial re-use, please contact journals.permissions@oup.com

Learning points

- Intracoronary imaging with optical coherence tomography can help guide percutaneous coronary intervention strategy in challenging cases, and plain old balloon angioplasty in combination with thrombus aspiration can be safe and effective in some cases.
- Patients with plaque erosion can present with acute coronary syndrome especially with high thrombus burden. Treatment should be individually tailored based on combination of angiographic and intra coronary imaging.

Introduction

Acute coronary syndrome (ACS) is the umbrella term for the clinical scenarios of myocardial ischaemia including unstable angina, non-ST-segment elevation myocardial infarction (STEMI), and STEMI.¹ Plaque rupture, plaque erosion, and calcified nodule are the main pathologies responsible for most of ACS presentations.² Plaque rupture and erosion are the two most common mechanisms for ACS.³ Plaque erosion with an intact fibrous cap are now responsible for about one-third of ACS and up to two-thirds of non-STEMI cases.⁴ Currently, ACS patients are treated with an intracoronary stent, irrespective of the underlying pathological aetiology. Stents are associated with complications, such as stent thrombosis, restenosis, and neoatherosclerosis although fortunately the incidence of this is low.⁵ A meta-analysis of drug-eluting stents showed around 1% risk of major adverse cardiac events and similar rates of target lesion failure (TLF).⁶ Diagnosis of plaque erosion can be established by optical coherence tomography (OCT).⁷ Optical coherence tomography is a high-resolution imaging modality with fast scanning speed that offers microscopic visualization of the coronary artery. Recent small retrospective studies suggested that patients with ACS caused by plaque erosion might be stabilized with antiplatelet therapy without the need for stenting. The EROSION study showed that patients presenting with ACS with plaque erosion who were managed with dual antiplatelet therapy (DAPT) without stenting remained free of major adverse cardiovascular event for around 1 year.⁸ Aspirin plus a P2Y₁₂ inhibitor constitute DAPT to prevent ischaemic events after coronary stenting at the expense of increased bleeding risks. In the absence of severe luminal narrowing and distorted vascular structure, it is conceivable that ACS caused by plaque erosion can be stabilized without stent implantation.⁹

Timeline

Day 0	Worsening chest pain and electrocardiogram changes of hyperacute T waves in anterior leads. Primary percutaneous coronary intervention (PCI) with thrombus aspiration and optical coherence tomography performed without stenting.
Day 1	Complete relief of symptoms post-primary PCI. Echocardiogram showed normal left ventricular size with regional wall motion abnormalities affecting the left anterior descending territory. Estimated ejection fraction 48% ± 5%.
Day 3	Discharged home after 72 h of stability.
5 months	The patient remains pain free and asymptomatic.

Case presentation

A 47-year-old gentleman, presented direct to the emergency department with central chest pain. He was a non-smoker with no history of hypertension, diabetes mellitus, or family history of ischaemic heart disease. He had no history of illicit drug use. He experienced retrosternal chest pain of 6 h duration radiating to both shoulders. A 12-lead electrocardiogram showed hyperacute T waves in anterior chest leads (Figure 1). Clinical examination was unremarkable. He had ongoing chest pain and was transferred to the cardiac cath lab on the primary PCI pathway. He was given 300 mg of Aspirin and 60 mg of Prasugrel. A bolus of 5000 IU of heparin was given with the aim to achieve activated clotting time of 300 s. Radial access coronary angiogram showed occlusion of proximal left anterior descending (LAD) (TIMI 0 flow) with angiographic evidence of large thrombus burden (Figure 2). Left main stem and left circumflex artery were free from disease. Pre-dilatation with a 2.5 × 15 mm balloon did not change flow and therefore aspiration with an Export catheter was carried out which was successful in retrieving a large amount of thrombus (Figure 3). The procedure was covered with Eptifibatide bolus. After thrombectomy, there was no obvious angiographic lesion within the LAD with TIMI III flow. We therefore performed OCT which confirmed only mild atheroma with a small amount of plaque and minimal red thrombus. There was OCT evidence of plaque erosion without any plaque rupture (Figures 4 and 5). The luminal area was above 9 mm² and we decided not to treat this with a stent. The right coronary artery had an anterior take-off and was unobstructed. Laboratory tests post-procedure showed high-sensitivity troponin I level of >50 000 ng/L (normal <34 ng/L) with normal lipid profile. Echocardiogram post-PCI showed normal left ventricular size with impaired systolic function with regional wall motion abnormalities affecting the LAD territory. Estimated ejection fraction 48% ± 5%. He was discharged home after 72 h and placed on 12 months of DAPT with Aspirin 75 mg o.d. and Prasugrel 10 mg o.d. The patient has remained angina free so far.

Discussion

Coronary atherosclerosis, usually with superimposed coronary thrombosis is the cause of almost all ACS.¹⁰ Plaque rupture, and plaque erosion are the morphologies primarily responsible for thrombosis, with plaque rupture being the most common cause of acute myocardial infarction, especially in men.² Optical coherence tomography studies by Kubo et al.,¹¹ in patients presenting with acute myocardial infarction showed that the incidence of plaque rupture was 73%, whereas plaque erosion was 23% and incidence of thin fibroatheroma was 83% in patients with plaque rupture. In the EROSION study, plaque erosion occurred in 25% of patients with ACS and

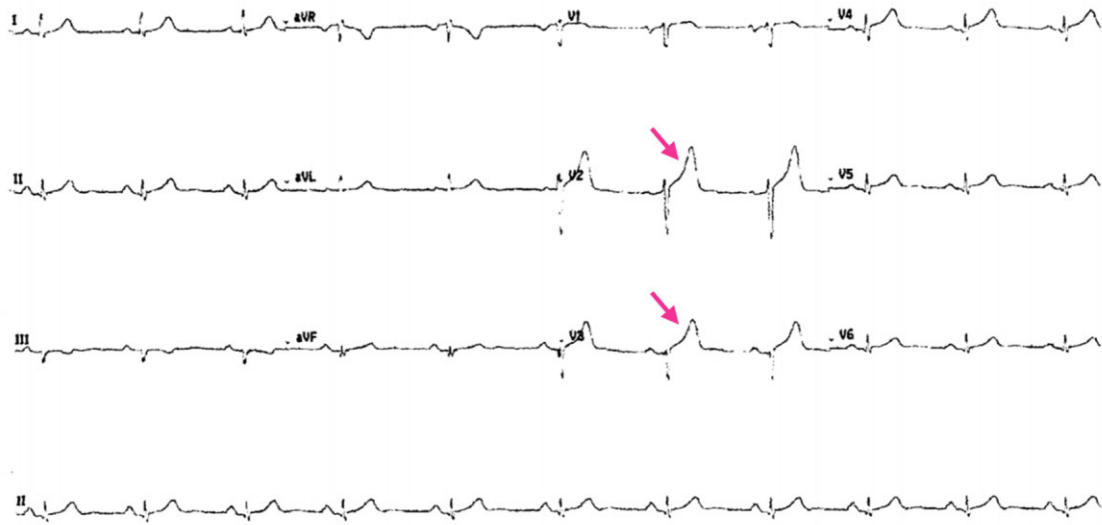


Figure 1 Electrocardiogram showing hyperacute T waves in anterior leads (red arrows).

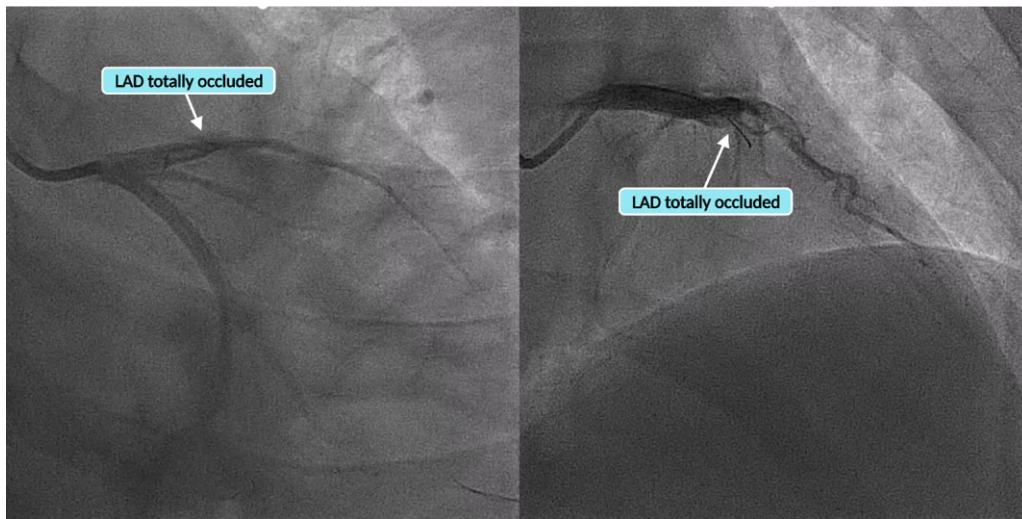


Figure 2 Angiogram showing left anterior descending total occlusion from proximal course.

these patients were successfully treated with medical therapy (aspirin and ticagrelor) without the need for stenting.⁸ In this study, 92.5% of ACS patients with erosion remained free from major adverse cardiovascular event at 1 year, suggesting the possibility of medical therapy of such patients. The EROSION study enrolled 55 patients with 49 patients completing 1-year follow-up. In 33 (62.3%) patients, glycoprotein inhibitor was used and in 44 (83.0%) manual thrombectomy was performed. Optical coherence tomography was used to define the underlying vascular pathology as it has a 10-fold higher image resolution compared to intravascular ultrasound.

The current European Society of Cardiology (ESC) guidelines give a class 1A recommendation for primary PCI with stenting over balloon angioplasty. In our case we felt that stenting was not essential, this approach was individualised for this patient and a deviation from the guidelines. This however was based on absence of significant stenosis with restoration of TIMI 3 flow and intracoronary imaging evidence of non-ruptured plaque.

Regarding our case, we were successful in establishing TIMI 3 flow with only balloon inflation and thrombus aspiration. Optical coherence tomography showed minimal thrombus burden and intact

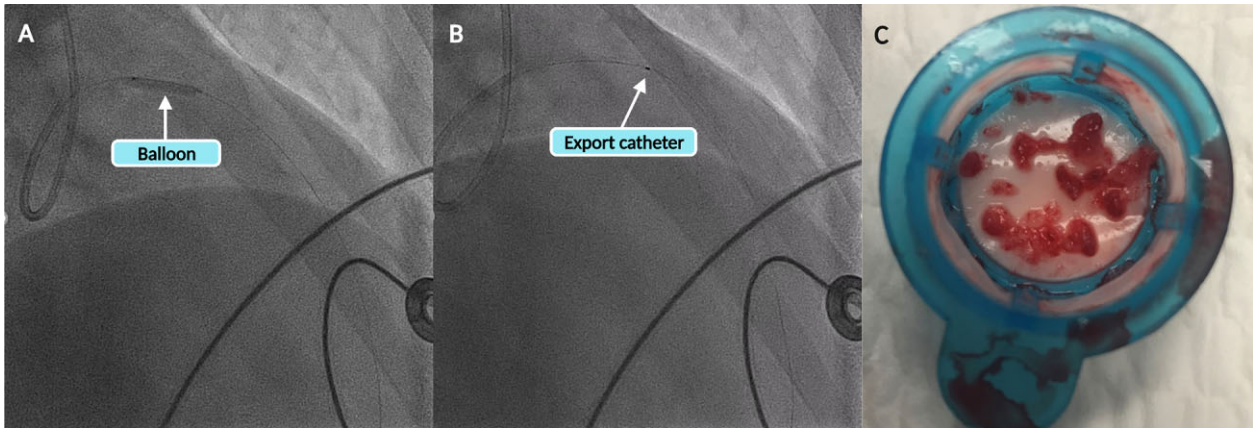


Figure 3 (A) Pre-dilatation with 2.5 × 15 mm balloon. (B) Thrombus aspiration using Export catheter. (C) Aspirated thrombus.

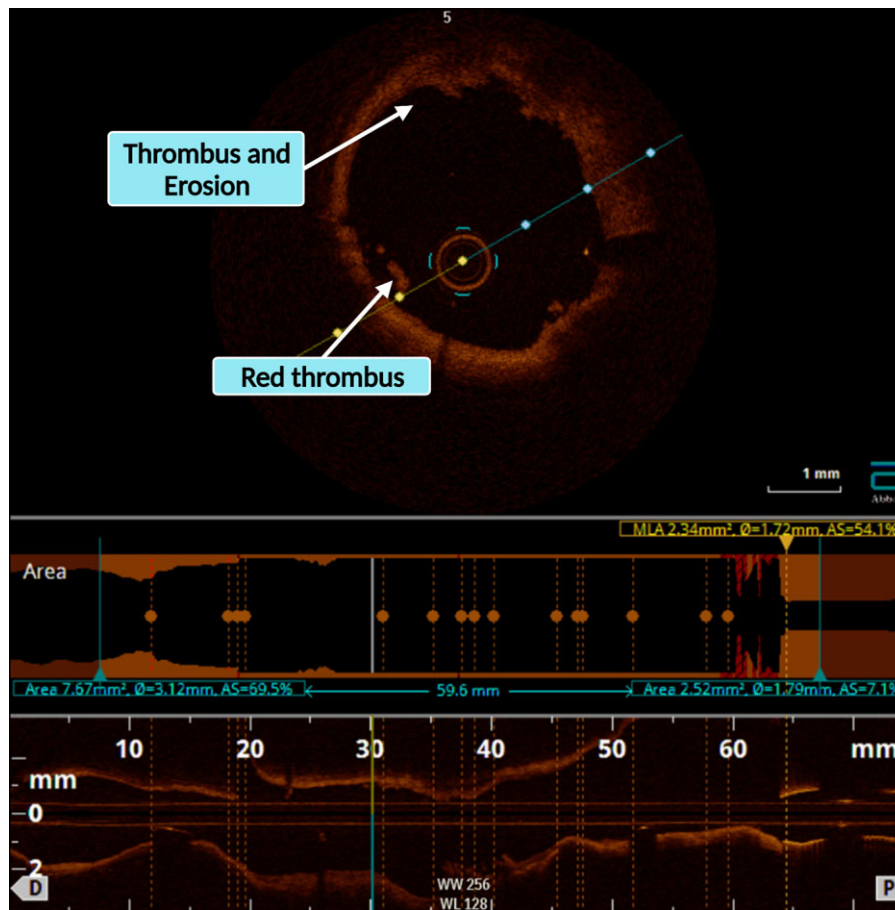


Figure 4 Optical coherence tomography showing red thrombus overlying lipidic plaque with evidence of plaque erosion.

fibrous cap of plaque, confirming plaque erosion. Vessel luminal analysis revealed no significant stenosis. Keeping in mind the favourable outcomes of medical management without stenting in the EROSION

study, we opted out of a stent strategy. We decided to place the patient on dual antiplatelet therapy with Aspirin and Prasugrel and monitored closely as an inpatient for 72 h and outpatient review after

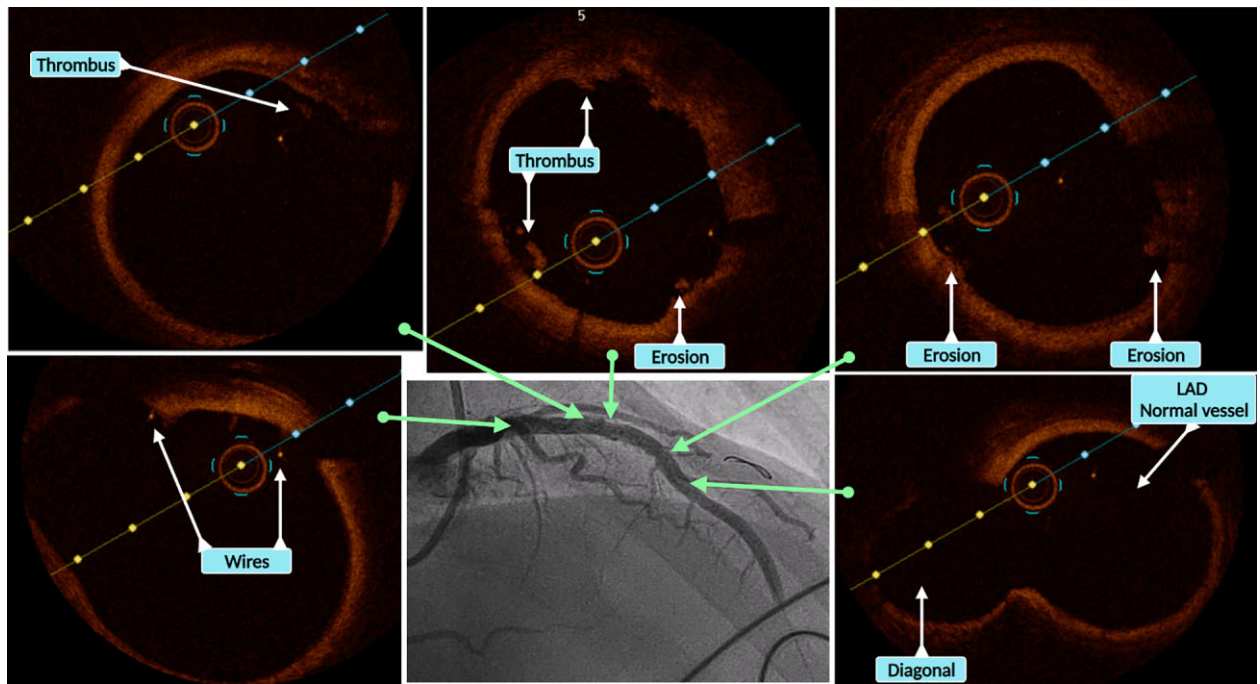
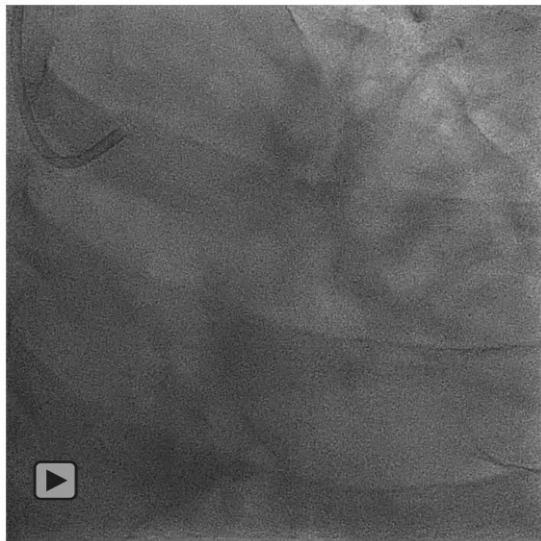
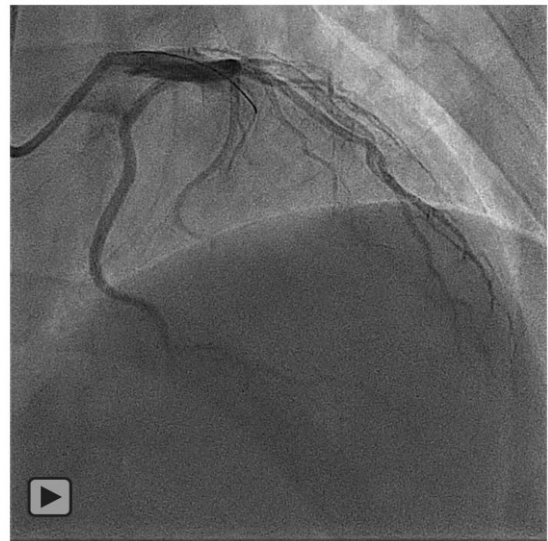


Figure 5 Optical coherence tomography images at different angiographic coordinates showing minimal thrombus and non-significant luminal narrowing.



Video 1 PA Caudal view showing proximal LAD occlusion.

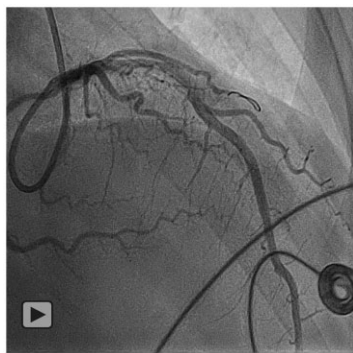


Video 2 PA Cranial view showing proximal LAD occlusion.

1 and 2 months. The patient remained electrically and haemodynamically stable and pain free. He remained pain free and asymptomatic after 5 months. This strategy has been useful in a previous case of acute myocardial infarction with OCT proven plaque erosion, in this

case, the avoidance of a stent was principally due to idiopathic thrombocytopenic purpura with uneventful follow-up at 1 year.¹²

Recurrent stenosis in the segment treated without stenting is regarded as a major concern in percutaneous old balloon angioplasty.



Video 3 PA Cranial view showing angiographic success.

High incidence of post-angioplasty dissection especially in narrowed vessels is the main factor for restenosis. We had a 3.5 mm OCT confirmed vessel diameter and images ruled out any dissection or plaque rupture. In addition, OCT images analysis was consistent with plaque erosion rather than rupture with no calcification. These images looked reassuring for risk of acute recoil and vessel closure. There are only few studies emphasizing individualized approaches based on intraluminal analysis by intracoronary imaging especially OCT. Stent-less strategy is expected to gain pace with increasing appreciation of plaque erosion as a cause of ACS, combined with implementation and better analysis of OCT images. The EROSION study, although a small, non-randomized, single-centre study, has provided a good platform for a stent-less approach for management of plaque erosion with continued DAPT.

Conclusion

This case highlights the need for establishing dynamic decision-making in dealing with ACS patients. Our case is unique in that there is limited data and uncertainty favouring a stent-less approach in patients with STEMI. Furthermore, we have highlighted the importance of intracoronary imaging in decision-making which was useful in establishing the diagnosis and determining treatment strategy.

Lead author biography



Dr Kumail Abbas Khan graduated from Army Medical College, Pakistan in 2003. He was awarded a fellowship in medicine (FCPS Medicine) in 2014 and a fellowship in cardiology (FCPS Cardiology) in

2020. Currently, he is specializing in complex percutaneous coronary intervention at the Queen Elizabeth Hospital (University Hospitals Birmingham NHS Foundation Trust) under the supervision of Dr Sohail Q. Khan, Consultant Interventional Cardiologist.

Supplementary material

[Supplementary material](#) is available at *European Heart Journal - Case Reports* online.

Slide sets: A fully edited slide set detailing this case and suitable for local presentation is available online as [Supplementary data](#).

Consent: The authors confirm that written consent for submission and publication of this case report including images and associated text has been obtained from the patient in line with COPE guidance.

Conflict of interest: None declared.

Funding: None declared.

References

- Overbaugh KJ. Acute coronary syndrome. *Am J Nurs* 2009;**109**:42–52; quiz 53.
- Falk E, Nakano M, Bentzon JF, Finn AV, Virmani R. Update on acute coronary syndromes: the pathologists' view. *Eur Heart J* 2013;**34**:719–728.
- Hu S, Zhu Y, Zhang Y, Dai J, Li L, Dauerman H et al. Management and outcome of patients with acute coronary syndrome caused by plaque rupture versus plaque erosion: an intravascular optical coherence tomography study. *J Am Heart Assoc* 2017;**6**:e004730.
- Virmani R, Kolodgie FD, Burke AP, Farb A, Schwartz SM. Lessons from sudden coronary death: a comprehensive morphological classification scheme for atherosclerotic lesions. *Arterioscler Thromb Vasc Biol* 2000;**20**:1262–1275.
- Niccoli G, Montone RA, Di Vito L, Gramagna M, Refaat H, Scalone G et al. Plaque rupture and intact fibrous cap assessed by optical coherence tomography portend different outcomes in patients with acute coronary syndrome. *Eur Heart J* 2015;**36**:1377–1384.
- Taglieri N, Bruno AG, Ghetti G, Marrozzini C, Saia F, Galíe N et al. Target lesion failure with current drug-eluting stents: evidence from a comprehensive network meta-analysis. *JACC Cardiovasc Interv* 2020;**13**:2868–2878.
- Jia H, Abtahian F, Aguirre AD, Lee S, Chia S, Lowe H et al. *In vivo* diagnosis of plaque erosion and calcified nodule in patients with acute coronary syndrome by intravascular optical coherence tomography. *J Am Coll Cardiol* 2013;**62**:1748–1758.
- Xing L, Yamamoto E, Sugiyama T, Jia H, Ma L, Hu S et al. EROSION study (effective anti-thrombotic therapy without stenting: intravascular optical coherence tomography-based management in plaque erosion): a 1-year follow-up report. *Circ Cardiovasc Interv* 2017;**10**:e005860.
- Kramer MC, Rittersma SZ, de Winter RJ, Ladich ER, Fowler DR, Liang YH et al. Relationship of thrombus healing to underlying plaque morphology in sudden coronary death. *J Am Coll Cardiol* 2010;**55**:122–132.
- Crea F, Liuzzo G. Pathogenesis of acute coronary syndromes. *J Am Coll Cardiol* 2013;**61**:1–11.
- Kubo T, Imanishi T, Takarada S, Kuroi A, Ueno S, Yamano T et al. Assessment of culprit lesion morphology in acute myocardial infarction: ability of optical coherence tomography compared with intravascular ultrasound and coronary angiography. *J Am Coll Cardiol* 2007;**50**:933–939.
- Al-Lawati K, Osheiba M, Lester W, Khan SQ. Management of acute myocardial infarction in a patient with idiopathic thrombocytopenic purpura, the value of optical coherence tomography: a case report. *Eur Heart J Case Rep* 2020;**4**:1–5.