

Received: 2013.10.07  
Accepted: 2013.10.22  
Published: 2014.02.03

ISSN 1941-5923  
© Am J Case Rep, 2014; 15: 56-59  
DOI: 10.12659/AJCR.889868

## Sudden onset of coma in a 70-year-old woman with cryoglobulinemia

Authors' Contribution:  
Study Design A  
Data Collection B  
Statistical Analysis C  
Data Interpretation D  
Manuscript Preparation E  
Literature Search F  
Funds Collection G

ABCDEF 1 **Gennaro Pagano\***  
BCDEF 1 **Klara Komici\***  
BD 1 **Grazia Daniela Femminella**  
BD 1 **Claudio de Lucia**  
BC 2 **Marta Ianniciello**  
BCDEF 1 **Dario Leosco**  
DE 1,3 **Nicola Ferrara**  
BCDEF 1,3 **Giuseppe Rengo**

1 Department of Translational Medical Sciences, Federico II University of Naples, Naples, Italy  
2 Epilepsy Center, Department of Neurological Sciences, Federico II University of Naples, Naples, Italy  
3 Division of Cardiology, "Salvatore Maugeri" Foundation – IRCCS – Institute of Telese Terme, Telese Terme (BN), Italy

\* These authors contributed equally to this work

Corresponding Author: Dario Leosco, e-mail: [dleosco@unina.it](mailto:dleosco@unina.it)

**Patient:** Female, 70  
**Final Diagnosis:** Chronic Hepatitis C  
**Symptoms:** Coma  
**Medication:** —  
**Clinical Procedure:** Plasmapheresis  
**Specialty:** Neurology

**Objective:** Unusual clinical course





**Background:** Hepatitis C Virus (HCV)-related chronic hepatitis can be associated with mixed cryoglobulinemia (MC). Although several MC cases have been described, the wide variety of symptoms often makes diagnosis challenging.

**Case Report:** We describe a sudden onset of coma in a 70-year-old woman with an undiagnosed chronic hepatitis C infection related to MC. Head CT did not show any important pathology. Laboratory tests showed leucocytosis, but it was not possible to identify any pathogenic microorganism. Examination of cerebrospinal fluid did not show any pathology. There was a strongly positive test result for rheumatoid factor (409 U/l) and hypocomplementemia (C4 0.04 g/l). Laboratory assay was positive for antibodies against HCV and HCV RNA. The cryoglobulins were positive and after treatment with plasmapheresis her conditions improved.

**Conclusions:** In this case, the cryoglobulins laboratory exam was very helpful for the diagnosis. This test could be considered in the early management of elderly patients with sudden onset of coma.

**MeSH Keywords:** Plasmapheresis • Plasmapheresis • Cryoglobulinemia • Hepatitis C, Chronic • Coma • Cryoglobulinemia

Full-text PDF: <http://www.amjcaserep.com/download/index/idArt/889868>

 1164  —  2  13

## Background

Mixed cryoglobulinemia (MC) type II is characterized by the formation of cold-precipitate immune complexes composed of monoclonal IgM and polyclonal IgG [1]. It is frequently associated with chronic hepatitis C virus (HCV) infection [2]. Clinical presentation of this syndrome includes purpura, arthralgia, and weakness and is often associated with extra-hepatic involvement such as neuropathy, vasculitis, and glomerulonephritis [3]. This wide range of clinical presentation can make diagnosis difficult, especially in elderly patients with several comorbidities [4,5]. We report the case of a neurological manifestation of MC type II in a woman affected by undiagnosed chronic HCV.

The aim of this case report is to emphasize the diagnostic role of cryoglobulins laboratory testing in the early management of elderly patients with sudden onset of coma and positive antibodies against HCV.

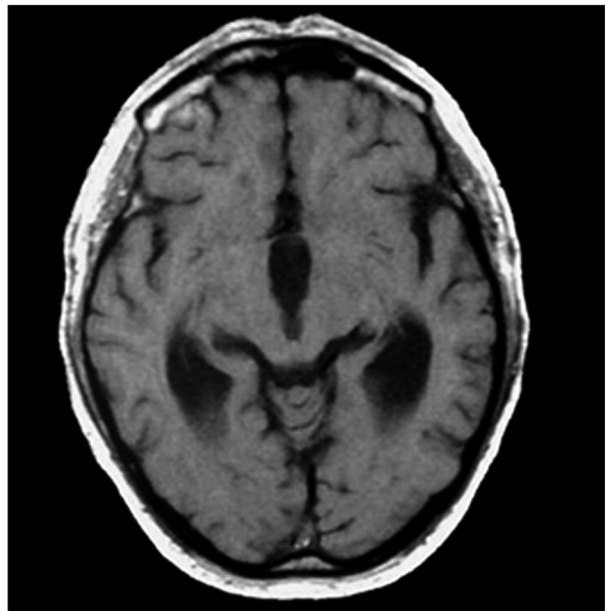
## Case Report

A 70-year-old woman with a history of arterial hypertension and dyslipidemia was admitted to the Emergency Department because she suddenly became drowsy and did not respond to verbal commands. The patient lived with her daughter, who noticed the sudden worsening of her mother's health condition. Approximately 2 weeks before, the patient complained of bilateral hand and foot pain.

At first examination the patient was unconscious, her speech was incomprehensible, and she had a Glasgow coma scale (GCS) score of 6 points. The initial differential diagnosis included hemorrhagic stroke, transient ischemic attack or ischemic stroke, and metabolic coma. Laboratory testing showed normal complete blood count, normal sodium and potassium level, normal glycemia, normal ammonia blood level, normal blood urea nitrogen, and elevated aspartate transaminase (151 U/l). A head CT did not show any important pathology. After Emergency Department protocol procedures, the patient was admitted to the geriatric ward.

Twenty-four hours after admission to the geriatric ward, the patient presented fever up to 39.3°C, leucocytosis with fluctuation of white blood cell count (WBC) ( $10.8\text{--}20 \times 10000/\mu\text{L}$ ) and platelets count ( $100000\text{--}674000/\mu\text{L}$ ) associated with normocytic anemia (hemoglobin 11.2 g/dl), low fibrinogen level (100 mg/dl), and normal C reactive protein (CRP) (3.3 mg/dl). Empiric antibiotic therapy was started.

Chest radiography did not show any pathology. The microbiological blood exam for septicemia and urine culture exam did not



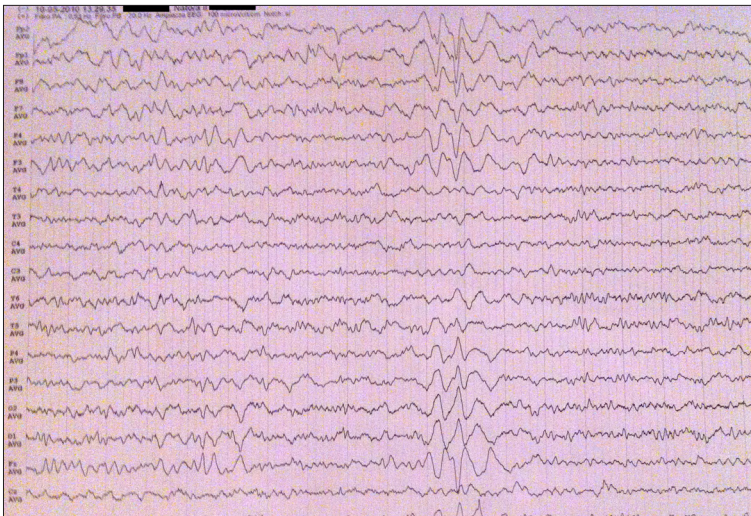
**Figure 1.** Cerebral Magnetic Resonance imaging showing increased subarachnoid space volume without increased ventricular volume.

show the presence of pathogenic microorganisms. Abdominal ultrasound imaging showed moderate liver steatosis without evidence of cirrhosis or focal hepatic lesions.

She was referred to the Neurology Unit with a suspected diagnosis of encephalitis. Cerebral MRI (Figure 1) showed an increased subarachnoid space volume without increased ventricular volume. It was followed by a lumbar puncture that showed normal cerebrospinal fluid, which excluded the diagnosis of encephalitis. An electroencephalogram (Figure 2) showed severe metabolic encephalopathy.

There was a low complement level (C4) (0.04 g/dl, compared to normal range of 0.10–0.40 g/dl) and anti-nuclear antibodies (ANA) were negative. Rheumatoid factor was elevated (409 U/l, compared to normal range of 0–15 U/l). A protein electrophoresis was requested and showed the presence of monoclonal proteins IgM/k and IgG/k. Bone marrow aspiration was performed, excluding the diagnosis of multiple myeloma. The patient tested positive for antibodies against HCV and the diagnosis of hepatitis was confirmed by the presence of HCV-RNA. Her daughter did not recall any risk factors for HCV infection.

The peripheral smear performed at 37°C showed normal WBC. Cryoglobulins tested several times were positive, presenting a cryocrit of 15%. According to the cryoglobulins test result and the presence of HCV-RNA and HCV antibodies, we excluded other diagnoses (encephalitis, multiple myeloma, or autoimmune connective tissue disease) and made a diagnosis of MC related to HCV infection.



**Figure 2.** Electroencephalogram showing diffuse slow wave, suggestive for metabolic encephalopathy.

Because of advanced age and her critical general conditions, treatment with interferon 2 and ribavirin was considered inappropriate. Treatment with plasmapheresis was started and after several therapeutical cycles the patient recovered consciousness. Her general conditions improved and laboratory findings (checked several times) were within normal values.

## Discussion

Chronic HCV infection is the most common cause of MC. In fact, about 80% of patients with diagnosis of MC are HCV-positive. Importantly, the majority of HCV-positive patients are asymptomatic and MC is detectable in only about 30% of them. In addition to HCV infection, other main causes of MC are B-cell lymphoma, multiple myeloma, HBV, HIV, systemic lupus erythematosus, and rheumatoid arthritis [6]. About 10% of cases are regarded as idiopathic. The clinical presentation of MC is associated with fatigue, fever  $>38^{\circ}\text{C}$ , fibromyalgia, arthralgia, arthritis, purpura, Raynaud's phenomenon, and skin ulcer. Kidney, liver, and peripheral nervous system involvement is also common [7]. The involvement of the peripheral nervous system is almost always present and is the first clinical sign [8]. In most of the cases, MC is suspected when HCV-positive patients show loss of strength, pain, pruritus, and paresthesias. Less frequent is central nervous system (CNS) involvement, usually characterized by dysarthria, hemiplegia, confusional state, cognitive impairment, and altered consciousness. In the literature, a few cases of MC related to HCV are described, but never in patients with undiagnosed hepatitis [9–11]. The laboratory findings in MC are characterized by reduced serum C4, positive serum RF, positive serum M component, false leucocytosis, and normal PCR value. The detection of serum cryoglobulins is essential for diagnosis. The pathogenic mechanisms include the effects of circulating cryoglobulins, binding of large immune IgG and IgM

complexes in the endothelial cell receptors following vascular deposition, causing inflammation and occlusion of small or medium-sized blood vessels.

The clinical presentation of our patient was characterized by altered consciousness (GCS of 6 points), fever, leucocytosis with normal PCR value associated with positive HCV markers and serum cryoglobulins, which led us to the diagnosis of MC related to chronic HCV. Important differential diagnoses, such as hemorrhagic ictus, metabolic coma, or myeloma multiple or encephalitis were previously excluded.

The peculiar characteristic of our clinical report is the unusual onset of cryoglobulinemia with presence of CNS symptoms without any common dermatological lesions such as purpura or pruritus. In emergency departments, many patients present with cognitive disorders or coma, but most of these cases are related to neurological disease, injuries, or metabolic disorders. The pathogenesis of this severe manifestation could be due to completely different mechanisms, such as ischemic, hemorrhagic, metabolic, or degenerative disorders. It is still not clear why our patient presented only CNS manifestation without any other systemic symptoms, but the efficacy of plasmapheresis, which resulted in normalization of health conditions, supports the hypothesis that the coma was related to cryoglobulins. Plasmapheresis removes the immunoglobulin complexes from the circulation, interrupting the immune-complex pathogenesis [12]. The quality and quantity of cryoglobulins modification induced by plasmapheresis could explain the rapid improvement in our patient's clinical condition. From the present therapeutical guidelines in patients with mild-moderate disease activity, the combination of ribavirin with pegylated  $\text{INF}\alpha$  is recommended. Patients presenting with severe clinical status require aggressive treatment. The use of plasmapheresis and/or corticosteroids is associated with a good outcome [13].

## Conclusions

We reported the clinical case of an older woman with sudden onset of coma related to cryoglobulins. Based on our report,

sudden onset of coma without any other plausible cause should be immediately tested for HCV infection and cryoglobulins in older adults.

## References:

1. Ferri C: Mixed cryoglobulinaemia. *Orphanet J Rare Dis*, 2008; 3: 25
2. Ferri C, Sebastiani M, Giuggioli D et al: Mixed cryoglobulinemia: demographic, clinical, and serologic features and survival in 231 patients. *Semin Arthritis Rheum*, 2004; 33(6): 355–74
3. Ramos-Casals M, Stone JH, Cid MC, Bosch X: The cryoglobulinemias. *Lancet*, 2012; 379(9813): 348–60
4. Rengo F, Parisi V, Rengo G et al: Instruments for geriatric assessment: new multidimensional assessment approaches. *J Nephrol*, 2012; 25(Suppl.19): S73–78
5. Rocco N, Rispoli C, Pagano G et al: Undertreatment of breast cancer in the elderly. *BMC Surgery*, 2013; 13(Suppl.2): S26
6. Trejo O, Ramos-Casals M, García-Carrasco M et al: Cryoglobulinaemia: study of etiologic factors and clinical and immunologic features in 443 patients from a single center. *Medicine (Baltimore)*, 2001; 80: 252–62
7. Faustini A, Colais P, Fabrizi E et al: Hepatic and extra-hepatic sequelae, and prevalence of viral hepatitis C infection estimated from routine data in at-risk groups. *BMC Infect Dis*, 2010; 10: 97
8. Gemignani F, Melli G, Inglese C, Marbini A: Cryoglobulinemia is a frequent cause of peripheral neuropathy in undiagnosed referral patients. *J Peripheral Nerv Syst*, 2002; 7(1): 59–64
9. Filippini D, Colombo F, Jann S et al: Central nervous system involvement in patients with HCV-related cryoglobulinemia: review and a case report. *Reumatismo*, 2002; 54(2): 150–55
10. Rocco N, Rispoli C, Pagano G et al: Breast cancer surgery in elderly patients: Postoperative complications and survival. *BMC Surgery*, 2013; 13(Suppl.2): S25
11. Origgi L, Vanoli M, Carbone A et al: Central nervous system involvement in patients with HCV-related cryoglobulinemia. *Am J Med Sci*, 1998; 315(3): 208–10
12. Reik L Jr, Korn JH: Cryoglobulinemia with encephalopathy: successful treatment by plasma exchange. *Ann Neurol*, 1981; 10(5): 488–90
13. Rieu V, Cohen P, André MH et al: Characteristics and outcome of 49 patients with symptomatic cryoglobulinaemia. *Rheumatology (Oxford)*, 2002; 41(3): 290–300