

Comparative evaluation of bite forces in patients after treatment of mandibular fractures with miniplate osteosynthesis and internal locking miniplate osteosynthesis

Saurab Kumar, Shashank Reddy Gattumedhi¹, Bharat Sankhla², Akshay Garg³, Ekta Ingle⁴, Namrata Dagli⁵

Department of Oral and Maxillofacial Surgery, Darshan Dental College and Hospital, Udaipur, Rajasthan, ¹General Dental Practitioner, Vokkaligara Sangha Dental College and Hospital, Bangalore, Karnataka, ²Department Oral Pathology, Government Dental College and Hospital, Jaipur, ³Department of Endodontics, Jaipur Dental College and Hospital, Jaipur, Rajasthan, ⁴Department of Oral Medicine and Radiology, Vasantdada Dental College, Sangli, Maharashtra, ⁵Editor in chief, Journal of Health Research and Review, Ahmedabad, Gujarat, India

Corresponding author (e-mail: sk053772@gmail.com)

Dr. Saurab Kumar, Reader, Department Oral Maxillofacial Surgery, Darshan Dental College and Hospital, Udaipur, Rajasthan, India.

Abstract

Aims and Objectives: The aim of present study was to compare the stability of fractured mandibular fragments under functional load, when fixed with conventional miniplate and internal locking miniplate. **Materials and Methods:** Bite force (in kg) recorded in twenty mandible fractured patients and fifty normal healthy individuals. Bite force was measured at incisor and molar regions. Comparative evaluation of bite force generated was performed between 10 cases treated with conventional miniplates and 10 cases treated with internal locking miniplates. Bite force generated by patients in mandibular fracture between symphysis and the angle of mandible was recorded in incisor and molar regions preoperatively. The fracture fragments were fixed using the above fixation techniques. Then same recording was undertaken on the 7th, 14th, 21st, 28th, and 90th days postoperatively. **Results:** Bite force generated by patients treated with locking plates at the 7th, 14th, 21st, 28th, and 90th postoperative days was significantly higher as compared to those in patients treated with miniplates. **Conclusion:** It was observed in our study that the locking plate/screw system offers significant advantages over the conventional plating system. There are no intraoperative difficulties associated with placement of the plate.

Key words: Bite force, internal locking miniplates, miniplate

INTRODUCTION

Fixation with plate/screw system is now a standard treatment modality for fractures, osteotomies, and reconstruction of defects of the cranio-maxillofacial

skeleton. Various types of plating systems have been developed from time to time for fixing fractures and in the continuity defects of the mandible.

In conventional bone plate/screw system, the plate must be perfectly adapted to the underlying bone to prevent alterations in anatomically fractured fragments.^[1] There have also been incidents of loosening of one or more screws during the convalescence period, resulting in changes in occlusal relationship.^[2]

This problem, to an extent, has been overcome by the development of locking plate/screw systems where the

Access this article online	
Quick Response Code: 	Website: www.jispcd.org
	DOI: 10.4103/2231-0762.144575

screw locks not only the bone but also the plate and serves as a mini-internal fixator.^[2] It is assumed that this relationship of plate and screw will reduce the number of fixation screws per osseous fragment,^[1,3] and thus, minimal hardware can achieve the same fixation objectives as with bulkier plating systems.

Cortical necrosis, which is observed in compression plates, is not noticed in locking plates since the plate gains its rigidity by locking the screw rather than by being compressed against the bone.^[2,4,5] To gain adequate stability, the locking plate need not be compressed or adapted against the underlying bone; thus, stripping and loosening of the screws is not noticed in this system.^[2] The locking system negates the disadvantages of the conventional system. There is minimal interference with underlying cortical vascular supply and primary stability provided by the “internal fixator” is greater than that obtained in the conventional system.

This study was done to substantiate the possible advantages that are offered by new internal locking miniplates over conventional miniplates. Bite force generated by the patient was recorded preoperatively and postoperatively after fixation of these plates on different days in patients for the same type of fractures of mandible. Comparative evaluation of bite force was done, so that masticatory efficiency offered by these two plating systems can be assessed, which in turn gives an idea of the stability achieved postoperatively after fixation.

MATERIALS AND METHODS

This study was carried out on 20 patients who suffered from fractures of mandible in the region from symphysis to the body of the mandible.

Inclusion criteria

- No sex predilection
- Normal healthy individuals with no debilitating systemic diseases
- Single, non-comminuted mandibular fractures excluding condylar and coronoid processes
- All patients who could be treated either intraorally or extraorally
- Follow-up at regular intervals for a period of 6 weeks.

Preoperatively, bite force recording was done on fractured and contralateral side before fixing Erich arch bar. Patients were randomly divided into two groups:

Group A- Ten patients who had undergone osteosynthesis for the fracture of mandible using single 4-hole, with/without gap, stainless steel internal locking miniplate (2.0 mm system) (SK Surgicals, Pune, Maharashtra)

Group B- Ten patients who had undergone osteosynthesis for mandibular fracture using two 4-hole, with/without gap, stainless steel conventional miniplates (2.0 mm system) (SK Surgicals)

Operative technique

Patients were operated under anesthesia (general/local) following strict asepsis. Intraoral approach was used in the majority of cases. Sublabial/degloving incision was made; reflection of mucoperiosteal flap was done leading to exposure of fracture fragments. Extraoral, either submental or submandibular, incision was made. Blunt dissection was performed; periosteum was incised leading to exposure of fractured fragments. In a few patients, the fractured fragments were exposed, dissecting through the existing extraoral lacerations. Anatomical reduction of fracture fragments was done, followed by intermaxillary fixation with the help of tie wires. Bone plates were placed along the lines of osteosynthesis, as described by Champy.

Fixation in Group A patients was done using single 4-hole, with/without gap, stainless steel internal locking miniplate, keeping at least two holes on each side of the fracture line [Figure 1].

Fixation in Group B patients was done using two stainless steel, 4-hole, with/without gap miniplates, keeping at least two holes on each side of the fracture line [Figure 2].

After bone plate fixation, intermaxillary fixation was released and the occlusion checked. Soft tissue closure was done in layers. All patients were placed on intermaxillary fixation with elastics for 1 week.

Bite force recording

Bite force recordings were made using indigenous Bite Force Recorder. Bite forces were recorded at the operated site. The subjects were instructed to bite on the pads of bite force gauge. This was accomplished by instructing the subject to bite as forcefully as possible and the bite force values were recorded. Bite force recordings were done preoperatively before fixing Erich arch bar and postoperatively at each follow-up (7th, 14th, 21st, 28th, and 90th day) [Figures 3 and 4].

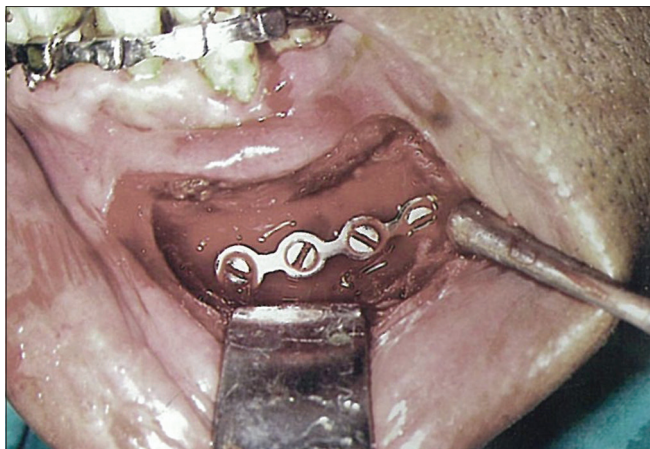

Figure 1: Fixation with single inter-locking plate

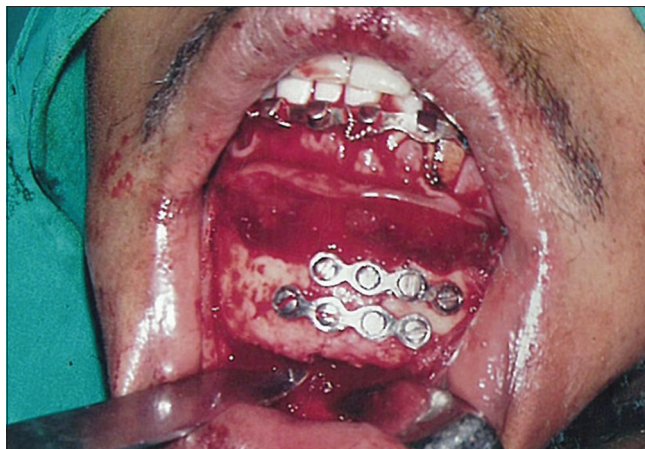


Figure 2: Fixation with two miniplates

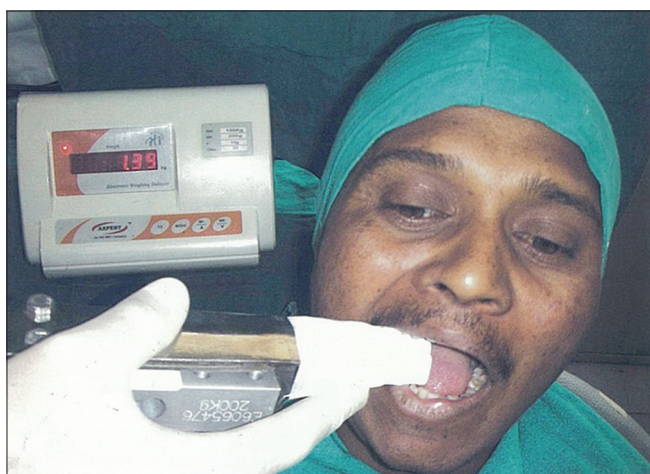


Figure 3: Bite force recording on non-fracture site

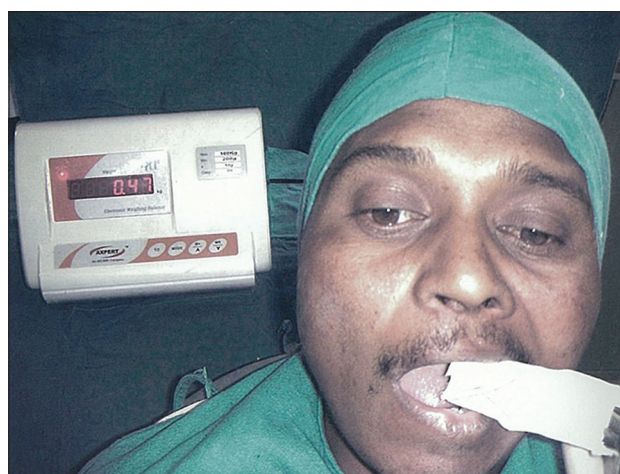


Figure 4: Bite force recording on fracture site

Control group

Bite force measurements were made using indigenous Bite Force Recorder in 50 normal healthy individuals belonging to different age groups at different sites between incisors and molar region. Mean value was calculated for the different regions. Mean bite force was 15 kg and 20 kg for females and males, respectively, at the incisor region and 33 kg and 40 kg for females and males, respectively, at the molar region.

Out of the 20 patients treated, 18 (90%) were males and 2 (10%) were females; the percentage of sexual distribution was same in both the groups, with a mean age of 27.2 years. The youngest patient was 14 years old and the eldest was 46 years old. The etiology was road traffic accident in 12 (60%) patients, assault in 1 (5%) patient, and miscellaneous causes in the remaining 7 (35%) patients which include falls or occupational injuries. The duration of time from injury to the time at which definitive management was accomplished ranged from 1 to 10⁰ days, with a mean of 7.4 days/3.5 days.

Out of 20 fractures, 7 (35%) patients had single parasymphysis fracture and 13 (65%) patients had body fractures. In 10 patients, step and deformity was noticed on palpation, there was associated existing extraoral soft tissue injury in 6 (30%) patients, and clinical examination was difficult in 7 (35%) patients due to reduced mouth opening.

Patients treated using locking plates (group A)

After application of locking plates, all the fractures appeared to be well reduced and stable. The postoperative radiograph confirmed the adequacy of reduction. Postoperatively, mobility of fracture fragments or occlusal discrepancies were not noticed in any patient. Two (20%) patients developed infection at the site of wound, which was drained and got resolved on administration of antibiotics.

Patients treated using conventional miniplates (group B)

After application of conventional miniplates, all fractures appeared to be well reduced and stable. The

postoperative radiograph confirmed the adequacy of reduction. Postoperatively, mobility of fracture fragments or occlusal discrepancies were not noticed.

Comparative evaluation of bite force

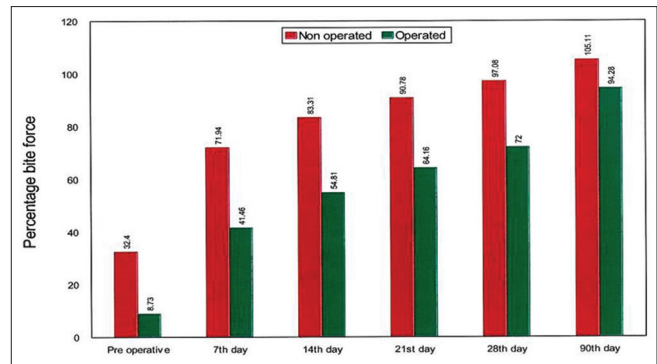
The difference in mean bite forces preoperatively was 7.47 kg, when comparison was done between fractured and contralateral non-fractured sites in all 20 patients over the control group. Postoperatively on the 7th day, it was 9.29 kg. Then it was recorded as 9.42 kg, 8.72 kg, 8 kg, and 2.27 kg on the 14th, 21st, 28th, and 90th days, respectively [Graph 1].

(a) The difference in mean bite force was -0.62 kg when comparison was done between group A with that of group B on the fractured side of molar over the control group preoperatively; postoperatively, it was 3.78 kg, 1.85 kg, 2.72 kg, 2.38 kg, and 4.21 kg on 7th, 14th, 21st, 28th, and 90th days, respectively [Graph 2].

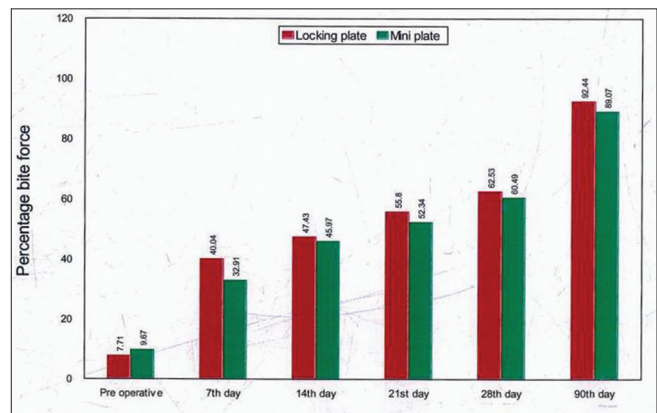
(b) The difference in mean bite force when comparison was done in group A with that of group B on the fractured side of incisors over the control group preoperatively was 0.76 kg; postoperatively on the 7th day, it was 4.43 kg. Then it was recorded as 4.32 kg, 3.79 kg, 3.38 kg, and 3.66 kg on 14th, 21st, 28th, and 90th days, respectively [Graph 3].

DISCUSSION

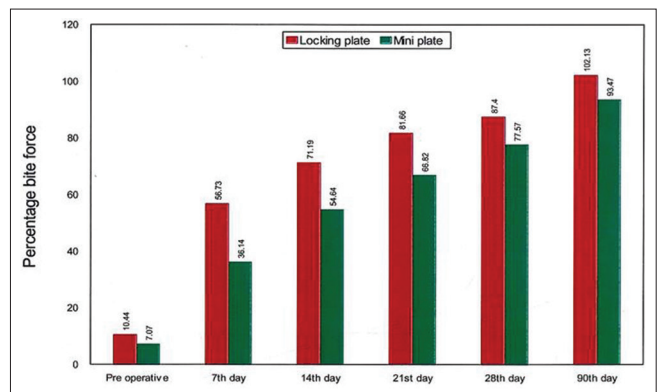
Rigid internal fixation (RIF) was considered an unacceptable mode of therapy until 1958 because of high rate of associated complications. During the ensuing 20 years, reconstructive surgeons witnessed tremendous improvement in the development of RIF, which has led to a more acceptable complication rate. More recently, authors have reported decreasing complication rates, especially related to operator's experience.^[6] The semi-rigid system with monocortical plates and screws is currently used universally for the fixation of bony fractures in the maxillofacial region.^[7] The miniplate system gives sufficient support and stability to bone fragments, allows precise anatomical reduction, and is easy to use.^[8] Proponents of the RIF believe that prevention of interfragmentary mobility is the key to success and should be the goal when treating fractures.^[7,9] A longstanding problem in miniplate osteosynthesis has been loosening of one or more screws and the plate must be adapted meticulously to the contours of the bone, as errors in fixation will result in permanent malocclusion.^[10] These problems have been overcome by development of a screw which locks not only to the bone but also to the bone plates.^[2] The past 10 years have witnessed the use of locking plate/screw systems in maxillofacial surgery.



Graph 1: Mean percent bite force over control group in fractured and contra lateral non fractured site at various post operative days



Graph 2: Mean percent bite force over control in group A and group B at various posts operative days in premolar and molar regions



Graph 3: Mean percent bite force over control in group A and group B at various posts operative days in incisor region

These plates function as internal fixators,^[3] and stability is achieved by locking the screw to the plate.^[2] The locking mechanism is such that the hole in the bone plate is engineered to accept screws that lock to it by the thread under the head of the screw,^[1,11] i.e. one thread will engage the bone and another will engage a threaded area of the bone plate,^[2] and this provides several potential advantages to such fixation devices. The main advantage of the locking plate over the conventional plate is that the locking plate

does not require precise adaptation of the plate to the underlying bone. As the screws are tightened, they “lock” to the plate, thus stabilizing the segments without the need to compress the plate to the bone. A second advantage of locking plate/screw system is that the screws are unlikely to loosen from the bone plate even if the screw is inserted into the fracture gap or a comminuted segment; hence, there is decreased incidence of inflammatory complications from loosening of the plate and screws.^[1] One more potential advantage in locking plate/screw system is that it does not disrupt the underlying cortical bone perfusion^[1,12] or the vascular supply of bone, and allows the periosteum to grow under the plates, supporting fracture healing.^[5] This avoids the cortical necrosis which is sometimes seen under the plate which is compressed against the bone.^[1,2]

Oguz *et al.*, evaluate the mechanical stresses over the bone and hardware after sagittal split ramusosteotomy (SSRO) fixed with standard titanium or locking plate/screws using finite element analysis. A 3-dimensional finite element model of the mandible was created, and SSRO and 5 mm advancement was simulated on a computer model. The model was fixed with either 2.0-mm titanium conventional miniplate/screw or 2.0-mm titanium locking miniplate/screw system, and oblique 200 N bite forces were applied. This study also concluded that locking miniplates system spreads the load over the plates and screws and diminishes the amount of force transferred to each unit.^[13] So, locking plates is efficacious enough to bear the masticatory loads during osteosynthesis of fracture and provides the advantage of a greater bite force.^[14]

Haug *et al.* did a biomechanical comparison between locking and non-locking plates to determine the degree of plate adaptation affecting the stability by using 130 polyurethane synthetic mandible replicas. In their study, they observed that the degree of plate adaptation affected the mechanical behavior of non-locking plates but did not affect the locking plates.^[12]

Gerlach and Schwarz evaluated the maximal biting forces in 22 patients with fractures of angle of mandible treated with miniplate osteosynthesis as per Champy’s tension banding principle. An electric test procedure for evaluating the load resistance between the incisors, canines, and molars was carried out 1–6 weeks following the treatment and also in 15 controls. They revealed that after 1 week of surgical treatment of fractures, only 31% of the maximal vertical loading found in controls was registered. These values increased to 58% at the 6th week postoperatively.^[15]

In our study, the operated sites of molars in patients treated with internal locking miniplates generated a bite force of

40% on day 7, 47% on day 14, 56% on day 21, 63% on day 28, and 92% on day 90, compared to the control group. Similarly, bite force generated postoperatively by patients treated with conventional miniplates on the operated sites of molars was 33% on day 7, 46% on day 14, 52% on day 21, 60% on day 28, and 89% on day 90, compared to the control group. When the operated sites of incisors were taken into consideration, patients in group A generated bite force of 57% on day 7, 71% on day 14, 82% on day 21, 87% on day 28, and 102% on day 9, compared to the control group. Similarly, bite force generated in the operated sites of incisors by patients treated with conventional miniplates was 36% on day 7, 55% on day 14, 67% on day 21, 78% on day 28, and 93% on day 90, in comparison to the control group.

This difference in bite force which was generated by patients in group A in comparison to group B patients over the control group is statistically inconclusive, because the size of sample was limited.

The results obtained from the study done by Tams *et al.* showed that one bone plate is sufficient for symphysis fractures, as well as in the treatment of mandibular body fractures.^[4] In our study, we found that fixation of fractures of parasymphysis and the body of mandible by a single locking plate provided sufficient stability when compared to two plates being used for fixation of the same type of fractures by conventional miniplates. We had achieved the same fixation objectives by using single locking plate against two miniplates used for fixation of same type of fracture. In our study, we did not notice fracture site mobility in any patient. This is in agreement with Kallela *et al.*^[16] where they found that the fracture site stability is dependent on the rigidity produced by the plate and screw system.

Collins *et al.* carried a prospective study comparing 2 mm locking plates and 2 mm conventional plates in mandibular fractures, in which surgical technique that was used to apply both the plating systems was the same.^[17] All fractures appeared to be well reduced and postoperative radiographs taken within the first 2 days showed excellent reduction.^[11] There were no intraoperative difficulties utilizing this locking plate/system.^[1,18] In our study, all fractures appeared to be well reduced and stable, and postoperative radiographs confirmed the adequacy of reduction; we did not encounter intraoperative difficulties in the form of screw being not locked with the plates. Ellis and Graham had mentioned that locking plates require precisely centered drill hole with the plate hole to ensure perpendicular placement of the screw. If screws are not placed perpendicular to the plate, the screw will not engage the threaded plate hole adequately and therefore will not lock; this is considered to be one of the disadvantages of locking plate/screw system.^[1,11]

In the study done by Tunovien *et al.* they found postoperative infection occurring in 3.6% of the patients treated with miniplates.^[19] This was seen in the first 6 weeks after plating. The infection may be treated conservatively by draining pus if present and packing with whitehead's varnish or impregnated gauze.^[20] Similarly, Ellis and Graham treated postoperative infection in the out-patient setting with incision and drainage, irrigation, and oral antibiotics.^[1,7,11] Locking head screws have a reduced tendency to loosen, which decreases the rate of postoperative infection and failure.^[1,11,20] In our study, 2 (20%) patients treated with locking plates/screw systems and 2 (20%) patients treated with conventional miniplates/screw system developed infection at the site of wound which was drained and got resolved on administration of antibiotics. The infection was due to local cause.

The results obtained from our study show that the mean difference of biting force in patients treated with internal locking miniplates/screw system and in patients treated with conventional miniplates/system over the control group was statistically insignificant. When comparisons was done regarding outcome of treatment and complications noticed between patients treated with internal locking miniplates/screw system and patients treated with conventional miniplates/system, statistically insignificant results were obtained.

CONCLUSION

It was observed in our study that patients treated with locking plate/screw system postoperatively generated more bite force compared to those treated with conventional miniplates/screw system. Hence, it provides adequate stability and reduces the amount of hardware with minimum chances of loosening of screws and cortical necrosis. Only the cost of hardware is increased by 8-10% when locking plate/screw system is used, compared to conventional miniplates/screw system.

REFERENCES

1. Herford AS, Ellis E 3rd. Use of a locking reconstruction bone plate/screw system for mandibular surgery. *J Oral Maxillofac Surg* 1998;56:1261-5.
2. Alpert B, Gutwald R, Schmelzeisen R. New innovations in craniomaxillofacial fixation: The 2.0 lock system. *Keio J Med* 2003;52:120-7.
3. Goyal M, Marya K, Chawla S, Pandey R. Mandibular osteosynthesis: A comparative evaluation of two different fixation systems using 2.0 mm titanium miniplates and 3-D locking plates. *J Maxillofac Oral Surg* 2011;10:316-20.
4. Tams J, van Loon JP, Otten E, Rozema FR, Bos RR. A three-dimensional study of bending and torsion moments for different fracture sites in the mandible: An *in vitro* study. *Int J Oral Maxillofac Surg* 1997;26:383-8.

5. Gutwald R, Alpert B, Schmelzeisen R. Principle and stability of locking plates. *Keio J Med* 2003;52:21-4.
6. Jaques B, Richter M, Arza A. Treatment of mandibular fractures with rigid osteosynthesis: Using the AO system. *J Oral Maxillofac Surg* 1997;55:1402-7.
7. Kim YK, Nam KW. Treatment of mandible fractures using low-profile titanium miniplates: Preliminary study. *Plast Reconstr Surg* 2001;108:38-43.
8. Kuriakose MA, Fardy M, Sirikumara M, Patton DW, Sugar AW. A comparative review of 266 mandibular fractures with internal fixation using rigid (AO/ASIF) plates or mini-plates. *Br J Oral Maxillofac Surg* 1996;34:315-21.
9. Potter J, Ellis E 3rd. Treatment of mandibular angle fractures with a malleable noncompression miniplate. *J Oral Maxillofac Surg* 1999;57:288-93.
10. Zachariades N, Papademetriou I. Complications of treatment of mandibular fractures with compression plates. *Oral Surg Oral Med Oral Pathol Oral Radiol Endod* 1995;79:150-3.
11. Ellis E 3rd, Graham J. Use of a 2.0-mm locking plate/screw system for mandibular fracture surgery. *J Oral Maxillofac Surg* 2002;60:642-6.
12. Haug RH, Street CC, Goltz M. Does plate adaptation affect stability? A biomechanical comparison of locking and non locking plates. *J Oral Maxillofac Surg* 2002;60:1319-26.
13. Oguz Y, Uckan S, Ozden AU, Uckan E, Eser A. Stability of locking and conventional 2.0-mm miniplate/screw systems after sagittal split ramus osteotomy: Finite element analysis. *Oral Surg Oral Med Oral Pathol Oral Radiol Endod* 2009;108:174-7.
14. Agarwal M, Mohammad S, Singh RK, Singh V. Prospective randomized clinical trial comparing bite force in 2-mm locking plates versus 2-mm standard plates in treatment of mandibular fractures. *J Oral Maxillofac Surg* 2011;69:1995-2000.
15. Gerlach KL, Schwarz A. Bite forces in patients after treatment of mandibular angle fractures with miniplate osteosynthesis according to Champy. *Int J Oral Maxillofac Surg* 2002;31:345-8.
16. Kallela I, Iizuka T, Salo A, Lindqvist C. Lag-screw fixation of anterior mandibular fractures using biodegradable polylactide screws: A preliminary report. *J Oral Maxillofac Surg* 1999;57:113-8.
17. Collins CP, Pirinjian-Leonard G, Tolas A, Alcalde R. A prospective randomized clinical trial comparing 2.0-mm locking plates to 2.0-mm standard plates in treatment of mandible fractures. *J Oral Maxillofac Surg* 2004;62:1392-5.
18. Militsakh ON, Wallace DI, Kriet JD, Girod DA, Olvera MS, Tsue TT. Use of 2.0-mm locking reconstruction plate system in oromandibular reconstruction after composite resection. *Otolaryngol Head Neck Surg* 2004;131:660-5.
19. Tuovinen V, Nørholt SE, Sindet-Pedersen S, Jensen J. A retrospective analysis of 279 patients with isolated mandibular fractures treated with titanium miniplates. *J Oral Maxillofac Surg* 1994;52:931-6.
20. Brown JS, Trotter M, Cliffe J, Ward-Booth RP, Williams ED. The fate of miniplates in facial trauma and orthognathic surgery: A retrospective study. *Br J Oral Maxillofac Surg* 1989;27:306-15.

How to cite this article: Kumar S, Gattumeedhi SR, Sankhla B, Garg A, Ingle E, Dagli N. Comparative evaluation of bite forces in patients after treatment of mandibular fractures with miniplate osteosynthesis and internal locking miniplate osteosynthesis. *J Int Soc Prevent Communit Dent* 2014;4:S26-31.

Source of Support: Nil, **Conflict of Interest:** None declared.