

# Case Series

## The isolated inferior glenohumeral labrum injury, anterior to posterior (the ILAP): A case series

Val Irion, Michael Cheah, Grant L. Jones, Julie Y. Bishop

### ABSTRACT

**Introduction:** We describe the presentation, exam findings, surgical repair techniques, and short-term outcomes in a series of patients with isolated inferior labral tears.

**Materials and Methods:** A retrospective chart review was performed at a large academic medical center. Isolated inferior labral tears were defined as between the 4 o'clock and 8 o'clock position of the glenoid as determined by direct arthroscopic visualization. Tears that were smaller were also included but were required to cross the 6 o'clock point, having anterior and posterior components. Patients were excluded if they had any other pathology or treatment of the shoulder. 1-year follow-up was required.

**Results:** Of the 17 patients who met inclusion criteria for review, 12 were available for a minimum 1-year follow-up. Average total follow-up for patients to complete the phone interview/Oxford Shoulder Instability Score (OSIS) was an average of 37.7 months (range: 16-79 months). Postoperatively, all reported symptom improvement or resolution since surgery. The mean preoperative pain on a scale of 0-10 was 6.3 (range: 0-10). Mean postoperative pain on a scale of 0-10 was 2.25 (range: 0-5). Eleven of 12 patients (91.7%) had returned to the level of activity desired. The mean OSIS was 41.4 (median: 43; range: 27-47). Eleven of 12 patients (91.7%) had good or excellent scores. Ten of 12 patients (83.3%) had a feeling of stability in the shoulder. All 12 patients reached were satisfied with the procedure and would undergo surgery again in a similar situation.

**Conclusions:** We have presented our series of patients with isolated inferior labral injury, and have shown that when surgically treated, outcomes of this uncommon injury are good to excellent and a full return to sports can be expected.

**Key words:** Arthroscopy, labral injury, labral tear, outcomes, shoulder

### INTRODUCTION

Injury to the labrum can create instability within the shoulder. Much work has been done to describe injuries, isolated and combined, to various aspects of the labrum. The Bankart lesion or antero-inferior labral injury is the most common labral injury observed. It was first described by Arthur Bankart, a British orthopedic surgeon, in 1938.<sup>[1]</sup> Recurrent anterior dislocation due to this lesion is common in patients <20 years old (up to 90%), creating chronic shoulder instability in this population.<sup>[2,3]</sup> This entity is

well-understood, and arthroscopic techniques have advanced to make corrective surgery very successful (up to 96% success rate).<sup>[2-7]</sup> In addition, the significance of injuries to the superior labrum, as first described by Andrews *et al.* in 1985,<sup>[8]</sup> and injuries to the posterior labrum have been increasingly studied and understood. Although these injuries are rare in isolation, comprising only 2-6% of arthroscopies, more reports have been devoted to these injuries.<sup>[8-19]</sup> Surgeons are learning of their importance both in isolation and more commonly, in combination as it relates to glenohumeral instability and surgical outcomes.

Access this article online

Website:

[www.internationalshoulderjournal.org](http://www.internationalshoulderjournal.org)

DOI:

10.4103/0973-6042.150218

Quick Response Code:



Department of Orthopaedics, OSU Sports Medicine, The Ohio State University Wexner Medical Center, Columbus, OH, USA

Address for correspondence:

Dr. Julie Y. Bishop,  
OSU Sports Medicine Center, The Ohio State University, 2050 Kenny Rd., Suite 3100, Columbus, OH 43221, USA.  
E-mail: [Julie.Bishop@osumc.edu](mailto:Julie.Bishop@osumc.edu)

Please cite this article as: Irion V, Cheah M, Jones GL, Bishop JY. The isolated inferior glenohumeral labrum injury, anterior to posterior (the ILAP): A case series. *Int J Shoulder Surg* 2015;9:13-9.

As the current understanding of glenoid labral pathology expands, the orthopedic community continues to define more specific types of injury to the labrum. Specific types of labral injuries in isolation will perhaps present different approaches to treatment and even more precise treatment algorithms.

We have recognized what is not a well-defined entity of labral injury, an isolated inferior labral tear. The inferior labrum would be defined as within 4 o'clock and 8 o'clock of a clock face along the glenoid surface. Therefore, not an extension of an already existing Bankart lesion or posterior labral tear, but truly a tear that is limited to the inferior quadrant of the glenoid. There is very little information in the literature regarding isolated inferior labral injury and the approach to diagnosis, mechanism of injury, management, and treatment. The small amount that does exist is more focused on associated paralabral cysts.<sup>[20]</sup>

We have experienced this injury in our practice and regard it as a unique entity with a paucity of published reports compared to other traditional glenoid labrum injuries. Thus, as minimal literature exists describing this type of isolated labral tear, evaluation of patients with this specific injury presents an opportunity to report on characteristics and presenting signs/symptoms that make it unique from other labral injuries.<sup>[21,22]</sup> The purpose of this report was to describe the presentation, exam findings, surgical repair techniques, and short-term outcomes in a series of patients with isolated inferior labral tears.

## MATERIALS AND METHODS

A retrospective chart review at a large academic medical center was performed on the patients of the two senior authors (JYB, GLJ). After appropriate IRB approval had been obtained, we began by searching CPT codes 29807 and 29806 to compile a list of patients from January 2006 to August 2012. We identified 592 potential patients with the above CPT codes. Charts, operative reports, and operative pictures were then reviewed to amass a list of all patients fitting the criteria of isolated inferior labral tears. For the purposes of this study, we defined isolated inferior labral tears between the 4 o'clock and 8 o'clock position of the glenoid as determined by direct arthroscopic visualization by the senior authors. In an effort to clearly distinguish this lesion from a Bankart tear that extended inferiorly or a primary posterior labral tear with anterior extension, these labral tears were centered over the 6 o'clock position. Tears that were smaller than this were also included but were still centered over the 6 o'clock position with equal anterior and posterior extension. Patients were excluded if they had any other pathology or treatment of the shoulder other than isolated inferior labral tear. A more detailed list of the inclusion and exclusion criteria is listed in Table 1. The final list of 17 patients was obtained and again verified via the operative pictures and operative reports.

After the final list of patients meeting the inclusion criteria was made, a chart review extracted the following data: Right

**Table 1: Inclusion and exclusion criteria**

Inclusion criteria	
Age 16-89 years	Intra-operative evidence of an isolated inferior labral tear as defined in paper (labral tear must be centered over the 6 o'clock position and extend both anterior and posteriorly in equal amounts and not pass the 8 or 4 o'clock positions, respectively)
Exclusion criteria	
<16 and >89 years of age	Intra-operative evidence of any other treated labral pathology during surgery
Associated SLAP repairs	Evidence of labral tear extending above the 8 or 4 o'clock positions
Associated biceps tenodesis	Intra-operative evidence of associated rotator cuff repairs
Concomitant pathology	Glenohumeral osteoarthritis
Associated fracture of the proximal humerus, clavicle, or scapula	Prior shoulder surgery

SLAP = Superior labral anterior posterior

versus left shoulder, chief complaint, age at surgery, occupation, mechanism of injury, level of pre- and post-operative pain, pre- and post-range of motion (ROM), number of pre- and post-operative subluxations/dislocations, result of pre- and post-operative apprehension test, result of inferior sulcus testing, number of anchors used, and pre- and post-operative participation in athletics. In addition, we attempted to contact all patients via telephone to conduct the Oxford Shoulder Instability Score (OSIS) questionnaire, along with a basic set of questions gauging overall satisfaction, results, stability, and return to activity postoperatively. The specific questions can be found in Appendix 1, along with the OSIS questionnaire. The telephone interview was conducted if patients were unable to come to our office for questioning and examination. The OSIS is a short, 12-item, condition-specific, patient-reported outcome measure developed and validated for measuring surgical and nonsurgical therapeutic outcomes of patients presenting with unidirectional or multidirectional instability of the shoulder sensitive to changes of clinical importance.<sup>[23]</sup> The survey, which is short, practical, reliable, and easy for patients to complete in person or over the phone, was first validated by Dawson *et al.* in 1999.<sup>[23]</sup> Patients receive a score based on their answers to the questions and receive a grade of poor, fair, good, or excellent based on what range their score falls. The score ranges are 0-19 poor, 20-29 fair, 30-39 good, and 40-48 excellent.

## Surgical technique

Patients were brought to the operating room and placed in the lateral decubitus (JYB) or beach chair position (GLJ) depending on the senior author. Interscalene block with general anesthesia was routinely utilized. After appropriate positioning, an exam under anesthesia was performed and in the case of patients in the lateral decubitus position, 10 pounds of traction was routinely utilized. Standard arthroscopy portals were then established. A diagnostic arthroscopy of the shoulder joint was performed to evaluate the location of the labral injury and any other associated

## Appendix 1: Telephone interview script

### Telephone script

The script for the telephone interview will be as follows:

*"Hello (patient name), my name is (physician name) from The Ohio State University Wexner Medical Center, department of Orthopaedics. Our records indicate that you had Shoulder Surgery for shoulder instability performed by one of our physician here at The Ohio State University Wexner Medical Center, is this correct? (if yes, continue; if no, thank the patient for their time) We are conducting a study on the procedure you had done and we would like to ask you a few quick questions. It will take approximately five to ten minutes.*

*Would you like to know more about the study? (if yes, continue; if no, thank the patient for their time).*

*"This study was designed to look at patients that had Shoulder Surgery to see what variables might affect your outcome/recovery from surgery.*

*"There are no direct benefits to you for participating in this study. Agreeing to answer our survey is completely voluntary."*

*"This is a minimal risk study, which means participants are not expected to experience harms or discomforts greater than those ordinarily encountered during daily life. There is risk of loss of confidentiality. There is a risk of someone else outside of the research study finding out about your participation and/or your results. To minimize this risk, your identity and all your data will be maintained with the principal investigator from The Ohio State University. No other individuals beyond the study personnel will have access to your questionnaire results. Information provided is used for research purposes only. All patient data will be stripped of direct identifiers prior to any analysis and individual patient results will not be made public."*

*You may choose not to participate in this study without any negative feelings from any of the doctors here at OSU. Choosing not to participate will not affect any treatment they might receive in the future at OSU.*

*If you have any questions, please contact Beth Sheridan at 614-293-9013.*

*Do you need some additional time to decide if you would like to participate in our study?"*

*If no, continue with the questionnaire.*

*If yes, set up a time when the patient would like you to call back.*

*"What would be a good day and time for me to contact you again? If it is easier for you we can mail you the questionnaires to complete at home. Would you like us to do that? "*

*If no, read "thank you so much for your time (patient name). I will call you back on (name day and time patient said would work) to answer any questions you have."*

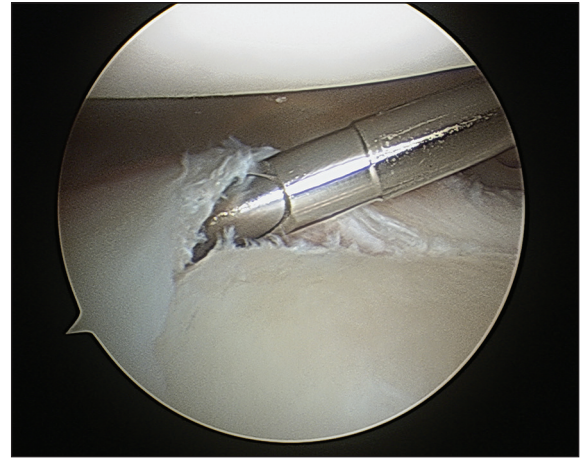
*"Would you like to participate in this study?"*

*If no, read "thank you so much for your time (patient name). Have a great day."*

*If yes, continue below:*

- 1. Have your symptoms resolved/improved since the operation?*
- 2. Rate your pain on a scale of 1-10 pre-op and now currently.*
- 3. Have you returned to the level of activities that you desire?*
- 4. If no, what is hindering you?*
- 5. Are you able to easily perform ADL's*
- 6. Have you returned to athletic activities?*

pathology. Once the labral pathology was identified [Figure 1], a second low anterior portal was created with an 8.25 mm cannula to help complete the anterior portion of the repair. The glenoid and labrum were then debrided from anterior to posterior [Figure 1], creating a lightly bleeding surface along the entire

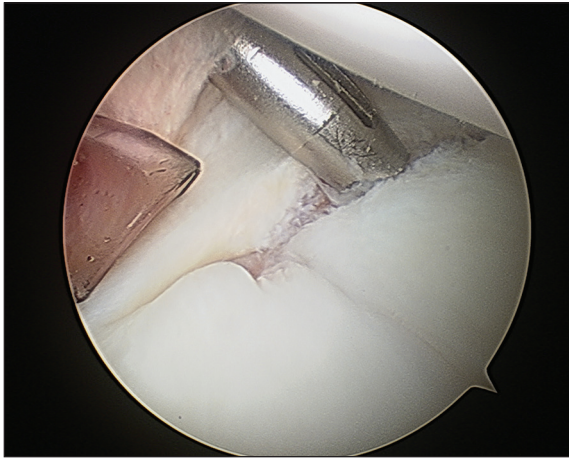


**Figure 1:** View from anterior-superior portal identifying inferior labral tear and preparation of the glenoid surface at the 6 o'clock position

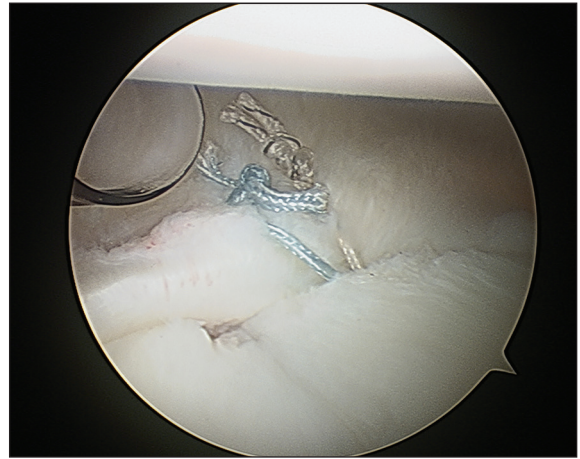
labral avulsion, including the 6 o'clock position as viewed from posterior. Next, the camera was placed anterior to view posterior. A 5.0 mm cannula was placed in the viewing portal posteriorly to complete the debridement of the glenoid and labrum.

Next, attention was turned to placement of the anchors. As placement of an anchor at the 6 o'clock position is both a technical challenge and dangerous secondary to the proximity of the axillary nerve, our technique calls for placement of anterior and posterior anchors as low as possible in order to adequately stabilize the inferior labrum anteriorly and posteriorly so that it may heal at this low position. The anchors utilized were the Arthrex (Naples, FL, USA) 3.0 mm Bio-SutureTak®. The mean number of anchors used was 3.75, and the anchors were either single or double loaded. As the standard posterior portal creates difficulty in getting low enough on the glenoid, we used a percutaneous technique at a 5 or 7 o'clock position, localizing with an 18-gauge spinal needle first, to place posterior anchors. The placement of the anchors and use of the percutaneous posterior technique is demonstrated in Figure 2. The suture lasso (Arthrex, Naples, FL, USA) is used percutaneously to pass the sutures around the labrum. The sutures were shuttled through our cannula in the standard posterior portal and then tied sequentially in order to close the posterior aspect of the labral tear as seen in Figure 3. The arthroscope is placed in the posterior portal to visualize and work anteriorly. The anchors were then placed at the 6:30 and 5 o'clock positions, (anteriorly and posteriorly, respectively, as viewed on the left shoulder) remaining cognizant of the location of the axillary nerve. Subsequent anchors were then placed at the 4 and 8 o'clock positions if necessary. The sutures are then shuttled and tied through the cannulas in the standard fashion anteriorly [Figure 4]. The final labral repair after all sutures have been tied is shown in Figures 5 and 6. Postoperatively, the patient was placed in an UltraSling (DJO, Vista, CA, USA) for immobilization.

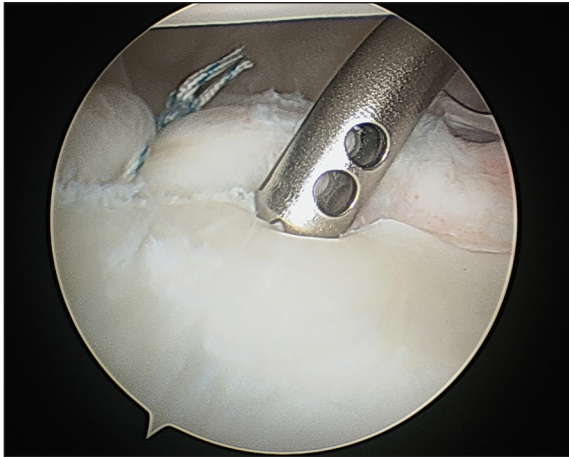




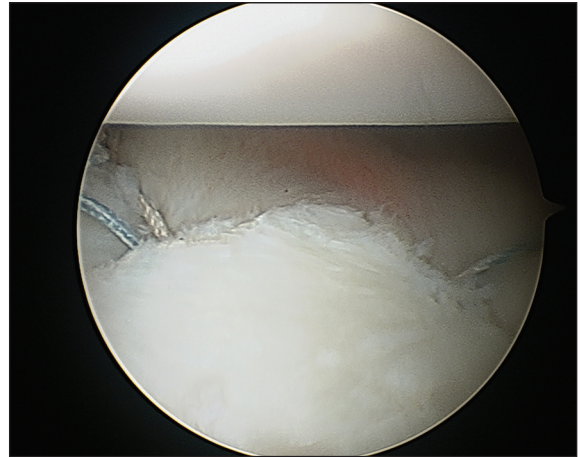
**Figure 2:** The trocar for the anchor is seen here utilizing the percutaneous technique for placement of the double loaded posterior anchor in the 5 o'clock position for this left shoulder



**Figure 3:** The double-loaded posterior anchor is tied to close down the posterior aspect of the tear



**Figure 4:** After placement of the low 6:30 anchor anteriorly in this left shoulder, a second anchor is seen being placed at the 8 o'clock position for added stability



**Figure 5:** Final construct showing the inferior aspect of the tear (6 o'clock position) anchored nicely to the glenoid by the 5 o'clock and 6:30 anchors in this left shoulder

### Postoperative care

In the immediate postoperative period, patients were encouraged to use ice for comfort, and they were also given standard narcotic pain medication for pain control. An abduction sling was used for 6 weeks, and formal physical therapy began within 2 weeks for all patients. The protocol consisted of a mixture of the anterior and posterior labral repair protocols.

Precautions included avoiding positions of horizontal adduction and internal rotation for the first 10-12 weeks to protect the posterior capsule and labrum. Passive ROM only was allowed for the first 6 weeks with a gradual progression in forward elevation and external rotation was limited to 30° for those 6 weeks to protect the anterior structures. The 6 weeks mark added active ROM to tolerance without upper trapezius substitution, and isotonic strengthening was begun at 8 weeks.

A gradual progressive strengthening program was started at the 12 weeks mark with closed chain weight bearing exercises on

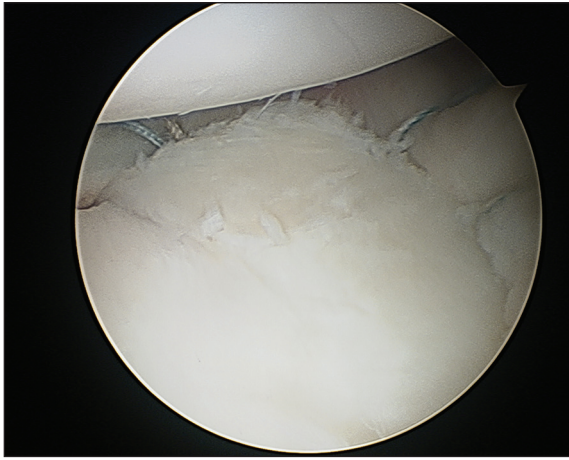
the wall, initiation of a thrower's program, and progression of endurance and neuromuscular exercises. At the 16-18 weeks mark, progression to sport-specific drills and a gradual return to sport were instituted if applicable/appropriate. Goals to return to sport included neuromuscular control, muscular strength no <80% of the contralateral side, full functional ROM, and full scapular, and rotator cuff strength. Return to contact sports required physician clearance no sooner than the 6 months mark.

### RESULTS

Seventeen patients met the criteria established for isolated inferior labral tear in this retrospective study. Arthroscopic pictures as referenced above are seen in Figures 1-7. They illustrate the typical appearance in this injury.

#### Pre-operative data (all 17 patients)

A magnetic resonance imaging (MRI) was obtained for all 17 patients. The findings were mixed, as a clearly demarcated



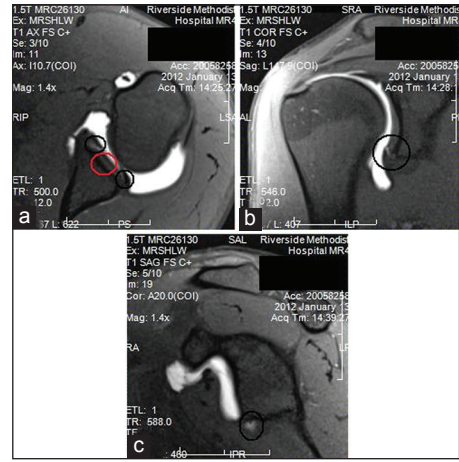
**Figure 6:** Another view demonstrating a broader view of the final construct

inferior labral tear was only seen radiographically in two patients. Six of our patients had evidence of an inferior paralabral cyst(s). More commonly, radiology interpretations of the imaging included a combination of anterior and inferior tears without specific appearance of posterior extension. In addition, six patients were thought to have superior labral anterior posterior (SLAP) tears based on imaging. However, none of these patients proved to have a superior labral tear arthroscopically. Representative MRI images are shown from a patient in Figure 7 illustrating the appearance of an inferior labral tear with inferior paralabral cysts radiographically.

All patients were male, with a mean age of 23.8 years (range: 16-42 years). There were 12 right and five left shoulders. Ten patients had a chief complaint of pain, three complained of recurrent instability and four complained of both pain and instability. The mechanism of injury varied greatly, as a frank dislocation event was not the primary mechanism causing the injury for the majority of patients. Only four patients had a documented dislocation. The mean number of dislocations in those four patients was 2.25 (range: 1-4). Other mechanisms included injuries during contact sports without true dislocation such as rugby, football, and wrestling. Additional mechanisms included a diving accident, motorcycle accident, labor-intensive injuries during heavy lifting, yard work, and three unknown mechanisms. Participation in sports both recreationally and competitively was very common. Twelve of the patients were actively competing in some type of athletics at the time of injury, including football, wrestling, cheerleading, rugby, baseball, volleyball, and golf. Most were high school or college students,<sup>[24]</sup> while other occupations included construction worker (one), salesman (one), state trooper (one), high school coaches (two), and unemployed (one). The pre-operative physical examination findings are outlined in Table 2.

**Postoperative data (12 patients reached for at least 1-year follow-up)**

Of the 17 patients forming the final list, 12 were available for either 1-year follow-up or to fill out a questionnaire via



**Figure 7:** Selective magnetic resonance imaging demonstrating an inferior labral tear and inferior paralabral cyst, which has been seen in inferior labral tear. An axial image (a) shows an inferior labral tear (red circle) with clear extension anteriorly and posteriorly (black circles). A coronal view (b) demonstrating inferior labral tear (circle). A sagittal view (c) demonstrating an inferior paralabral cyst (circle)

telephone interview. Five patients were unavailable for either 1-year follow-up or telephone interview despite repeated attempts to contact them from provided institutional record. The average clinical follow-up in the office for the 12 patients was 5.75 months (range: 1.25-11 months) with total follow-up via telephone interview/questionnaire being a mean 37.7 months (range: 16-79 months). Postoperative physical exam findings in those patients are outlined in Table 3. All 12 patients reported that they were satisfied with the procedure. All 12 reported symptom improvement or resolution since the surgery. Ten of 12 patients (83.3%) reported an overall feeling that the shoulder was stable. Self-reported patient satisfaction was 100%. Eleven of 12 patients (91.7%) had returned to the level of activity desired. Eleven of 12 patients (91.7%) had returned to athletic activities. Patients did note diminished strength, weakness, or fatigue as a reason to not be able to compete at the same level at times in athletics. The mean OSIS was 41.4 (median: 43; range: 27-47). There were eight excellent scores, three good scores, one fair score, and zero poor scores in the 12 patients. Eleven of 12 (91.7%) of patients had good or excellent results as measured by the OSIS.

**DISCUSSION**

Lesions of the glenoid labrum can create shoulder instability. There have been many reports of the treatment of anterior instability<sup>[1-7,12,14,15,21,24-26]</sup> and more recently superior labral (SLAP) tears and posterior instability.<sup>[8,10,11,13,15-18,27]</sup> There have even been reports describing treatment of combinations of the above injuries.<sup>[28,29]</sup> There has been very little devoted to the literature in regards to treatment and surgical technique for isolated inferior labral injury. We found two retrospective studies from Korea detailing a total of six patients with an inferior labral tear associated with an inferior paralabral cyst.<sup>[20,30]</sup> Both of these studies focus on detailing the MRI appearance and treatment



**Table 2: Preoperative evaluation**

Preoperative ROM	
ER	72° (range: 40-90)
FE	171° (range: 160-180)
Preoperative apprehension	
Yes	71% (12/17 patients)
No	29% (5/17)
Preoperative sulcus	
Yes	47% (8/17 patients)
No	53% (9/17 patients)
Preoperative VAS pain scores	
6.3 (range: 0-10)	

ROM = Range of motion; ER = External rotation; FE = Forward elevation; VAS = Visual analogue scale

**Table 3: Postoperative evaluation**

Postoperative ROM	
ER	74° (range: 50-90)
FE	173° (range: 150-180)
Postoperative apprehension	
Yes	8% (1/12 patients)
No	92% (11/12)
Postoperative VAS pain scores	
2.25 (range: 0-5)	

ROM = Range of motion; ER = External rotation; FE = Forward elevation; VAS = Visual analo scale

of the paralabral cyst. Our study reports on a larger series of patients and focuses not only on MRI appearance and treatment but also the presentation, mechanisms of injury and outcome measures. To our knowledge, there have been no other studies dedicated to looking at isolated inferior labral tear mechanisms, chief complaint, surgical technique, and outcomes.

The isolated inferior labral tear is a rare entity in regard to labral injury evidenced by the lack of reported literature, thus, the authors were careful to assure, via operative report review and evaluation of intra-operative pictures, that these lesions were truly inferior labral tears, centered over the 6 o'clock position, and not just an isolated low anterior Bankart or low posterior Bankart. The challenges in the diagnosis of an isolated inferior labral tear include the varied differences in presentation, causes, and MRI. A common mechanism of injury in our patients was not seen, and patient presentation varied widely as well, as pain, not instability, was found to be the chief complaint in a majority of our patients. Furthermore, unlike with anterior or posterior labral injury, where dislocation is usually the inciting event,<sup>[22]</sup> it was not the main cause of injury to the inferior labrum. Only 23.5% (4/17) of patients had a true dislocation as a precursor to their injury. Moon *et al.* postulated that repetitive microtrauma and not frank dislocation was the main cause of inferior labral tear in a recent case report.<sup>[30]</sup> Similarly, Ji *et al.* theorized that unrecognized trauma or multiple minor events could be the cause of inferior labral injury.<sup>[20]</sup> We agree with these theories and believe that for some patients, repetitive microtrauma led to this inferior lesion, as again, only four patients noted a frank dislocation event. In addition, as this area is hard to visualize

radiographically, MRI appearance is not as obvious in this entity compared to other locations of labral injury, as we saw only 2 out of 17 patients had an obvious inferior labral tear. The different MRI interpretations we saw in our population illustrate that the radiographic appearance is not always clear even on advanced imaging. One clue on the MRI that can point to an inferior labral tear is an inferior paralabral cyst. This uncommon appearance on MRI was reported by Ji *et al.* in five patients.<sup>[20]</sup> Labral cysts are very uncommonly found in this position and hence, its appearance on MRI can key one into the diagnosis of inferior labral tear, as we also saw this in 35% of our patient population.<sup>[20,30]</sup>

Because a consistent mechanism, presentation, or MRI appearances were not found, this injury was ultimately detected and confirmed at the time of surgery. We believe our series supports the notion that when patients present with these somewhat unclear findings, a high index of suspicion should be utilized. Therefore, the surgeon can be prepared for a more challenging surgery if this entity is encountered. This injury creates not only diagnostic challenges but surgical difficulties. As the inferior labrum is involved, it is nearly impossible to create an appropriate angle to place inferior (6 o'clock) anchors without placing vital neurovascular structures such as the axillary nerve in unacceptable danger. With the inability to place direct inferior anchors, it is often impossible to place anchors close enough together at each "mark on the clock face" as recommended in traditional labral repairs.<sup>[31,32]</sup> To address this difficulty, we have utilized the technique of placing anchors at the 6:30 and 5 o'clock positions anteriorly and posteriorly, respectively, for the left shoulder. This would then essentially tether the labrum on both sides, preventing any motion of the labrum so that it could heal to the well-prepared bone bed despite not having a 6 o'clock anchor. It is important to note that even though this area is difficult to visualize, we are not able to know definitively if the labrum actually healed without MR arthrogram, which was not realistic to order postoperatively in our patient cohort. However, as all 12 patients were satisfied with the procedure, had improvement or resolution of their symptoms, were happy with the results, and would have the surgery again if needed, we are confident that our technique created an environment for labral healing.

We acknowledge limitations to this study, most notably the small number of patients, and lack of long-term clinical follow-up. However, we do believe that this is a real entity deserving attention in the literature so that it can be entertained as a diagnosis upon presentation and if encountered intra-operatively, surgeons are better prepared, with more techniques to undertake the repair. Our review of records identified the injury in 17 of 592 (2.9%) potential patients who underwent surgical intervention for labral injury. Despite losing five patients to follow-up, we felt it was important to include all pre-operative data as to understand better how this injury presents, which still remains variable. Although our clinical follow-up was 5.75 months, our total follow-up for the Oxford

questionnaire was at a mean of 37.7 months. The authors believe the only thing lost with clinical follow-up was the ability to measure final ROM, which did not seem to be affected in the limited follow-up that was obtained. Therefore, we believed it is important to report our results because our ability to obtain solid follow-up with the telephone interview and Oxford scores gathered useful information on shoulder stability, return to sports/activities, and overall satisfaction. In our opinion, it is these outcomes that reveal the most about the surgery and its chances for success.

## CONCLUSION

We have presented our series of patients with isolated inferior labral injury and have shown that this is a difficult entity to diagnose. Often, final diagnosis is confirmed at the time of arthroscopy. However, when recognized and surgically treated appropriately, outcomes of this uncommon injury are good to excellent, and a full return to sports can be expected.

## REFERENCES

- Bankhart AS. The pathology and treatment of recurrent dislocation of the shoulder joint. *Br J Surg* 1938;26:23-9.
- Cole BJ, Warner JJ. Arthroscopic versus open Bankart repair for traumatic anterior shoulder instability. *Clin Sports Med* 2000;19:19-48.
- Mazzocca AD, Brown FM Jr, Carreira DS, Hayden J, Romeo AA. Arthroscopic anterior shoulder stabilization of collision and contact athletes. *Am J Sports Med* 2005;33:52-60.
- Archetti Netto N, Tamaoki MJ, Lenza M, dos Santos JB, Matsumoto MH, Faloppa F, et al. Treatment of Bankart lesions in traumatic anterior instability of the shoulder: A randomized controlled trial comparing arthroscopy and open techniques. *Arthroscopy* 2012;28:900-8.
- Burkhart SS, De Beer JF. Traumatic glenohumeral bone defects and their relationship to failure of arthroscopic Bankart repairs: Significance of the inverted-pear glenoid and the humeral engaging Hill-Sachs lesion. *Arthroscopy* 2000;16:677-94.
- Harris JD, Gupta AK, Mall NA, Abrams GD, McCormick FM, Cole BJ, et al. Long-term outcomes after Bankart shoulder stabilization. *Arthroscopy* 2013;29:920-33.
- Petrera M, Dwyer T, Tsuji MR, Theodoropoulos JS. Outcomes of arthroscopic Bankart repair in collision versus noncollision athletes. *Orthopedics* 2013;36:e621-6.
- Andrews JR, Carson WG Jr, McLeod WD. Glenoid labrum tears related to the long head of the biceps. *Am J Sports Med* 1985;13:337-41.
- Bisson LJ. Thermal capsulorrhaphy for isolated posterior instability of the glenohumeral joint without labral detachment. *Am J Sports Med* 2005;33:1898-904.
- Bradley JP, Forsythe B, Mascarenhas R. Arthroscopic management of posterior shoulder instability: Diagnosis, indications, and technique. *Clin Sports Med* 2008;27:649-70.
- Bradley JP, Tejwani SG. Arthroscopic management of posterior instability. *Orthop Clin North Am* 2010;41:339-56.
- Burkhart SS. Arthroscopic treatment of anterior shoulder instability. *Oper Tech Orthop* 2001;11:17-23.
- Burkhart SS, Morgan C. SLAP lesions in the overhead athlete. *Orthop Clin North Am* 2001;32:431-41, viii.
- Gartsman GM, Roddey TS, Hammerman SM. Arthroscopic treatment of anterior-inferior glenohumeral instability. Two to five-year follow-up. *J Bone Joint Surg Am* 2000;82-A:991-1003.
- Hantes ME, Venouziou AI, Liantis AK, Dailiana ZH, Malizos KN. Arthroscopic repair for chronic anterior shoulder instability: A comparative study between patients with Bankart lesions and patients with combined Bankart and superior labral anterior posterior lesions. *Am J Sports Med* 2009;37:1093-8.
- Provencher MT, Mologne TS, Romeo AA, Bradley JP. The use of rotator interval closure in the arthroscopic treatment of posterior shoulder instability. *Arthroscopy* 2009;25:109-10.
- Snyder SJ, Banas MP, Karzel RP. An analysis of 140 injuries to the superior glenoid labrum. *J Shoulder Elbow Surg* 1995;4:243-8.
- Snyder SJ, Karzel RP, Del Pizzo W, Ferkel RD, Friedman MJ. SLAP lesions of the shoulder. *Arthroscopy* 1990;6:274-9.
- Zhang AL, Kreulen C, Ngo SS, Hame SL, Wang JC, Gamradt SC. Demographic trends in arthroscopic SLAP repair in the United States. *Am J Sports Med* 2012;40:1144-7.
- Ji JH, Shafi M, Lee YS, Kim DJ. Inferior paralabral ganglion cyst of the shoulder with labral tear — A rare cause of shoulder pain. *Orthop Traumatol Surg Res* 2012;98:193-8.
- Guanche CA, Quick DC, Sodergren KM, Buss DD. Arthroscopic versus open reconstruction of the shoulder in patients with isolated Bankart lesions. *Am J Sports Med* 1996;24:144-8.
- Hintermann B, Gächter A. Arthroscopic findings after shoulder dislocation. *Am J Sports Med* 1995;23:545-51.
- Dawson J, Fitzpatrick R, Carr A. The assessment of shoulder instability. The development and validation of a questionnaire. *J Bone Joint Surg Br* 1999;81:420-6.
- Castagna A, Markopoulos N, Conti M, Delle Rose G, Papadaku E, Garofalo R. Arthroscopic bankart suture-anchor repair: Radiological and clinical outcome at minimum 10 years of follow-up. *Am J Sports Med* 2010;38:2012-6.
- Fabre T, Abi-Chahla ML, Billaud A, Geneste M, Durandeau A. Long-term results with Bankart procedure: A 26-year follow-up study of 50 cases. *J Shoulder Elbow Surg* 2010;19:318-23.
- Zaffagnini S, Marcheggiani Muccioli GM, Giordano G, Bonanzinga T, Grassi A, Nitri M, et al. Long-term outcomes after repair of recurrent post-traumatic anterior shoulder instability: Comparison of arthroscopic transglenoid suture and open Bankart reconstruction. *Knee Surg Sports Traumatol Arthrosc* 2012;20:816-21.
- Maffei MW, Lowe WR. Superior labral injuries. In: Miller MD, Thompson SR, editors. *DeLee & Drez's Orthopaedic Sports Medicine*. 3<sup>rd</sup> ed. New York: Saunders; 2009. p. 1016-32.
- Lo IK, Burkhart SS. Triple labral lesions: Pathology and surgical repair technique-report of seven cases. *Arthroscopy* 2005;21:186-93.
- Warner JJ, Kann S, Marks P. Arthroscopic repair of combined Bankart and superior labral detachment anterior and posterior lesions: Technique and preliminary results. *Arthroscopy* 1994;10:383-91.
- Moon CY, Ji JH, Kim SJ. Multidirectional instability accompanying an inferior labral cyst. *Clin Orthop Surg* 2010;2:121-4.
- Arciero RA, Mazzocca AD, Spang JT. Arthroscopic treatment of anterior shoulder instability. In: Wiesel SW, editor. *Operative Techniques in Orthopaedic Surgery*. Philadelphia: Lippincott Williams & Wilkins; 2010. p. 14-23.
- Cole BJ, Romeo AA. Arthroscopic shoulder stabilization with suture anchors: Technique, technology, and pitfalls. *Clin Orthop Relat Res* 2001;17-30.

Source of Support: Nil, Conflict of Interest: None declared.