

Left Thigh Pain and Rind Sign

Sir,

The Rind sign is radiological feature used when a lesion is surrounded by a thick layer of sclerotic reactive bone and is suggestive of fibrous dysplasia (FD). The Rind sign is most commonly seen in the proximal femur.

A 28-year-old male presented with dull aching left thigh pain worsening with activity and reduced by rest of 2-year duration. There was no history of preceding trauma, joint pain, muscle weakness, or evidence of hormonal hypersecretion. His past history was unremarkable and on examination, there was no cutaneous lesion or deformities. There was mild tenderness in deep palpation of left upper thigh with no myopathy. His bone mineral profile including bone turnover markers was within normal limits. The plain radiograph [Figure 1] showed a well-defined expansile lytic lesion with thick sclerotic margin (Rind sign) in the left femoral neck and in the inter trochanteric region, with narrow zone of transition, with ground glass matrix, no cortical break, no periosteal reaction, no soft tissue involvement which was indicative fibrous dysplasia. In the MRI [Figure 2], the lesion appeared hypointense on T1 and measured $5 \times 2.5 \times 2$ cm. Technetium-99m methylene diphosphonate (MDP) scan [Figure 3] showed an increased tracer activity in the left proximal femur. He was advised treatment with bisphosphonates as he had pain of moderate severity.

FD is a sporadic disorder characterized by replacement of normal bone with poorly organized fibrous tissue and increased bone resorption.^[1] Monostotic FD is the most common form of FD where rib, skull, and femur are usually involved. In the polyostotic form, skull, mandible, pelvis, and femur are the most frequently affected. Most of the monostotic FD lesions are discovered incidentally, while polyostotic form usually presents in childhood and is associated with syndrome like McCune-Albright syndrome (MAS). Patients with

polyostotic FD present with pain, deformities, or pathological fractures.^[2,3]

Computerized Tomography (CT) is useful for assessing complex skeletal anatomy like face, pelvis and spine. MRI allows differentiation of FD from a cystic lesion and bone scintigraphy demonstrates the extent of disease. Differential diagnoses include nonossifying fibroma, aneurysmal bone cyst, adamantinoma, giant cell tumor, and low-grade central osteosarcoma. Bisphosphonates are used to manage FD in patients with significant pain.^[2]

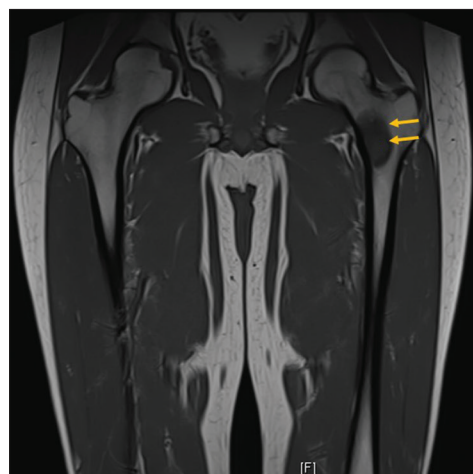


Figure 2: MRI of pelvis

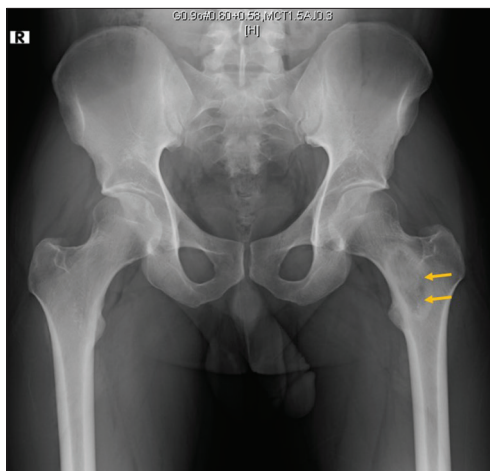


Figure 1: Plain radiograph of pelvis

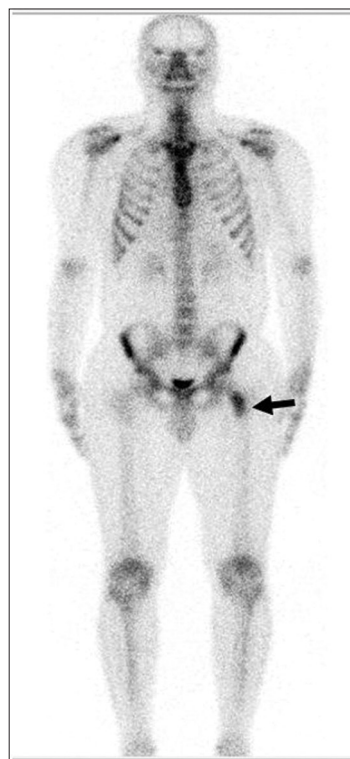


Figure 3: Bone scintigraphy

Declaration of patient consent

The authors certify that they have obtained all appropriate patient consent forms. In the form the patient(s) has/have given his/her/their consent for his/her/their images and other clinical information to be reported in the journal. The patients understand that their names and initials will not be published and due efforts will be made to conceal their identity, but anonymity cannot be guaranteed.

Financial support and sponsorship

Nil.

Conflicts of interest

There are no conflicts of interest.

Sindhu Sree Rallapalli, Kripa Elizabeth Cherian, Nitin Kapoor, Thomas V. Paul

Department of Endocrinology, Christian Medical College and Hospital, Vellore, Tamil Nadu, India

Address for correspondence: Prof. Thomas V. Paul,
Department of Endocrinology, Christian Medical College,
Vellore, Tamil Nadu, India.
E-mail: thomasvpaul@yahoo.com

REFERENCES

1. Kushchayeva YS, Kushchayev SV, Glushko TY, Tella SH, Teytelboym OM, Collins MT, *et al.* Fibrous dysplasia for radiologists: Beyond ground glass bone matrix. *Insights Imaging* 2018;9:1035-56.

2. Javaid MK, Boyce A, Appelman-Dijkstra N, Ong J, Defabianis P, Offiah A, *et al.* Best practice management guidelines for fibrous dysplasia/McCune-Albright syndrome: a consensus statement from the FD/MAS international consortium. *Orphanet J Rare Dis.* 2019;14:139.
3. Fitzpatrick KA, Taljanovic MS, Speer DP, Graham AR, Jacobson JA, Barnes GR, *et al.* Imaging findings of fibrous dysplasia with histopathologic and intraoperative correlation. *AJR Am J Roentgenol* 2004;182:1389-98.


Submitted: 31-May-2022

Revised: 21-Jul-2022

Accepted: 21-Jul-2022

Published: 20-Sep-2022

This is an open access journal, and articles are distributed under the terms of the Creative Commons Attribution-NonCommercial-ShareAlike 4.0 License, which allows others to remix, tweak, and build upon the work non-commercially, as long as appropriate credit is given and the new creations are licensed under the identical terms.

Access this article online	
Quick Response Code: 	Website: www.ijem.in
	DOI: 10.4103/ijem.ijem_218_22

How to cite this article: Rallapalli SS, Cherian KE, Kapoor N, Paul TV. Left thigh pain and rind sign. *Indian J Endocr Metab* 2022;26:392-3.

© 2022 Indian Journal of Endocrinology and Metabolism | Published by Wolters Kluwer - Medknow