

# Low incidence of vascular uptake during ganglion impar sympathetic nerve blocks for coccydynia

Patrick M Foye<sup>1,2</sup>, Woon T K Jason<sup>3</sup>, Kevin Y Zheng<sup>2</sup>, Kenneth K Leong<sup>2</sup>

<sup>1</sup>Coccyx Pain Center, <sup>2</sup>Department of Physical Medicine and Rehabilitation, Rutgers New Jersey Medical School, Newark, New Jersey, United States, <sup>3</sup>School of Medicine, The University of Auckland, Auckland, New Zealand

**Correspondence:** Dr. Patrick M Foye, Coccyx Pain Center, Department of Physical Medicine and Rehabilitation, Rutgers New Jersey Medical School, Newark, New Jersey, United States. E-mail: Doctor.Foye@gmail.com

## Abstract

**Context:** Focal sympathetic nerve blocks of the ganglion impar are often effective treatments for coccydynia (coccyx pain) and other pelvic pain syndromes. These injections are generally performed under contrast-enhanced fluoroscopic guidance. Vascular uptake may potentially occur during the injection and vascular uptake rates have been reported for other spinal injections, but never for ganglion impar blocks. **Aims:** The purpose of the study was to determine vascular uptake rates during fluoroscopy-guided ganglion impar blocks. **Settings and Design:** An academic/University-based Coccyx Pain Center. **Methods and Materials:** A total of 78 consecutive trans-coccygeal ganglion impar blocks were analyzed for vascular uptake of contrast as determined by intermittent fluoroscopy. **Statistical Analysis Used:** Direct calculation of incidence. **Results:** Only one patient (1.3%) demonstrated a vascular uptake pattern, which was readily recognized and corrected by slightly adjusting the position of the needle tip and thereby subsequently obtaining the desired contrast pattern at the ganglion impar. **Conclusions:** Vascular uptake incidence is low during ganglion impar blocks. This information can be one of the multiple factors considered when a physician is deciding whether or not to use contrast in an individual patient.

**Key words:** Coccydynia; coccyx pain; ganglion impar; sympathetic nerve block; vascular uptake

## Introduction

Focal sympathetic nerve blocks of the ganglion impar are often effective treatments for coccydynia (coccyx pain)<sup>[1]</sup> and other pelvic pain syndromes. The ganglion impar is a solitary sympathetic nerve ganglion located anterior to the upper coccyx or sacrococcygeal joint (in the pre-sacrococcygeal, retrorectal space).<sup>[2]</sup> Ganglion impar blocks appear to relieve pain by decreasing sympathetically-maintained pain. These injections are generally performed under fluoroscopic guidance with contrast-enhancement.

Vascular uptake during pain management injections is when the injectate enters the bloodstream rather than staying locally at the site of injection. This has implications for potentially decreasing the effectiveness of the injection locally, as well as potentially increasing complications systemically. For example, the adverse effects of intravascular lidocaine include blood pressure changes and headaches.<sup>[3]</sup>

This is an open access journal, and articles are distributed under the terms of the Creative Commons Attribution-NonCommercial-ShareAlike 4.0 License, which allows others to remix, tweak, and build upon the work non-commercially, as long as appropriate credit is given and the new creations are licensed under the identical terms.

**For reprints contact:** WKHLRPMedknow\_reprints@wolterskluwer.com

**Cite this article as:** Foye PM, Jason WT, Zheng KY, Leong KK. Low incidence of vascular uptake during ganglion impar sympathetic nerve blocks for coccydynia. *Indian J Radiol Imaging* 2020;30:181-3.

**Received:** 11-Jun-2019

**Revised:** 23-Dec-2019

**Accepted:** 20-Feb-2020

**Published:** 13-Jul-2020

### Access this article online

#### Quick Response Code:



**Website:**  
www.ijri.org

**DOI:**  
10.4103/ijri.IJRI\_302\_19

Multiple prior publications regarding contrast injection prior to medication injection demonstrated rates of vascular uptake of contrast at various injection sites. Examples include vascular uptake rates of 20% for caudal epidural steroid injections<sup>[4]</sup> and 17%, 6%, 8%, and 21%, for sacral, lumbar, thoracic, and cervical transforaminal epidural injections, respectively.<sup>[5]</sup>

However, no previous publications have ever documented the vascular uptake rate for ganglion impar sympathetic nerve blocks. The purpose of this study was to document vascular uptake rate during ganglion impar sympathetic nerve blocks performed under fluoroscopic guidance with contrast enhancement.

## Subjects and Methods

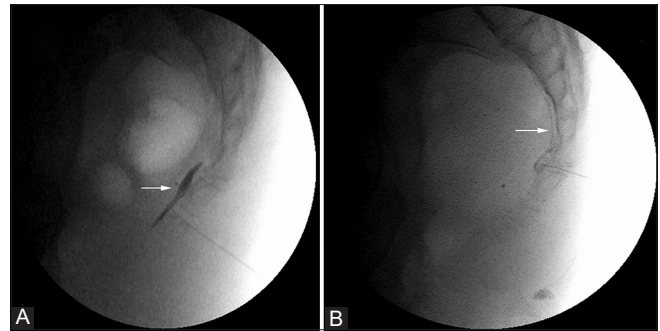
A total of 78 consecutive ganglion impar injections performed under fluoroscopic guidance for patients with coccydynia were evaluated. The patients were treated at a university-based Coccyx Pain Center. All these injections were performed using the trans-coccygeal (trans-disc) approach to the ganglion impar, where the needle is inserted from a posterior to anterior approach and traverses the sacrococcygeal or intercoccygeal joint space until it reaches just anterior to the coccyx (anterior to the anterior sacrococcygeal ligament, which is the inferior extension of the anterior longitudinal ligament of the spine). These approaches have been previously published.<sup>[1,6,7]</sup> After the needle tip reached this target location, the syringe plunger (piston) was withdrawn to look for any aspirated blood that would suggest intravascular placement, which in all cases was negative. Next, nonionic contrast (Omnipaque 300) was injected and fluoroscopy was used to evaluate the contrast flow pattern. Classically, contrast properly placed at the ganglion impar forms a “comma sign” when injected at this site, or hugs against the anterior coccygeal border [Figure 1A]. Conversely, in instances of vascular uptake, the injected contrast quickly disappears from the target site and/or can be seen in an intravascular pattern (e.g., a venogram appearance, Figure 1B).

In all 78 injections, the injecting physician documented whether the initial contrast flow pattern was vascular or not. Later, the patients’ procedure notes were retrospectively reviewed for statistical analysis.

This study was approved by the Institutional Review Board at the medical school university where the injections were performed.

## Results

Out of the 78 consecutive injections, only one patient (1.3%) demonstrated a vascular pattern [Figure 1B]. In that case, the position of the needle tip was slightly adjusted, and



**Figure 1 (A and B):** Classically, contrast properly placed at the ganglion impar forms a “comma sign” when injected at this site, or hugs against the anterior coccygeal border (Figure 1A). Conversely, in instances of vascular uptake, the injected contrast quickly disappears from the target site and/or can be seen in an intravascular pattern (e.g., a venogram appearance, Figure 1B)

the contrast then stayed locally, as desired, at the ganglion impar region.

## Discussion

Based on the results of this study, the rate of vascular uptake during ganglion impar injection using the trans-disc (trans-sacrococcygeal or trans-coccygeal) approach has been shown to be extremely low, at 1.3%. This implies that these injections could be performed without contrast and the risk of intravascular injection would be very low, at approximately 1%. Thus, without contrast, approximately 1% of such injections would be an intravascular local anesthetic bolus with potential systemic effects instead of the desired ganglion impar sympathetic nerve block. Theoretically, the potential systemic side effects from an intravascular local anesthetic bolus could be minimized by decreasing the total local anesthetic volume injected and/or decreasing the speed at which it is injected.

Even if aspiration prior to injection is negative for the withdrawal of a “flash” of blood, it is still possible to be intravascular. Specifically, if the bevel is against the blood vessel wall, then the negative pressure of aspiration may suction the vessel wall against the bevel, thus preventing aspiration of blood and giving the clinician a false reassurance against intravascular placement. Or, suction may cause the entire blood vessel to locally collapse, which would also result in a false-negative aspiration. Thus, contrast flow pattern is more reliable than aspiration.

Meanwhile, there are other reasons to give contrast besides the avoidance of an intravascular pattern. Contrast use can help to confirm that the tip of the injection needle is anterior to the anterior sacrococcygeal ligament (which is the inferior extension of the anterior longitudinal ligament of the spine). It is moderately common for the needle tip to appear appropriately located via fluoroscopy without contrast, only to find out via contrast that the needle tip is still, in fact,

posterior to the anterior sacrococcygeal ligament (which is a structure that is not in itself visible by fluoroscopy without contrast), which would result in an inadvertent injection into the coccygeal disc/joint. Thus, the contrast flow pattern is extremely helpful for ensuring that the needle tip is far enough anterior. On the other hand, contrast use is also necessary to confirm that the needle placement has not inadvertently been positioned too far anteriorly, i.e. within the rectum. Rectal perforation can generally be easily avoided via advancing only in small, controlled increments with intermittent fluoroscopic visualization.

A recent case report published in November 2019 noted a ganglion impar injection without contrast or even image guidance, which appeared to cause significant complications including cauda equina syndrome.<sup>[8]</sup> That case further demonstrates the importance of using image guidance and contrast, when possible.

Meanwhile, the peer-reviewed published literature has indicated that there are some risks added by contrast injection and that these risks can be independent of contrast dose and “unpredictable” so that even an injection of a very low volume of contrast would not be completely risk-free.<sup>[9]</sup>

Whether to use contrast or not in any particular patient is an individualized decision to be made by the treating physician. We hope that this research will aid clinicians in weighing the pluses and minuses of contrast administration during sympathetic nerve blocks of the ganglion impar.

### Financial support and sponsorship

Nil.

### Conflicts of interest

There are no conflicts of interest.

### References

1. Foye PM, Buttaci CJ, Stitik TP, Yonclas PP. Successful injection for coccyx pain. *Am J Phys Med Rehabil* 2006;85:783-784.
2. Oh CS, Chung IH, Ji HJ, Yoon DM. Clinical implications of topographic anatomy on the ganglion impar. *Anesthesiology* 2004;101:249-50.
3. Raphael JH, Southall JL, Treharne GJ, Kitas GD. Efficacy and adverse effects of intravenous lignocaine therapy in fibromyalgia syndrome. *BMC Musculoskelet Disord* 2002;3:21.
4. Park SJ, Yoon KB, Shin DA, Kim K, Kim TL, Kim SH, *et al.* Influence of needle-insertion depth on epidural spread and clinical outcomes in caudal epidural injections: A randomized clinical trial. *J Pain Res* 2018;11:2961-7.
5. Nahm FS, Lee CJ, Lee SH, Kim TH, Sim WS, Cho HS, *et al.* Risk of intravascular injection in transforaminal epidural injections. *Anaesthesia* 2010;65:917-21.
6. Foye PM. New approaches to ganglion impar blocks via coccygeal joints. *Reg Anesth Pain Med* 2007;32:269.
7. Wemm K Jr, Saberski L. Modified approach to block the ganglion impar (ganglion of Walther). *Reg Anesth* 1995;20:544-5.
8. Kuek DKC, Chung SL, Zishan US, Papanikitas J, Yanny S, Meagher T, *et al.* Conus infarction after non-guided transcoccygeal ganglion impar block using particulate steroid for chronic coccydynia. *Spinal Cord Ser Cases* 2019. doi: 10.1038/s41394-019-0237-1.
9. Böhm I, Morelli J, Nairz K, Silva Hasembank Keller P, Heverhagen JT. Myths and misconceptions concerning contrast media-induced anaphylaxis: A narrative review. *Postgrad Med* 2017;129:259-66.