



Case Report

Interdisciplinary Approach to an Unusual Case of Myocarditis in Pregnancy

Aude Marceau, MD,^a Justin M. McGinnis, MD,^b Fatemeh Derakhshan, MD,^c Yi Ariel Liu, MD,^c Gnalini Sathananthan, MBBS, BSc,^a Ana Clara Sosa Cazales, MD,^b Jasmine Grewal, BSc, MD,^a Andrew Ignaszewski, MD,^a Elisabet Joa, MD,^b Michael Luong, MD,^a Mustafa Toma, MD, MSc,^a Sean A. Virani, MD, MSc, MPH,^a and Michael A. Seidman, MD, PhD^{a,c}

^a Department of Medicine, Division of Cardiology, Providence Health Care/University of British Columbia, Vancouver, British Columbia, Canada

^b Department of Obstetrics and Gynaecology, Providence Health Care/University of British Columbia, Vancouver, British Columbia, Canada

^c Department of Pathology and Laboratory Medicine, Providence Health Care/University of British Columbia, Vancouver, British Columbia, Canada

ABSTRACT

We present a case of myocarditis in a 26-year-old pregnant woman at 29 weeks gestation. Despite optimal medical therapy, she experienced a cardiac arrest 10 days postadmission. An interdisciplinary team facilitated emergency delivery of her baby by perimortem (ie, during maternal cardiac arrest) Caesarean section and initiation of emergency mechanical circulatory support. A cardiac biopsy revealed a mixed eosinophilic and histiocytic infiltrate. After a course of steroid therapy, she experienced full recovery. Both the patient and the infant are alive and well. The case highlights the success of modern interdisciplinary care, as well as ongoing gaps in our knowledge of myocarditis.

RÉSUMÉ

Nous présentons un cas de myocardite chez une femme de 26 ans enceinte de 29 semaines, qui a subi un arrêt cardiaque 10 jours après son admission. Une équipe interdisciplinaire a favorisé l'accouchement d'urgence par césarienne perimortem (c.-à-d. durant l'arrêt cardiaque de la mère), et la mise en place en urgence d'une assistance mécanique. Une biopsie cardiaque a révélé un infiltrat mixte d'éosinophiles et d'histiocytes. Il y a eu récupération complète de la fonction ventriculaire après un traitement aux stéroïdes. La patiente et l'enfant sont en vie et se portent bien. Le cas témoigne de la réussite de la pratique moderne des soins interdisciplinaires, et met en lumière les lacunes actuelles de nos connaissances sur la myocardite.

Case Presentation

A 26-year-old gravida 4 para 2 woman at 29 weeks gestation presented to the hospital with 5 days of pleuritic chest pain, shortness of breath, and orthopnea. She recently quit smoking and had no known drug allergies, and her only medication was melatonin. Her obstetrical history included a spontaneous vaginal delivery, an elective Caesarean section, and a spontaneous miscarriage. At presentation, she was hypotensive (systolic blood pressure 75 mm Hg), tachycardic (heart rate 140–150 beats per minute), and borderline febrile (38.0°C).


Received for publication January 8, 2019. Accepted February 5, 2019.

Ethics Statement: This manuscript conforms to the Declaration of Helsinki and the Canadian Tri-Council Policy Statement version 2 (TCPS2).

Corresponding author: Dr Michael A. Seidman, Department of Pathology and Laboratory Medicine, 1081 Burrard St, Vancouver V6Z 1Y6, British Columbia, Canada. Tel.: +1-604-682-2344 ×64817; fax: +1-604-806-8158.

E-mail: mseidman@providencehealth.bc.ca

See page 105 for disclosure information.

Electrocardiogram revealed ST-segment elevation in the lateral leads. Her admission blood test results were remarkable for high-sensitivity troponin T 1200 ng/L, N-terminal pro-hormone brain natriuretic peptide 20,000 pg/mL, C-reactive protein 200 mg/dL, white blood count $18 \times 10^9/L$, and eosinophil count $0.7 \times 10^9/L$ (upper limit of normal). Kidney and liver function were normal. Blood cultures were negative. Angiogram showed no evidence of atherosclerosis. An echocardiogram (Video 1A-C , view video online) revealed global left ventricular (LV) systolic dysfunction (LV ejection fraction 30%) without dilation, elevated myocardial echogenicity, a slightly thickened myocardium (13-mm ventricular septum and 12-mm posterior wall), an elevated LV mass index (132 g/m^2), and a small pericardial effusion without tamponade. Chest computed tomography scan revealed a small right pleural effusion but no other significant pulmonary pathology. Cardiac magnetic resonance imaging was not performed because the patient could not lie flat. Fetal ultrasound showed normal fetal growth and amniotic fluid levels. Fetal noninvasive stress testing showed no fetal cardiac compromise.

Novel Teaching Points

- Interdisciplinary care teams are essential in pregnancy-associated heart failure and should be organized early in any care plan.
- Skilled learners can significantly supplement care teams.
- Emergency delivery during maternal cardiac arrest may assist resuscitative efforts.
- There is likely a role for endomyocardial biopsy in cases of myocarditis that fail to improve with supportive therapy alone.
- Biopsy is still limited in the ability to make precise distinctions between different etiologies of myocarditis.
- Mechanical circulatory support and immunosuppression may be helpful in a subset of patients with myocarditis, even without precise understanding of etiology.

A clinical diagnosis of myocarditis was made.^{1,2} At this time, the Anesthesia, Cardiac Intensive Care, Cardiac Obstetrics, Cardiology, Heart Failure, Maternal Fetal Medicine, Obstetrics, and Pediatrics services were all consulted to provide input as to the optimal care for the patient and her fetus. These services continued to follow the patient and reassess the situation daily. Emergency anaesthesia and Caesarean delivery carts were assembled at the patient's bedside in preparation for any clinical deterioration. Cardiac surgery was also consulted in the event that emergency mechanical circulatory support would be required, for example, in the event of a cardiac arrest. Milrinone and norepinephrine were administered to the patient. For 10 days, the patient remained in the cardiac intensive care unit with tachycardia approximately 120 beats per minute, troponin up to 1800 ng/L, and C-reactive protein up to 200 mg/L.

At 30 weeks plus 3 days gestational age, the patient experienced a pulseless electrical activity arrest. Already prepared for this possibility, the Obstetrics team arrived within 5 minutes of maternal circulatory arrest to perform an emergency bedside perimortem (ie, during maternal cardiac arrest) repeat Caesarean section. Less than 2 minutes later, the baby was delivered successfully, resuscitated by the pediatrics team (APGAR scores of 5 and 7 at 1 and 5 minutes, respectively, and a birth weight of 1670 g), and transferred to the neonatal intensive care unit. The mother, under ongoing management by the Anesthesia, Cardiac Intensive Care, Cardiac Surgery, and Heart Failure Cardiology services, experienced return of spontaneous circulation after 27 minutes of cardiopulmonary resuscitation, and both central venoarterial extracorporeal membrane oxygenation (ECMO) and empiric steroid therapy were initiated. Because this occurred in the middle of the night, limited staff were available to support this rapid and complex care process, with house staff from all specialties contributing significantly to rapidly implementing the necessary procedures, including the bedside delivery, maternal resuscitation, and initiation of mechanical circulatory support. As such, there were no delays that might otherwise have occurred in mobilizing care teams, facilitating the best possible outcome for the patient and her child.

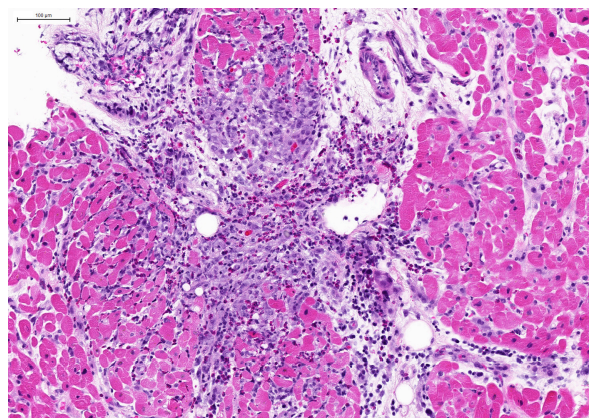


Figure 1. Endomyocardial biopsy findings. Biopsy taken at the time of cardiac arrest (10 days postadmission) showed myocardial necrosis and a predominantly eosinophilic and histiocytic inflammatory infiltrate. A high-resolution version of this slide for use with the Virtual Microscope is available as eSlide: VM05601.

Subsequent myocardial biopsy demonstrated multifocal myocyte necrosis with an inflammatory infiltrate composed predominantly of eosinophils and histiocytes (Fig. 1, Supplemental Digital Slide). In consultation among numerous subspecialty cardiac pathologists, the findings were ultimately interpreted as an atypical presentation of either (or both) eosinophilic myocarditis or giant cell myocarditis.³ Microbiological and serological investigations were unrevealing for a specific etiology. The exact diagnosis and proposed therapy at this point were discussed extensively at interdisciplinary rounds.

The patient was weaned off ECMO in less than 3 days and was ultimately discharged from the hospital 2 weeks after her delivery on oral prednisone. Less than 1 month after ECMO was discontinued, a repeat echocardiogram revealed normalization of her LV ejection fraction and LV wall thickness (Video 2A-C [\[video icon\]](#), view video online), and she was slowly weaned off prednisone. Her baby remained in the neonatal intensive care unit for routine care, given the prematurity, before being discharged home without complications.

Discussion

This case, although initially similar to other peripartum cardiac cases, was ultimately distinguished by the nature of an emergency delivery coincident with initiation of mechanical circulatory support and in having an indeterminate histologic diagnosis. Management included an extensive and well-integrated interdisciplinary care approach with an ultimately positive outcome. Each team was actively engaged in the patient's care and was ready to respond in the event of maternal or fetal deterioration. Furthermore, at every step, the process was facilitated by numerous skilled learners (medical students, residents, and fellows) and diverse team members, all of whom were available in the middle of the night, during times of reduced attending staff coverage, dramatically improving the ability to manage this complex and rapidly evolving case.

The exact etiology of the patient's presentation remains uncertain. The case was rapidly identified as a peripartum

cardiomyopathy, with a likely myocarditis etiology.^{4,5} Given poor evidence for the use of immunosuppressive treatment in acute myocarditis, the patient's initial management was conservative.^{6,7} After the patient's cardiac arrest, the cardiac biopsy demonstrated significant active myocarditis, but given an unusual histologic pattern, a precise diagnosis could not be rendered. Despite this uncertainty, the significant immunologic activity and severity of symptoms were deemed adequate to support a trial of steroids.^{1,2,8} Determining which component of treatment (systemic steroids, emergency delivery, or cardiac rest provided by ECMO) ultimately contributed most to her recovery remains unresolved.

Conclusion

This case highlights the success of modern emergency delivery, mechanical circulatory support, interdisciplinary care, and academic medical centres. It also highlights significant knowledge gaps in pregnancy-associated heart failure, the ability of current diagnostics to provide an etiologically specific diagnosis in cases of myocarditis, and the uncertainty around optimal individualized therapy in myocarditis.

Acknowledgements

The amazing outcomes in this case could not have been possible without the work of numerous members of the healthcare team across multiple disciplines. We acknowledge their significant contribution to the care of this patient. In particular, all of our colleagues, both physicians and staff, from Anesthesia, Cardiac Intensive Care Unit, Cardiac Obstetrics, Cardiac Surgery, Cardiology, Interventional Cardiology, Obstetrics, and Pediatrics, as well as nursing and allied health, were of critical importance to the positive outcome for this patient and her child.

Funding Sources

The preparation of this case report was supported entirely by internal institutional funds.

Disclosures

The authors have no conflicts of interest to disclose.

References

1. Feldman AM, McNamara D. Myocarditis. *N Engl J Med* 2000;343:1388-98.
2. Cooper LT. Myocarditis. *N Engl J Med* 2009;360:1526-38.
3. Seidman MA, McManus BM. Chapter 9 - Myocarditis. In: Butany J, Buja LM, eds. *Cardiovascular Pathology*. 4th ed. New York: Elsevier, 2016:341-59.
4. Blauwet LA, Cooper LT. Diagnosis and management of peripartum cardiomyopathy. *Heart* 2011;97:1970.
5. Karaye KM, Henein MY. Peripartum cardiomyopathy: a review article. *Int J Cardiol* 2013;164:33-8.
6. Heart Failure Society of America. HFSA 2010 Comprehensive Heart Failure Practice Guideline. *J Card Fail* 2010;16:e2.
7. Howlett JG, McKelvie RS, Arnold JMO, et al. Canadian Cardiovascular Society Consensus Conference guidelines on heart failure, update 2009: diagnosis and management of right-sided heart failure, myocarditis, device therapy and recent important clinical trials. *Can J Cardiol* 2009;25:85-105.
8. Frustaci A, Russo MA, Chimenti C. Randomized study on the efficacy of immunosuppressive therapy in patients with virus-negative inflammatory cardiomyopathy: the TIMIC study. *Eur Heart J* 2009;30:1995-2002.

Supplementary Material

To access the supplementary material accompanying this article, visit *CJC Open* at <https://www.cjopen.ca/> and at <https://doi.org/10.1016/j.cjco.2019.02.001>.