

## Pregnancy in a woman with untreated bladder exstrophy: a case report

Suhui Wu<sup>a,\*</sup>, Jingfen Sun<sup>a</sup>, Huimin Lv<sup>a</sup>, Yangang Zhang<sup>b</sup>, Haixia Shang<sup>c</sup>, Huajun Zhang<sup>b</sup>, Jerome L. Belinson<sup>d</sup>

<sup>a</sup> Department of Obstetrics and Gynecology, Shanxi Academy of Medical Sciences & Shanxi Dayi Hospital, Taiyuan 030032, Shanxi, China

<sup>b</sup> Department of Urology, Shanxi Academy of Medical Sciences & Shanxi Dayi Hospital, Taiyuan 030032, Shanxi, China

<sup>c</sup> Department of Obstetrics and Gynecology, Dayi Hospital of Shanxi Medical University, Taiyuan 030001, Shanxi, China

<sup>d</sup> Preventive Oncology International Inc. and Women's Health Institute, Cleveland Clinic, Cleveland, OH, USA

### ARTICLE INFO

#### Article history:

Received 11 January 2018

Received in revised form 2 February 2018

Accepted 27 February 2018

Available online 10 March 2018

#### Keywords:

Bladder exstrophy

Infection

Pregnancy

Urinary tract

### ABSTRACT

**Objective:** To report the management of urinary tract obstruction and infection in a pregnant woman with unrepai red bladder exstrophy.

**Case Report:** A 27-year-old pregnant woman with unrepai red bladder exstrophy was referred to our hospital with a complaint of bilateral flank pain in the second trimester. After two-dimensional abdominal ultrasound, magnetic resonance imaging and a urine analysis, she was diagnosed with an upper urinary tract infection due to ureteral obstruction secondary to unrepai red congenital bladder exstrophy and an intrauterine pregnancy. J-tube insertion was performed after locating the ureteral orifices and antibiotics were administered. Symptoms rapidly resolved. She delivered a normal male infant by caesarean section at 34 weeks of gestation.

**Conclusion:** Standard urological management of the ureteral obstruction in pregnancy was successful in this extreme case of unrepai red bladder exstrophy associated with an intrauterine pregnancy. The perinatal outcome was good.

© 2018 Published by Elsevier B.V. This is an open access article under the CC BY-NC-ND license (<http://creativecommons.org/licenses/by-nc-nd/4.0/>).

### 1. Introduction

Bladder exstrophy (BE) is a rare congenital anomaly of the genitourinary tract that is in the spectrum of the exstrophy–epispadias complex. The embryological mechanism is unknown, though it is thought to be a ventral fusion error due to failed reinforcement of the cloacal membrane by the underlying mesoderm [1]. Its most visible consequence is protrusion of the dorsal mucosal surface of the urinary bladder (trigone and ureteral orifices exposed) through a defect in the abdominal wall. The clinical presentation frequently will include other ventral fusion defects, including of the pubic symphysis, pelvic musculature and genitalia [2,3]. The function of the urinary and reproductive systems is often affected. The benefits of exstrophy repair include moving the bladder into the abdomen (with a reconstructed ventral wall), developing control of urination, reducing the risk of infection, reducing the risk of urinary obstruction, improving physical appearance (self-esteem) and reducing the risk of infertility [2]. Several centres have collectively reported more than 130 corrected BE patients, experiencing more than 100 pregnancies. These data include more than 55 caesarean sections, with 4 stillbirths and 1 neonatal death [4–6]. However, rarely has pregnancy been reported in non-reconstructed BE patients [7,8]. Here, we present the case of a pregnancy in a woman with untreated

BE, who in addition developed urinary tract obstruction and upper tract infection in the second trimester.

### 2. Case Report

A 27-year-old pregnant woman (gravida 1, para 0) with unrepai red bladder exstrophy was referred to our hospital with a chief complaint of bilateral flank pain in the second trimester. The patient was diagnosed with congenital BE but reconstructive surgery was refused by her family. Her regular menstrual cycles had started at the age of 13 years. She had no medical complaint in relation to sexual intercourse and conceived normally. She had not received any antenatal care before this hospital visit. Her medical history and family history were unremarkable.

Physical examination revealed her vital signs were stable. Heart, lung and neurological examinations were unremarkable. Her body mass index (BMI) was 22.6 kg/m<sup>2</sup>. The abdomen was enlarged secondary to a 21<sup>+3</sup>-week pregnancy. The pubic symphysis was not fused, resulting in a 14 cm separation. The exposed mucosa of the posterior bladder wall occupied the lower central abdomen with absence of an umbilicus, urinary meatus, anterior abdominal wall and anterior bladder wall. The mucosal edges of the bladder were fused with the skin. Paroxysmal urine egressed from the exposed ureteral orifices. The vaginal introitus was small and presented as a line approximately only 2.5 cm in length. Percussion pain was evident over the kidneys bilaterally.

\* Corresponding author at: No. 99 Longcheng Street, Taiyuan 030032, Shanxi Province, China.

E-mail address: [shwu1215@163.com](mailto:shwu1215@163.com) (S. Wu).

Laboratory data showed normal complete blood count and normal renal function. A urine sample was collected from the exstrophy and urinalysis showed sheets of white blood cells. A magnetic resonance urography (MRU) was used to identify the level of the obstruction of the urinary tract because computerized tomography (CT) urography is not appropriate to use during pregnancy. Both two-dimensional abdominal ultrasound and MRU exams revealed a single intrauterine pregnancy with maternal bilateral hydronephrosis, ureteral stricture and ureterectasis.

Ceftriaxone was used because the drug was available to us and its spectrum of activity covers bacteria found in urinary tract infections. In addition, the US Food and Drug Administration (FDA) lists ceftriaxone in category B, which is generally considered safe for use during pregnancy. Therefore, ceftriaxone sodium was administered at a dose of 1.0 g BID by intravenous drip. Bilateral J-tubes were inserted ureteroscopically. The J-tubes were secured and connected to sterile collection bags. The patient was discharged when symptoms had resolved and the urine tested clear after 11 days of IV antibiotics in hospital.

The patient did not return to our clinic until 34 weeks' gestation, when she began to experience irregular uterine contractions and light vaginal bleeding. Two-dimensional abdominal ultrasound showed a single intrauterine pregnancy (compatible with 33<sup>+6</sup> weeks of gestation) in the breech position and second-degree placental maturity. Laboratory data showed mild anaemia. The management strategy included promoting fetal lung maturation with dexamethasone, tocolytic therapy with magnesium sulfate, anti-anaemia treatment with oral haematinics and antibiotics, along with careful fetal monitoring. After three days of monitoring, a caesarean section was performed secondary to regular uterine contractions, a transverse lie presentation, and the previously described small vaginal introitus. Care was provided by a team that included obstetricians, a urologist and an anaesthetist. A transverse incision 12 cm long was made in the skin located three-horizontal-finger distance above the upper edge of exstrophic bladder (Fig. 1). The uterus and both adnexa appeared normal. A healthy normal male infant was positioned transverse-breech and delivered weighing 2010 g through a low transverse incision in the uterus. The 1-minute Apgar score was 9, and the 5-minute Apgar score was 10. When

checking the placenta, a partial placental abruption was evident, with a separation area of 4 cm × 5 cm.

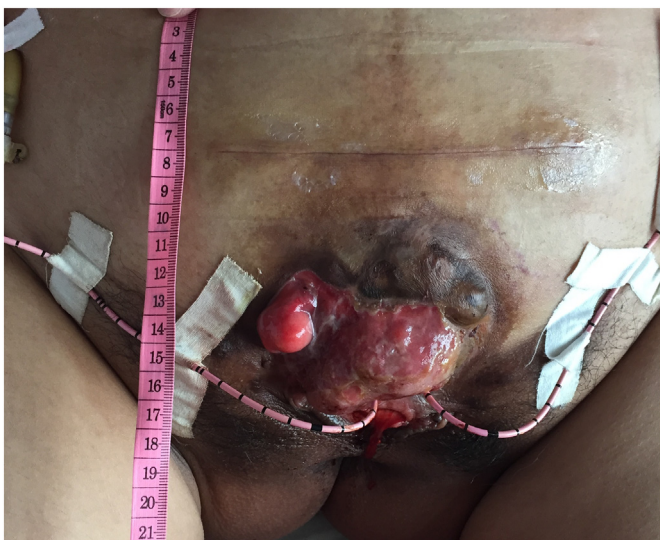The patient was discharged on her 7th post-delivery day with both her and her baby in good condition. She was scheduled for a postpartum evaluation and a discussion of reconstructive therapy for her bladder exstrophy. A post-partum pelvic X-ray was obtained to aid in the planning of the reconstructive surgery. The X-ray revealed that the rami of the pubic bones were chondrified and separated by 14 cm. The two J-tubes were imaged in situ. The left J-tube showed a circuitous trajectory and its upper end was located lower than the position of a normal kidney. This tube remained in a stable position even though it did not reach the location of her left kidney, which was documented by two-dimensional abdominal ultrasound and MRU to be in a normal position. We believe the J-tube followed this circuitous trajectory as a result of ureterovesical obstruction, which led to pyeloureterectasis and circuitous ureter (Fig. 2).

A repair plan was offered but the patient refused further treatment. Therefore, she was scheduled for radiographic evaluation 6-weeks postpartum to assess the upper urinary tract prior to removal of the J-tubes. After appropriate patient education concerning recurrent obstruction, the patient was scheduled for regular follow-up with colour Doppler ultrasound.

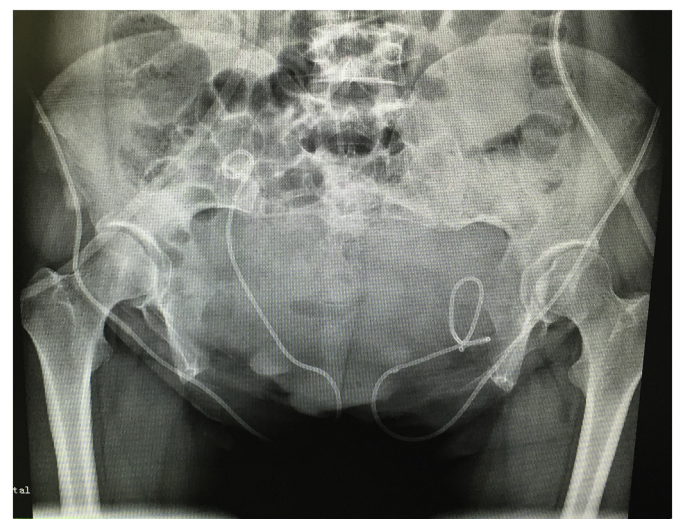
### 3. Discussion

Bladder exstrophy is a rare congenital anomaly that is often accompanied by multiple malformations [1]. Patients who have not undergone reconstructive surgery have more complications. Obstetric complications include infection, prematurity, placental abruption, malpresentations and genital prolapse [1]. Reported urinary complications include: urinary tract infection, urinary obstruction, hydronephrosis, ureteral stricture and ureteric stones [1,2]. In our case all these complications were present except for genital prolapse and ureteric stones. Urinary tract infection is very common due to the defects of abdominal wall and bladder wall. In our case this was diagnosed by symptoms and numerous white blood cells in urinalysis. BE can also lead to stricture of uretero-vesical orifices (as it did in our case) which causes uretero-vesical obstruction followed by pyeloureterectasis and hydronephrosis [1]. This was confirmed by two-dimensional abdominal ultrasound and MRU in our patient. Furthermore, the enlarged gestational uterus aggravated the uretero-vesical obstruction.

Ideally, urinary tract infection and uretero-vesical obstruction in such patients should be monitored by urinalysis, urine culture, colour



**Fig. 1.** Post-corporeal caesarean section image showing the untreated exstrophic bladder. Operative incision was well healed. Bladder exstrophy was untreated. Umbilicus was absent and inner surface of the posterior wall of the bladder occupied the lower central abdomen. The mucosal edges of the exstrophic bladder were fused with the skin. J-tubes were inserted in both ureteral orifices and connected with urine collecting bags. Vaginal orifice located below exstrophic bladder as line shape and meatus urinarius was absent.



**Fig. 2.** Bone radiography of pelvis. X-ray revealed the rami of the pubic bones were chondrified and separate by 14 cm. Circuitous inserted J-tube image is shown on the left of the image.

Doppler ultrasound exam and even MRU exam. Unfortunately, our patient was non-compliant. Antibiotics were of course important and effective in combination with removal of the obstruction. Extensive surgical intervention should be avoided until the pregnancy has concluded to avoid inducing an abortion or premature labour [9]. In our case the intraureteral J-tube insertion with the assistance of a ureteroscope was successful, and was the least invasive way to remove the obstruction.

Often, due to the non-closure of the pubic symphysis, vaginal birth is readily achievable in these patients [10]. However, the delivery in our case was more complex. Caesarean section delivery was the only option due to malformations of the birth canal and malpresentation. In addition, the presence of a placental abruption would have added progressive risk. Caesarean section was performed promptly at the onset of labour [3]. It was difficult to decide the position of the incision since the lower central abdomen was occupied by the exstrophic bladder. We were concerned that a high incision would make it difficult to deliver the fetal head [7]. We did the caesarean section after choosing a transverse incision of 12 cm at three-horizontal-finger distance above the upper edge of the exstrophic bladder, and then made a low transverse incision in the uterus. We assembled a multidisciplinary team so we could respond confidently to any unexpected events.

In conclusion, although BE is rare, pregnancies in women with untreated BE do occur, and are often accompanied by urinary and obstetric complications. Reconstructive surgery should also be offered to improve quality of life.

#### Contributors

All authors have made a substantive contribution to the information or material submitted for publication and take public responsibility.

#### Conflict of Interest Statement

The authors declare that they have no conflict of interest.

#### Funding

No funding was sought or secured in relation to this case report.

#### Consent

Written informed consent was obtained from the patient for the publication of this case report and the accompanying images.

#### Provenance and Peer Review

This case report was peer reviewed.

#### References

- [1] E.C. Muecke, The role of the cloacal membrane in exstrophy: the first successful experimental study, *J. Urol.* 92 (1964) 659.
- [2] R. Deans, F. Banks, L.M. Liao, D. Wood, C. Woodhouse, S.M. Creighton, Reproductive outcomes in women with classic bladder exstrophy: an observational cross-sectional study, *Am. J. Obstet. Gynecol.* 206 (6) (2012) (496.e1–6).
- [3] G.G. Mendes, J.R. Lusa, Bladder exstrophy, *Rev. Assoc. Med. Bras.* 62 (3) (2016) 197–198.
- [4] G.W. Dy, K.H. Willihnganz-Lawson, M. Shnorhavorian, et al., Successful pregnancy in patients with exstrophy-epispadias complex: a University of Washington experience, *J. Pediatr. Urol.* 11 (4) (2015) (213.e1–6).
- [5] A.M. Giron, C.C. Passerotti, H. Nguyen, J.A. Cruz, M. Srougi, Bladder exstrophy: reconstructed female patients achieving normal pregnancy and delivering normal babies, *Int. Braz. J. Urol.* 37 (5) (2011) 605–610.
- [6] C.R. Blakeley, W.G. Mills, The obstetric and gynaecological complications of bladder exstrophy and epispadias, *Br. J. Obstet. Gynaecol.* 88 (2) (1981) 167–173.
- [7] T. Hanprasertpong, V. Wootipoom, M. Tanthanuch, J. Hanprasertpong, Successful pregnancy in a non-reconstructed congenital bladder exstrophy woman: the first case report, *Arch. Gynecol. Obstet.* 288 (4) (2013) 955–957.
- [8] A. Mandal, S. Chaudhuri, S.S. Manna, S.K. Jana, T. Biswas, S. Das, Successful pregnancy outcome in a woman with untreated ectopia vesicae: a case report and review of literature, *J. Obstet. Gynaecol. Res.* 39 (4) (2013) 868–871.
- [9] E. Schlußner, The prevention, diagnosis and treatment of premature labor, *Dtsch. Arztebl. Int.* 110 (13) (2013) 227–235.
- [10] R. Lachica, Y. Chan, K.R. Uquillas, R.H. Lee, Vaginal delivery after Dührssen incisions in a patient with bladder Exstrophy and uterine prolapse, *Obstet. Gynecol.* 129 (4) (2017) 689–692.