

A Pilot Study to Investigate the Efficacy of Tobramycin–Dexamethasone Ointment in Promoting Wound Healing

Rachel Andrew · Gwendolyn Luecke ·
Susan Dozier · Dayna G. Diven

To view enhanced content go to www.dermtherapy-open.com
Received: July 19, 2012 / Published online: August 28, 2012
© The Author(s) 2012. This article is published with open access at Springerlink.com

ABSTRACT

Introduction: The standard postsurgical treatment of wounds after dermatologic procedures is currently limited. Topical corticosteroids have been used successfully in postoperative management of ophthalmologic surgeries that involve the skin of the eyelid. In particular, tobramycin 0.3%/dexamethasone 0.1% ophthalmic ointment is considered the “gold standard” of steroid-antibiotic fixed combinations and is marketed worldwide as an agent used to control postsurgical inflammation and prevent postsurgical infection. The purpose of this study is to evaluate both the efficacy and

safety of tobramycin–dexamethasone ointment for the postsurgical management of Mohs or dermatologic surgery in comparison to white petrolatum.

Methods: The authors employed a half-scar study in which patients who underwent skin cancer removal surgery were given tobramycin–dexamethasone ointment and white petrolatum to apply to each half of their wound for 2 weeks. The study was double blinded, and physicians and the patients independently evaluated the scars for cosmetic appearance at 2 and 6 weeks postoperatively. The evaluation criteria included judging which side of the wound looked better based on color, thickness, and discomfort.

Results: Eighteen patients were enrolled, of which 13 patients completed the three phases of the study. After 6 weeks the wounds did not show a statistically significant difference in color, thickness, or discomfort on either side.

Conclusion: Results obtained to date suggest that the application of tobramycin–dexamethasone ointment to wounds after dermatologic surgery does not promote better wound healing than white petrolatum. These findings indicate that a topical steroid and antibiotic ointment may not be an effective intervention in improving

R. Andrew (✉) · G. Luecke
University of Texas Southwestern Medical Center,
Dallas, TX 75390, USA
e-mail: Rachel.Andrew@utsouthwestern.edu

S. Dozier · D. G. Diven
Department of Dermatology, University of Texas
Southwestern Austin Program, Dallas, TX 75390,
USA



Enhanced content for this article is
available on the journal web site:
www.dermtherapy-open.com

postoperative outcomes in dermatologic surgeries.

Keywords: Half scar; Tobramycin; Tobramycin-dexamethasone; Wound healing

INTRODUCTION

Aesthetically pleasing wound healing is a topic of great interest. The success of a surgery is often judged by the appearance of a scar, which may lead to numerous cosmetic and psychological consequences for the patient, including anxiety, self-consciousness, and low self-esteem [1]. Current recommendations for postoperative wound care following Mohs and other dermatological surgery include the application of white petrolatum or a topical antibiotic to the closed incision site before covering the wound with a dressing in order to create a moist healing environment [2, 3]. In recent years, studies have questioned the benefit of topical antibiotics in lieu of white petrolatum in reducing the incidence of postoperative wounds or leading to a more positive cosmetic outcome [2]. In this study, we sought to improve wound healing and reduce infection and inflammation by applying a tobramycin-dexamethasone ointment to the wound postoperatively. We believed that the combination of antimicrobial and anti-inflammatory agents might serve to improve the cosmetic appearance of the scars following skin cancer removal surgery.

Tobramycin-dexamethasone is a sterile, multiple dose antibiotic and steroid combination, US Food and Drug Administration approved for steroid-responsive inflammatory ocular conditions for which a corticosteroid is indicated and where the risk of bacterial infection may exist. Between 2001 and 2006,

physicians prescribed over 16.3 million doses of tobramycin-dexamethasone—more than any other steroid/antibiotic ophthalmic combination [4]. Tobramycin-dexamethasone is a widely used empiric therapy for suspected eye infection, and studies performed by Rhee and Mah [5] demonstrated that it significantly decreases all signs of ocular inflammation including blepharitis, discharge, and conjunctivitis. Tobramycin-dexamethasone has been found to improve wound healing successfully after ophthalmic surgeries by suppressing the inflammatory response and protecting against infection by susceptible strains of Gram-positive and Gram-negative microorganisms [6].

In addition to its role in ocular and cataract research, tobramycin-dexamethasone has proved effective in reducing extracellular matrix deposition in the treatment of external and middle ear inflammation. In a study performed with murine models, corticosteroids effectively reduced the formation of granulation tissue at the wound site [7]. The amount of extracellular matrix components, especially collagen, was decreased as were the angiogenic factors that contributed to the blood supply of the wound. The corticosteroid agent inhibited the synthesis and processing of multiple enzymes contributing to inflammation, and in this manner effectively reduced granulation tissue formation [7].

The purpose of this pilot study was to examine whether tobramycin-dexamethasone ointment, as both a corticosteroid and antimicrobial agent, was more effective in promoting wound healing than white petrolatum.

MATERIALS AND METHODS

The authors performed an institutional review board approved, double blinded, randomized

pilot study. Patients who had undergone skin cancer removal surgery were recruited. The investigation was designed as a half-scar study similar to those that have been employed to test the efficacy of other topical agents in promoting wound healing [8].

Study Design

After completing surgery, the patients were given two de-identified ointments, one of which was white petrolatum, a common emollient, and the other was the tobramycin–dexamethasone combination ointment. Each ointment was randomly labeled A or B. The postsurgery scars were randomly divided into two halves, A and B, distal and proximal or medial and lateral depending on the position of the incision. Patients were asked to put ointment A on side A and ointment B on side B twice daily for 2 weeks, starting immediately after surgery.

The physicians and the patients independently evaluated the scars for cosmetic appearance on weeks 2 and 6. In this study, we used a simplified version of the patient and observer scar assessment scale (POSA) [9]. This scar assessment scale, developed by Draaijers et al. [9], takes into consideration both the opinion of the patient and the physician when considering wound healing. The observer scar assessment scale evaluates a scar based on vascularity, pigmentation, thickness, relief, and pliability on a numerical rating scale from 1 (normal skin) to 10 (worst scar imaginable). The patient scar assessment scale evaluated the scar on the same scale, but based on pain, itching, color, stiffness, thickness, and irregularity. The opinions of the observer were shown to be most affected by color (vascularization and pigmentation) and thickness, whereas the opinions of the patients were mainly influenced by itching and thickness of the scar [9].

Although the POSA was developed for burn scars specifically, further investigation has also proved it a reliable method of evaluation for linear scars [10]. We adapted the scale for our small group of patients in our pilot study so that the patients and observers evaluated the scar based on the same parameters shown to be most significant in the POSA: color, thickness, and discomfort. The patients and observers then made an overall judgment on which side of their scar appeared “better,” while taking the above said parameters into consideration.

After the patients’ and the observer’s opinions were recorded, a third blinded investigator was also shown photographs of the outcomes, and his opinions were noted.

Data Analysis

As this is a pilot study, the analysis consists of descriptive statistics. The results are presented as a percentage of the total number of patients who assessed their wounds as healing equally on both sides, better on the tobramycin–dexamethasone half, and better on the control half.

A total of 13 patients was included. The demographic characteristics included seven women and six men, with a mean age of 59 years (range 34–82 years). They consisted of all non-Hispanic white adults. The scars were located on the face ($n = 2$), neck ($n = 2$), chest ($n = 3$), back ($n = 1$), arm ($n = 3$), and leg ($n = 2$). The average scar length was approximately 4 cm, which was deemed sufficient to perceive a difference between the two halves. Data were recorded as shown in the [Appendix](#).

RESULTS

Twenty-four patients were assessed for eligibility, six were excluded because they were taking anticoagulants, 18 completed enrollment,

and 13 completed the study with 6 weeks of follow-up. Those who did not complete the study withdrew on the day of surgery when they were reminded of the study requirements, and they reported that it was due to the added inconvenience of applying more than one ointment to their scar postoperatively.

No patients withdrew from the study after receiving the two ointments. None of the patients experienced adverse reactions to the medications such as hypersensitivity and localized toxicity, itching, swelling, and erythema. Overall assessment at 2 weeks demonstrated a relatively equal distribution between the halves appearing equal, better on the tobramycin–dexamethasone half, and better on the white petrolatum half.

As seen in Fig. 1, when the patient's subjective opinion of the scar was procured, approximately half of the patients deemed that the scars had healed equally well on both sides at 2 weeks. Observer 1 deemed that 69% of the scars were equal, and observer 2 deemed that there was an equal distribution between the halves appearing equal, the tobramycin–dexamethasone half appearing better, and the control appearing better.

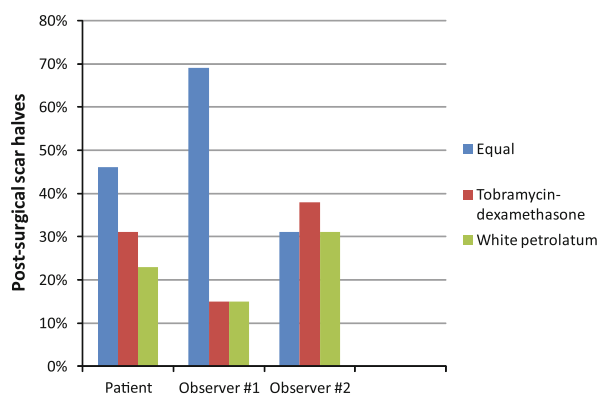


Fig. 1 The comparison of the scar halves at 2 weeks by each evaluator

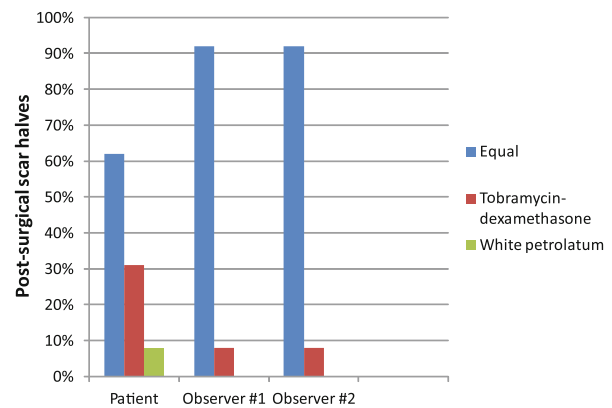


Fig. 2 The comparison of the scar halves at 6 weeks by each evaluator

Figure 2 demonstrates that by 6 weeks patients and observers found no perceivable difference in the two halves of the scar in the majority of cases. Sixty-two percent of patients found no perceivable difference in the two halves of their scar. According to both observers, over 90% of the scars were deemed identical on both sides. Overall, the results of the study did not show that tobramycin–dexamethasone ointment was more effective in reducing erythema, scar thickness, or discomfort than white petrolatum, nor did tobramycin–dexamethasone lead to a more attractive cosmetic outcome to the scar.

DISCUSSION

Both physicians and patients have employed a variety of methods to improve wound healing, including compression therapy, acrylic casts, antihistamine drugs, silicone sheeting, and a variety of topical creams [11]. The present study was the first to our knowledge to compare the effect of this particular steroid-antibiotic combination to the current standard of care in patients undergoing skin cancer removal surgery. Although topical steroids and antibiotics have been used successfully for many types of skin care [2], our study did not

indicate that a steroid-antibiotic agent improved the cosmetic outcome of scars after dermatologic surgery.

A limitation to the study was the small sample size, as many of the patients screened were excluded on the basis of their anticoagulation medications. The results could be confirmed by a larger study in a more diverse group of subjects. Another limitation was possible inaccuracy in the application of each agent to its specified half of the scar. However, this may not have impacted the outcome of the study because the majority of the scars were equal on each side, demonstrating that there was no benefit of one agent over the other.

Corticosteroids have been shown to be associated with impaired wound healing and skin atrophy probably due to their inhibition of collagen synthesis and degradation [12]. Topical antibiotics have been associated with allergic contact dermatitis and are known contributors to antibiotic resistance [13].

In conclusion, a topically applied corticosteroid and antibiotic combination did not offer improved cosmesis and wound healing when compared to petrolatum.

ACKNOWLEDGMENTS

Dr. Degan is the guarantor of this article, and takes responsibility for the integrity of the work as a whole.

Conflict of interest. No conflicts of interest have been reported by the authors or by any individuals in control of the content of this article.

Open Access. This article is distributed under the terms of the Creative Commons Attribution Noncommercial License which permits any noncommercial use, distribution, and reproduction in any medium, provided the original author(s) and the source are credited.

APPENDIX

See Tables 1 and 2.

Table 1 Example of the table supplied to patients to record their subjective comparison of the appearance of the two halves of the scar at set points in time after surgery

Time	Tobramycin-dexamethasone better	Control better	No difference
2 weeks			
6 weeks			

Table 2 Example of the table supplied to observers to record their blinded subjective comparison of the appearance of the two halves of the scar at set points in time after surgery

Time	Tobramycin-dexamethasone better	Control better	No difference
2 weeks			
6 weeks			

REFERENCES

1. Brown BC, McKenna SP, Siddhi K, McGrouther DA, Bayat A. The hidden cost of skin scars: quality of life after skin scarring. *J Plast Reconstr Aesthet Surg.* 2008;61:1049–58.
2. Sheth VM, Weitzul S. Postoperative topical antimicrobial use. *Dermatitis.* 2008;19:181–9.
3. Drucker CR. Update on topical antibiotics in dermatology. *Dermatol Ther.* 2012;25:6–11.
4. Scoper SV, Kabat AG, Owen GR, et al. Ocular distribution, bactericidal activity and settling characteristics of TobraDex ST ophthalmic suspension compared with TobraDex ophthalmic suspension. *Adv Ther.* 2008;25:77–88.
5. Rhee SS, Mah FS. Comparison of tobramycin 0.3%/dexamethasone 0.1% and tobramycin 0.3%/loteprednol 0.5% in the management of blepharokeratoconjunctivitis. *Adv Ther.* 2007;24:60–7.
6. Russo S, Papa V, Di Bella A, et al. Dexamethasone-netilmicin: a new ophthalmic steroid-antibiotic combination. Efficacy and safety after cataract surgery. *Eye (Lond).* 2007;21:58–64.
7. Sobol SE, Keswani S, Parvadia JK, Crombleholme T, Potsic WP. Effect of corticosteroid-antibiotic agents

- on granulation tissue in a murine model. *Arch Otolaryngol Head Neck Surg.* 2005;131:330–5.
8. Baumann LS, Spencer J. The effects of topical vitamin E on the cosmetic appearance of scars. *Dermatol Surg.* 1999;25:311–5.
 9. Draaijers LJ, Tempelman FR, Botman YA, et al. The patient and observer scar assessment scale: a reliable and feasible tool for scar evaluation. *Plast Reconstr Surg.* 2004;113:1960–5 (discussion 6–7).
 10. Van de Kar AL, Corion LU, Smeulders MJ, Draaijers LJ, Van der Horst CM, Van Zuijlen PP. Reliable and feasible evaluation of linear scars by the Patient and Observer Scar Assessment Scale. *Plast Reconstr Surg.* 2005;116:514–22.
 11. Bayat A, McGrouther DA, Ferguson MW. Skin scarring. *BMJ.* 2003;326:88–92.
 12. Oishi Y, Fu ZW, Ohnuki Y, Kato H, Noguchi T. Molecular basis of the alteration in skin collagen metabolism in response to in vivo dexamethasone treatment: effects on the synthesis of collagen type I and III, collagenase, and tissue inhibitors of metalloproteinases. *Br J Dermatol.* 2002;147:859–68.
 13. Draelos ZD, Rizer RL, Trookman NS. A comparison of postprocedural wound care treatments: do antibiotic-based ointments improve outcomes? *J Am Acad Dermatol.* 2011;64(3 Suppl.):S23–9.