



Surgical resolution of an oesophageal duplication cyst causing regurgitation in a domestic shorthair cat

Journal of Feline Medicine and Surgery
Open Reports
1–4

© The Author(s) 2015
Reprints and permissions:
sagepub.co.uk/journalsPermissions.nav
DOI: 10.1177/2055116915623799
jfmsopenreports.com



Ivan CP Doran¹, Lou J Dawson² and Marta Costa³

Abstract

Case summary An 18-month-old female domestic shorthair cat was referred for investigation of a 6 month period of regurgitation. Contrast radiography indicated an intramural oesophageal structure. Ultrasound-guided fine-needle aspiration of the area retrieved viscous fluid containing high numbers of squamous epithelial cells. Computed tomography disclosed a thin-walled contrast-enhancing structure containing non-enhancing homogenous contents. Exploratory thoracotomy confirmed an intramural cystic oesophageal structure, which was resected. Histopathological analysis of the resected tissue demonstrated an intramural oesophageal duplication cyst. A 12 month follow-up period has seen complete resolution of the cat's clinical signs.

Relevance and novel information This is the first report of successful oesophageal duplication cyst removal in a cat. Oesophageal duplication cysts should be included on the differential list for dysphagia and regurgitation in cats. Complete surgical removal in this cat carried a good long-term outcome.

Accepted: 1 December 2015

Case description

An 18-month-old female domestic shorthair cat was referred to our facility for investigation of a 6 month history of regurgitation. The episodes were progressively frequent and occurred after each meal. The cat had a ravenous appetite and was underweight. Postural feeding and empirical treatment for oesophagitis was initiated (famotidine 0.5 mg/kg PO q12h and sucralfate 250 mg PO q12h), but this regimen had no effect on the cat's clinical signs.

The referring veterinary surgeon had obtained cervical and thoracic radiographs, both before and after oral administration of barium sulfate. These radiographs had been submitted to the imaging department at our facility for a further opinion. A space-occupying lesion was visible that had characteristics of a cranial mediastinal mass, such as tracheal elevation, in addition to characteristics of an oesophageal dilation/diverticulum. The cat was referred for further investigation.

Computed tomographic imaging demonstrated a well-defined space-occupying lesion, measuring 26 mm × 26 mm × 50 mm, within the cranial mediastinum, lying flush to the left thoracic wall. The lesion was fluid

attenuating (mean Hounsfield unit value 16). The lesion's thin wall enhanced postcontrast administration (2.5 g IV iopamidol), while its homogenous contents did not enhance.

The lesion compressed the trachea and cranial vena cava where these structures passed dorsal to the lesion. At the thoracic inlet, the oesophagus was markedly and focally dilated with gas ventral to the trachea. It was displaced ventrally and to the right side and was compressed by the cranial thoracic lesion, before resuming a more normal position dorsolateral and to the right of the trachea at the level of the fourth pair of ribs.

¹Small Animal Surgery Department University of Bristol, Bristol, UK

²Pathology Department, University of Bristol, Bristol, UK

³Clinical Pathology Department, University of Bristol, Bristol, UK

Corresponding author:

Ivan CP Doran BVSc, Cert SAS, DSAS (Soft Tissue), Small Animal Hospital, Bristol University School of Veterinary Science (Langford Veterinary Services), Langford, Bristol, BS40 5DU, UK
Email: ivan.doran@bristol.ac.uk



An ultrasound-guided fine-needle aspirate harvested thick cream-coloured material from the space-occupying lesion. Cytological analysis demonstrated very high numbers of well-differentiated squamous epithelial cells exhibiting mild anisocytosis, polygonal-to-angular shape with predominantly pyknotic nuclei and fully keratinised pale blue cytoplasm. Additionally, there were low numbers of non-degenerated neutrophils and very low numbers of deeply vacuolated macrophages. No organisms were seen. No criteria for neoplasia were identified.

The following day the cat underwent surgical resection of the mass. A median sternotomy was performed along sternbrae 1–6, using an oscillating saw. The mass was found to be within the wall of the thoracic oesophagus. An oesophageal tube was passed orally and guided by the surgeon past the oesophageal mass. The oesophageal muscle was incised longitudinally over the mass and the exposed mass was bluntly dissected free after a plane of cleavage was identified (Figure 1). The mass was readily separated from the oesophageal tissues and appeared smooth and thin walled. At one point in the procedure, the mass wall began to split releasing turbid fluid that resembled that retrieved during fine-needle aspiration. When the mass was removed, only a translucent non-muscular membrane separated the oesophageal lumen from the external surface. The oesophagus in this region was repaired using 4-0 polydioxanone sutures in a simple interrupted pattern, engaging the submucosa and the muscular layer.

A 10 F Mila chest drain was placed at the left seventh intercostal space and the sternotomy site was closed in routine fashion, employing 2-0 polydioxanone figure-of-eight mattress sutures around the sternbrae. The overlying pectoral muscles, subcutaneous tissues and skin were closed in layers.

Multi-modal analgesia was provided; an epidural block (morphine) was administered preoperatively, an opiate (fentanyl) continuous rate infusion was administered intra- and postoperatively, local anaesthetic was infused into the parasternal tissues during surgery and non-steroidal anti-inflammatory agents were delivered postoperatively.

The mass was fixed in 10% neutral buffered formalin, processed routinely and embedded in paraffin (Figure 2). Sections were cut at 5 µm and stained with haematoxylin and eosin. The histopathological appearance was of a partially collapsed cystic mass, the lumen of which contained a small amount of amorphous, eosinophilic material (fluid) with aggregates of macrophages, neutrophils and sloughed epithelial cells. The cyst lining consisted of stratified squamous epithelium, appearing multifocally spongiotic and being infiltrated by small numbers of lymphocytes, plasma cells and neutrophils. The

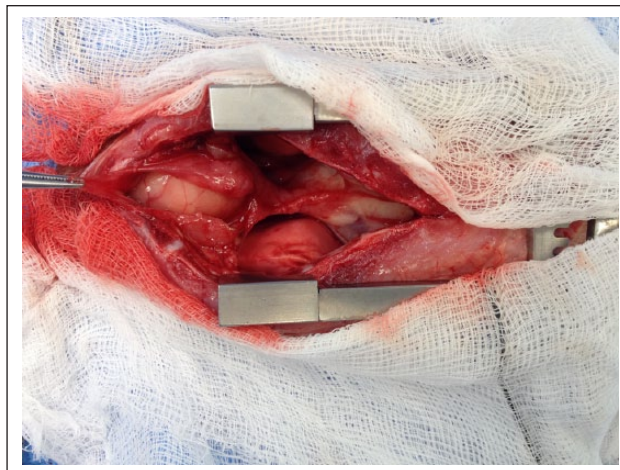


Figure 1 Cranial sternotomy. The cat's head is to the left. The ventral wall of the thoracic oesophagus has been longitudinally incised to reveal the duplication cyst

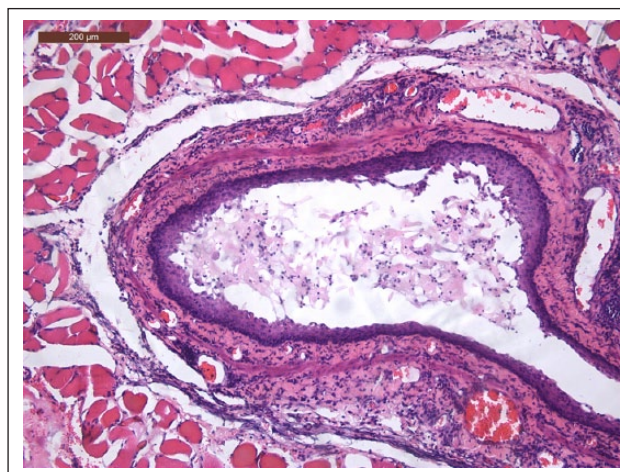


Figure 2 Histology. The cyst wall is surrounded by skeletal muscle and the lumen contains sloughed epithelial cells (haematoxylin and eosin, × 100)

connective tissues underlying the epithelium contained a moderate-to-marked, nodular-to-coalescing infiltrate of lymphocytes and plasma cells, with some macrophages and neutrophils. The inflammation extended into skeletal muscle surrounding the cyst, where it varied from aggregates of lymphocytes and plasma cells to large numbers of neutrophils infiltrating between skeletal muscle myocytes. The histopathological appearance of the cyst was considered consistent with a diagnosis of intramural oesophageal duplication cyst.

At the time of writing (June 2015), 12 months after surgery, the cat has gained weight, has had no further episodes of regurgitation since its return home, receives no medication and eats a normal commercial (dry and tinned) cat food.

Discussion

This is the first report, to our knowledge, of successful removal of an oesophageal duplication cyst in a cat. An oesophageal duplication cyst has been reported once in a dog, five times in horses and once in a crab-eating macaque (*cynomolgus* monkey).¹⁻⁷ Duplication cysts have been reported in the lower gastrointestinal tract in cats.^{8,9} They are a recognised phenomenon in humans, although they are considered to be very rare.¹⁰ Differential diagnoses include a thyroglossal duct cyst, which has been reported in both the cervical tissues and mediastinum of cats,^{11,12} in addition to branchial cysts, which have been reported in cats.¹³ Other differential diagnoses included abscessation and neoplasia.

Mediastinal cysts typically display a clear low-cellularity fluid and are usually lined with columnar ciliated epithelium. Both of these features contrast with the cytological picture in this case. Another distinguishing feature is that mediastinal cysts do not include a muscular wall. Simple oesophageal cysts are reported in humans. Unlike duplication cysts, simple oesophageal cysts exhibit only an epithelial lining. To our knowledge, simple oesophageal cysts are also yet to be reported in cats.

Oesophageal duplication cysts are congenital abnormalities of the foregut. In humans, they arise from developmental abnormalities which occur during the first 8 weeks of embryological development. They are characterised by three elements:¹⁴ (1) the cyst is contained within or attached to the oesophageal wall; (2) the cyst wall includes one or two muscle layers (this distinguishes them from simple oesophageal cysts, which only contain epithelium within their wall); and (3) the epithelial layer represents some level of the gastrointestinal tract (squamous, cuboidal, columnar, ciliated or pseudostratified).

There are three types of foregut duplication cysts in humans: bronchogenic, oesophageal (enteric) and neuroenteric. Bronchogenic cysts are the most common cystic lesions of the mediastinum and are usually accompanied by cartilaginous tissue in the cystic wall. Neuroenteric cysts are oesophageal duplication cysts that extend into the spinal canal. In the literature, foregut duplication cysts have been reported in one dog and in one cat,^{1,9} and both were non-neuroenteric oesophageal cysts. In 80–90% of human cases, oesophageal duplication cysts do not communicate with the oesophageal lumen. All locations along the oesophageal axis are represented. Their aetiology is unknown.

Several theories are proposed regarding the aetiopathogenesis.¹⁵ The first is that during embryological development, the laryngotracheal groove divides into the dorsal and ventral portions, which become the oesophagus and respiratory tract, respectively. An oesophageal cyst forms when the secretory vacuoles during foregut luminal obliteration fail to coalesce. The

timing of the budding error dictates the location of the cyst. The second theory is partial or abortive twinning, namely the incomplete fusion of two individuals during embryogenesis. Intrauterine vascular accidents are the third theory. Finally, there is the split notochord theory. The notochord separates from the endoderm during embryogenesis due to ingrowth of mesoderm. If this separation is incomplete, endoderm is drawn into the spinal canal, creating either a cyst or diverticulum and causing failure of ventral closure of the spinal canal. This is the only theory that can explain the association, seen in humans, between mediastinal duplications and vertebral anomalies.

One cat has been reported with multiple cysts along the gastrointestinal tract,⁹ which included a cyst in the caudal thoracic oesophagus. That cyst was partially resected and omentalisised on two occasions but recurred each time and so the cat underwent a third surgery but did not recover from general anaesthesia.

Oesophageal duplication cysts may cause dysphagia and discomfort, because of local compression of the oesophageal lumen. Rupture of these cysts, in a mediastinal location, has been reported to cause mediastinitis in humans. A single report of malignant transformation exists in the human literature.¹⁶

Conclusions

Treatment of oesophageal duplication cysts entails surgical removal. The reported prognosis following complete surgical resection is good.¹⁰ Oesophageal duplication cysts should be included in the list of differentials for cats presenting with regurgitation or dysphagia.

Funding The authors received no financial support for the research, authorship, and/or publication of this article.

Conflict of interest The authors declared no potential conflicts of interest with respect to the research, authorship, and/or publication of this article.

References

- 1 Gabor LJ and Walshaw R. **Oesophageal duplication cyst in a dog.** *Vet Pathol* 2008; 45: 61–62.
- 2 Bassage LH, Habecker PL, Russell EA, et al. **Colic in a horse associated with a massive cystic duplication of the ascending colon.** *Equine Vet J* 2000; 32: 565–568.
- 3 Loynachan AT. **Oesophageal cyst in the duodenum of a foal.** *J Vet Diagn Invest* 2014; 26: 308–311.
- 4 Peek SF, De Lahunta A and Hackett RP. **Combined oesophageal and tracheal duplication cyst in an Arabian filly.** *Equine Vet J* 1995; 27: 475–478.
- 5 Taylor EA, Lillich JD, Canada N, et al. **Caecal duplication in a 13-year-old Thoroughbred.** *Equine Vet Educ* 2014; 26: 477–480.
- 6 Orsini JA, Sepesy L, Donawick WJ, et al. **Oesophageal duplication cyst as a cause of choke in the horse.** *J Am Vet Med Assoc* 1988; 193: 474–476.

- 7 Okazaki Y, Matsumota M, Tsubota K, et al. **Foregut cyst of the esophageal wall in a cynomolgus monkey (*Macaca fascicularis*)**. *J Comp Path* 2006; 135: 256–262.
- 8 Kook PH, Hagen R, Willi B, et al. **Rectal duplication cyst in a cat**. *J Feline Med Surg* 2010; 12: 978–981.
- 9 Bernardé A, Forget J and Bernard F. **Multiple level enteric duplication cysts in a cat**. *Rev Vet Clin* 2014; 49: 31–35.
- 10 Lima M. (ed) *Pediatric thoracic surgery*. Bologna, Italy: Springer, 2013.
- 11 Giles JT, Rochat MC and Snider TA. **Surgical management of a thyroglossal duct cyst in a cat**. *J Am Vet Med Assoc* 2007; 230: 686–689.
- 12 Lynn A, Dockins JM, Kuehn NF, et al. **Caudal mediastinal thyroglossal duct cyst in a cat**. *J Small Anim Pract* 2009; 50: 147–150.
- 13 Joffe DJ. **Branchial cyst in a cat**. *Can Vet J* 1990; 31: 525–526.
- 14 Arbona JL, Fazzi JGF and Mayoral J. **Congenital esophageal cysts: case report and review of literature**. *Am J Gastroenterol* 1984; 79: 177–182.
- 15 Parikh D and Singh M. **Esophageal duplication cysts**. In: Puri P (ed). *Newborn surgery*. 3rd ed. Dublin, Ireland, FL: Taylor & Francis, 2011, pp 406–411.
- 16 Lee MY, Jensen E, Kwak S, et al. **Metastatic adenocarcinoma arising in a congenital foregut cyst of the esophagus: a case report with a review of the literature**. *Am J Clin Oncol* 1998; 21: 64–66.