

Solution of Azelaic Acid (20%), Resorcinol (10%) and Phytic Acid (6%) Versus Glycolic Acid (50%) Peeling Agent in the Treatment of Female Patients with Facial Melasma

Abstract

Background: Melasma, a common acquired disorder of hyperpigmentation, especially in women, is often resistant to therapy. This study was aimed to evaluate the efficacy and safety of azelaic acid, resorcinol and phytic acid solution in chemical peeling of melasma in comparison to 50% glycolic acid. **Materials and Methods:** This clinical trial was performed, on 42 female patients with bilateral melasma. Severity of melasma was assessed by melasma area and severity index (MASI). Combination of (20% azelaic acid + 10% resorcinol + 6% phytic acid) was used as a new peeling agent on the right side of the face and 50% glycolic acid on the left side every 2 weeks for 6 times. Follow-up was carried out for 3 months after the last session. Any decrease in MASI score and unwanted complications following peeling were evaluated and compared during the trial. **Results:** Patients showed marked improvement as calculated with MASI score before and after treatment in both sides of the face. The efficacy of combination formula (azelaic acid, resorcinol and phytic acid) was similar to glycolic acid, but with fewer complications. There was no statistically difference in improvement between two groups ($P > 0.05$). However, the patient's discomfort following procedures was significantly lower with azelaic acid, resorcinol and phytic compared with the glycolic acid peels ($P < 0.05$) and there was the same duration in the beginning of the therapeutic response in both groups. **Conclusion:** Results showed that triple-combination was found to be an effective and safe peeling agent in the treatment of melasma and it was as effective as 50% glycolic acid peel.

Keywords: Azelaic acid, glycolic acid, melasma, phytic acid, resorcinol

Introduction

Melasma is a commonly acquired, localized, usually symmetrical hyperpigmentation characterized by irregular, light to dark-brown macules affecting the cheeks, forehead, chin and predominantly in women with skin type IV to VI.^[1] It occurs almost exclusively in the sun exposed area, especially those living in areas of intense ultraviolet radiation.^[2]

However, sunlight, pregnancy, thyroid disturbances and hormonal therapy are all thought together to play a role in pathogenesis, but the exact etiology of melasma is unknown.^[3] In previous studies of patients with a variety of skin types a significant effect on quality-of-life has been documented.^[4,5] Sun screens, sun avoidance and bleaching agents, such as 4% hydroquinone alone or in combination with retinoid and topical steroids are

conventional treatments.^[6,7] In addition, in some patients who do not respond to bleaching agents alone, superficial peeling agents have been reported to be of profit.^[8]

α -Hydroxy acids are non-toxic acids formed naturally in foods like sugarcane (glycolic acid). It is reported that using high concentrations and a larger number of glycolic acid peels have shown a positive effect on melasma. Furthermore, azelaic acid has anti-inflammatory, antibacterial and antikeratinizing effects, which make it useful in a variety of dermatologic conditions.^[9] Triple-combination agent is formulated as follows: 20% azelaic acid^[10] +10% resorcinol^[11] +6% phytic acid^[12] in hydroalcoholic base. The purpose of the current prospective study was to determine if the triple-combination agent, compared with glycolic acid peel, produced

This is an open access article distributed under the terms of the Creative Commons Attribution-NonCommercial-ShareAlike 3.0 License, which allows others to remix, tweak, and build upon the work non-commercially, as long as the author is credited and the new creations are licensed under the identical terms.

For reprints contact: reprints@medknow.com

How to cite this article: Faghihi G, Taheri A, Shahmoradi Z, Nilforoushzadeh MA. Solution of Azelaic Acid (20%), Resorcinol (10%) and Phytic Acid (6%) Versus Glycolic Acid (50%) Peeling Agent in the Treatment of Female Patients with Facial Melasma. *Adv Biomed Res* 2017;6:9.

Received: January, 2013. **Accepted:** May, 2013.

**Gita Faghihi,
Azam Taheri,
Zabihollah
Shahmoradi,
Mohammad Ali
Nilforoushzadeh¹**

From the Skin Disease and Leishmaniasis Research Center, Department of Dermatology, Isfahan University of Medical Sciences, Isfahan, ¹Skin and Stem Cell Research Center, Tehran University of Medical Sciences, Tehran, Iran

Address for correspondence:
Mrs. Azam Taheri,
Skin Diseases and Leishmaniasis
Research Center, Department
of Dermatology, Isfahan
University of Medical Sciences,
Isfahan, Iran.
E-mail: univertaheri@
yahoo.com

Access this article online

Website: www.advbiosres.net

DOI: 10.4103/2277-9175.200784

Quick Response Code:



significant improvement of melasma in women with facial melasma with skin type III and IV.

Materials and Methods

This study was conducted between January, 2012 and October, 2012, on 42 female patients with melasma at department of dermatology in Isfahan University of medical sciences. Female patients between 18 and 65 years old with skin type IV or less with bilateral facial melasma were eligible if they had epidermal or mixed melasma based on wood's light examination at the time of recruitment were resistant or intolerant to topical therapy and hypersensitivity to hydroquinone products. Exclusion criteria, included: Skin type more than IV, pregnancy, use of 4% hydroquinone formulation within 3 months of entry; history of chemical peels, microdermabrasion or facial laser treatment within 9 months of entry, history of drug hypersensitivity, active orolabial herpes infection, history of hypertrophic scar or keloid, uncooperative patients for follow-up and sun protection after peeling and in cases, which erythema is persistent until the next session. This study was investigated and approved in Isfahan University of Medical Sciences (number: 390540) and written informed consent after the participating patients were explained about and informed of the purposes of the study, was obtained from them all. A detailed history was taken from each patient at the onset of the study. A careful wood's light examination of melasma was performed including the following: Site, distribution, homogeneity and the color of the patches. Clinical assessment of melasma severity was graded with the melasma area and severity index (MASI) score.^[13] In this scoring system, the face is divided into four areas: Forehead, right malar, left malar and chin that correspond respectively to 30%, 30%, 30% and 10% of the total face area. The melasma in each of these areas was graded on three parameters [Table 1].

Then, the MASI score calculated on each side of the face at baseline and before each session by the equation:

MASI score on right side of the face:

$$\frac{0.3(DF+HF)AF}{2} + 0.3(DMR+HMR) \\ AMR + \frac{0.1(DC+HC)AC}{2}$$

MASI score on the left side of the face:

$$\frac{0.3(DF+HF)AF}{2} + 0.3(DML+HML) \\ AML + \frac{0.1(DC+HC)AC}{2}$$

Where D is darkness, H is homogeneity, A is area, F is forehead, MR is right malar, ML is left malar and c is chin. The values 0.3, 0.3, 0.3 and 0.1 stand for respective

Table 1: Graded of melasma in each of face areas

A: Percentage of total area involved	D: Darkness	H: Homogeneity
No involvement	No melasma	Normal skin color without evidence of hyperpigmentation
<10	Barely visible hyperpigmentation	Specks of involvement
10-29	Mild hyperpigmentation	Small patch areas of involvement <1.5 cm diameter
30-49	Moderate hyperpigmentation	Patches of involvement >2 cm
50-69	Severe hyperpigmentation	Uniform skin involvement without any clear area
70-89		
90-100		

percentage of total facial area. Maximum MASI score for total face is 48 and on each side of the face is 24.

Photographic assessment color photograph for each patient were performed at a baseline and before each session and at the end of treatment. All photographs were taken using a canon-digital camera, 8 megapixels. All patients were photographed in the same place with fixed illumination and distance. Peels were performed using the previously mentioned protocol.^[7] The patients cleaned their face before treatment and then the face was defatted with acetone solution. A small fan chilled the treated area. Nearly, 50% glycolic acid solution was applied on the left side of the face for all patients. Using the standard cotton-tipped applicators, the 50% glycolic acid was spread over the melasma area on the left side of the face. The forehead area was treated first, following by the malar area and finally the chin area. an erythematous response or burning sensation by the patient were the end point. If neither of them occurred, 50% glycolic acid was left for 5 min, after that it was washed with tap water.

Combination formula (20% azelaic acid + 10% resorcinol + 6% phytic acid) solution was applied on the right side of the face for all patients, with the same manner. Again an erythematous response or burn sensation by patient were end points, if not present, it left for longer than previous agent. All treatment regimens manufactured and prepared in Isfahan University, Faculty of Pharmacy. A moisturizing sunblock was applied (sensitive skin sunblock SPF 30). Patients who complained from discomfort or redness and exfoliation of the face were given 1% hydrocortisone skin cream to be applied twice daily.

Patients were seen regularly every 2 weeks to assess the response to treatment, to record the side effect and to calculate MASI score for each patient.

All patients were evaluated for the frequency of complications and type of complication (erythema, dyspigmentation, burning, atrophy and scar) on each side of the face before beginning the peeling.

All analyses were performed by SPSS version-20 and data are reported as mean \pm SD and number (percent) as appropriate. Repeated measurement of analysis of variance test was used to compare the mean of MASI score during 10 weeks treatment between two groups. On the other way, MASI score in each week and change in MASI score at each time point compared with baseline between two sides of the face were assessed using paired-samples *t*-test. Furthermore, Chi-square test was used for comparison of the frequency of complications between groups. The level of significance is considered to be less than 0.05.

Results

Four patients of 46 reviewed patients were not eligible and did not enter to the study. Also, of 42 patients, during follow-up one patient did not desire to continue and was excluded. Finally, 41 patients completed the study and analyzed either; most patients had noted a relationship with sun exposure. The mean age studied patients was 35.21 ± 9.16 years old and 78% of them were married. Characteristics of studied patients are summarized in Table 2.

Table 3 shows the mean of MASI score at time points in study groups. As shown during the treatment period mean of MASI score decreased in both groups, whereas in (20% azelaic acid + 10% resorcinol + 6% phytic acid) group this score decreased from 8.12 at baseline to 4.01 at the end of treatment (week-10), also, in glycolic acid group the score decreased from 8.25 at baseline to 3.97 at week-10. Analyses show that in time points and during 10 weeks treatment mean of MASI score were similar in both groups and there were no statistical difference between groups ($P > 0.05$). Decrease in MASI score at time points compared to baseline was assessed between (20% azelaic acid + 10% resorcinol + 6% phytic acid) and glycolic acid groups using paired *t*-test. At week-2 MASI score in (20% azelaic acid + 10% resorcinol + 6% phytic acid) group was decrease more than glycolic acid groups, but in weeks 4, 6, 8 and 10, MASI score in glycolic acid group was decrease more than (20% azelaic acid + 10% resorcinol + 6% phytic acid) group. A difference in a decrease in MASI score in each session compared with the baseline was not statistically significant between both groups [Figure 1].

Response to treatment in patients at the end of treatment was assessed in both groups. Response to treatment define as decrease in MASI score: No response: $<25\%$, moderate: $25-50\%$, good: $50-75\%$ and excellent: $>75\%$. Figure 2 shows the comparison of the frequency of response to treatment between study groups. Most of the patients in both groups had good response and no response to

Table 2: Characteristics of 41 female patients with melasma

Characteristics	
Age	35.2 \pm 9.16
Marital status	
Married	32 (78)
Unmarried	9 (22)
Fitzpatrick skin type	
III	20 (48.7)
IV	21 (51.2)
Type of melasma	
Epidermal	19 (46.3)
Mixed	22 (53.7)
Duration of melasma (years)	5.2 \pm 3.56
Aggravating factor	
Oral contraceptive	5 (12.2)
Pregnancy	13 (31.7)
Sun exposure	32 (78)

Data presented as mean \pm SD or number (percent)

Table 3: Comparison of MASI score in study groups

MASI score	Solution of azelaic acid, resorcinol and phytic acid	Glycolic acid	P value*
Baseline	8.12 \pm 3.11	8.25 \pm 3.25	0.9
Week-2	7.6 \pm 2.8	8.08 \pm 2.73	0.57
Week-4	7.1 \pm 2.35	7.15 \pm 2.49	0.9
Week-6	5.44 \pm 1.93	5.48 \pm 1.98	0.91
Week-8	4.59 \pm 1.55	4.25 \pm 1.51	0.46
Week-10	4.01 \pm 1.22	3.97 \pm 1.11	0.73
P value†	0.49		

Data are mean \pm SD; P values calculated by *paired-samples *t*-test and †repeated measurement of ANOVA; MASI: Melasma area severity index

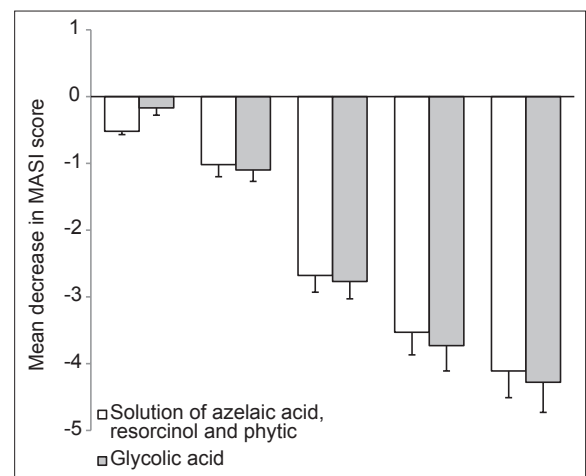


Figure 1: The mean decrease in melasma area severity index (MASI) score in each group in sequential weeks in comparison with baseline MASI score. Data are mean \pm SEM, P values derived from by Paired-Samples *t*-test. There were no significant differences between study groups

treatment in study groups was similar. Differences in the frequency of response to treatment between (20% azelaic

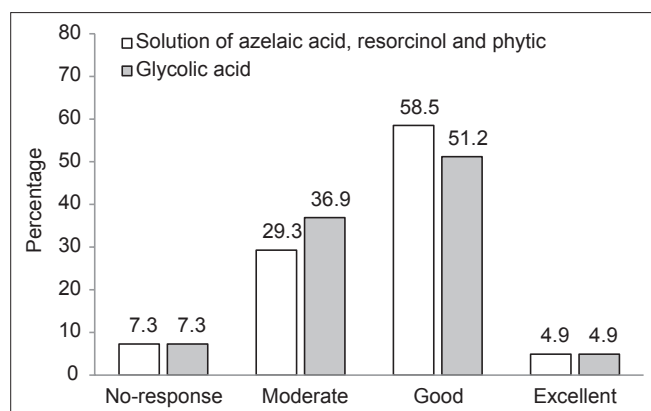


Figure 2: Comparison of the percentage of response to treatment in 41 female patients with melasma. *P* value derived from Chi-square test. There were no significant differences between study groups ($P=0.08$). Response to treatment define as decrease in melasma area severity index score, no response: <25%, moderate: 25-50%, good: 50-75%, and excellent: >75%

acid + 10% resorcinol + 6% phytic acid) and 50% glycolic acid groups were not significant based on Chi-square analyses ($P > 0.05$). Figure 3 is an example of a patient who completed the study. Evaluation of complication in patients showed that in (20% azelaic acid + 10% resorcinol + 6% phytic acid) group there is no complication and patients are more satisfied from this chemical peel than glycolic acid peel. In glycolic acid group, there is no persistent erythema, atrophy or scar, but 31.7% (13 patients) have a burning sensation that long for few days and 36.4% (15 patients) have dyspigmentation that treated by bleaching agent such as hydroquinone. Using Chi-square test showed that there is statistical difference ($P < 0.0001$) between two groups.

Discussion

Topical treatments are largely aimed at disrupting the enzymatic procedures of pigment production within melanocytes because of define melasma as a disorder of pigmentation.^[14] This study aimed to confirm the efficacy and safety of (20% azelaic acid + 10% resorcinol + 6% phytic acid) and 50% glycolic acid in the treatment of facial melasma and our results showed that improvement in patients in both groups with using the MASI score, was observed; however, there was no significant difference detected between the efficacy of two drugs. There was no complication with (20% azelaic acid + 10% resorcinol + 6% phytic acid), but in glycolic acid group there were complications that was statically significant.

The role of peeling agents in melasma is controversial. Several studies have reported improvement with superficial peeling agents^[8,15-17] while others have not showed significant improvement.^[18,19] Clinically recurrence of melasma was seen in the majority of both patient groups at the 3-months follow-up, indicate that triple topical therapy should still be considered as the gold standard in the treatment of melasma.

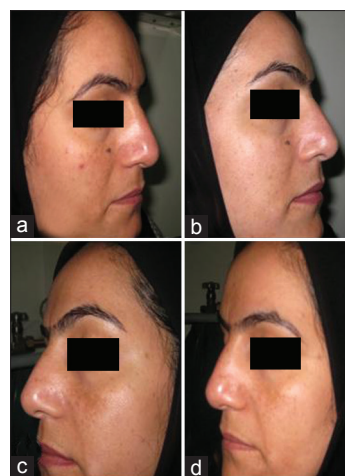


Figure 3: Example of patient showing improvements on both sides. Right side at baseline (a) and week-10 after using solution 20% azelaic acid, 10% resorcinol and 6% phytic acid (b), left side at baseline (c) and week-10 after using 50% glycolic acid (d)

Most of the previous experience with α -hydroxy acid peels in melasma is limited to glycolic acid.^[8] one study demonstrated that serial glycolic acid peels provide an additional effect for treating melasma in dark-skinned individuals if used judiciously and under supervision.^[8] Another study showed that prepeel program followed by 50% glycolic acid facial peel once per month for 3 consecutive months proved to be an effective treatment modality without any significant side-effects.^[17]

In one split-face study comparing a glycolic acid/hydroquinone preparation to a glycolic acid/kojic acid preparation, the authors found improved melasma, but no significant difference between the two formulations in terms of clinical efficacy.^[20] A gel containing glycolic acid and hydroquinone examined in another split-face trial and results showed more improvement in patients applying a gel that also contained kojic acid versus a gel that contained only glycolic acid and hydroquinone.^[21] The effect of varying concentrations of glycolic acid peels for melasma studied in a dose-response trial and authors in this study found that 52.5% glycolic acid applied for 3 min led to clinical improvement, whereas lower concentrations did not.^[22] A decrease in MASI score in patients with mixed or epidermal melasma after 2 weeks treatment by sun protection involved the use of 10% glycolic acid followed by monthly 50% glycolic acid facial peels for 3 months was reported in Indian females with melasma.^[17] Results of all referred studies in agreement with our result demonstrated that glycolic acid improved melasma; however, in these studies glycolic acid alone or in combination with other drugs and in different dose was assessed.

New combination formula used in this study contains azelaic acid, resorcinol and phytic acid that before it wasn't used in clinical trials. Azelaic acid is a natural dicarboxylic acid that is tyrosinase inhibitor and inhibits production of

free oxygen radicals by neutrophils and reduces oxidative tissue injury in inflammation site and therefore production of melanin.^[10] Resorcinol is a dihydroxybenzene that used in the treatment of acne, psoriasis and dyspigmentation.^[11] Phytic acid is an ester of acid hexaphosphoric inositol, is a major constituent of most cereals and soybean. It is a chelating agent that inhibits entrance iron and copper in to the cells and therefore inhibits melanin production.^[12]

The investigators in a study evaluated patients with epidermal melasma treated with azelaic acid plus adapalene with half of the group additionally treated with glycolic acid peels of increasing concentrations every 2 weeks and found that the group treated with peels in addition to agent topical had more decrease in MASI scores as compared to the group using the topical alone.^[23] It is shown that the combination of azelaic acid with 0.05% tretinoin or 15-20% glycolic acid may produce earlier, more pronounced skin lightening,^[24] also, azelaic acid was shown to be as effective as HQ 4%, but without its side effects.^[25] These studies showed the effect of azelaic acid in combination with other drugs and in combination with glycolic acid, in treatment of melasma, our findings despite the difference in drugs combination were similar with these results.

Limitations of this study may be are the inclusion of only female patients with skin types III and IV and the use of only six peel sessions and due to study conditions we were unable to blind patients about kind of treatment each side of patients face. Furthermore, there was difference in face washing after treatment whereas, in glycolic acid group, face was washed after maximum 5 min, but in (20% azelaic acid + 10% resorcinol + 6% phytic acid) group face was washed after 10 min. Therefore, we suggest further randomized, controlled trials using these drugs with good sample size and in different dose to improve the management of this disorder.

Conclusion

Results of this study demonstrated that (20% azelaic acid + 10% resorcinol + 6% phytic acid) solution was to be an effective and safe peeling agent in the treatment of melasma and it was as effective as 50% glycolic acid peel.

Declaration of patient consent

The authors certify that they have obtained all appropriate patient consent forms. In the form the patient(s) has/have given his/her/their consent for his/her/their images and other clinical information to be reported in the journal. The patients understand that their names and initials will not be published and due efforts will be made to conceal their identity, but anonymity cannot be guaranteed.

Financial support and sponsorship

Financial support was provided by the Isfahan University of Medical Sciences (Grant 390540); Isfahan, Iran.

Conflicts of interest

There are no conflicts of interest.

References

1. Grimes PE. Melasma. Etiologic and therapeutic considerations. *Arch Dermatol* 1995;131:1453-7.
2. Kroon MW, Wind BS, Beek JF, van der Veen JP, Nieuweboer-Krobotová L, Bos JD, *et al.* Nonablative 1550-nm fractional laser therapy versus triple topical therapy for the treatment of melasma: A randomized controlled pilot study. *J Am Acad Dermatol* 2011;64:516-23.
3. Grimes PE, Bhawan J, Guevara IL, Colón LE, Johnson LA, Gottschalk RW, *et al.* Continuous therapy followed by a maintenance therapy regimen with a triple combination cream for melasma. *J Am Acad Dermatol* 2010;62:962-7.
4. Balkrishnan R, McMichael AJ, Camacho FT, Saltzberg F, Housman TS, Grummer S, *et al.* Development and validation of a health-related quality of life instrument for women with melasma. *Br J Dermatol* 2003;149:572-7.
5. Dominguez AR, Balkrishnan R, Ellzey AR, Pandya AG. Melasma in Latina patients: Cross-cultural adaptation and validation of a quality-of-life questionnaire in Spanish language. *J Am Acad Dermatol* 2006;55:59-66.
6. Ennes SB, Paschoalick RC, Mota M. A double-blind, comparative, placebo-controlled study of the efficacy and tolerability of 4% hydroquinone as a depigmenting agent in melasma. *J Dermatol Treat* 2000;11:173-9.
7. Taylor SC, Torok H, Jones T, Lowe N, Rich P, Tschen E, *et al.* Efficacy and safety of a new triple-combination agent for the treatment of facial melasma. *Cutis* 2003;72:67-72.
8. Sarkar R, Kaur C, Bhalla M, Kanwar AJ. The combination of glycolic acid peels with a topical regimen in the treatment of melasma in dark-skinned patients: A comparative study. *Dermatol Surg* 2002;28:828-32.
9. Gupta AK, Gover MD, Nouri K, Taylor S. The treatment of melasma: A review of clinical trials. *J Am Acad Dermatol* 2006;55:1048-65.
10. Bansal C, Naik H, Kar HK, Chauhan A. A Comparison of Low-Fluence 1064-nm Q-Switched Nd: YAG Laser with Topical 20% Azelaic Acid Cream and their Combination in Melasma in Indian Patients. *J Cutan Aesthet Surg* 2012;5:266-72.
11. Kolbe L, Mann T, Gerwat W, Batzer J, Ahlheit S, Scherner C, *et al.* 4-n-butylresorcinol, a highly effective tyrosinase inhibitor for the topical treatment of hyperpigmentation. *J Eur Acad Dermatol Venereol* 2013;27 Suppl 1:19-23.
12. Levy JL, Pons F, Agopian L, Besson R. A double-blind controlled study of a nonhydroquinone bleaching cream in the treatment of melasma. *J Cosmet Dermatol* 2005;4:272-6.
13. Gilchrist BA, Fitzpatrick TB, Anderson RR, Parrish JA. Localization of melanin pigmentation in the skin with Wood's lamp. *Br J Dermatol* 1977;96:245-8.
14. Sheth VM, Pandya AG. Melasma: A comprehensive update: Part II. *J Am Acad Dermatol* 2011;65:699-714.
15. Lawrence N, Cox SE, Brody HJ. Treatment of melasma with Jessner's solution versus glycolic acid: A comparison of clinical efficacy and evaluation of the predictive ability of Wood's light examination. *J Am Acad Dermatol* 1997;36:589-93.
16. Cotellessa C, Peris K, Onorati MT, Fargnoli MC, Chimenti S. The use of chemical peelings in the treatment of different cutaneous hyperpigmentations. *Dermatol Surg* 1999;25:450-4.
17. Javaheri SM, Handa S, Kaur I, Kumar B. Safety and efficacy of

- glycolic acid facial peel in Indian women with melasma. *Int J Dermatol* 2001;40:354-7.
18. Lim JT, Tham SN. Glycolic acid peels in the treatment of melasma among Asian women. *Dermatol Surg* 1997;23:177-9.
 19. Hurley ME, Guevara IL, Gonzales RM, Pandya AG. Efficacy of glycolic acid peels in the treatment of melasma. *Arch Dermatol* 2002;138:1578-82.
 20. Garcia A, Fulton JE Jr. The combination of glycolic acid and hydroquinone or kojic acid for the treatment of melasma and related conditions. *Dermatol Surg* 1996;22:443-7.
 21. Lim JT. Treatment of melasma using kojic acid in a gel containing hydroquinone and glycolic acid. *Dermatol Surg* 1999;25:282-4.
 22. Gupta RR, Mahajan BB, Garg G. Chemical peeling – Evaluation of glycolic acid in varying concentrations and time intervals. *Indian J Dermatol Venereol Leprol* 2001;67:28-9.
 23. Erbil H, Sezer E, Taştan B, Arca E, Kurumlu Z. Efficacy and safety of serial glycolic acid peels and a topical regimen in the treatment of recalcitrant melasma. *J Dermatol* 2007;34:25-30.
 24. Lynde CB, Kraft JN, Lynde CW. Topical treatments for melasma and postinflammatory hyperpigmentation. *Skin Ther Lett* 2006;11:1-6.
 25. Johnston GA, Sviland L, McLelland J. Melasma of the arms associated with hormone replacement therapy. *Br J Dermatol* 1998;139:932.