


## Immune thrombocytopenic purpura

Abir Zainal, Amr Salama and Richard Alweis 

Department of Medicine, Unity Hospital, Rochester Regional Health, Rochester, NY, USA

### ABSTRACT

Immune thrombocytopenic purpura (ITP) is a bleeding disorder characterized by isolated thrombocytopenia (platelet count  $<150,000$  u/L), which is not associated with a systemic illness. ITP is reported in approximately 2 per 100,000 adults. The mean age of diagnosis is 50 years. ITP is more common in females of childbearing age and in pregnancy. In adults, the course is more chronic although spontaneous remission can also occur within months of initial diagnosis. A thorough and timely workup of thrombocytopenia is imperative to rule out other differentials of ITP as it is considered a diagnosis of exclusion. Primary care physicians encounter patients who exhibit signs of thrombocytopenia such as petechiae or purpura on a regular basis. A high index of clinical suspicion is required to accurately diagnose ITP and commence the appropriate treatment including glucocorticoids to increase the chances of a favorable prognosis as described by the authors.

### ARTICLE HISTORY

Received 5 November 2018  
Accepted 28 December 2018

### KEYWORDS

Immune thrombocytopenic purpura; hematology; platelets; corticosteroids

## 1. Introduction

Immune thrombocytopenic purpura (ITP) is a bleeding disorder characterized by isolated thrombocytopenia (platelet count  $<150,000$  u/L), which is not associated with a systemic illness. ITP is reported in approximately 2 per 100,000 adults with a mean age of diagnosis of 50 years [1]. ITP is more common in females of childbearing age and in pregnancy [2]. Prognosis is good in children, with most achieving remission [1]. In adults, the course is more chronic although spontaneous remission can also occur. This would usually happen within months of initial diagnosis. Mortality is higher in older patients and those who do not respond to initial therapy.

## 2. Pathophysiology

Although the pathogenesis is still unclear, ITP is believed to result from the development of an immunoglobulin G autoantibody targeting structural platelet membrane glycoproteins IIb-IIIa [3]. This renders platelets susceptible to phagocytosis by splenic macrophages and Kupffer cells in the liver. These autoantibodies are detected in 40–60% of individuals [4]. Thus, other mechanisms including impaired production of the glycoprotein hormone thrombopoietin, a stimulant for platelet production as well as triggers such as childhood exposure to viruses, helicobacter pylori infection and pregnancy are thought to contribute to ITP [5,6].

## 3. Diagnosis

### 3.1. Clinical signs

An initial suspicion of ITP and classification of its severity can be formed by examining a patient's skin and mucous membranes and enquiring about their tendency to bleed or bruise with minimal trauma. Mucocutaneous bleeding occurs as a consequence of a primary hemostasis defect versus a secondary hemostasis defect and deeper organ bleeding which occur more commonly in other coagulopathies. Clinical manifestations include petechiae, purpura and ecchymosis that occur primarily in the upper and lower extremities (Figure 1). Petechiae can also occur in mucosal membranes including the hard palate, nasal septum or gums leading to nose and gum bleeds. Menorrhagia can be seen in females. Platelet counts  $<10,000$  u/L can be associated with spontaneous widespread hematomas [7]. Fatal complications including intracerebral hemorrhage or overt gastrointestinal bleeding are less common.

### 3.2. Differential diagnosis

The differential diagnosis includes thrombotic thrombocytopenic purpura, hemolytic uremic syndrome, disseminated intravascular coagulation, paroxysmal nocturnal hemoglobinuria, myelodysplastic syndrome, lymphoproliferative disorders, infection (HIV, Hepatitis C), and drug-induced thrombocytopenia (alcohol, heparin, sulfonamides).

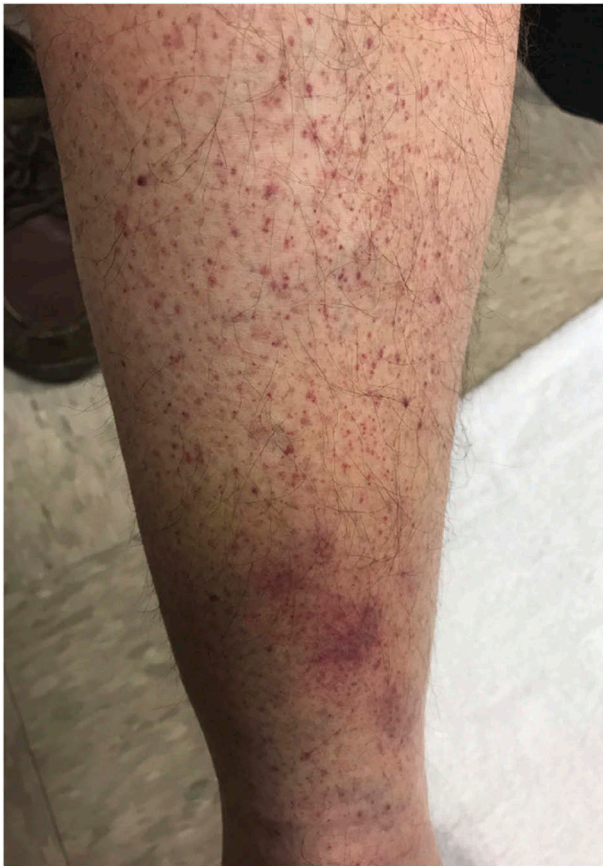

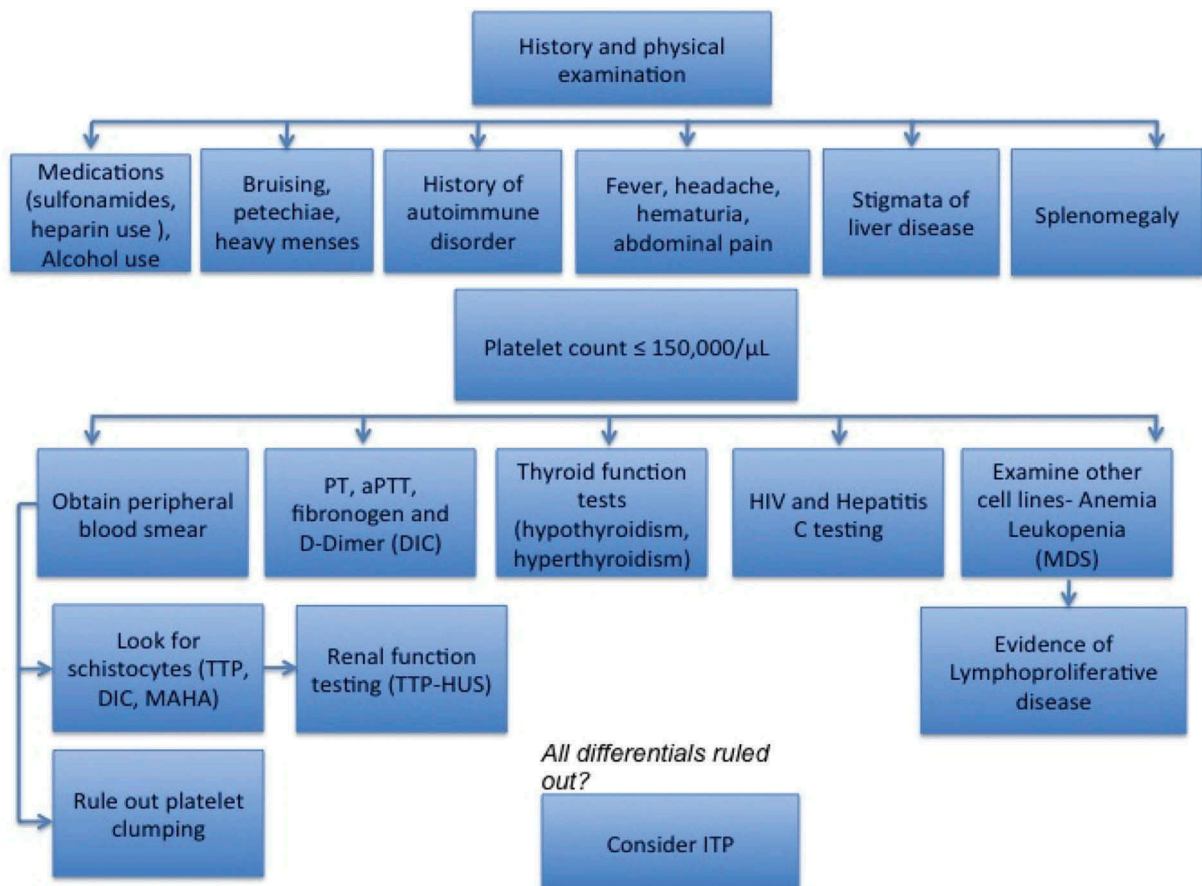
Figure 1. Petechial rash and ecchymosis.

### 3.3. Investigations

In patients with ITP, isolated thrombocytopenia with normal hemoglobin and leukocyte count are evident, unless bleeding has occurred. ITP is a diagnosis of exclusion, therefore it is imperative to rule out other causes of isolated thrombocytopenia. Typically, coagulation studies, HIV and Hepatitis C testing and a peripheral blood smear are essential investigations [8]. Peripheral blood smear can show enlarged platelets without schistocytes. Bone marrow aspiration is rarely required and reserved for patients whom the diagnosis is uncertain; who are not responding to standard therapies or if the blood smear shows abnormalities aside from thrombocytopenia [8]. The measurement of platelet-associated antibodies is not helpful as this testing lacks both sensitivity and specificity.

### 4. Treatment

When platelet counts drop below 30,000/uL without active bleeding clinical observation is indicated. When significant bleeding occurs treatment is initiated. Glucocorticoids are first line therapy such as Prednisone 1 mg/kg po once/day with a slow taper [8]. Second line therapies include



An approach to the workup of thrombocytopenia

PT- prothrombin, aPTT- activated partial thromboplastin time, DIC- disseminated intravascular coagulation, TTP- thrombotic thrombocytopenic purpura, HUS- hemolytic uremic syndrome, MAHA- microangiopathic hemolytic anemia, MDS- myelodysplastic syndrome, ITP

Rituximab (375 mg/m<sup>2</sup> IV once/week for one month) or in refractory cases, thrombopoietin-like agents such as Eltrombopag (25–75 mg once/day) or Romiplostim (1–10 mcg/kg once/week) are indicated [7]. Splenectomy can achieve complete remission in two thirds of patients however can increase the risk of thrombosis and infection with encapsulated bacteria. As such, vaccination against *Streptococcus pneumoniae*, *Haemophilus influenzae type B* and *Neisseria meningitidis* is indicated [8].

Intravenous immunoglobulin (IVIG) and anti D immunoglobulin (IG) are indicated for glucocorticoid-resistant ITP or for management of severe bleeding. In patients who are actively bleeding or in those with platelet counts <10,000 rapid phagocytic blockade through IVIG (1 g/kg once/day for 1–2 days) is attempted and IV anti-D IG in Rhesus positive patients can be tried [7]. In life threatening bleeds, platelet transfusion can also be initiated which otherwise would normally be ineffective due to rapid consumption.

## 5. Conclusion

Clinical symptoms and signs to suggest thrombocytopenia can be commonly encountered in primary care offices. Signs of thrombocytopenia such as petechia and purpura are a common presentation to primary care. Thrombocytopenia should be reflexive in a differential and if established, it is imperative to rule out other systemic illnesses and medications associated with thrombocytopenia as listed above to avoid devastating complications.

## Disclosure statement

No potential conflict of interest was reported by the authors.

## ORCID

Richard Alweis  <http://orcid.org/0000-0002-4747-8066>

## References

- [1] Michel M. Immune thrombocytopenic purpura: epidemiology and implications for patients. *Eur J Haematol.* 2009;82(s71):3–7.
- [2] Provan D, Newland AC. Current management of primary immune thrombocytopenia. *Adv Ther.* 2015;32(10):875–887.
- [3] Stasi R, Newland AC. ITP: a historical perspective. *Br J Haematol.* 2011;153(4):437–450.
- [4] Nazy I, Moore JC, Clare R, et al. Autoantibodies to thrombopoietin and the thrombopoietin receptor in patients with immune thrombocytopenia. *Blood.* 2016;128(22):2548.
- [5] Imbach P, Crowther M. Thrombopoietin-receptor agonists for primary immune thrombocytopenia. *N Engl J Med.* 2011;365(8):734–741.
- [6] Frydman GH, Davis N, Beck PL, et al. *Helicobacter pylori* eradication in patients with immune thrombocytopenic purpura: a review and the role of biogeography. *Helicobacter.* 2015;20(4):239–251.
- [7] Bohn JP, Steurer M. Current and evolving treatment strategies in adult immune thrombocytopenia. *Memo.* 2018;11(3):241–246.
- [8] Matzdorff A, Meyer O, Ostermann H, et al. Immune thrombocytopenia - current diagnostics and therapy: recommendations of a joint working group of DGHO, OGHO, SGH, GPOH, and DGTI. *Oncol Res Treat.* 2018;41(Suppl 5):1–30.