

# Surgically Assisted Rapid Palatal Expansion to Correct Maxillary Transverse Deficiency

Adi Rachmiel<sup>1,2</sup>, Shahar Turgeman<sup>1</sup>, Dekel Shilo<sup>1,2</sup>, Omri Emodi<sup>1</sup>, Dror Aizenbud<sup>3</sup>

Departments of <sup>1</sup>Oral and Maxillofacial Surgery and <sup>3</sup>Orthodontics and Craniofacial Anomalies, Rambam Health Care Campus, <sup>2</sup>Academic Institution, Bruce Rappaport Faculty of Medicine, Technion – Israel Institute of Technology, Haifa, Israel

## Abstract

**Background:** Transverse maxillomandibular discrepancies are widespread. Treatment is comprised of orthodontic expansion in patients younger than 15 years or by surgically assisted rapid palatal expansion (SARPE) in skeletally mature patients where the possibility of successful orthodontic maxillary expansion decreases as sutures close and resistance to mechanical forces increases. **Aim:** To present our experience of treating transverse maxillary deficiency using a unique L-shaped osteotomy and to demonstrate stable results. **Patients and Methods:** 32 patients aged between 19 and 54 years exhibiting transverse maxillary deficiency. L-shaped osteotomy was performed laterally from the pterygoid plate posteriorly to above the roots of the second incisor anteriorly continuing with a vertical osteotomy between the lateral incisor and canine teeth toward the horizontal osteotomy. In 18 patients with dysgnathia, bimaxillary surgery was performed one year following the SARPE procedure. **Results:** Mean transverse maxillary expansion of 6.2mm at the canine incisal and 6.4mm at the first molar occlusal regions were obtained. One year postoperatively results were relatively stable, 5.8mm and 6.2mm respectively. The SARPE procedure resulted in overcoming the maxillary buttress resistance, expansion of the anterior dental arch and bilateral distraction creating bone on both sides of the premaxilla contributing to better alignment of the anterior teeth and superior stability. **Conclusions:** We conclude that SARPE is an effective and stable method for addressing severe maxillary transverse discrepancy in adults while the unique osteotomy performed allowed for maintaining proper position of the premaxilla and maxillary midline and allowing for division of the newly created bone bilaterally thus resulting in a more stable outcome.

**Keywords:** Maxillary distraction osteogenesis, maxillary transverse deficiency, surgically assisted rapid palatal expansion

## INTRODUCTION

Maxillary deficiency and accompanying crossbite is a common malocclusion encountered clinically with a prevalence of 4%–23%.<sup>[1]</sup> Maxillary transverse deficiency (MTD) can be treated either orthodontically using rapid maxillary expansion (RME) or surgically using surgically assisted rapid palatal expansion (SARPE). In children and adolescents, conventional orthodontic RME has been successful when used prior to sutural closure.<sup>[2-6]</sup> In skeletally mature patients, the possibility of successful maxillary expansion decreases as sutures close and resistance to mechanical forces increases.<sup>[2,4,6]</sup> SARPE is an effective method of addressing the severe maxillary transverse discrepancy in patients over the age of 15 years. In young adults and adults in their 20s and 30s, palatal expansion may result in the tipping of the molars with little expansion of the maxillary arch. It has also been suggested that the intermaxillary suture

anterior to the incisive canal never ossifies until very late in life, resulting in some relapse.<sup>[7-9]</sup> A number of modifications for the traditional SARPE surgical technique have been described. The traditional method describes a midpalatal osteotomy between the two central incisors, followed by maxillary expansion using a tooth- or bone-borne device.<sup>[5]</sup>

Various combinations of maxillary, pterygopalatine lateral nasal, septal, and palatine osteotomies have been used based

**Address for correspondence:** Dr. Shahar Turgeman,  
Department of Oral and Maxillofacial Surgery, Rambam Health Care  
Campus, POB 9602, Haifa 31096, Israel.  
E-mail: turgemanshahar@gmail.com

Received: 20-07-2019

Published: 08-06-2020

Accepted: 03-12-2019

This is an open access journal, and articles are distributed under the terms of the Creative Commons Attribution-NonCommercial-ShareAlike 4.0 License, which allows others to remix, tweak, and build upon the work non-commercially, as long as appropriate credit is given and the new creations are licensed under the identical terms.

**For reprints contact:** WKHLRPMedknow\_reprints@wolterskluwer.com

**How to cite this article:** Rachmiel A, Turgeman S, Shilo D, Emodi O, Aizenbud D. Surgically assisted rapid palatal expansion to correct maxillary transverse deficiency. *Ann Maxillofac Surg* 2020;10:136-41.

### Access this article online

Quick Response Code:



Website:  
www.amsjournal.com

DOI:  
10.4103/ams.ams\_163\_19

on different theories regarding the location of resistance to expansion.<sup>[10,11]</sup> Some of the initial reports indicated that the zygomatic buttress and pterygomaxillary junction are the main areas of resistance,<sup>[12-14]</sup> and some reports have recommended the sectioning of almost all articulating maxillary structures.<sup>[15-17]</sup>

In this report, we present a novel surgical technique for the treatment of MTD. We use a bilateral transverse L-shaped maxillary osteotomy followed by tooth-borne Hyrax® device for palatal expansion in skeletally mature patients. We present the technique, our experience, and the reason for choosing this technique over the conventional surgical procedure described in the literature.

## MATERIALS AND METHODS

A total of 32 patients, 17 males and 15 females, aged between 19 and 54 years were treated using a bilateral transverse L-shaped maxillary osteotomy followed by palatal expansion using a tooth-borne Hyrax® device. The inclusion criteria in this work were all patients aged 15 years or more who reached their skeletal maturity, exhibiting MTD (hypoplasia), which can be associated with another skeletal dysgnathia such as retruded maxilla or open bite and treated using the bilateral transverse L-shaped maxillary osteotomy. The transversal hypoplasia could not be corrected by orthodontic treatment

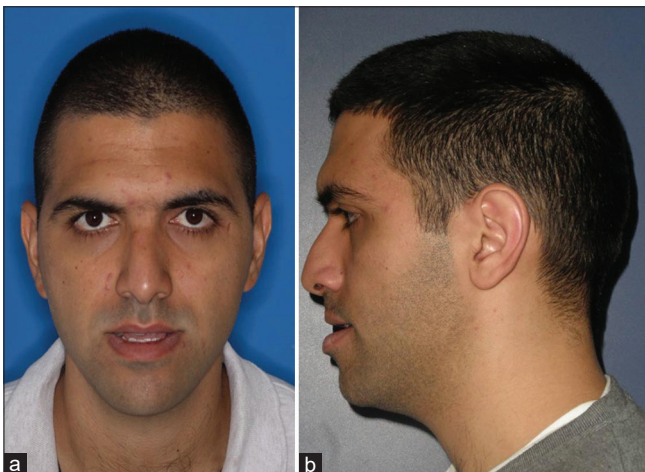alone due to the full skeletal maturation. Exclusion criteria included syndromic patients and cleft palate patients.

All patients included had bilateral transverse posterior crossbite, high and narrow palatal vault, and dental crowding [Figures 1 and 2]. All impacted or ectopic third molar teeth were extracted prior to the surgical intervention. Eighteen patients presented with maxillary retrusion and ten of them also exhibited an anterior open bite which was associated with mandibular prognathism. Patients presented with an anterior open bite exhibited two planes of occlusion in the sagittal plane. Generally, in this study, SARPE preceded the orthodontic leveling. The eighteen dysgnathic patients underwent an additional bimaxillary orthognathic surgery, 1 year following the SARPE procedure and completion of the orthodontic preparation. Bimaxillary orthognathic surgeries included the Le Fort I maxillary osteotomy and bilateral sagittal split mandibular osteotomy.

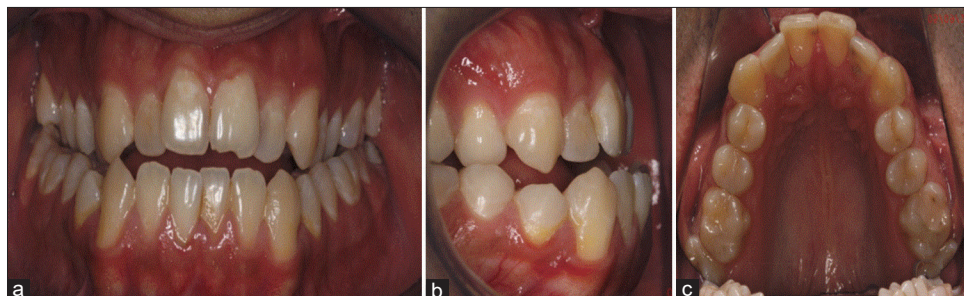
### Surgical technique

Hyrax® device was bonded by the orthodontist prior to the surgery [Figure 3]. Twenty-six SARPE surgeries were performed under deep sedation with the administration of local anesthesia, while the remaining six patients underwent the procedure under general anesthesia with nasotracheal intubation.

Horizontal incisions were made in the maxillary vestibule above the attached mucosa, between the lateral incisor anteriorly and the second molar region posteriorly on both sides, followed by an exposure of the lateral walls of the maxilla [Figure 4]. Subsequently, a sulcular incision was made between the central incisor and the first premolar teeth. Using fine periosteal elevators, the gingival mucoperiosteal flaps were reflected carefully over the relevant teeth to allow the proper surgical visibility and access to perform a vertical osteotomy between the second incisor and canine teeth, avoiding damage to the integrity of the elevated crestal part of the mucoperiosteal flap. Using a reciprocating saw, a horizontal maxillary osteotomy on the lateral wall of the maxilla was performed at least 5 mm above the apex of the teeth from the pterygoid plate posteriorly toward and above the apex of the canine anteriorly. Great care was taken not to damage the canine apex which is higher than the other teeth. While protecting



**Figure 1:** A 21-year old patient with maxillary transverse deficiency presenting with associated retruded maxilla and anterior open bite. Clinical photo frontal view (a) and profile view (b)



**Figure 2:** Intraoral photos of the patient are described in Figure 1. Anterior (a), lateral (b), and occlusal (c) views demonstrate the maxillary transverse deficiency



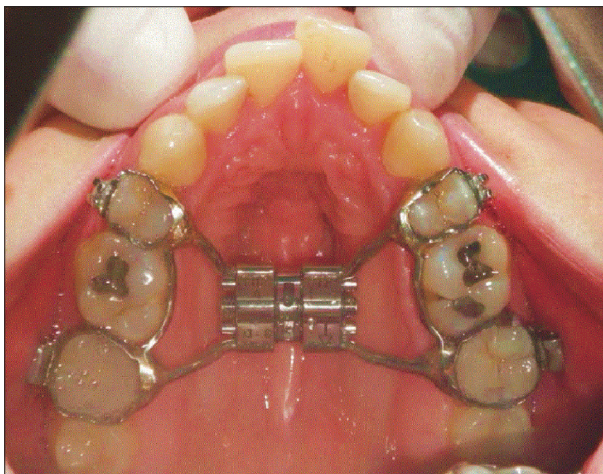the previously reflected mucogingival flap and using a reciprocating saw, a vertical osteotomy starting from the alveolar crest was performed between the lateral incisor and canine teeth toward the horizontal osteotomy on both the sides. To complete the vertical osteotomy, a fine osteotome was introduced and a manual pressure was applied until the slight movement of the lateral maxillary segments on both the sides was created. The pterygomaxillary suture was osteotomized by a curved osteotome.

Activation of the Hyrax® device was initiated on the first postoperative day by turning the device twice a day at a rate of 0.5 mm [Figure 5]. Dental casts and preoperative panoramic X-ray as well as lateral and posteroanterior cephalograms were taken before the treatment (T1), after the palatal distraction phase (T2), and at 12-month postoperative (T3).

The palatal expansion was measured on dental casts at all three periods (T1, T2, and T3) using four points of reference: canine incisal (Ci), canine gingival (Cg), molar occlusal (Mo), and molar gingival (Mg). Clinically, patients were evaluated intra- and postoperatively for dysesthesia of the infraorbital nerve, loss of teeth associated to the procedure, loss of sensation in the maxillary teeth, infection, bleeding, mechanical issues during expansion, unintended early ossification, and dehiscence of soft and bony tissue.

## RESULTS

During device activation and while the two lateral maxillary segments were apart, a gap was opened between the second incisor and the canine teeth bilaterally until the transverse deficiency was corrected. Subsequently, orthodontic alignment of the teeth was performed by the orthodontist [Figure 6]. Postoperative dental models demonstrated the palatal expansion at Ci, Cg, Mo, and Mg [Table 1]. The mean

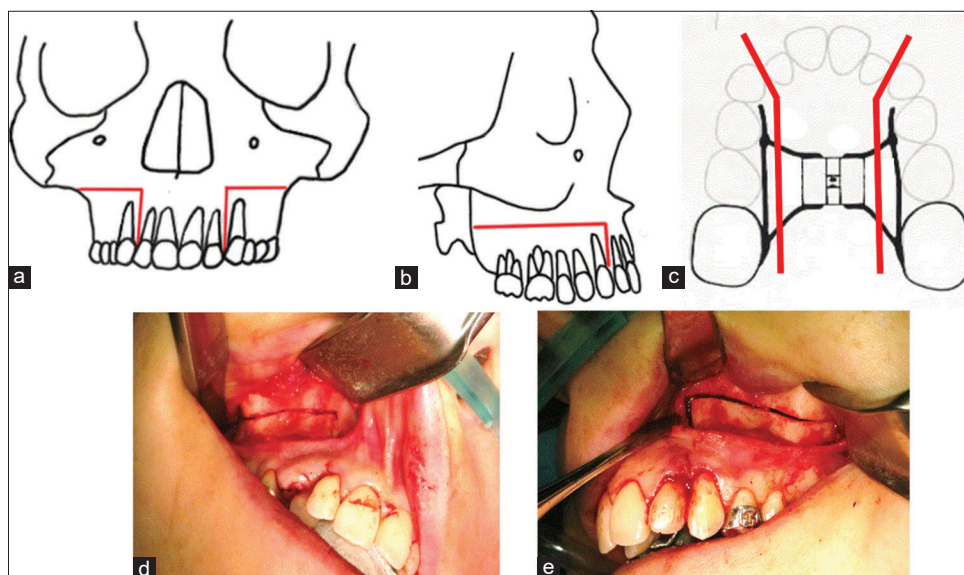


**Figure 3:** The tooth-borne Hyrax® device postoperative and before activation

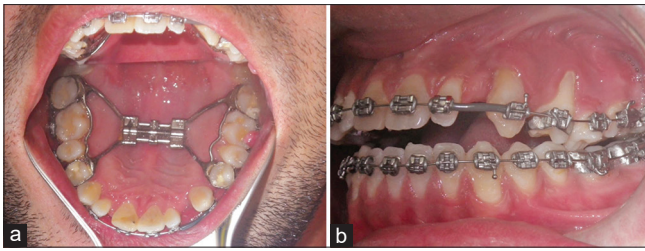
**Table 1: Maxillary palatal expansion measured on dental models at the end of expansion and orthodontic alignment and 1 year later at canine incisal, canine gingival, molar occlusal, and molar gingival regions**

	mm ± SD (range)	
	Mean expansion	Mean expansion after 1 year
Ci	6.2±0.2 (5.8-6.6)	5.8±0.2 (5.5-6.1)
Cg	5.9±0.2 (5.4-6.4)	5.8±0.2 (5.3-6.1)
Mo	6.4±0.3 (5.9-6.9)	6.2±0.2 (5.8-6.5)
Mg	6.1±0.2 (5.8-6.4)	6.0±0.2 (5.7-6.3)

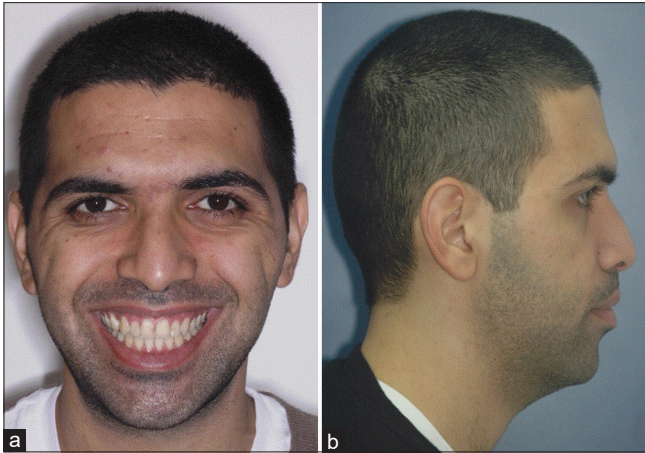SD: Standard deviation, Ci: Canine incisal, Cg: Canine gingival, Mo: Molar occlusal, Mg: Molar gingival



**Figure 4:** Anteroposterior (a), lateral (b), and occlusal (c) illustrations of the bilateral transverse L-shaped maxillary osteotomy comprising a lateral horizontal maxillary osteotomy from the pterygoid plates posteriorly to above the roots of the second incisor anteriorly and a vertical osteotomy between the lateral incisor and canine teeth toward the horizontal osteotomy. Clinical intraoperative photos of the transverse L shape maxillary osteotomy (d and e)



**Figure 5:** Palatal expansion in the same patient described in Figure 1 can be observed by the gap created between the lateral incisor and the canine. (a) Occlusal view (b) Lateral view



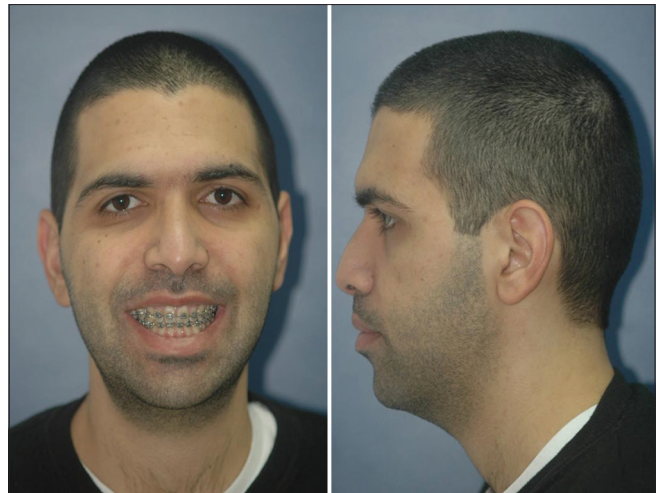
**Figure 7:** The same patient described before following the surgically assisted rapid palatal expansion procedure and a maxillary Le Fort I and sagittal split osteotomy of the mandible to advance the maxilla and close the open bite. Frontal (a) and profile (b) views

transverse maxillary expansion measured was 6.2 mm at the Ci and 6.4 mm at the first Mo [Table 1].

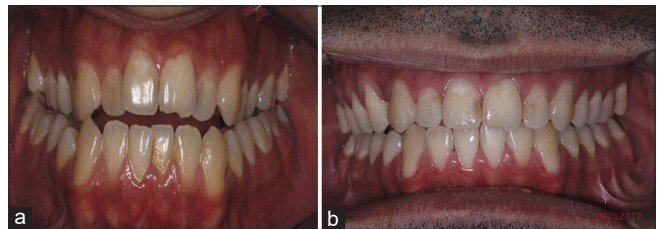
The bilateral osteotomies allowed for splitting of the distraction length into two different distraction sites. This allowed for a smaller strain on the maxillary buttresses. In all patients, the premaxilla and thus the maxillary midline remained in its original position owing to the bilateral osteotomies lateral to the second maxillary incisors. One-year follow-up demonstrated stable results in all patients with only 0.4 mm and 0.2 mm in Ci and Mo, respectively.

Cases which exhibited two planes of occlusion prior to the SARPE procedure achieved one occlusal plane following the palatal enlargement and dental alignment, which contributed to the postoperative stability.

Although the two vertical osteotomies were performed without preorthodontic tooth movement in all 32 patients (64 sides), there was no damage to the tooth roots and no loss of tooth sensation either in the lateral incisive or canine teeth. In 3 of the 64 sides, there was damage to the integrity of the muco-gingivo periosteal flap over the vertical osteotomy resulting in two patients with a gingival recession in the canine teeth and one patient with alveolar bone exposure that required further debridement and mucosal graft for proper healing. The



**Figure 6:** Orthodontic treatment following surgically assisted rapid palatal expansion in the same patient described before. Clinical photo frontal and profile view



**Figure 8:** Intraoral anterior photos of the patient described before. Prior to the surgically assisted rapid palatal expansion (a) and postsurgically assisted rapid palatal expansion and orthognathic surgery (b)

18 patients with dysgnathia underwent bimaxillary surgery 1 year following the leveling and stabilization of the occlusion and achieved normognathic relations and stable skeletal and dental results [Figures 7 and 8].

## DISCUSSION

Treatment of MTD can be performed by orthodontic expansion in patients younger than 15 years or by SARPE in skeletally mature patients.<sup>[2-6]</sup> SARPE has gradually gained popularity as a treatment option to correct MTD. It allows clinicians to achieve effective maxillary expansion in skeletally mature patients.

The maxillary osteotomy used in SARPE can overcome the resistance of ossified sutures.<sup>[17-21]</sup> The indication of SARPE includes adult patients, where marked sutural expansion is not possible, and patients which exhibited transverse relapse following rapid palatal expansion. Suri and Taneja<sup>[6]</sup> proposed that the correction of MTD in skeletally mature patients is more challenging due to changes in the osseous articulations of the maxilla with the adjoining bones and areas of major resistance.

Various combinations of midmaxillary, pterygopalatine, lateral nasal, septal, and palatine osteotomies have been used based on different theories regarding the locations of resistance to



expansion.<sup>[10-14]</sup> The major resistance of transverse palatal expansion is the zygomaticomaxillary buttresses.<sup>[6,12,14,18]</sup> Sectioning of almost all articulating maxillary structures is recommended to address all sites of resistance.<sup>[15-17]</sup> Therefore, in adult patients due to significant sutural ossification and maturation of the facial skeleton, we performed surgical sectioning of the two lateral zygomaticomaxillary buttresses which allowed the lateral expansion to overcome the resistance. It is necessary to make sure that the buccal osteotomy did not interfere with the apices of the dentition and did not damage the infraorbital nerve.

Several studies linked the relative postoperative instability after transversal expansion using midpalatal osteotomy to the low bone contacts and less bone generation along the suture.<sup>[22,23]</sup> In the present work in addition to the two horizontal osteotomies at the zygomaticomaxillary buttresses, we used two vertical osteotomies laterally to the midpalatal suture to enhance the amount of bone contacts being used during the palatal expansion. We achieved a mean transverse maxillary expansion of 6.2 mm at the canines and 6.4 mm at the first Mo. During lateral distraction and expansion of the palate, the premaxilla remains stable while the anterior dental arch increases by the newly bone generated on both sides of the maxilla. Using this method of bilateral maxillary arch expansion, the major strain created from the zygomaticomaxillary buttresses is controlled bilaterally leading to a greater stability and reduced relapse. We demonstrated maximum relapse rates of 0.4 mm and 0.2 mm at Ci and Mo, respectively.

According to the distraction osteogenesis literature, a greater skeletal advancement demonstrates higher relapse rates than those of short distance of elongation.<sup>[24]</sup>

Our method allows for splitting of the distraction length in two, thus allowing for superior stability due to shorter lengths of elongation. In mild cases, it is not necessary to fracture the pterygoid plates. However, in severe cases which may need marked lateral expansion at the molar region, this fracture should be performed. After the planned bony and dental arch expansion was achieved, orthodontic dental alignment was performed. The creation of a bilateral space between the second incisors and canine teeth allows symmetric alignment of teeth superior to that of a single midline osteotomy.

Distraction at two sites may result in better skeletal arch expansion and stability which may contribute to dental alignment. In patients with a narrow maxilla, the impacted or ectopic upper third molars should be extracted prior to the osteotomy.

In the present article, the preferred option was to perform the vertical osteotomies on both sides between the lateral incisors and canine teeth without damaging the tooth apices and roots. The overlying mucosa and periosteum should bridge the vertical osteotomy for proper healing. Rupture of the muco-gingivo periosteal bridge may result in unesthetic healing of the gingiva around the osteotomy and improper

ossification between the lateral incisors and canine teeth that may affect the bony distraction and later the tooth alignment. Therefore, this osteotomy is initiated using a tracing corticotomy with a fine burr followed by vertical osteotomy with a small reciprocating saw between the roots to cut the bony ridge from the papilla area toward the lateral maxillary osteotomy. Next, an osteotome is placed to separate the lateral bone segments. It is not necessary to perform palatal access for palatal osteotomy. Two of 64 sides resulted in root dehiscence due to partial mucosal rupture during the bony vertical osteotomy, and in another case, there was alveolar bone exposure that required further correction.

The operation can be performed also unilaterally in cases of unilateral transverse deficiency as in unilateral cleft palate patients. In cleft patients, the procedure should be performed only on patients that were previously bone grafted and thus acquired continuous dental arch and bony alveolus.

Another option to expand transversely the maxilla is to perform a Le Fort I osteotomy and segmentalization.<sup>[25]</sup> The disadvantages of this method are the need to extract teeth at the osteotomy site, the need for bone graft between the osteotomized segments, less stability of the osteotomized segments, transverse relapse, which may result in postoperative open bite and improper occlusion, and the need for postoperative orthodontic treatment for leveling and closing of the sites of extraction.<sup>[26-27]</sup> The use of SARPE has the advantages of a relatively simple procedure followed by gradual transverse distraction and bone generation at the distraction sites which prevents the relapse. It is safer and more predictable to begin with expansion of the adult maxillary palate prior to dental alignment and finally perform the maxillary Le Fort I orthognathic surgery achieving a stable occlusion, as opposed to performing a Le Fort I osteotomy with segmentalization (3-piece maxilla) which may result in less postoperative stability<sup>[25-27]</sup> and periodontal defects or tooth extraction for the vertical osteotomy. The presented procedure does not require tooth extraction at the osteotomy site.

In some of our patients (18 of 32 cases), SARPE was the first stage prior to orthognathic surgery which was performed following completion of the arch expansion and orthodontic alignment. Performing the orthognathic bimaxillary surgery 1 year following the palatal expansion and orthodontic treatment has the advantage of operating after stabilization of the two occlusal planes which contribute to long-term stability.

It is known that patients with transverse maxillary constriction may benefit from the expansion of the nasal base. SARPE increases the nasal and maxillary width and improves nasal breathing.<sup>[24,28-30]</sup>

Summary of the advantages in the bilateral transverse L-shaped maxillary osteotomy method for SARPE is as follows:

1. Two sites of palatal expansion with bone generation between the lateral and canine teeth contribute to a better stability

2. Esthetic consequences of maxillary diastema are avoided since the osteotomy is being performed laterally to the midline, therefore allowing a more symmetric expansion
3. The premaxilla area including the midpalatal septum is left unattached, avoiding the risk of damaging blood supply and innervation of an incisive canal through the osteotomy
4. SARPE can be the first surgical orthodontic phase in the treatment of adult patients with dysgnathia that also had a MTD. This treatment is optimally carried out in two phases: SARPE followed by orthognathic surgery.

## CONCLUSION

The bilateral transverse L-shaped osteotomy is indicated for MTD. Midpalatal osteotomy is avoided and the bilateral bony maxillary arch expansion overcomes the resistance of maxillary buttresses, with two-site distraction and bone generation contributing to better stability. This procedure may be the first surgical orthodontic phase prior to orthognathic surgery.

## Consent

Written patient consent has been obtained to publish clinical photographs.

## Financial support and sponsorship

Nil.

## Conflicts of interest

There are no conflicts of interest.

## REFERENCES

1. Thilander B, Lennartsson B. A study of children with unilateral posterior crossbite, treated and untreated, in the deciduous dentition-occlusal and skeletal characteristics of significance in predicting the long-term outcome. *J Orofac Orthop* 2002;63:371-83.
2. Banning LM, Gerard N, Steinberg BJ, Bogdanoff E. Treatment of transverse maxillary deficiency with emphasis on surgically assisted-rapid maxillary expansion. *Compend Contin Educ Dent* 1996;17:170, 174-8.
3. Bell RA. A review of maxillary expansion in relation to rate of expansion and patient's age. *Am J Orthod* 1982;81:32-7.
4. Chrcanovic BR, Custodio AL. Orthodontic or surgically assisted rapid maxillary expansion. *Oral Maxillofac Surg* 2009;13:123-37.
5. Glassman AS, Nahigian SJ, Medway JM, Aronowitz HI. Conservative surgical orthodontic adult rapid palatal expansion: Sixteen cases. *Am J Orthod* 1984;86:207-13.
6. Suri L, Taneja P. Surgically assisted rapid palatal expansion: A literature review. *Am J Orthod Dentofacial Orthop* 2008;133:290-302.
7. Anttila A, Finne K, Keski-Nisula K, Somppi M, Panula K, Peltomäki T. Feasibility and long-term stability of surgically assisted rapid maxillary expansion with lateral osteotomy. *Eur J Orthod* 2004;26:391-5.
8. Cureton SL, Cuenin M. Surgically assisted rapid palatal expansion: Orthodontic preparation for clinical success. *Am J Orthod Dentofacial Orthop* 1999;116:46-59.
9. Strömberg C, Holm J. Surgically assisted, rapid maxillary expansion in adults. A retrospective long-term follow-up study. *J Craniomaxillofac Surg* 1995;23:222-7.
10. Kilic E, Kilic B, Kurt G, Sakin C, Alkan A. Effects of surgically assisted rapid palatal expansion with and without pterygomaxillary disjunction on dental and skeletal structures: A retrospective review. *Oral Surg Oral Med Oral Pathol Oral Radiol* 2013;115:167-74.
11. Laudemann K, Santo G, Revilla C, Harth M, Kopp S, Sader RA, *et al.* Assessment of surgically assisted rapid maxillary expansion regarding pterygomaxillary disjunction using thin volume-rendering technique: In variance analysis and in reliability, accuracy, and validity. *J Oral Maxillofac Surg* 2011;69:2631-43.
12. Barber AF, Sims MR. Rapid maxillary expansion and external root resorption in man: A scanning electron microscope study. *Am J Orthod* 1981;79:630-52.
13. Holberg C, Steinhäuser S, Rudzki I. Surgically assisted rapid maxillary expansion: Midfacial and cranial stress distribution. *Am J Orthod Dentofacial Orthop* 2007;132:776-82.
14. Timms DJ, Moss JP. An histological investigation into the effects of rapid maxillary expansion on the teeth and their supporting tissues. *Trans Eur Orthod Soc* 1971:263-71.
15. Bell WH, Epker BN. Surgical-orthodontic expansion of the maxilla. *Am J Orthod* 1976;70:517-28.
16. Kraut RA. Surgically assisted rapid maxillary expansion by opening the midpalatal suture. *J Oral Maxillofac Surg* 1984;42:651-5.
17. Turvey TA. Maxillary expansion: A surgical technique based on surgical-orthodontic treatment objectives and anatomical considerations. *J Maxillofac Surg* 1985;13:51-8.
18. Matteini C, Mommaerts MY. Posterior transpalatal distraction with pterygoid disjunction: A short-term model study. *Am J Orthod Dentofacial Orthop* 2001;120:498-502.
19. Mommaerts MY. Transpalatal distraction as a method of maxillary expansion. *Br J Oral Maxillofac Surg* 1999;37:268-72.
20. Pogrel MA, Kaban LB, Vargervik K, Baumrind S. Surgically assisted rapid maxillary expansion in adults. *Int J Adult Orthodon Orthognath Surg* 1992;7:37-41.1.
21. Shetty V, Caridad JM, Caputo AA, Chaconas SJ. Biomechanical rationale for surgical-orthodontic expansion of the adult maxilla. *J Oral Maxillofac Surg* 1994;52:742-9.
22. Petrick S, Hothan T, Hietschold V, Schneider M, Harzer W, Tausche E. Bone density of the midpalatal suture 7 months after surgically assisted rapid palatal expansion in adults. *Am J Orthod Dentofacial Orthop* 2011;139:S109-16.
23. Sannomiya EK, Macedo MM, Siqueira DF, Goldenberg FC, Bommarito S. Evaluation of optical density of the midpalatal suture 3 months after surgically assisted rapid maxillary expansion. *Dentomaxillofac Radiol* 2007;36:97-101.
24. Neeley WW 2<sup>nd</sup>, Edgin WA, Gonzales DA. A review of the effects of expansion of the nasal base on nasal airflow and resistance. *J Oral Maxillofac Surg* 2007;65:1174-9.
25. Kretschmer WB, Baciut G, Baciut M, Zoder W, Wangerin K. Stability of Le Fort I osteotomy in bimaxillary osteotomies: Single-piece versus 3-piece maxilla. *J Oral Maxillofac Surg* 2010;68:372-80.
26. Baker DL, Stoelinga PJ, Blijdorp PA, Brouns JJ. Long-term stability after inferior maxillary repositioning by miniplate fixation. *Int J Oral Maxillofac Surg* 1992;21:320-6.
27. Chow J, Hägg U, Tideman H. The stability of segmentalized Le Fort I osteotomies with miniplate fixation in patients with maxillary hypoplasia. *J Oral Maxillofac Surg* 1995;53:1407-12.
28. Baratieri C, Alves M Jr., de Souza MM, de Souza Araújo MT, Maia LC. Does rapid maxillary expansion have long-term effects on airway dimensions and breathing? *Am J Orthod Dentofacial Orthop* 2011;140:146-56.
29. Magnusson A, Bjerklin K, Nilsson P, Jönsson F, Marcusson A. Nasal cavity size, airway resistance, and subjective sensation after surgically assisted rapid maxillary expansion: A prospective longitudinal study. *Am J Orthod Dentofacial Orthop* 2011;140:641-51.
30. Oliveira De Felipe NL, Da Silveira AC, Viana G, Kusnoto B, Smith B, Evans CA. Relationship between rapid maxillary expansion and nasal cavity size and airway resistance: Short- and long-term effects. *Am J Orthod Dentofacial Orthop* 2008;134:370-82.