

Received: 2017.05.28
Accepted: 2017.07.07
Published: 2018.01.30

Enhancement of Choriocapillaris Visualization in En Face Swept-Source Optical Coherence Tomography Angiography Images

Authors' Contribution:
Study Design A
Data Collection B
Statistical Analysis C
Data Interpretation D
Manuscript Preparation E
Literature Search F
Funds Collection G

ABCDEF **Maciej Czepita**
A **Damian Czepita**

Private Office, Szczecin, Poland

Corresponding Author: Maciej Czepita, e-mail: maciej@czepita.pl
Source of support: Private sources

Background: Visualization of the choriocapillaris vessels using swept-source optical coherence tomography is a novel technique. However, en face images obtained with current commercial equipment using this method are still unclear. Therefore, using freely available image processing software, we have been able to enhance and clearly visualize single choriocapillaris blood vessels.





Material/Methods: We examined 4 swept-source optical coherence tomography en face images of the choriocapillaris in 2 male patients in both eyes and processed them using Image J software.

Results: In our study, all images displayed clearly individual choriocapillaris vessels.

Conclusions: Implementation of this technique significantly improves visualization of the choriocapillaris. Further studies need to be carried out in order to validate this method of enhancement.

MeSH Keywords: **Choroid • Diagnostic Techniques, Ophthalmological • Image Processing, Computer-Assisted • Tomography, Optical Coherence**

Full-text PDF: <https://www.medscimonit.com/abstract/index/idArt/905534>

 1551  —  4  18



Background

The choriocapillaris is a single layer of vessels lying in a plane internal to the arteries and veins of the choroid and external to Bruch's membrane [1]. It serves multiple functions, including sustaining photoreceptor cells, removing waste products in the outer retina, and in thermoregulation [2]. The capillaries range in diameter from 10 to 50 μm . The vessels of the choriocapillaris appear as a continuous meshwork with the highest density in the posterior pole. Due to the optical filtering properties of the retinal pigment epithelium, the choriocapillaris has been difficult to image *in vivo*. The first direct method of choriocapillaris imaging was through fluorescein angiography developed by Novotny and Alvis in 1959 [3]. Later, indocyanine green angiography was introduced in the 1970s. Finally, with the development of spectral domain optical coherence tomography (SD-OCT), the choroid could be visualized, which was not possible with time-domain optical coherence tomography (TD-OCT). This meant that choroidal vascular patterns and density using reconstructed SD-OCT volume imaging was possible [4]. Unfortunately, segmentation artifacts related to RPE curvature and inadequate resolution were observed when evaluating the choriocapillaris with this method. Through further research, swept-source optical coherence tomography (SS-OCT) was introduced into ophthalmology as a novel imaging modality to supersede spectral domain OCT. The advantage of SS-OCT over SD-OCT is the improved axial resolution and axial scan rates as well as signal-to-noise ratio. This is achieved by using a short cavity-swept laser with a tunable wavelength of operation instead of the diode laser used in spectral domain OCT [5]. SS-OCT operating at 1050 nm wavelength has greater penetration into the choroid than SD-OCT operating at 850 nm. This is due to the fact that absorption of light from melanin the major chromophore in the RPE decreases monotonically with increasing wavelength. Additionally, according to the ANSI standard, the maximum permissible light exposure increases with wavelength and is around 3 times higher at 1050 nm than at 850 nm [6]. Therefore, by using higher-power settings at longer wavelengths, SS-OCT also achieves higher signal sensitivity than SD-OCT. SS-OCT has enabled clearer visualization of the choroid as compared to SD-OCT and easier quantification of its parameters [7,8]. This has led to several studies looking into the choroidal thickness and volume in numerous diseases such as central serous chorioretinopathy (CSCR) [9], age-related macular degeneration (AMD) [10], diabetic retinopathy [11], gestational diabetes mellitus [12], or even following cataract surgery [13].

Currently, there are a number of ophthalmic swept-source OCT systems on the market. Unfortunately, the en face images of the choriocapillaris obtained with these systems are unclear and pixelated, and individual vessels cannot be discerned. Therefore, we decided to develop a technique to enhance the

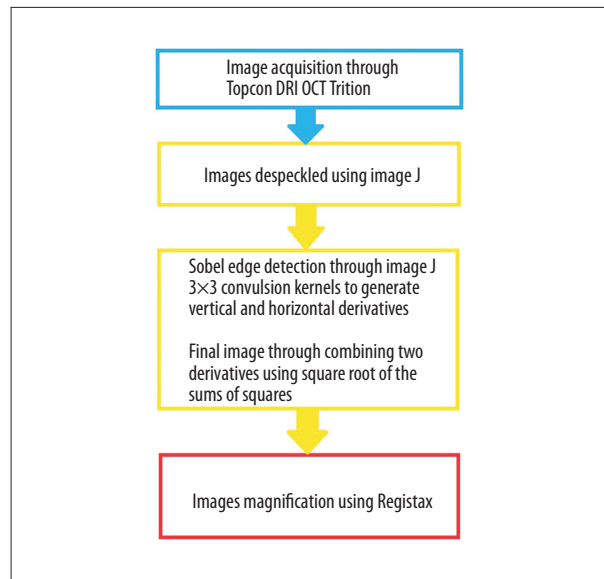


Figure 1. Flow chart of data acquisition and processing.

visualization of the choriocapillaris through computer image processing.

Material and Methods

To conduct this study, we used the DRI OCT Triton (Topcon, Tokyo, Japan). This swept-source OCT system operates using a wavelength of 1050 nm and achieves 100,000 A scans per second. En face images of the choriocapillaris at the fovea were 3×3 mm in size (320×320 pixels) and saved in JPEG format. The 3×3 mm image size was assessed to be the most suitable for our patients. The fovea was our region of interest due to the pathologies involved (CSCR and cone-rod dystrophy). These images were then transferred for further processing to ImageJ software (National Institute of Health, Bethesda, MD) version bundled with 32-bit Java 1.6.0_24. First, the images were despeckled. This is done through a median filter, which replaces each pixel with the median value in its 3×3 neighborhood. Next, a Sobel edge detector was used to highlight sharp changes in intensity. Two 3×3 convolution kernels were used to generate vertical and horizontal derivatives. The final image was produced by combining the 2 derivatives using the square root of the sum of squares. To magnify the image, the zoom mode with the Lanczos filter of RegiStax version 6 (Cor Berrevoets, Netherlands) was used. The flow chart of our data acquisition and processing can be seen in Figure 1.

Two male patients referred to our clinic were selected to undergo swept-source optical coherence tomography angiography (angio OCT) examination using the Topcon DRI OCT Triton in both eyes to aid in the differential diagnosis of their conditions. Our first patient was a 17-year-old male with suspected




Figure 2. The upper 3 images display were obtained from the right eye of patient no. 1. The image on the left is the original choriocapillaris image obtained using the Topcon DRI OCT Triton. The middle image has been processed using ImageJ and magnified 1.2x. The image on the right has been processed using ImageJ and magnified 2x using RegiStax. The lower 3 images display were obtained from the left eye of patient no. 1. The image on the left is the original choriocapillaris image obtained using the Topcon DRI OCT Triton. The middle image has been processed using ImageJ and magnified 1.2x. The image on the right has been processed using ImageJ and magnified 2x using RegiStax.

of cone-rod dystrophy. Uncorrected distance visual acuity was 20/20 in both eyes. He reported nyctalopia since childhood, but his history was otherwise unremarkable. Apart from swept-source optical coherence tomography angiography, color fundus photography (CFP) and short wavelength fundus autofluorescence imaging (FAF) was performed. No abnormalities were found in either the superficial or deep capillary plexus on angio OCT. No visible changes were evident in the original choriocapillaris images in both eyes. Our second patient was a 45-year-old male with presumed past bilateral central serous chorioretinopathy. Uncorrected distance visual acuity was 20/25 in both eyes. He reported having blurry vision in both eyes for over 1 year, but his history was otherwise unremarkable. As in our first patient CFP, FAF, and swept-source angio OCT were performed. No abnormalities were seen in either the superficial or deep capillary plexus or in the original choriocapillaris images.

Results

Clearly identifiable individual choriocapillaris vessels were found in all 4 enhanced en face images from both eyes of both patients. This is seen in Figure 2 from the first patient and in Figure 3 from the second patient. In the upper half of Figure 2, the original and enhanced images from the right eye may be observed, while in the bottom half the original and enhanced images from the left eye are visible. The same sequence of images was used in Figure 3 for patient no. 2. Choriocapillaris vessel diameter was inspected in the processed images and found to be relatively similar throughout the entire images. Ten representative vessel diameters were measured from each eye of both patients. The diameter was found to be 14 μm. These results seem to correlate well when compared to images of the choriocapillaris taken using adaptive optics OCT (AO-OCT). In a study by Kurokawa et al. [14],




Figure 3. The upper 3 images display were obtained from the right eye of patient no. 2. The image on the left is the original choriocapillaris image obtained using the Topcon DRI OCT Triton. The middle image has been processed using ImageJ and magnified 1.2x. The image on the right has been processed using ImageJ and magnified 2x using RegiStax. The lower 3 images display were obtained from the left eye of patient no. 2. The image on the left is the original choriocapillaris image obtained using the Topcon DRI OCT Triton. The middle image has been processed using ImageJ and magnified 1.2x. The image on the right has been processed using ImageJ and magnified 2x using RegiStax.

choriocapillaris vessel diameter was found to be $17.4 \pm 2.3 \mu\text{m}$ in a group of 9 healthy patients using AO-OCT. Apart from choriocapillaris vessel diameter, the vessel structure of the choriocapillaris in our images seems to be consistent with images obtained with AO-OCT and in histologic sections [15]. Images of the superficial and deep capillary plexus of patient no. 1 revealing no changes can be seen in Figure 4 along with the original choriocapillaris image. Normal-appearing images of the deep and superficial capillary plexus of patient no. 2, along with the original choriocapillaris, can be seen in Figure 5.

Discussion

OCT angiography is an imaging method that facilitates visualization of blood flow in biological tissues [16]. Motion as a

contrast mechanism is used to visualize the location of moving cells. In ophthalmic angio OCT, the movement of red blood cells in the vessels of the retina and choroid is used. When the red blood cells flow across the imaging beam, fluctuations in the interference signal arise. Various detection and visualization techniques for these fluctuations have been developed for optical OCT angiography. Unfortunately, the obtained en face images do not show individual vessels. Therefore, in this study we developed a method of enhancement of the choriocapillaris, which yielded good results. To the best of our knowledge, there has previously been only 1 study, carried out by Spaide [17], using Image J software to process and enhance the visualization of the choriocapillaris layer in en face OCT angiography images. The author of the study was not able to visualize individual choriocapillaris vessels. En face angio OCT images obtained from 104 eyes of 80 patients were

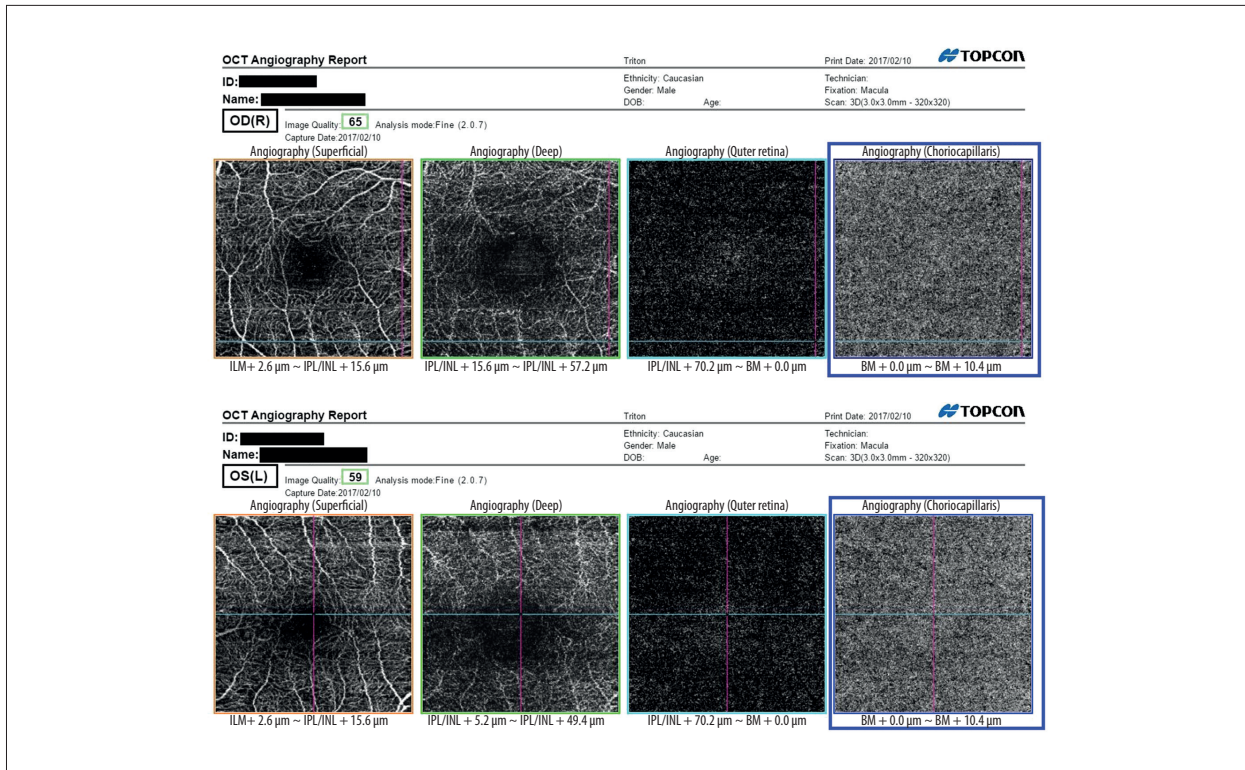


Figure 4. Superficial and deep capillary plexus as well as choriocapillaris layer of both eyes in patient no. 1.

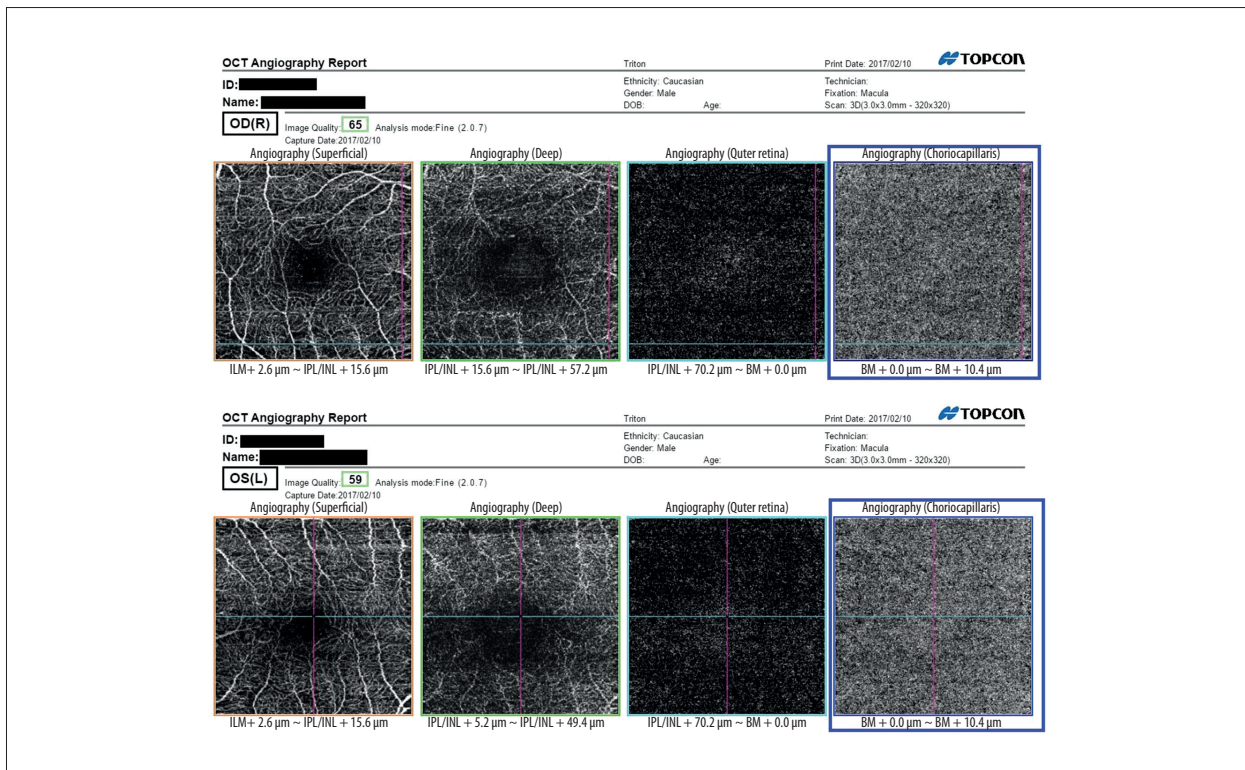


Figure 5. Superficial and deep capillary plexus as well as choriocapillaris layer of both eyes in patient no. 2.

imported into FIJI software (an expanded version of ImageJ version 1.51a). Automatic local thresholding was performed with the Phansalkar method. The threshold images were later analyzed with the “Analyze Particles” command. This resulted in images that were analyzed for the presence of flow voids as dark areas of decreased local blood flow. These flow voids were found to be smaller in size than individual choriocapillaris lobules. The first limitation of our study is that we examined only 4 eyes of 2 subjects. However, our results are similar to results obtained with higher-resolution adaptive optics optical coherence tomography and in histologic examinations. Secondly, since blood is highly scattering, large retinal blood vessels result in a lower signal level below the vessels and a more rapidly fluctuating speckle pattern, causing shadow-like artifacts in the choriocapillaris [8]. We did not have the means to compensate for this effect in our images. Research into the removal of these shadow-like artifacts on the choriocapillaris is still ongoing and there have been mixed results so far [18].

References:

1. Buggage RR, Torczynski E, Grossniklaus HS: Choroid and suprachoroid. In: Tasman W, Jaeger EA (eds.), *Duane's ophthalmology*. Philadelphia: Lippincott Williams & Wilkins, 2006
2. Zouache MA, Eames I, Klettner CA, Luthert PJ: Form, shape and function: Segmented blood flow in the choriocapillaris. *Sci Rep*, 2016; 6: 35754
3. Marmor MF, Ravin JG: Fluorescein angiography: Insight and serendipity half a century ago. *Arch Ophthalmol*, 2011; 129(7): 943–48
4. Sohrab M, Wu K, Fawzi AA: A pilot study of morphometric analysis of choroidal vasculature *in vivo*, using en face optical coherence tomography. *PLoS One*, 2012; 7(11): e48631
5. Lavinsky F, Lavinsky D: Novel perspectives on swept-source optical coherence tomography. *Int J Retina Vitreous*, 2016; 2: 25
6. Povazay B, Bizheva B, Hermann B et al: Enhanced visualization of choroidal vessels using ultrahigh resolution ophthalmic OCT at 1050 nm. *Opt Express*, 2003; 11(17): 1980–86
7. Montaghiannezam R, Schwartz DM, Fraser SE: *In vivo* human choroidal vascular pattern visualization using high-speed swept-source optical coherence tomography at 1060 nm. *Invest Ophthalmol Vis Sci*, 2012; 53(4): 2337–48
8. Choi W, Mohler KJ, Potsaid B et al: Choriocapillaris and choroidal microvasculature imaging with ultrahigh speed OCT angiography. *PLoS One*, 2013; 8(12): e81499
9. Hamzah F, Shinjima A, Mori R, Yuzawa M: Choroidal thickness measurement by enhanced depth imaging and swept-source optical coherence tomography in central serous chorioretinopathy. *BMC Ophthalmol*, 2014; 14: 145
10. Zheng F, Gregori G, Schaal KB et al: Choroidal thickness and choroidal vessel density in nonexudative age-related macular degeneration using swept-source optical coherence tomography imaging. *Invest Ophthalmol Vis Sci*, 2016; 57(14): 6256–64
11. Láins I, Talcott KE, Santos AR et al: Choroidal thickness in diabetic retinopathy assessed with swept-source optical coherence tomography. *Retina*, 2017 [Epub ahead of print]
12. Acmaz G, Atlas M, Gulhan A et al: Assessment of macular peripapillary nerve fiber layer and choroidal thickness changes in pregnant women with gestational diabetes mellitus, healthy pregnant women, and healthy non-pregnant women. *Med Sci Monit*, 2015; 21: 1759–64
13. Yilmaz T, Karci AA, Yilmaz I et al: Long-term changes in subfoveal choroidal thickness after cataract surgery. *Med Sci Monit*, 2016; 22: 1566–70
14. Kurokawa K, Liu Z, Miller DT: Adaptive optics optical coherence tomography angiography for morphometric analysis of choriocapillaris. *Biomed Opt Express*, 2017; 8(3): 1803–22
15. Torczynski E, Tso MO: The architecture of the choriocapillaris at the posterior pole. *Am J Ophthalmol*, 1976; 81(4): 428–40
16. Gorczyńska I, Migacz JV, Zawadzki RJ et al: Comparison of amplitude-decorrelation, speckle-variance and phase-variance OCT angiography methods for imaging the human retina and choroid. *Biomed Opt Express*, 2016; 7(3): 911–42
17. Spaide RF: Choriocapillaris flow features follow a power law distribution: Implications and characterization and mechanisms of disease progression. *Am J Ophthalmol*, 2016; 170: 58–67
18. Scripsema NK, Garcia PM, Bavier RD et al: Optical coherence tomography angiography analysis of perfused peripapillary capillaries in primary open-angle glaucoma and normal-tension glaucoma. *Invest Ophthalmol Vis Sci*, 2016; 57(9): OCT611–20

Conclusions

This method of enhancement of choriocapillaris visualization in en face swept-source angio OCT images is quick and easy to perform and only requires the use of open access software (ImageJ and RegiStax), making it widely available to clinicians and researchers alike.

Conflict of interest

None.