



The role of cranial CT in the investigation of meningitis

Inderjeet Nagra¹ • Bernard Wee² • Jennifer Short³ • Arpan K Banerjee¹

¹Heart of England NHS Foundation Trust – Department of Radiology, Bordesley Green East, Birmingham, UK

²Sandwell and West Bromwich Hospital – Department of Radiology, Birmingham, UK

³Heart of England NHS Trust – Department of Infectious Diseases, Birmingham, UK

Correspondence to: Inderjeet Nagra. Email: indynagra@doctors.org.uk

DECLARATIONS

Competing interests

None declared

Funding

None

Ethical approval

Not applicable

Guarantor

AB

Contributorship

All authors
contributed equally

Acknowledgements

None

Reviewer

Marcus Bradley

Summary

Objective To assess the usage of cranial computed tomography (CT) in patients admitted with meningitis.

Design Retrospective study.

Setting Heart of England NHS foundation trust, a teaching hospital in the West Midlands.

Participants Two groups of adult patients admitted with meningitis between April 2001 and September 2004 and from September 2006 until September 2009.

Main outcome measures The numbers of patients having cranial CT and lumbar puncture and whether any complications had arisen following lumbar puncture. The appropriateness of the CT request according to local criteria.

Results A total of 111 patients were admitted in the initial time period and 47 patients in the second time period. In the first group, 67 patients underwent CT (61%), compared with 36 patients (80%) in the second group. There were eight abnormal scans (12%) in the initial group including three patients with radiological features of cerebral oedema. Of these patients, one underwent lumbar puncture and had no neurological sequelae. In the second group, there were five abnormal scans (14%) with one presenting a contraindication for lumbar puncture due to mild ventricular dilatation. A lumbar puncture was performed in this patient without complication. All patients with abnormal scans had clinical features to suggest raised intracranial pressure. CT scan requests were considered inappropriate in 26% of patients in the initial study period and 56% of patients in the second study period.

Conclusion More patients with meningitis are undergoing CT and the number of inappropriate requests are increasing. There are few abnormal CT scans presenting a contraindication for lumbar puncture and the majority of these patients usually have clinical signs to suggest raised intracranial pressure.

Introduction

Bacterial meningitis is an important clinical condition, which progresses rapidly and can result in death or significant morbidity if it is not treated as a medical emergency. Prompt diagnosis and early management with antibiotics and supportive treatment is vital to reduce mortality and subsequent complications. The annual incidence of meningitis in the UK is approximately 1200 cases per year¹ and 4–6 per 100,000 adults in the US.² The majority of patients have no predisposing factors for bacterial meningitis and most cases are community acquired. Presentation is usually with headache, neck stiffness, photophobia and fever. In bacterial meningitis, patients can present with a rash and more adverse features such as seizures, confusion and reduced consciousness. The presentation of viral meningitis is similar with a triad of headache, neck stiffness and fever but photophobia is far more common and the illness is often preceded by a flu-like illness. It is a self-limiting condition usually requiring only supportive management.

Although computed tomography (CT) scanning prior to lumbar puncture is not recommended in uncomplicated cases, a number of departments are performing cranial CT in patients without clinical signs of raised intracranial pressure to determine the safety of lumbar puncture. However, CT is a poor indicator of raised intracranial pressure and appropriate clinical assessment is a more useful predictor of an intracranial abnormality. Inappropriate imaging may cause an unacceptable delay in the administration of antibiotics and the treatment of bacterial meningitis, leading to higher rates of mortality and morbidity. All patients with suspected meningitis should undergo lumbar puncture to establish the diagnosis, except those where meningococcal septicaemia is likely. Very few cases where lumbar puncture has led to or hastened cerebral herniation have been reported. Cerebral herniation is a rare complication and the majority of these complications have been reported in children. Nevertheless, it is important to identify patients who are at risk of cerebral herniation where a lumbar puncture would be contraindicated. The clinical features which suggest raised intracranial pressure include reduced consciousness levels, focal neurology or papilloedema. CT scanning

should not replace the need for a thorough clinical assessment in these patients as the CT scan may be normal providing false reassurance. In our experience, a large number of CT scans are being performed as a routine screening tool often in uncomplicated meningitis.

Method

Two groups of patients admitted with meningitis were reviewed over two separate time periods chosen approximately 5 years apart. The first group of patients were admitted between April 2001 and September 2004 and the second group between September 2006 and September 2009. Only consecutive adult patients with a clinical coded diagnosis of meningitis were included. Patients with insufficient clinical information were excluded. Information on the presentation, whether cranial CT or lumbar puncture had been performed and any complications following lumbar puncture were recorded. All CT scans were performed on a multislice Toshiba scanner. Radiological requests, imaging results and microbiological reports were reviewed. In patients undergoing CT, the notes and request cards were reviewed to assess the indication for the CT request and whether the CT request was appropriate. The criteria for assessing the appropriateness of requesting CT imaging were reduced GCS, focal neurological signs, papilloedema, seizures, a history of immunocompromise or neurological disease. Other clinical features which were suggestive of an intracranial bleed, for example, were also considered as an appropriate indication for CT imaging.

Results

Group 1

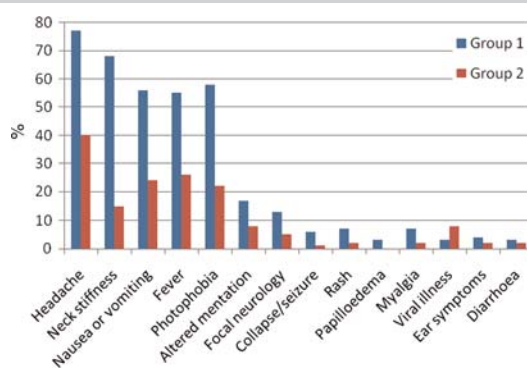
In the period between April 2001 and September 2004, 111 patients were coded with a diagnosis of meningitis (69 women, 42 men). The mean age was 35 years (range 16–82). Three patients were excluded due to a lack of clinical information. Of the remaining 108 patients, there were 59 cases of viral meningitis, 30 with bacterial meningitis, five with unspecified meningitis, two with

fungal meningitis and 14 with a diagnosis other than meningitis (Table 1). The commonest presenting complaints were headache (84 patients), neck stiffness (74 patients), nausea and vomiting (61 patients), fever (60 patients) and photophobia (63 patients) (Figure 1). Nineteen patients had reduced Glasgow Coma Score (GCS) due to confusion and 14 had focal neurological signs; 17 patients in this group had predisposing factors for meningitis (Table 2).

In this group, 67 patients underwent CT (61%). There were eight abnormal scans (12%). The abnormal scan results included three scans with cerebral oedema (Figure 2), one with meningeal enhancement, one with subcortical infarcts, one with tonsillar descent, a small subdural and a possible subarachnoid haemorrhage. On review of the scans, meningeal enhancement is compatible with meningitis and the reported finding of tonsillar descent is a normal variant and should not be considered a contraindication for lumbar puncture. In the case of the subdural haematoma, there was no midline shift to indicate raised intracranial pressure. Therefore there were three scans with evidence of mass effect, namely cerebral oedema (4%) which presented a contraindication for lumbar puncture (Table 3). Of these, two patients did not have a lumbar puncture as a result of the CT findings. One patient had a lumbar puncture, resulting in no complication. Most of the patients with abnormal scans and all of the patients with radiological findings of cerebral oedema had clinical features of reduced consciousness or focal neurology suggesting raised intracranial pressure.

No indication for CT was found on the request card in nine patients (Table 4). Of those where an indication was stated, this was usually to exclude a subarachnoid haemorrhage (22

Figure 1
Clinical features at presentation in both groups



patients). Other indications for CT included confusion, safety of lumbar puncture, focal neurology, papilloedema and a history of neurological disease, trauma, surgery or immunosuppression. Safety of lumbar puncture was considered an inappropriate request for cranial CT in the absence of any other clinical information. CT requesting was considered inappropriate in 18 out of 67 (26%) patients undergoing CT.

Group 2

In the period between September 2006 and September 2009, 47 patients were coded with a diagnosis of meningitis (25 women, 22 men). The mean age was 37 years (range 17–87). Two patients were excluded, due to a lack of clinical information. Of the remaining 45 patients, 36 patients had viral meningitis, four had bacterial meningitis, two had unspecified meningitis and three patients had another diagnosis (Table 1).

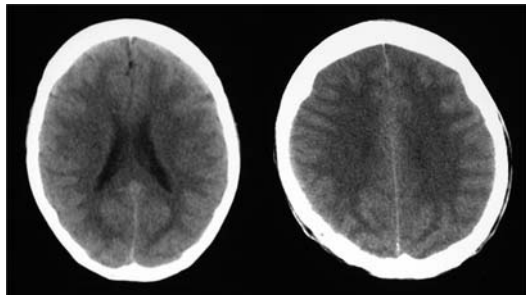
Table 1
Type of meningitis

	Group 1 (%)	Group 2 (%)
Viral	59 (53)	36 (80)
Bacterial meningitis	30 (28)	4 (9)
Unspecified meningitis	5 (5)	2 (4)
Fungal meningitis	2 (2)	0
Other diagnosis	14 (13)	3 (6)

Table 2
Predisposing factors for meningitis

Predisposing factor	Group 1	Group 2
Immunocompromised	6	2
Sinusitis or otitis media	4	4
Neurological or ENT surgery	2	1
Diabetes	2	0
Cerebrospinal fluid leak	1	0
Trauma	1	0
Splenectomy	1	0
Pregnancy	0	1

Figure 2
Cerebral oedema with sulcal effacement in a clinically obtunded patient with bacterial meningitis



The presenting complaints were headache (40 patients), neck stiffness (15 patients), fever (26 patients) and photophobia (21 patients). Eight patients had reduced GCS due to confusion and five patients had focal neurology. No papilloedema was reported, although fundoscopy was only documented in 10 patients. Nine patients had conditions predisposing towards meningitis (Table 2). In this group, 36 patients underwent cranial CT (80%). There were 31 normal and five abnormal scans (14%). Of the abnormal scans, the major finding was opacified sinuses (Figure 3), temporal lobe changes which later developed into an abscess (Figure 4), previous infarcts and a small vault meningioma. The patient with a small vault meningioma was reported to have mild ventricular dilatation, therefore a possible contraindication for lumbar puncture. Ventricular dilatation may result from central atrophy or from normal pressure

hydrocephalus and does not necessarily reflect increased cerebrospinal fluid (CSF) pressure. A lumbar puncture was still performed in this case, resulting in no neurological sequelae. Review of the request cards showed that safety of lumbar puncture was the main indication (15 patients), followed by exclusion of subarachnoid haemorrhage, focal neurology and immunosuppression or the exclusion of encephalitis (Table 4). In 20 of the 36 (56%) patients undergoing CT, the request for CT was considered inappropriate in relation to the local criteria for CT.

Discussion

There are an increasing number of scans being performed for patients with meningitis in our department from 2001 to 2009 (61% increasing to 80%). This is likely to be related to the increasing demand for all forms of imaging throughout radiology departments. The trend for performing cranial imaging prior to lumbar puncture is increasing,³⁻⁵ perhaps reflecting the wider availability of CT and the prompt out-of-hours service provision. A study of emergency department CT requesting by Hasbun *et al.* showed that 78% of patients with meningitis were undergoing cranial CT.³ Other studies are outlined in Table 5; a study by Gopal and Durand found figures of 66–87% of patients with meningitis were undergoing CT.^{5,6} There is evidence to show that CT may not significantly influence the clinical decision making and that CT findings fail to reveal any significant abnormality that was not suspected on clinical examination.⁵ The need for imaging has to be balanced against the resources

Table 3
Characteristics relating to group 1 (Apr 2001–Sep 2004) and group 2 (Sep 2006–Sep 2009)

	Mean age (range)	Gender	Recurrent meningitis	Predisposing factors	CT scans, n (%)	Abnormal CT scans, n (%)	Scans presenting a CI for LP (%)
Group 1 (n = 108)	35 (16–82)	66 women; 42 men	7	17	67 (61)	8 (12)	3 (4)
Group 2 (n = 45)	37 (17–87)	25 women; 20 men	4	9	36 (80) (P = 0.7)	5 (14) (P = 0.3)	1 (3) (P = 0.7)

P values calculated using the chi-squared test

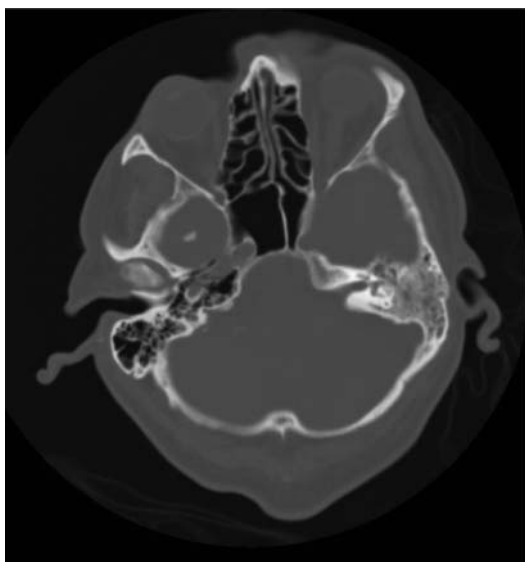
Table 4**Indication for CT according to request card**

	Group 1	Group 2
Indication unknown	9	3
Exclusion of subarachnoid haemorrhage	22	11
Altered mentation, focal neurology or papilloedema	9	4
Safety of lumbar puncture	12	16
Intracranial abscess or space-occupying lesion	6	0
Other (history of neurological disease, trauma or immunosuppression)	7	1

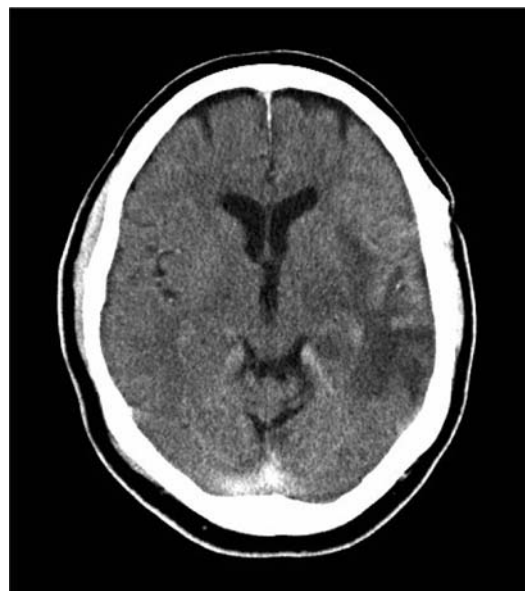of the imaging department. We found the vast majority of scans being performed in patients with meningitis are normal (88% and 86%) and abnormal scans presenting a contraindication for lumbar puncture are few (4% and 2%). Radiation doses must be justified according to radiation guidelines and local criteria when deciding whether an examination is appropriate and whether it will influence the patients' management.

Figure 3

Opacification of the left mastoid air cells in keeping with sinus disease on bony windows in a patient with pneumococcal meningitis

**Figure 4**

Post-contrast axial CT head, showing an area of low attenuation change in the left temporal lobe, which later developed into an abscess



In our review, the main limitation was the small numbers of patients in the second group. This is despite using a similar methodology and the same method of identification of patients between the two time periods. The number of cases of meningitis dramatically decreased over the two groups reviewed. This may relate to a genuine reduction in the number of cases of meningitis presenting to the trust or to an error in coding cases by the medical team or a change in the coding system. Nevertheless, there is an increasing trend for imaging in this condition although it is difficult to draw any firm conclusions as to the reasons for this with such small numbers.

It appears that there are more CT scans being requested for the safety of lumbar puncture. There is a general lack of information on the request card relating to the clinical presentation and on review of the notes. A reason for requesting the CT was not always stated in the notes. The limited clinical information may yield an unexpected result. Excessive imaging reflects the lack of knowledge of the limitations of CT in assessing intracranial pressure. The safety of lumbar

Table 5
Comparative table of literature on cranial CT in meningitis

Study	Type of study	Year of publication	Mean age (range)	Patient records reviewed (n)	CT scans, n (%)	Abnormal CT scans making LP a contraindication, n (%)
Rennick	Retrospective	1993	2 (4 months–15 years)	445	127 (29)	–
Durand	Retrospective	1993	Adult	122	87 (71)	20 (27%)
Gopal, Whitehouse <i>et al.</i>	Prospective	1999	42	113	111	2.7%
Hasbun, Abrahams <i>et al.</i>	Prospective	2001	40 (18–93)	301	235 (78)	11 (5%)
Chadwick and Lever	Retrospective	2002	15–30	116	(66)	–
Proulx, Frechette <i>et al.</i>	Retrospective	2005	54 (19–86)	119	48 (40)	–

puncture should be a clinical decision rather than a radiological one and local policy should be to reject any requests without enough clinical information. These issues can be addressed by education of juniors or placing the care of these patients under specialist infectious diseases teams.

Clinical predictors such as altered mentation, papilloedema or focal neurology and the overall clinical impression are more useful indicators of raised intracranial pressure than cranial CT.⁷ Papilloedema is a difficult sign to detect in patients with photophobia and the exclusion of raised intracranial pressure may be an indication for requesting a CT if the clinician has not been able to exclude papilloedema. A study by Gopal found a low number of CT scans presenting a contraindication for lumbar puncture and concluded that routine screening in patients with meningitis gives limited additional information.⁷ In a study by Chadwick, 55% of scans were deemed inappropriate and only 45% of patients met the criteria for CT scanning but exclusion of a subarachnoid haemorrhage was thought to be warranted due to the symptoms suggestive of an intracranial bleed.⁸ In an American study, there was a perceived need by clinicians for imaging in meningitis due to a routine standard of care or the fear of litigation.³ Litigation may be an increasing indication in the UK to exclude pathology rather

than as a justification for CT on the basis of clinical need.

Meningitis can be a difficult condition to diagnose as many conditions mimic the clinical features and patients may not present with the typical triad of headache, neck stiffness and photophobia. The condition should be considered in those patients that are immunocompromised or without an obvious diagnosis. Atypical features are seen in up to 37–66% of cases.^{2,9} Patients that are particularly susceptible to meningitis and have higher rates of morbidity and mortality are those at the extremes of age, reaching up to 25% in bacterial meningitis.⁶ Delays in diagnosis are associated with a poor clinical outcome.^{6,10} The commonest pathogens are *Streptococcus pneumoniae*, *Neisseria meningitidis* and *Haemophilus Influenzae* type B² causing 72% of cases and 70% of deaths.¹¹ Other causes of bacterial meningitis are gram negative organisms such as *Escherichia Coli* and *Klebsiella* species, which have increased over the last four decades due to a rising number of neurological and oncological procedures.¹² In immunosuppressed patients, listeria monocytogenes and fungal infections should be considered.

Viral meningitis is most often caused by enteroviridae such as Coxsackie B and echovirus. Other causes include mumps, varicella zoster, herpes simplex virus and cytomegalovirus.

Viral meningitis is a self-limiting condition which usually has a good clinical outcome and a limited hospital stay. The main differential diagnosis of meningitis is subarachnoid haemorrhage. This can present with similar symptoms to meningitis although without a history of fever (53 of 108 patients in group 1). It is also important to consider other conditions which mimic meningitis such as subdural empyema, cerebral abscess, herpes simplex and toxoplasma encephalitis. In the majority of cases, a CSF sample should be obtained for confirmation of the diagnosis and for microbiological analysis. This is especially important as early treatment is vital and it is preferable to treat the causative organism with the appropriate antibiotic cover.

In bacterial meningitis, pathogens reach the subarachnoid space via the haematogenous route causing a host inflammatory response leading to inflammation of cortical vessels with swelling and proliferation of endothelial cells in arterioles and veins.¹³ This leads to raised CSF pressure due to cerebral oedema and further inflammatory occlusion of the arachnoid villi or ventricular foramina, resulting in the obstruction of CSF outflow.¹⁴⁻¹⁶ A lumbar puncture is contraindicated in the presence of brain shift as shifts occur with or without raised intracranial pressure.¹⁷ Other causes of raised intracranial pressure are from space-occupying lesions such as haematoma, tumours or abscesses and these causes can be excluded by imaging. The complications of meningitis found on imaging are hydrocephalus, subdural empyema, ventriculitis, venous thrombosis or infarction. Additional findings include evidence of trauma, sinus infection (Figures 2 and 3) or congenital abnormalities. A lumbar puncture could increase the brain shifts already present due to a space-occupying lesion. The original studies highlighting the dangers of lumbar puncture were first reported in children^{14,18,19} but cases of herniation have also been reported in children and adults that have not had lumbar puncture.^{15,20} The percentage of adult patients with bacterial meningitis herniating after lumbar puncture is 2-5%.^{6,21} Herniation occurred within the first 12 hours¹⁰ or between 30 minutes and two hours^{22,23} following lumbar puncture.

Clinicians have become increasingly reliant on CT to detect patients where lumbar puncture

should be avoided and many authors have advocated that all patients should undergo CT prior to LP.²⁴⁻²⁶ Although, CT can detect anatomical shifts as a result of space-occupying lesions, CSF pressure can be normal in patients with space-occupying lesions²⁷ and in those who are actively herniating, demonstrating the relationship between CSF pressure and CT is indirect.¹⁷ The late imaging signs of raised intracranial pressure on CT are delayed presenting late after the clinical signs. The imaging signs include brain shift and lateral shift of midline structures, obliteration or dilatation of the ventricles and effacement of CSF spaces (sulci, sylvian fissures, basal cisterns). The early signs are loss of grey-white matter differentiation. On autopsy, the findings include necrosis of the cerebellar tonsils, mesencephalic necrosis and brainstem haemorrhage.

In a series of 445 children by Rennick, 4.3% of patients had clinical signs of herniation.¹⁵ CT was performed at the time of herniation in 14 patients and five (36%) of the scans were normal despite the clinical picture. In another study, approximately 50% of patients with clinical features suggestive of raised intracranial pressure had a normal CT scan.⁶ The explanation for CT failing to demonstrate severely raised intracranial pressure are alterations in intracranial compliance or meningeal hardening, particularly in chronic or recurrent meningitis where there may be the simultaneous occurrence of decreased CSF absorption and significant cerebral oedema.¹⁹ CT has been recommended in patients with new-onset seizures, the immunocompromised, aged above 60 years, signs of a space-occupying lesion or moderate to severe impairment of consciousness and a history of neurological disease.^{1,3,17}

There is evidence to show that performing a CT prior to lumbar puncture may delay the institution of antibiotics with the time delay ranging from 2 to 4.9 hours.^{10,28-30} A longer delay of 6 hours was found in a study by Proulx but this delay included an interhospital transfer. The effect of a delay in treatment is incremental with longer delays resulting in higher case fatality rates.³ Some studies have reported low levels of antibiotic administration prior to CT^{31,32} but since many departments are now treating empirically with antibiotics prior to imaging, this is not such a

concern. CT scans are usually requested by junior staff but in our experience, management decisions after discussion with seniors often does not change the practice of scanning prior to lumbar puncture. However, the involvement of specialist infectious diseases teams at an early stage may alter the decision for imaging. The education of junior doctors is needed to ensure that CT scanning is not performed routinely to screen for intracranial abnormalities in patients with suspected meningitis. A thorough clinical assessment prior to imaging is important as the imaging findings may not be supportive of raised intracranial pressure and may provide false reassurance for clinicians. The fear of litigation should be balanced against the risks associated with unwarranted radiation in patients that are often young. A more focused approach is recommended so that patients do not undergo unnecessary CT scans which could potentially delay diagnosis or treatment.

Conclusion

Increasing numbers of patients with meningitis are undergoing cranial CT putting pressure on imaging departments. A large proportion of scans are normal with very few scans presenting a contraindication for lumbar puncture. Patients with abnormal CT scans often have clinical features to suggest intracranial pathology. Criteria for CT scanning in this group of patients should be agreed locally with clinicians and imaging should be requested according to clinical need rather than as a screening tool.

References

- Health Protection Agency. Statutory notifications of Infectious Diseases – annual total 1994–2008 (England and Wales). London: HPA, 2010. See <http://www.hpa.org.uk/Topics/InfectiousDiseases/InfectionsAZ/NotificationsOfInfectiousDiseases/NOIDSReportsAndTables/>
- Van de Beek D, de Gans J, Tunkel AR, Wijdicks EFM. Community-acquired bacterial meningitis in adults. *N Engl J Med* 2006;**354**:44–53
- Cooper JR. Routine use of CT prior to lumbar puncture. *Br J Radiol* 1999;**72**:319
- Ganeshan D. CT before lumbar puncture in meningitis-what every radiology trainee should know. *Clin Radiol* 2009;**64**:845
- Gopal AK, Whitehouse JD, Simel DL, Corey R. Cranial computed tomography before lumbar puncture. *Arch Intern Med* 1999;**159**:2681–5
- Durand ML, Calderwood SB, Weber DJ, et al. Acute bacterial meningitis in adults. A review of 493 episodes. *N Engl J Med* 1993;**328**:21–8
- Cabral DA, Flodmark O, Farrell K, Speert DP. Prospective study of computed tomography in acute bacterial meningitis. *J Pediatr* 1987;**111**:201–5
- Chadwick DR, Lever AML. The impact of new diagnostic methodologies in the management of meningitis in adults at a teaching hospital. *QJM* 2002;**95**:663–670
- Proulx N, Frechette D, Toye B, Chan J, Kravcik S. Delays in the administration of antibiotics are associated with mortality from adult acute bacterial meningitis. *QJM* 2005;**98**:291–8
- Aronin SI, Peduzzi P, Quagliarello VJ. Community-acquired bacterial meningitis: risk stratification for adverse clinical outcome and effect of antibiotic timing. *Ann Intern Med* 1998;**129**:862–9
- Tunkel AR. Reducing Intracranial Pressure may increase survival among patients with bacterial meningitis. *Curr Infect Dis Rep* 2004;**6**:296–7
- Tunbridge A, Read R. Management of meningitis. *Clin Med* 2004;**4**:499–505
- Tauber MG, Moser B. Cytokines and chemokines in meningeal inflammation: biology and clinical implications. *Clin Infect Dis* 1999;**28**:1–11
- Horwitz SJ, Boxerbaum B, O'Bell J. Cerebral herniation in bacterial meningitis in childhood. *Ann Neurol* 1980;**7**:524–8
- Rennick G, Shann F, de Campo J. Cerebral herniation during bacterial meningitis in children. *BMJ* 1993;**306**:953–5
- Van Crevel H, Hijdra A, de Gans J. Lumbar puncture and the risk of herniation: when should we first perform CT? *Neurol* 2002;**249**:129–37
- Lorber J, Sunderland R. Lumbar puncture in children with convulsions associated with fever. *Lancet* 1980;**1**:785–6
- Williams CPS, Swanson AG, Chapman JT. Brain swelling with acute purulent meningitis: report of treatment with hypertonic intravenous urea. *Pediatrics* 1964;**34**:220–7
- Winkler F, Kastenbaeur S, Yousry TA, et al. Discrepancies between brain CT imaging and severely raised intracranial pressure proven by ventriculostomy in adults with pneumococcal meningitis. *J Neurol* 2002;**249**:1292–7
- Dodge PR, Swartz MN. Bacterial meningitis - a review of selected aspects II. Special neurological problems, post meningitic complications and clinicopathological correlations. *N Engl J Med* 1965;**272**:954–60, 1003
- Swartz MN, Dodge PR. Bacterial meningitis – a review of selected aspects I. General clinical features, special problems and unusual meningeal reactions mimicking bacterial meningitis. *N Engl J Med* 1965;**272**:725–31, 779
- Joffe AR. Lumbar puncture and brain herniation in acute bacterial meningitis. *J Intens Care Med* 2007;**22**:194–207
- Haslam RH. Role of computerized tomography in the early management of bacterial meningitis. *J Pediatr* 1991;**119**:157–9
- Richards J, Swann RA, Ponton AW. Recurrence of listeria monocytogenes meningitis. *J Infect* 1988;**16**:65–71
- Gower DJ, Baker AL, Bell WO, Ball MR. Contraindications to lumbar puncture as defined by computed cranial tomography. *J Neurol Neurosurg Psych* 1987;**50**:1071–4

- 26 Lundberg N. Continuous recording and control of ventricular fluid pressure in neurosurgical practice. *Acta Psychiatr Neurol Scand* 1960;**36** (Suppl.149):148–93
- 27 Hasbun R, Abrahams J, Jekel J, Quagliarello VJ. Computed tomography of the head before lumbar puncture in adults with suspected meningitis. *N Engl J Med* 2001;**345**:1727–33
- 28 Bryan CS, Reynolds KL, Crout L. Promptness of antibiotic therapy in acute bacterial meningitis. *Ann Emerg Med* 1986;**15**:544–7
- 29 Talan DA, Guterman JJ, Overturf GD, Singer C, Hoffman JR, Lambert B. Analysis of emergency department management of suspected bacterial meningitis. *Ann Emerg Med* 1989;**18**:856–62
- 30 Meadow WL, Lantos J, Tanz RR, Mendez D, Unger R, Wallskog P. Ought 'standard care' be the 'standard of care'? A study of the time to administration of antibiotics in children with meningitis. *Am J Dis Child* 1993;**147**:40–4
- 31 Cartwright K, Reilly S, White D, Stuart J. Early treatment with parenteral penicillin in meningococcal disease. *BMJ* 1992;**305**:143–7
- 32 Strang JR, Pugh EL. Meningococcal infections: reducing the case fatality rate by giving penicillin before admission to hospital. *BMJ* 1992;**305**:141–3

© 2011 Royal Society of Medicine Press

This is an open-access article distributed under the terms of the Creative Commons Attribution License (<http://creativecommons.org/licenses/by-nc/2.0/>), which permits non-commercial use, distribution and reproduction in any medium, provided the original work is properly cited.