


SHORT REPORT

Ultraviolet photography in vitiligo: image quality, validity and reliability

S.E. Uitentuis,^{1,*}  M.N. Heilmann,¹ R.M. Verdaasdonk,² J.M. Bae,³ R.M. Luiten,¹ A. Wolkerstorfer,¹ M.W. Bekkenk¹

¹Netherlands Institute for Pigment Disorders, Department of Dermatology, Amsterdam University Medical Centers, University of Amsterdam, Amsterdam, The Netherlands

²Department of Biomedical Photonics & Imaging, University of Twente, Enschede, The Netherlands

³Department of Dermatology, St. Vincent's Hospital, College of Medicine, The Catholic University of Korea, Suwon, Korea

*Correspondence: S.E. Uitentuis. E-mail: s.e.uitentuis@amsterdamumc.nl

Abstract

Background For clinical care and research in vitiligo, photographs with the use of ultraviolet (UV) light or Wood's lamp are often made. Conventional cameras are insensitive to UV light. The use of a UV camera (UV photography) might improve image quality and ameliorate the assessment of target lesions in vitiligo.

Objectives To determine image quality and the validity and reliability of UV photography for the assessment of vitiligo target lesions.

Methods Images of patients with vitiligo were made with UV photography and a conventional camera, and lesions were drawn on graph paper and transparent sheets. Image quality was scored by vitiligo experts and medical interns. The intraclass correlation coefficients (ICCs) of the lesion size determined with UV photography combined with digital surface measurement and the other techniques were hypothesized to be above 0.6. The ICCs between UV images taken by the same physician and between two different physicians were calculated for determining inter- and intra-reliability.

Results In total, 31 lesions of 17 patients were included. Image quality was assessed as good or very good for 100% and 26% for UV photography and the conventional camera, respectively. ICCs of UV photography and the conventional camera, drawing the lesions on transparent sheets and graph paper, were 0.984, 0.988 and 0.983, respectively, confirming our hypotheses. The ICCs of the intra-rater and inter-rater were 0.999 and 0.998, respectively.

Conclusions The results of this study indicate that the use of UV photography for the assessment of vitiligo lesions improves image quality and is valid and reliable.

Received: 13 August 2019; Accepted: 7 January 2020

Conflicts of interest

None declared.

Funding sources

This article has no funding source.

Introduction

For the follow-up of vitiligo and for research purposes, photographs are often made with the use of UV light. UV light is not visible to the human eye, thereby greatly limiting the observation by the physician to only a small bandwidth of the light present. Using a UV camera which passes UV light,^{1–3} and thus captures all light emitted by the UV lamps, could improve image quality and contrast and therefore ameliorate the assessment of vitiligo lesions.

To evaluate repigmentation of targeted therapy, repigmentation can be measured by comparing the lesion size before and after treatment.

Recently, van Geel *et al.* published a validation study for the conventional camera method and the transparent sheet method using ImageJ software for digital surface measurement.⁴ No study has been performed on the combination of UV photography images and digital surface measurement software. This method could be a valuable and easy to use instrument to measure the size of target lesions.

The aim of this study was to evaluate image quality of UV photography images in vitiligo and to assess the validity and reliability of UV photography images in combination with digital surface measurement for determining surface area of target lesions in vitiligo.

Materials and methods

This cohort study was executed at the outpatient clinic of the Netherlands Institute For Pigment Disorders (SNIP) in the Amsterdam University Medical Centers (Amsterdam UMC). Approval was granted by the local medical ethical committee.

Patients

Patients diagnosed with either segmental or non-segmental vitiligo, aged 16 years or older, with Fitzpatrick skin types 1–4 were included. One or two lesions per patient were included. A sample size of at least 30 target lesions was pursued. The vitiligo lesions had to be localized on a flat surface.

Images and measurements

The following four techniques to measure the size of target lesions were used:

- 1 UV photography images combined with digital surface measurement – the UV photography method.
- 2 Conventional digital camera images combined with digital surface measurement – the conventional camera method.
- 3 Lesions drawn on transparent sheets combined with digital surface measurement – the transparent sheet method.
- 4 Lesions drawn on graph paper containing boxes with a size of 1 mm² and counting the number of enclosed boxes – the graph paper method.

UV photography images were obtained using a UV camera: a full spectrum ultraviolet light-adapted mirrorless digital camera (Sony α 5000, Sony, Tokyo, Japan). The UV/NIR filter was removed, and the conventional lens was replaced with a UV transparent 50-mm focal lens. A 20-nm narrow-band filter was used transmitting UV light around 365 nm. The capture of the images was standardized: two softboxes with UV light bulbs (Omnilux, Waldbüttelbrunn, Germany, 25W, 365 nm) were placed on both sides of the lesion as close as possible.⁵ Conventional camera images (Canon EOS 1100D, Tokyo, Japan) were taken with two handheld Wood's lamps (1004 Wood's lamp, Weelko, Barcelona, Spain, 22W). A 0.75 inch size sticker was applied next to the selected lesions as a reference. The lesions were drawn on a transparent sheet and subsequently on semi-transparent graph paper containing boxes with a size of 1 mm².

The surface area of the target lesions on the UV photography images, on the conventional camera images and on the transparent sheets were uploaded and measured by the digital image analysis system ImageJ 1.50i (National Institute of Health, Bethesda, MD, USA). The surface area of the target lesions on the graph paper was calculated by counting the number of enclosed boxes.

Image quality

Image quality was assessed independently by two dermatologists with vitiligo expertise and two medical interns. The

medical interns knew how to recognize vitiligo but lacked practical experience with the Wood's lamps and were therefore somewhat blinded when looking at the images. They were asked to score each image on overall image quality (considering sharpness, contrast and lesion borders).

Validity

In the absence of consensus on a gold standard for measuring target lesions in vitiligo, validity assessment relies on testing hypotheses.⁶ Four hypotheses to test the validity were formulated beforehand:

- 1 An intraclass correlation coefficient (ICC) of >0.6 for lesions size between the UV photography method and the conventional camera method.
- 2 An ICC of >0.6 for lesions size between the UV photography method and the transparent sheet method.
- 3 An ICC of >0.6 for lesions size between the UV photography method and the graph paper method.
- 4 The ICCs of the first two hypotheses will be higher than the ICCs of the conventional camera and graph paper/transparent sheets.

To confirm the construct validity of using UV photography for target lesion assessment, 75% of the hypotheses should be achieved.⁷

Reliability

To test the intra-rater reliability, two UV photography images of each lesion were taken by the same physician. To test the inter-rater reliability, a UV photography image was taken of each lesion by a second physician.

Statistical analyses

To test the validity of the UV photography method, the ICCs between the different measurement instruments were determined in a two-way random model with absolute agreement and reported as single measures. To test the intra- and inter-rater reliabilities, the ICCs were determined. Calculated *P*-values were two-sided and given per analysis, with a *P*-value <0.05 considered significant.

Results

A total of 31 target lesions of 17 consecutively screened patients were included in the study. Baseline characteristics of patients and lesions are reported in Table 1.

Image quality

Figure 1 shows UV photography and conventional camera images of three vitiligo target lesions. Figure 2 shows the frequency of scores by the vitiligo experts and medical interns on

Table 1 Baseline characteristics of the patients ($n = 17$) and the localization of the lesions ($n = 31$)

Characteristics	
Age (years) mean; median (range)	44; 45 (24–60)
Sex, n (%)	
Male	6 (35.3)
Female	11 (64.7)
Fitzpatrick skin type, n (%)	
I	2 (11.8)
II	9 (52.9)
III	3 (17.6)
IV	3 (17.6)
Localization lesions, n (%)	
Trunk	16 (51.6)
Legs	13 (41.9)
Arms	2 (6.5)

image quality. Overall quality of the UV photography images was mostly scored as 'very good'. Quality for the conventional camera was mainly scored as 'average'.

Validity


All ICCs between the different measurement instruments are shown in Table 2. The ICCs between determining the size of target lesions by using the UV photography method and the three other measurement techniques (conventional camera method, transparent sheet method and graph paper method) were 0.984, 0.988 and 0.983, respectively. Therefore, the first three *a priori* defined hypotheses that these ICCs would be higher than 0.6 are met.

The ICCs comparing UV photography with the transparent sheet method and the graph paper method were higher than the ICCs comparing the conventional camera method with the transparent sheet method and the graph paper method. This confirms our fourth hypothesis.

The scatter plots (Fig. S1, Supporting Information) show our results of the correlations between the measured surface area of target lesions by the different measurement instruments.

Reliability

The ICC for the intra-rater reliability was 0.999 [95% confidence interval (CI): 0.997–0.999], and the ICC for the inter-rater

**Figure 1** Vitiligo lesions. Ultraviolet photography images (a, c, e) and conventional camera images (b, d, f).

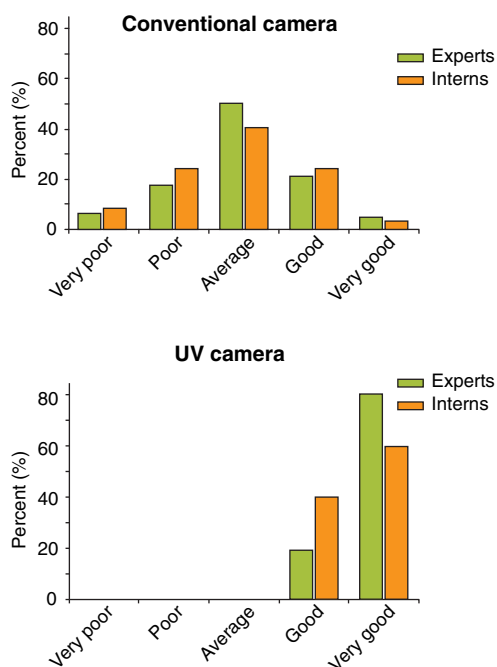


Figure 2 Frequency of quality scores for images of vitiligo lesions made with a conventional camera and ultraviolet photography.

Table 2 Validity: ICCs between the different measurement instruments

	ICC	95% CI
Ultraviolet photography method – conventional camera method	0.984	0.963–0.992
Ultraviolet photography method – transparent sheet method	0.988	0.974–0.994
Ultraviolet photography method – graph paper method	0.983	0.955–0.992
Conventional camera method – transparent sheet method	0.975	0.945–0.988
Conventional camera method – graph paper method	0.960	0.869–0.984

reliability was 0.998 (95% CI: 0.996–0.999). The correlations were closely clustered around the regression lines, both for the intra- and inter-rater reliability (Fig. S2, Supporting Information).

The mean difference in the intra-rater reliability was 0.04 cm² with limits of agreement of 0.35 and –0.28 cm². The mean difference in the inter-rater reliability was 0.04 cm² with limits of agreement of 0.42 and –0.33 cm² (Fig. S3, Supporting Information). These limits of only a few millimetres illustrate a high level of agreement for both intra- and inter-rater reliabilities.

Discussion

UV photography and its promises for dermatology have been described in multiple studies.^{1–3} Mustakallio and Korhonen already described the use of UV photography for pigment disorders including vitiligo in 1966.³ We did not find studies that assess image quality or validation studies for digital UV photography in vitiligo.

We found a high consensus on image quality for the UV photography images, both vitiligo experts and unexperienced medical interns agree separately that the UV photography images were of high or very high quality, and superior to the conventional digital camera images. Furthermore, we found very high ICCs when comparing the UV photography method with other measurement instruments and for multiple measurements by the same or different physicians, supporting its validity and reliability. Another benefit of UV photography is the ease of use. A disadvantage is that UV photography cannot be used for assessment of lesions which are localized on curved skin; this could be resolved by using multiple cameras or other 3D image analysis systems.⁸

With a sample size of 31, our study can be considered as of fair quality,⁶ but larger studies need to be performed to support our findings. Secondly, our study was performed in one centre and findings should be confirmed in other settings and populations. Thirdly, even though the correlations coefficients are high, these correlations do not implicate exact agreement between the different measurement instruments.

Some images showed pinpoint or confetti lesions that were barely visible with UV light. This might imply that UV photography could ameliorate the assessment of vitiligo activity, although this could also be follicular *Propionibacterium acnes*. Further research is needed to explore this hypothesis.

Conclusion

The digital UV-enhanced camera is a very promising tool for assessing vitiligo especially in fair-skinned patients in practice as well as in research. The results of this study indicate that the use of UV photography improves image quality and is valid and reliable.

Acknowledgement

We would like to express our gratitude to the volunteering patients who participated in this study.

References

- Fulton JE. Utilizing the ultraviolet (UV Detect) camera to enhance the appearance of photodamage and other skin conditions. *Dermatol Surg* 1997; **23**: 163–169.
- Draelos ZD, Klein G, Biancone G. A novel ultraviolet photography technique for assessing photodamage. *J Cosmet Dermatol* 2008; **7**: 205–209.
- Mustakallio KK, Korhonen P. Monochromatic ultraviolet-photography in dermatology. *J Invest Dermatol* 1966; **47**: 351–356.

- 4 van Geel N, Vandendriessche D, Vandersichel E *et al.* Reference method for digital surface measurement of target lesions in vitiligo: a comparative analysis. *Br J Dermatol* 2019; **180**: 1198–1205.
- 5 Uitentuis SE, Bekkenk MW, van Geel N, de Rie MA, Wolkerstorfer A. UV light set-ups for vitiligo photography, a comparative study on image quality and ease of use. *J Eur Acad Dermatology Venereol* 2019; **33**: 1971–1975.
- 6 de Vet HCW, Terwee CB, Mokkink LB, Knol DL. *Measurement in Medicine: A Practical Guide*. Cambridge University Press, 2011.
- 7 Terwee CB, Bot SDM, de Boer MR *et al.* Quality criteria were proposed for measurement properties of health status questionnaires. *J Clin Epidemiol* 2007; **60**: 34–42.
- 8 Hayashi M, Okamura K, Araki Y *et al.* A novel three dimensional imaging method for the measurement of area in vitiligo and chemical leukoderma. *J Dermatol Sci* 2016; **84**: 219–221.

Supporting information

Additional Supporting Information may be found in the online version of this article:

Fig. S1 Correlations between the measured surface area (cm²) of target lesion assessment by the different measurement instruments (a) Correlation UV photography method – conventional camera method (b) Correlation UV photography method – transparent sheet method (c) Correlation UV photography method – graph paper method (d) Correlation conventional camera method – transparent sheet method (e) Correlation conventional camera method – graph paper method.

Fig. S2 Correlations between the measured surface area (cm²) of target lesion assessment using UV photography by the same physician and two different physicians (a) Intra-rater reliability. (b) Inter-rater reliability.

Fig. S3 Bland–Altman plots. Differences in the measured surface area (cm²) of target lesion assessment using the UV photography method (a) for the same physician (intra-rater reliability) (b) for different physicians (inter-rater reliability).