

Capryloyl glycine and soy isoflavonoids in hypertrichosis: An experimental and placebo-controlled clinical study

Mauro Barbareschi MD¹ | Federico Benetti MS² | Elisa Gaio MS² | Luisa Angileri MD¹ | Stefano Veraldi MD¹

¹Department of Pathophysiology and Transplantation, Università degli Studi, Foundation IRCCS Ca' Granda Ospedale Maggiore Policlinico, Milan, Italy

²European Center for the Sustainable Impact of Nanotechnology (ECSIN), ECAMRICERT SRL, Padova, Italy

Correspondence

Stefano Veraldi, Dermatology Unit, University of Milan, Via Pace 9, 20122 Milan, Italy.

Email: stefano.veraldi@unimi.it

Abstract

Background: The management of acquired hypertrichosis (HT) is based on the search of the causes and subsequent specific treatment. However, simultaneous hair removal is important. No single method for hair removal is appropriate for all patients and skin areas. Treatment options are actually limited and clinical results are often unsatisfactory. Ornithine decarboxylase 1 (ODC1), an enzyme present in hair follicles, is considered as a potential target to inhibit hair growth. Only eflornithine hydrochloride, an inhibitor of ODC1, showed to be partially effective in the management of acquired HT.

Aims: The aim of our study was to evaluate the potential inhibition of ODC1 activity by a cream containing 4% capryloyl glycine, an ODC1 inhibitor, and 1% glycine soy-fermented extract (soy isoflavonoids). Furthermore, we present the results of a placebo-controlled clinical study that evaluated the efficacy and tolerability of this cream.

Methods: The ODC1 activity was detected by measuring absorbance at 340 nm. In the presence of ODC1 inhibitors, absorbance decreases as a function of inhibition. Difluoromethylornithine (DFMO) was provided as an inhibitor control. ODC1 activity inhibition was expressed as percentage of control (untreated sample). All data were presented as mean \pm standard deviation of three independent experiments. To determine if statistically significant differences between treatments were present, a *t* test analysis was performed. The differences between groups were considered significant at $p < 0.05$. Twelve Caucasian female adult patients, with HT located on the forearms, were enrolled. The study cream (product A) was applied twice/day for four months on the right forearm. A placebo cream (product B) was applied twice/day for four months on the left forearm. Clinical efficacy was evaluated by means of macrophotography.

Results: The cream significantly inhibited ODC1 activity ($35.1 \pm 0.5\%$ inhibition, equivalent to a $64.9 \pm 0.5\%$ ODC1 activity). DFMO completely abolished the enzymatic activity ($100 \pm 5\%$ inhibition, equivalent to $0 \pm 5\%$ ODC1 activity). All patients were considered evaluable. In 11 out of 12 patients (91.7%), who were treated with

This is an open access article under the terms of the Creative Commons Attribution-NonCommercial-NoDerivs License, which permits use and distribution in any medium, provided the original work is properly cited, the use is non-commercial and no modifications or adaptations are made.

© 2021 The Authors. *Journal of Cosmetic Dermatology* published by Wiley Periodicals LLC.

product A, an improvement was observed. No improvement was observed in patients treated with product B. The global assessment showed good efficacy in 7 patients (58.3%) and moderate efficacy in 5 patients (41.7%) treated with the product A. No efficacy was detected in patients treated with product B.

Conclusions: The study cream showed to be effective in Caucasian, adult, female patients with hypertrichosis located on the forearms.

KEYWORDS

capryloyl glycine, glycine soy-fermented extract, hypertrichosis, ornithine decarboxylase 1, soy isoflavonoids

1 | INTRODUCTION

Hypertrichosis (HT) is an abnormal increase of hair for race, gender, or age of an individual, or for a specific area of the skin surface. HT may be congenital or acquired. Furthermore, it may be localized or widespread. Acquired HT may be caused by/associated with malnutrition, anorexia, hormonal diseases, polycystic ovary syndrome, porphyrias, and neoplasms. Some drugs (minoxidil, cyclosporine, phenytoin) can also cause HT.¹

The management of acquired HT is based on the search of the causes and subsequent specific treatment. However, simultaneous hair removal is important. No single method for hair removal is appropriate for all patients and skin areas. Treatment options are actually limited and clinical results are often unsatisfactory. The simplest procedures include bleaching, trimming, shaving, and the application of depilatory products.² All of them remove hair at the level of the skin surface: the duration is approximately two weeks. Epilation methods (plucking, waxing, electrosurgical epilation) remove hair from deeper levels: In these cases, the results usually last four weeks. Permanent hair removal is based on the use of lasers and intense pulse light (IPL); however, they are effective only in patients with pigmented hair, because lasers target melanin located in the lower third of the hair: Lasers are, therefore, ineffective in patients with fair hair. In addition, they are expensive.²

Ornithine decarboxylase 1 (ODC1), an enzyme present in hair follicles, is considered as a potential target to inhibit hair growth. Systemic administration of ODC1 inhibitors alters the diameter, length, and composition of hair. In human skin, topical application of an inhibitor of ODC1 reduces hair growth. The activity of ODC1 is specific to hair.^{3,4} Among topical drugs, only 13.9% eflornithine hydrochloride cream, an inhibitor of ODC1, showed to be partially effective in the treatment of acquired HT.⁵ However, clinical results are slow. Furthermore, cases of irritant contact dermatitis are not rare. Among systemic drugs, only antiandrogens are effective in promoting the "miniaturization" of hair; however, important side effects are possible. The aim of our study was to evaluate the potential inhibition of ODC1 activity by a novel cream, containing capryloyl glycine (CG), an ODC1 inhibitor, and glycine soy-fermented extract (soy isoflavonoids).

Furthermore, we present the results of a placebo-controlled clinical study that evaluated the efficacy and tolerability of this cream.

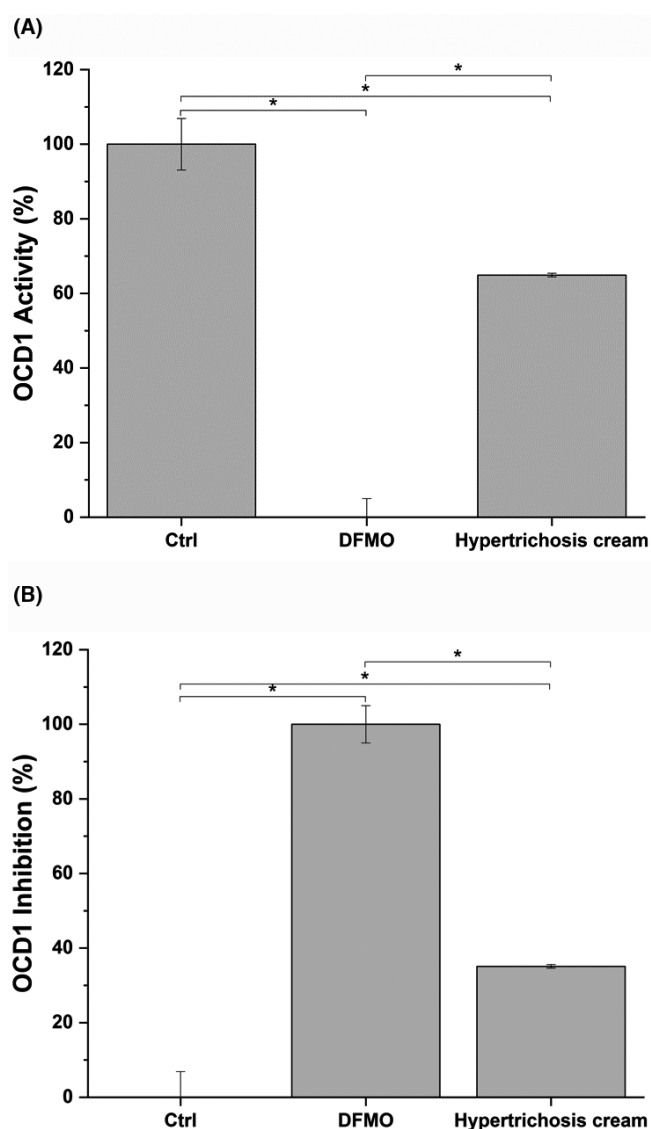


FIGURE 1 ODC1 (A) and inhibition (B) by the study cream. Ctrl: Control (untreated); DFMO: positive control; * $p < 0.05$

TABLE 1 ODC1 activity and inhibition by the study cream

	ODC1 Activity (%)	ODC1 Inhibition (%)
Ctrl	100 ± 6.9	0 ± 6.9
DFMO	0 ± 5	100 ± 5
Study cream	64.9 ± 0.5	35.1 ± 0.5

Ctrl: Control (untreated); DFMO: positive control. Results are presented as mean ± standard deviation.

2 | MATERIALS AND METHODS

The study cream contains 4% CG and 1% glycine soy-fermented extract (soy isoflavonoids).⁶ The ODC1 activity was detected by measuring absorbance at 340 nm. In the presence of ODC1 inhibitors, absorbance decreases as a function of inhibition. Difluoromethylornithine (DFMO) was provided as an inhibitor control. ODC1 activity inhibition was expressed as percentage of control

(untreated sample). All data were presented as mean ± standard deviation of three independent experiments. To determine if statistically significant differences between treatments were present, a *t* test analysis was performed. The differences between groups were considered significant at *p* < 0.05. All statistical analyses were performed with OriginalLab[®] software.

3 | PATIENTS

Twelve Caucasian (with phototypes I-III) female patients, aged 18–30 years (mean age: 22.2 years), with hypertrichosis located on the forearms were enrolled. Exclusion criteria included pregnancy, breastfeeding, hormonal abnormalities evaluated by laboratory and instrumental tests, hormonal therapies, menopause, sun exposure, and laser and/or IPL therapies in the last three months. No patient was under systemic treatments during the study period. A cream containing CG and glycine soy-fermented extract (product A) was applied twice/day for four months on the right forearm. A placebo




FIGURE 2 Patient 1. (A) Before the beginning of the study and (B) Four months later




FIGURE 3 Patient 3. (A) Before the beginning of the study and (B) Four months later




FIGURE 4 Patient 4. (A) Before the beginning of the study and (B) Four months later

cream (product B), containing all compounds of the cream except for CG and soy isoflavonoids, was applied twice/day for four months on the left forearm. Clinical efficacy was evaluated by means of macro photography with FotoFinder[®]. Photographs were made before the beginning of the study and four months later. Clinical results were defined as 0 = worsening; 1 = no change and 2 = improvement. For the global assessment, the following grading was used: 0 = no efficacy; 1 = moderate efficacy; and 2 = good efficacy. For cosmetic acceptability, the following grading was used: 1 = poor; 2 = mediocre; and 3 = good.

4 | RESULTS

The tested cream significantly inhibited ODC1 activity ($35.1 \pm 0.5\%$ reduction, equivalent to a $64.9 \pm 0.5\%$ ODC1 activity). DFMO completely abolished the enzymatic activity ($100 \pm 5\%$ inhibition, equivalent to $0 \pm 5\%$ ODC1 activity) (Figure 1; Table 1).

All patients were considered evaluable. No laboratory or instrumental abnormalities were observed. In 11 out of 12 patients (91.7%), who were treated with product A, improvement (=2) was observed (Figures 2-4). No improvement was observed in patients treated with product B. The global assessment showed the following results: good efficacy (=2) in 7 patients (58.3%) and moderate efficacy (=1) in 5 patients (41.7%) treated with the product A. No efficacy was detected in patients treated with product B. Cosmetic acceptability was judged as good (=3) by all patients. No adverse events were reported or observed in both groups of patients.

5 | DISCUSSION

CG [synonyms: 2-(otanoilamino) acetic acid and N-(1-oxooctyl)glycine and 2-octanoilaminoacetic acid] is a lipoaminoacid made up of glycine and caprylic acid, a fatty acid obtained from coconut oil. CG appears as a white, odorless powder that is almost insoluble in water, and soluble in alcohol and acetone. Molecular weight is 201.26 g/mol. Molecular formula is $C_{10}H_{19}NO_3$. CG possesses antibacterial and antimycotic activity, in particular against *Malassezia* spp.. Furthermore, CG is one of the most important compounds contained in a cream successfully used for the treatment of atopic dermatitis.⁷⁻¹⁶ CG showed to be an extremely rare irritant or sensitizer agent.¹⁷ As previously mentioned, in the study cream CG was associated with glycine soy-fermented extract (soy isoflavonoids). It was shown that two serine protease inhibitors isolated from soybeans, soybean trypsin inhibitor and Bowman-Birk protease inhibitor, decrease skin and hair pigmentation.⁶ It was also demonstrated that these compounds affect not only hair pigmentation but also the size of hair follicles and the rate of hair growth.⁶ It was hypothesized that these compounds alter the pattern of melanogenic gene expression.⁶ According to the results of our two studies, the study cream significantly inhibited ODC1 activity and showed to be effective in Caucasian, adult, female patients with hypertrichosis located on

the forearms. Furthermore, the cream seems to be effective also in females with I-III phototypes. No adverse events were reported or observed. Cosmetic acceptability was judged as good by all patients. More trials, based on a larger number of patients, are necessary in order to confirm our results.

CONFLICT OF INTEREST

None to declare.

ETHICAL STATEMENT

This study was carried out in accordance with Good Clinical Practice and the Declaration of Helsinki guidelines. Written informed consent was obtained from all study patients at the time of enrollment.

REFERENCES

1. Wendelin DS, Pope DN, Mallory SB. Hypertrichosis. *JAAD*. 2003;48:161-179.
2. Trüeb RM. Causes and management of hypertrichosis. *Am J Clin Dermatol*. 2002;3:617-627.
3. Kern AD, Oliveira MA, Coffino P, Hackert ML. Structure of mammalian ornithine decarboxylase at 1.6 Å resolution: stereochemical implications of PLP-dependent amino acid decarboxylases. *Structure*. 1999;7:567-581.
4. Auvinen M, Paasinen A, Andersson LC, Hölttä E. Ornithine decarboxylase activity is critical for cell transformation. *Nature*. 1992;360:355-358.
5. Hickman JG, Huber F, Palmisano M. Human dermal safety studies with eflornithine HCl 13.9% cream (Vaniqa), a novel treatment for excessive facial hair. *Curr Med Res Opin*. 2001;16:235-244.
6. Seiberg M, Liu JC, Babiarz L, et al. Soy milk reduces hair growth and hair follicle dimensions. *Exp Dermatol*. 2001;10:405-413.
7. Belloni G, Pinelli S, Veraldi S. A randomized, double-blind, vehicle-controlled study to evaluate the efficacy and safety of MAS063D in the treatment of mild to moderate atopic dermatitis. *JEADV*. 2004;18(Suppl. 2):379.
8. Belloni G, Pinelli S, Veraldi S. A randomised, double-blind, vehicle-controlled study to evaluate the efficacy and safety of MAS063D (Atopiclair) in the treatment of mild to moderate atopic dermatitis. *Eur J Dermatol*. 2005;15:31-36.
9. Abramovits W, Hebert A, Boguniewicz M. A multicenter randomized, vehicle-controlled, double-blind clinical study to examine the safety and efficacy of MAS063DP in the management of AD. *JAAD*. 2006;54(Suppl):AB84.
10. Abramovits W, Boguniewicz M. Adult Atopiclair Study Group. A multicenter, randomized, vehicle-controlled clinical study to examine the efficacy and safety of MAS063DP (Atopiclair) in the management of mild to moderate atopic dermatitis in adults. *J Drugs Dermatol*. 2006;5:236-244.
11. Boguniewicz M, Zeichner JA, Eichenfield LF, et al. MAS063DP is effective monotherapy for mild to moderate atopic dermatitis in infants and children: a multicenter, randomized, vehicle-controlled study. *J Pediatr*. 2008;152:854-859.
12. Abramovits W, Hebert AA, Boguniewicz M, et al. Patient-reported outcomes from a multicenter, randomized, vehicle-controlled clinical study of MAS063DP (Atopiclair) in the management of mild-to-moderate atopic dermatitis in adults. *J Dermatol Treat*. 2008;19:327-332.
13. Veraldi S, De Micheli P, Schianchi R, Lunardon L. Treatment of pruritus in mild-to-moderate atopic dermatitis with a topical non-steroidal agent. *J Drugs Dermatol*. 2009;8:537-539.
14. Yates JE, Phifer JB, Flake D. Clinical inquiries. Do nonmedicated topicals relieve childhood eczema? *J Fam Pract*. 2009;58:280-281.

15. Miller DW, Koch SB, Yentzer BA, et al. An over-the-counter moisturizer is as clinically effective as, and more cost-effective than, prescription barrier creams in the treatment of children with mild-to-moderate atopic dermatitis: a randomized, controlled trial. *J Drugs Dermatol*. 2011;10:531-537.
16. Tang MB, Leong KF, Ou LS, et al. Cost-effectiveness study of pediatric atopic dermatitis in Asia: Atopiclair vs. regular emollient (AD-ATOP). *J Drugs Dermatol*. 2015;14:169-175.
17. Mangodt EA, Dendooven E, De Fré C, et al. Capryloyl glycine: a polyfunctional cosmetic ingredient and potential skin sensitizer. *Contact Dermatitis*. 2019;80:400-402.

How to cite this article: Barbareschi M, Benetti F, Gaio E, Angileri L, Veraldi S. Capryloyl glycine and soy isoflavonoids in hypertrichosis: An experimental and placebo-controlled clinical study. *J Cosmet Dermatol*. 2021;20(Suppl 1):18-22. <https://doi.org/10.1111/jocd.14096>