



## Case report

# Familial exudative retinopathy *TSPAN12* positive presenting as bilateral retinal stalks: late structural and functional findings



Giulia M. Amorelli<sup>a</sup>, Marco H. Ji<sup>a,b</sup>, Lorenzo Orazi<sup>c</sup>, Fernando Molle<sup>a</sup>, Domenico Lepore<sup>a,\*</sup>

<sup>a</sup> Department of Ophthalmology, Catholic University of Sacred Heart, Rome, Italy

<sup>b</sup> Byers Eye Institute, Department of Ophthalmology, Stanford University School of Medicine, Palo Alto, CA, USA

<sup>c</sup> Italian National Center of Services and Research for Prevention of Blindness and Rehabilitation of the Visually Impaired, Rome, Italy

## 1. Introduction

Familial exudative vitreoretinopathy (FEVR) is a rare genetic disease characterized by an incomplete development of the retinal vasculature due to genetic mutations in the Wnt pathway.<sup>1</sup> It is most commonly diagnosed in newborns with no history of prematurity or oxygen supplementation and with a positive family history. No other predisposing factors are known for the development of FEVR. The condition usually occurs bilaterally with asymmetric ocular involvement.

The differentiation of FEVR from other pediatric retinal vascular abnormalities can be a challenge. For instance, the fundus appearance may be similar to that of persistent hyperplastic primary vitreous (PHPV),<sup>2</sup> also known as persistent fetal vasculature (PFV), a developmental anomaly of incomplete or absent hyaloid artery regression leading to varying degrees of visual impairment. Usually, ocular involvement in PFV is unilateral and obvious microphthalmos is present, whereas bilateral cases are rare and ordinarily associated with other systemic conditions. In turn, the stalk in PFV can superficially resemble the retinal fold seen in FEVR, although the former runs directly from the disc to the center of the posterior aspect of the lens, whereas in FEVR it runs from the optic disc to the peripheral retina.

We present the case of a 9-year-old child who was diagnosed as having bilateral PFV on fundus appearance and wide-angle fundus fluorescein angiography but was later found to have a genetic mutation in the Wnt signaling pathway suggestive of FEVR.

## 2. Case report

A 9-year-old male child was referred for bilateral leukocoria to the pediatric retina service at “Agostino Gemelli” University Hospital (Rome, Italy) for consultation. The child was born at full term and had negative family history for ocular diseases. Both parents underwent ophthalmologic evaluations and no retinal abnormalities were found. On clinical examination, the child was able to fix and follow with each eye and showed reduced pupillary response to light (both direct and

consensual). Nystagmus without a null point was present. ETDRS monocular testing showed a similar best corrected visual acuity (BVCA) of 1.3 logMAR in each eye. Anterior segment examination showed horizontal corneal diameters of 11.8 mm in the right eye and 11.9 mm in the left, and localized opacification of the capsule in an otherwise clear lens. Fundus examination revealed bilateral fibrovascular stalks connecting the optic disk head to the lens with dragging of retinal vessels (Fig. 1). At a subsequent examination under anesthesia, digital retinal imaging using the RetCam III (Natus Medical Incorporated, Pleasanton, CA) revealed bilateral fibrovascular stalks (Fig. 1). In the right eye the stalk ran temporally from the optic disk to the posterior aspect of the lens leading to opacification of the latter. In the left eye the stalk was infero-temporally stretched resulting in a more peripheral posterior capsular opacification. FA allowed for visualization of patent vessels running along the stalk and branching on the posterior lens capsule. Bilateral retrolental membranes composed of a fine capillary arborization and bridging fibrous material were observed. The macula was clearly included in the fold in the right eye and infero-temporally stretched into the fold in the left eye. Therefore, the foveal avascular zone was not identifiable in neither eye. Ischemic tissue within the areas of the vascularized retina, patchy perivascular hyperreflectivity and defective peripheral vascularization with no signs of exudation were observed.

Optical coherence tomography exam was performed using Envisu C2300 (Bioptigen, Durham, NC), but low-quality images were obtained due to the capsular opacities and shadowing from the stalks. A diffuse hyper-reflectivity of the internal limiting membrane was observed but a foveal depression was not detected. A scan centered on the stalk showed an abrupt interruption of retinal layers with fibrous tissue rising from the optic nerve head in a cone-shaped manner.

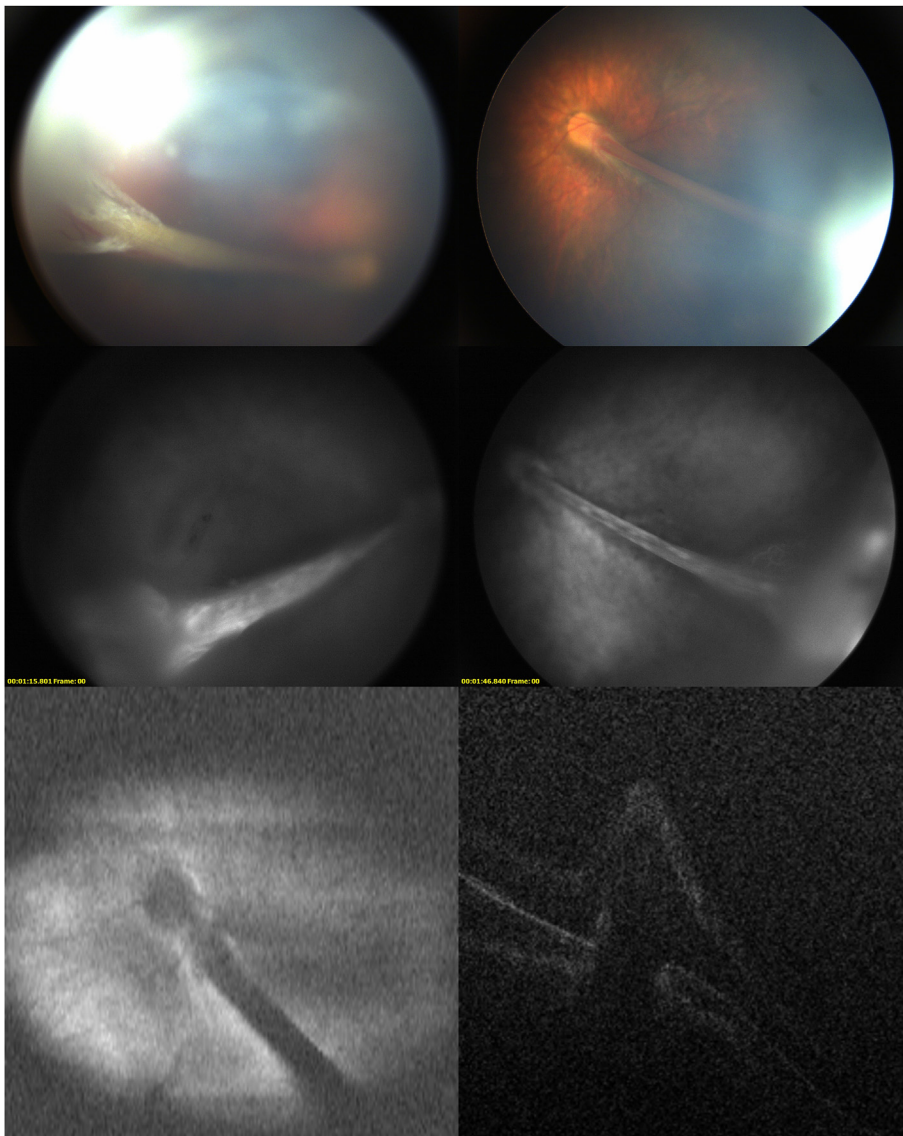
Genetic testing revealed a new heterozygous mutation in the *TSPAN12* gene (IVS2 c.67-2A > G), supporting the diagnosis of FEVR.

The child underwent subsequent cataract extraction with intraocular lens implantation bilaterally. The fibrovascular stalks were left in place because they did not obstruct the visual axis.

Currently, BVCA has improved to 1.0 logMAR and the nystagmus

\* Corresponding author. Dept Ophthalmology, Catholic University of Sacred Heart, Largo Francesco Vito 8, 00168, Rome, Italy.

E-mail address: [domenico.lepore@unicatt.it](mailto:domenico.lepore@unicatt.it) (D. Lepore).



**Fig. 1.** Digital retinal imaging of the eyes of the patient. Wide-angle fundus color photographs of the (top left) right eye and (top right) left eye show a fibrovascular stalk drawing up the retina around the optic nerve in either eye extending from the optic disc toward the posterior aspect of the lens capsule. Fluorescein angiograms obtained at an early phase of the (middle left) right eye and of the (middle right) left eye showed additional vascular features. Hyperfluorescence throughout the stalk demonstrates the prominent fibrovascular features. Optical coherence tomography (SLO bottom left, B-scan bottom right) showed the papillary insertion of the stalk. (For interpretation of the references to color in this figure legend, the reader is referred to the Web version of this article.)

was unchanged.

### 3. Discussion

Familial exudative vitreoretinopathy (FEVR) is a hereditary vitreoretinal disorder first described by Schepens and Criswick in 1969. They were the first to observe the overlapping fundoscopic characteristics of FEVR and other pediatric vitreoretinopathies, noting the challenging differential diagnosis in children affected by this disease. Understanding the genetic abnormalities found in FEVR has made it possible to study the relationship between distinct, but clinically similar conditions with incomplete retinal vascular development and possible neovascularization, tractional alterations or exudative activity.<sup>3</sup> FEVR, Norrie's disease, retinopathy of prematurity<sup>4</sup> and PFV<sup>5</sup> have been associated with different mutations in genes of the Wnt pathway: *FZD4* (frizzled 4), *LRP5* (low density lipoprotein receptor-like protein 5), *NDP* (Norrie disease pseudoglioma) and *TSPAN12* (tetraspanin 12). Recently, a novel mutation in the gene *ZNF408* (Zinc Finger Protein 408) has been associated with the development of the disease in a large Chinese cohort of FEVR patients.<sup>6</sup> Robitaille et al. reported overlapping retinal features between FEVR and Microcephaly, Lymphedema, and Chorioretinal Dysplasia in patients with a mutation in the *KIF11* gene (Kinesin Family Member 11).<sup>7</sup> Our patient was found to have a sporadic

mutation in the *TSPAN12* gene, encoding for a protein of the tetraspanin family. *TSPAN12* has been found to be correlated to autosomal dominant FEVR<sup>8</sup> and mutation of *TSPAN12* gene in mice model showed a phenotype similar to FEVR.<sup>9</sup> None of the proband's family members were found to have genetic mutations, nor they did present with any ophthalmic anomaly. A paternity test was also performed. To date, mutations of this gene have been linked to autosomal dominant and autosomal recessive FEVR and Norrie's disease.<sup>10</sup> Unfortunately, few data are available to date about the frequency of the *TSPAN12* mutation in the general population and its correlation with FEVR phenotypes.

Few cases have been reported in the literature of unusual presentation of FEVR as PFV, with either bilateral<sup>11</sup> or unilateral involvement. Kartchner JZ and Hartnett ME<sup>12</sup> reported the case of a child with another mutation consistent with FEVR who presented with unilateral retinal detachment and bilateral peripheral retinal exudation, thus showing a clinical appearance consistent with PFV.

Considering the 2011 classification of FEVR,<sup>1</sup> the fundoscopic and angiographic findings of this patient are not characteristic for this disease. The case here presented exhibited bilateral stalks with patent vessels extending from the optic nerve head to the posterior capsule of the lens without signs of exudation and an appearance more consistent with PFV.

#### 4. Conclusions

FEVR can manifest clinically with a wide range of findings. Further investigation is needed to understand the incidence and linkage of mutations in the Wnt pathway or in other yet unknown genes. It appears that the manifestations of FEVR and PFV seen in this patient may indeed represent a spectrum of the same genetic disorder.

#### Acknowledgements

None.

#### Appendix A. Supplementary data

Supplementary data to this article can be found online at <https://doi.org/10.1016/j.ajoc.2019.100480>.

#### Patient consent

Consent to publish the case report was not obtained. This report does not contain any personal information that could lead to the identification of the patient.

#### Funding

No funding or grant support.

#### Conflicts of interest

No financial disclosures.

#### Authorship

All authors attest that they meet the current ICMJE criteria for Authorship.

#### References

- Ranchod TM, Ho LY, Drener KA, Capone A, Trese MT. Clinical presentation of familial exudative vitreoretinopathy. *Ophthalmology*. 2011;118(10):2070–2075. <https://doi.org/10.1016/j.ophtha.2011.06.020>.
- Robitaille JM, Wallace K, Zheng B, et al. Phenotypic overlap of familial exudative vitreoretinopathy (FEVR) with persistent fetal vasculature (PFV) caused by FZD4 mutations in two distinct pedigrees. *Ophthalmic Genet*. 2009;30(1):23–30. <https://doi.org/10.1080/13816810802464312>.
- Kondo H. Complex genetics of familial exudative vitreoretinopathy and related pediatric retinal detachments. *Taiwan J Ophthalmol*. 2015;5(2):56–62. <https://doi.org/10.1016/j.tjo.2015.04.002>.
- Kondo H, Kusaka S, Yoshinaga A, Uchio E, Tawara A, Tahira T. Genetic variants of FZD4 and LRP5 genes in patients with advanced retinopathy of prematurity. *Mol Vis*. 2013;19(February):476–485. <http://www.ncbi.nlm.nih.gov/pubmed/23441120>, Accessed date: 11 March 2018.
- Prasov L, Masud T, Khaliq S, et al. ATOH7 mutations cause autosomal recessive persistent hyperplasia of the primary vitreous. *Hum Mol Genet*. 2012;21(16):3681–3694. <https://doi.org/10.1093/hmg/dds197>.
- Rao F-Q, Cai X-B, Cheng F-F, et al. Mutations in LRP5, FZD4, TSPAN12, NDP, ZNF408, or KIF11 genes account for 38.7% of Chinese patients with familial exudative vitreoretinopathy. *Investig Ophthalmology Vis Sci*. 2017;58(5):2623. <https://doi.org/10.1167/iovs.16-21324>.
- Robitaille JM, Gillett RM, LeBlanc MA, et al. Phenotypic overlap between familial exudative vitreoretinopathy and microcephaly, Lymphedema, and chorioretinal Dysplasia caused by KIF11 mutations. *JAMA Ophthalmol*. 2014;132(12):1393. <https://doi.org/10.1001/jamaophthalmol.2014.2814>.
- Poulter JA, Ali M, Gilmour DF, et al. Mutations in TSPAN12 cause autosomal-dominant familial exudative vitreoretinopathy. *Am J Hum Genet*. 2010;86(2):248–253. <https://doi.org/10.1016/j.ajhg.2010.01.012>.
- Junge HJ, Yang S, Burton JB, et al. TSPAN12 regulates retinal vascular development by promoting norrin- but not wnt-induced FZD4/ $\beta$ -catenin signaling. *Cell*. 2009;139(2):299–311. <https://doi.org/10.1016/j.cell.2009.07.048>.
- Toomes C, Bottomley HM, Scott S, et al. Spectrum and frequency of FZD4 mutations in familial exudative vitreoretinopathy. *Investig Ophthalmol Vis Sci*. 2004;45(7):2083–2090. <https://doi.org/10.1167/iovs.03-1044>.
- Jain TP. Bilateral persistent hyperplastic primary vitreous. *Indian J Ophthalmol*. 2009;57(1):53–54. <http://www.ncbi.nlm.nih.gov/pubmed/19075412>, Accessed date: 9 April 2018.
- Kartchner JZ, Hartnett ME. Familial exudative vitreoretinopathy presentation as persistent fetal vasculature. *Am J Ophthalmol Case Reports*. 2017;6:15–17. <https://doi.org/10.1016/j.ajoc.2017.01.001>.