

Successful Treatment of Persistent Hypoxemia by Nasal Suctioning in a Neonate with Primary Ciliary Dyskinesia

Sonia L. Molchan, Daniel P. Hsu

Department of Pediatrics, San Antonio Military Medical Center, 3551 Roger Brooke Drive, Fort Sam Houston, TX 78234, USA

ABSTRACT

Primary ciliary dyskinesia (PCD) is a genetic disorder that manifests clinically with chronic sinopulmonary and otologic disease. Despite the majority of patients presenting with respiratory symptoms in the neonatal period, the diagnosis is often delayed until several years of age. We report the case of a 5-day-old male who was diagnosed with PCD by electron microscopic evaluation of cilia obtained from nasal brush biopsy. This case also demonstrated the successful treatment of persistent hypoxemia with frequent nasal suctioning.

Key words:

Hypoxemia, neonatal respiratory distress, primary ciliary dyskinesia

INTRODUCTION

The patient was an infant male born at 38 and 5/7 weeks estimated gestational age to a healthy 29-year-old woman following an uncomplicated pregnancy. Family history was notable for an older brother with Kartagener Syndrome. Delivery was uneventful with APGAR scores of 9 and 9. The patient was noted to have an intermittent moist cough several hours following birth, with rhonchi transmitted from the upper airway audible throughout all lung fields. A chest radiograph (CXR) obtained on hospital day 1 was unremarkable. Discharge home was anticipated on hospital day two.

Pulse oximetry was obtained during the discharge physical exam and the patient was noted to be hypoxemic with an oxygen saturation of 88%. Respiratory rate varied between 40 and 55 breaths per minute. There was no evidence of accessory respiratory muscle use. Auscultation of the chest revealed normal breath sounds and no evidence of a cardiac murmur. The rest of the physical examination was unremarkable.

CASE REPORT

The infant was admitted to the level two nursery and further diagnostic evaluations were obtained. Repeat CXR showed no evidence of pulmonary disease. Complete blood count, cerebral spinal fluid (CSF) cell count, and venous blood gas were within normal limits. Blood and CSF cultures were negative for infectious organisms. An electrocardiogram, hyperoxia test, and echocardiogram were within normal limits. Antibiotics were started empirically for a presumed neonatal pneumonia, but were discontinued after 6 days due to negative culture results and a lack of clinical change during the course of antibiotic therapy. Supplemental

oxygen was provided via nasal cannula at an initial flow rate of 2 liters per minute (LPM). However, this decreased to 0.5 LPM by hospital day 4. The patient did not tolerate multiple attempts to wean to room air.

Pediatric pulmonology consultation was obtained on hospital day 5 and a nasal brush biopsy of the inferior turbinate was obtained for electron microscopy (EM) analysis of the cilia. A 3.0-mm disposable cytology brush was used to obtain the nasal epithelial sample from the right nares. Nasal suctioning with saline drops and chest physiotherapy (CPT) was recommended. CPT was discontinued after 1 day due to the lack of clinical response. Nasal suctioning, performed with a 10 French catheter advanced 4–6 cm into each nare, repeatedly obtained thick nasal secretions. The patient began to tolerate trials of room air immediately following nasal suctioning with progressive clinical improvement as nasal suctioning was performed initially every 4 hours and spaced to every six hours. Neither oxygen desaturation nor other complications were noted during the nasal suctioning procedure. Supplemental

Address for correspondence:

Dr. Daniel P. Hsu,
Department of Pediatrics, San Antonio Military Medical Center, 3551
Roger Brooke Drive, Fort Sam Houston, TX 78234, USA.
E-mail: daniel.hsu@us.army.mil

Access this article online

Quick Response Code:



Website:

www.jcnonweb.com

DOI:

10.4103/2249-4847.96774

oxygen was permanently discontinued 60 hours after nasal suctioning was first initiated, with pulse oximetry recordings consistently above 95% on room air. The patient was discharged home on day 11 of life with instructions to continue nasal suctioning four times daily. Results of the EM studies were available on the day of discharge and confirmed the diagnosis of primary ciliary dyskinesia (PCD), noted by the absence of inner dynein arms [Figure 1].

DISCUSSION

PCD is a predominantly autosomal recessive inherited disorder that renders ciliary processes in the body ineffective. This leads to dysfunction in mucus clearance in the sinopulmonary tracts, recurrent otitis media, and male infertility. Defective embryonic cilia result in random lateralization of the viscera with approximately 50% of cases having situs inversus or other forms of heterotaxy.^[1] Rarely, patients can demonstrate hydrocephalus, esophageal atresia, or biliary atresia.^[2] The estimated prevalence of PCD is 1 in 15–30,000 live births; however, due to underdiagnosis this is likely an underestimate.^[3]

Review of the literature and previous case reports presents early neonatal diagnosis almost exclusively in patients with a finding of some form of situs inversus on prenatal ultrasound or neonatal CXR.^[4–6] Despite more than 75% of full-term neonates with PCD having symptoms of neonatal respiratory distress in the first few days of life, it is the latter physical finding in the neonatal period that usually leads to the suspicion and ultimate testing for the disease.^[7] Even so, in a review of the age at diagnosis and the symptom history of children with PCD in a pediatric PCD clinic in the UK, Coren *et al.* calculated the mean age of diagnosis to be 6 years in cases that lacked situs inversus and still 4.4 years in those children with this known lateralization defect.

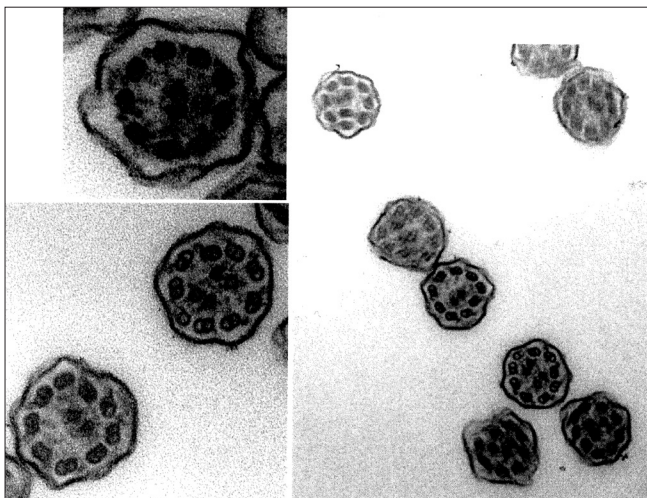


Figure 1: Electron micrograph of ciliary ultrastructure from nasal brush biopsy showing missing inner dynein arms

Our patient showed a normal left-sided cardiac silhouette on CXR and echocardiogram with normal structure of the heart. However, his older sibling was previously diagnosed with Kartagener Syndrome (PCD with situs inversus), giving practitioners in this case a higher index of suspicion for PCD in the patient.

While it has been noted for over 30 years that PCD should be recognized in the differential diagnosis for neonatal respiratory distress, testing and diagnosis are consistently delayed sometimes into adulthood.^[1,6] Diagnosis of PCD by nasal biopsy has been previously reported.^[3–5] Nasal brush sampling is a relatively noninvasive means for obtaining ciliated epithelium for EM analysis and does not require sedation. It is a simple test that should be performed when PCD is considered in the differential diagnosis of neonatal respiratory distress. Although there is a paucity of research demonstrating conclusive cause and effect, general consensus suggests that failure to diagnose and treat PCD can lead to progressive and permanent lung damage due to repeated infections and obstruction of airways leading to bronchiectasis.^[7,8] Other complications of this disorder include chronic otitis media, rhinosinusitis, atypical asthma, and pneumonia.^[5] Early diagnosis and, therefore, treatment can be paramount to decrease morbidity in this condition as this case demonstrates.

We report here a case of a neonate with PCD as the underlying cause of persistent hypoxemia. Rhinosinusitis with thickened nasal secretions is a hallmark of PCD. This case demonstrates that onset of rhinosinus disease can occur soon after birth. The combination of relatively narrow nasal passages along with obligate nasal breathing in neonates likely contributed to nasal airflow obstruction. Persistent hypoxemia was the only significant finding that led to a prolonged hospital course in this patient. Frequent nasal suctioning with saline drops proved to be successful treatment for the persistent hypoxemia. Caution should be used when performing frequent nasal suction. Mucosal edema, trauma, bradycardia, and laryngospasm are known complications from nasal suctioning.^[9] However, when used judiciously, nasal suctioning can be an effective treatment for nasopharyngeal obstruction caused by thickened secretions. To our knowledge, this is the first report that describes the successful treatment of hypoxemia in a neonate with PCD.

In summary, patients with PCD may present with a wide spectrum of respiratory signs and symptoms in the neonatal period. The diagnosis of PCD should be considered in any neonate with unexplained persistent respiratory findings. Nasal congestion with airflow limitation and subsequent hypoxemia may be a manifestation of PCD in the neonate, which improves with nasal suctioning.

REFERENCES

- O'Callaghan C, Chilvers M, Hogg C, Bush A, Lucas J. Diagnosing primary ciliary dyskinesia. *Thorax* 2007;62:656-7.
- Gemou EV, Warner JO, Bush A. New associations of primary dyskinesia syndrome. *Pediatr Pulmonol* 1993;16:9-12.
- Bush A, Cole P, Hariri M, Mackay I, Phillips G, O'Callaghan C, *et al*. Primary ciliary dyskinesia: Diagnosis and standards of care. *Eur Respir J* 1998;12:982-8.
- Ramet J, Byloos J, Deiree M, Sacre L, Clement P. Neonatal diagnosis of the immotile cilia syndrome. *Chest* 1986;90:138-40.
- Tanzeema H, Kappelman M, Perez-Atayde AR, Young GJ, Huttner KM, Christou H. Primary ciliary dyskinesia as a cause of neonatal respiratory distress: Implications for the neonatologist. *J Perinatol* 2003;23:684-7.
- Whitelaw A, Evans A, Corrin B. Immotile cilia syndrome: A new cause of neonatal respiratory distress. *Arch Dis Child* 1981;56:432-5.
- Coren ME, Meeks M, Buchdahl RM, Buchdahl RM, Bush A. Primary ciliary dyskinesia: Age at diagnosis and symptom history. *Acta Paediatr* 2002;91:667-9.
- Meeks M, Bush A. Primary ciliary dyskinesia (PCD). *Pediatr Pulmonol* 2002;29:307-16.
- Czarnecki ML, Kaucic CL. Infant nasal-pharyngeal suctioning: Is it beneficial? *Pediatr Nurs* 1999;25:193-6, 218.

How to cite this article: Molchan SL, Hsu DP. Successful treatment of persistent hypoxemia by nasal suctioning in a neonate with primary ciliary dyskinesia. *J Clin Neonatol* 2012;1:98-100.

Source of Support: Nil, **Conflict of Interest:** None declared.

New features on the journal's website

Optimized content for mobile and hand-held devices

HTML pages have been optimized of mobile and other hand-held devices (such as iPad, Kindle, iPod) for faster browsing speed.

Click on [**Mobile Full text**] from Table of Contents page.

This is simple HTML version for faster download on mobiles (if viewed on desktop, it will be automatically redirected to full HTML version)

E-Pub for hand-held devices

EPUB is an open e-book standard recommended by The International Digital Publishing Forum which is designed for reflowable content i.e. the text display can be optimized for a particular display device.


Click on [**EPub**] from Table of Contents page.

There are various e-Pub readers such as for Windows: Digital Editions, OS X: Calibre/Bookworm, iPhone/iPod Touch/iPad: Stanza, and Linux: Calibre/Bookworm.

E-Book for desktop

One can also see the entire issue as printed here in a 'flip book' version on desktops.

Links are available from Current Issue as well as Archives pages.

Click on  View as eBook