

Durable Responses in Patients With Advanced Cholangiocarcinoma on Sequential Dual-agent Immunotherapy After Progressing on Single-agent Immunotherapy

Dalia Kaakour, MD,* Garo Hagopian, MD,* Sonia Lee, MD,†
and Fa Chyi Lee, MD‡

Objectives: Biliary tract tumors have a poor prognosis despite advancements in targeted therapies. More recent studies have started to investigate the use of combination immunotherapy in advanced biliary cancers. However, currently, there are no clinical trials investigating the use of dual-agent immunotherapy with ipilimumab and nivolumab as a sequential treatment after patients have progressed on single-agent immunotherapy. In this case series, we discussed 3 patients with advanced cholangiocarcinoma who have an objective response to dual-agent immunotherapy with ipilimumab and nivolumab after having disease progression on pembrolizumab and multiple other failed lines of treatment.

Materials and Methods: A case series, including 3 patients treated at the University of California, Irvine Chao Family Comprehensive Cancer Center, was completed.

Results: Although none of the 3 patients had microsatellite instability or high tumor-mutation burden and were not necessarily predicted to have a response to dual-agent immunotherapy, all 3 patients had an objective radiographic and/or tumor-marker response to a combination of ipilimumab and nivolumab.

Conclusions: This case series serves as proof of the concept that sequential immunotherapy can be beneficial after progression on single-agent immunotherapy for patients with advanced cholangiocarcinoma. This study can also serve as the foundation to build further tests on the true effectiveness and ideal duration of sequential therapy with dual immunotherapy agents.

Key Words: metastatic cholangiocarcinoma, immunotherapy, durable responses, sequential dual agent

(*Am J Clin Oncol* 2022;45:410–414)

Biliary tract tumors have an incredibly poor prognosis due to their often late diagnosis at advanced stages, with limited treatment options available.¹ Median survival is estimated to be <2 years, and the survival rate is estimated to be <10%.² There

has been minimal improvement in prognosis over the past several decades despite advancements in precision treatment.³ Patients on the current first-line chemotherapy regimen with cisplatin and gemcitabine have an overall survival of ≈1 year.^{4,5} In recent years immunotherapy has become a mainstay in the treatment of several malignancies such as melanoma, renal cell carcinoma, colorectal cancer, and non-small cell lung carcinoma.^{2,6} This has prompted investigations of the effects of immunotherapy on gallbladder cancers. For example, it was recently shown that adding durvalumab to the standard gemcitabine and cisplatin regimen significantly improved overall survival, progression-free survival, and objective response rate, without exacerbating toxicity.⁷ In addition, in recent clinical trials KEYNOTE-028 and KEYNOTE-158, pembrolizumab was shown to have anti-tumor activity in 6% to 13% of patients with advanced biliary-tract tumors regardless of programmed cell death ligand 1 (PD-L1) expression.⁸ Nivolumab was also shown to have modest efficacy with durable response in patients with refractory biliary-tract tumors.⁹ More recent studies have investigated the use of combination immunotherapy in advanced biliary cancers. One such phase II clinical study using a combination of ipilimumab and nivolumab demonstrated an objective response rate of 23%, disease control rate of 44%, progression-free survival of 2.9 months, and overall survival of 5.7 months in patients with advanced biliary cancers.¹⁰ Interestingly, there are no clinical trials or studies on the use of dual-agent immunotherapy with ipilimumab and nivolumab as sequential treatment after patients have progressed on single-agent immunotherapy. In this case series, we reported 3 cases, in which patients had an objective response to dual-agent immunotherapy with ipilimumab and nivolumab after disease progression on pembrolizumab.

MATERIALS AND METHODS

Three patients with metastatic cholangiocarcinoma whose disease progressed on at least 3 prior lines of therapy including cisplatin+gemcitabine, irinotecan+capecitabine, and single-agent immunotherapy with pembrolizumab were all subsequently treated with dual checkpoint inhibitor therapy with ipilimumab (ipi) +nivolumab (nivo). All 3 patients were treated at the University of California, Irvine Chao Family Comprehensive Cancer Center.

RESULTS

In summary, all 3 patients progressed on single-agent immunotherapy with pembrolizumab yet responded to and continue to respond to dual-agent immunotherapy to date. Patients 1 and 3, each did not show documented benefit on serial imaging after starting pembrolizumab 200 mg every 3 weeks, and both

From the *Department of Medicine; †Department of Radiological Sciences; and ‡Division of Hematology/Oncology, Department of Medicine, University of California Irvine, Irvine, CA.

The authors declare no conflicts of interest.

Correspondence: Dalia Kaakour, MD, Department of Medicine, University of California, 333 The City Boulevard West, Suite 400, Orange, CA 92868. E-mail: dkaakour@hs.uci.edu.

Copyright © 2022 The Author(s). Published by Wolters Kluwer Health, Inc.

This is an open access article distributed under the terms of the Creative Commons Attribution-Non Commercial-No Derivatives License 4.0 (CCBY-NC-ND), where it is permissible to download and share the work provided it is properly cited. The work cannot be changed in any way or used commercially without permission from the journal.

ISSN: 0277-3732/22/4510-0410

DOI: 10.1097/COC.0000000000000941

TABLE 1. Patient’s Baseline Characteristics

Case	Age (y)	Sex	Primary	Site of Metastases	PD-L1	Immunotherapy*	Months Since Diagnosis	Best Response to Immunotherapy
Case 1	67	Male	Cholangiocarcinoma	Liver, lung, lymph nodes	0	ipi (low-dose)+nivo	34	Partial response
Case 2	64	Female	Cholangiocarcinoma	Liver, adnexa, omentum, peritoneum, lymph nodes	NA	ipi+nivo	39	Partial response
Case 3	63	Male	Cholangiocarcinoma	Liver, bone, lung, pleura	NA	ipi+nivo	43	Partial response

*Most recent regimen, does not include prior regimens. ipi indicates ipilimumab; NA, not available; nivo, nivolumab.

completed just 3 cycles. Patient 2 showed initial documented clinical benefit on serial imaging after starting on pembrolizumab 200 mg every 3 weeks and completed 27 cycles before progressing. The patients’ characteristics are listed in Table 1.

We followed tumor markers sequentially. Case 2 showed the most dramatic drop with treatment. As shown in Figure 1.

Case 1

Case 1 was a male patient in his mid-60s with metastatic cholangiocarcinoma to the liver, lung, and lymph nodes diagnosed in June 2019. His molecular profiling showed microsatellite-stable disease, and a PD-L1 of 0 (Caris Life Science). The patient progressed after multiple lines of treatment including (in sequential order) capecitabine, cisplatin+gemcitabine, pembrolizumab (February 14, 2020 to April 4, 2020, 3 treatments), folinic acid+fluorouracil+oxaliplatin (FOLFOX), and irinotecan+capecitabine. Hospice was discussed with the patient upon progressing on irinotecan+capecitabine, however, he asked for 1 more attempt in treatment. He started on ipilimumab (3 mg/kg)+nivolumab (1 mg/kg) every 21 days on

August 30, 2020. The dose of ipilimumab was later reduced to 2 mg/kg due to the periodic elevation of liver enzymes. Subjective response with resolution of abdominal pain was noted after the first 2 treatments. The objective response was confirmed with a computed tomography (CT) scan after the third treatment. Sequential CT about 9 months into treatment did note that 1 retroperitoneal lymph node was slowly enlarging whereas all other known sites of the disease continued to show excellent response to treatment. In consultation with radiation oncology, the decision was to proceed with stereotactic body radiotherapy (SBRT) to this 1 growing retroperitoneal lymph node in hopes of introducing neoantigens. After completion of radiation, he received 4 more cycles of a higher dose of ipilimumab (3 mg/kg)+nivolumab (1 mg/kg) with the goal of boosting the antigen-presenting part of the checkpoint-inhibitor response. He was then hospitalized for fulminant hepatic failure after the fourth treatment. He improved with high-dose steroids followed by a steroid taper for 6 weeks and continued low-dose ipilimumab (1 mg/kg)+nivolumab (1 mg/kg) every 3 weeks to date (twenty-seventh treatment on June 6, 2022), with a

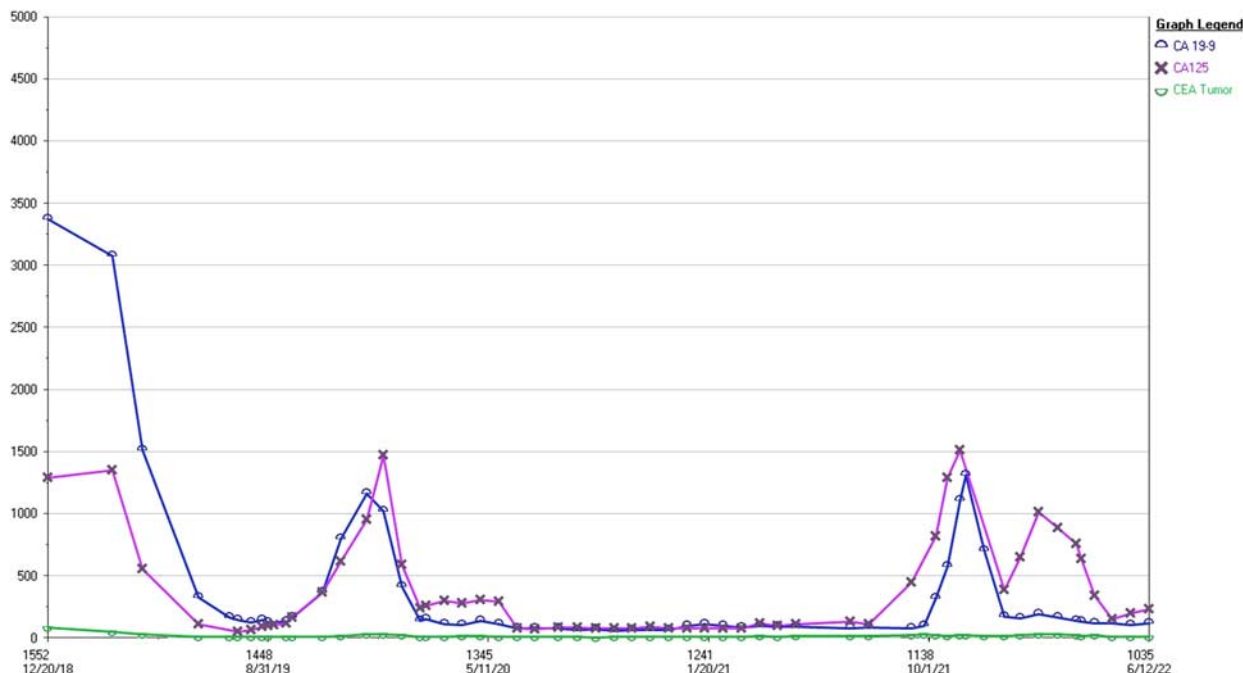


FIGURE 1. Tumor markers over time in case 2. [full color online](#)

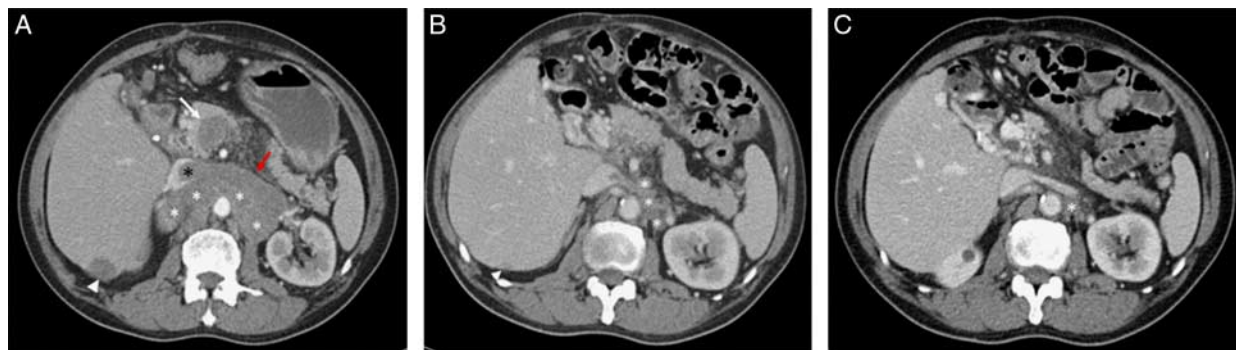

FIGURE 2. Case 1 computed tomography (CT) scans over treatment course. A, CT axial image with intravenous contrast performed 14 months after initial diagnosis and 4 days before dual immunotherapy implementation demonstrates right lobe metastasis (white arrowhead) and retroperitoneal lymphadenopathy (white *) with left renal vein tumor thrombus (red arrow) extending to IVC (black *) and portal vein tumor thrombus (white arrow) extending from peripancreatic lymphadenopathy not included in the image. B, Axial image of CT abdomen performed 19 months after initial staging, and 5 months after dual immunotherapy demonstrates significant interval decrease in size of right posterior liver metastasis (white arrowhead), retroperitoneal lymphadenopathy (white *) and complete resolution of left renal vein and portal vein tumor thrombus with trace residual fibrotic tissue. C, Axial CT abdomen 33 months after initial staging, 19 months after initiation of dual immunotherapy, and 9 months after SBRT to retroperitoneal lymphadenopathy demonstrate further decrease in retroperitoneal lymphadenopathy size (white *), and complete resolution of renal vein and portal vein thrombus. Right hepatic lobe metastasis remained significantly smaller since initiation of dual immunotherapy, and morphologically consistent with posttreatment change (not included in the imaging field). full color online

continued objective response on CT scan on all known metastatic sites (Fig. 2).

Case 2

Case 2 was a female patient in her early-60s with metastatic cholangiocarcinoma to the liver, adnexa, omentum, peritoneum, and lymph nodes diagnosed in January 2019. Her molecular profiling showed microsatellite-stable disease and isocitrate dehydrogenase 1 (IDH1) mutation (Foundation Medicine, no PD-L1 reported). The patient progressed after multiple lines of treatment including (in sequential order) cisplatin+gemcitabine, irinotecan+capecitabine. By November 2019, her disease was progressing with worsening abdominal pain. Hospice as an option was discussed with her but she desired to continue treatment. Pembrolizumab was started in December 2019 and achieved excellent control of her disease until early August 2021 (27 treatments total with pembrolizumab) with CT showing progression with recurrence of her abdominal pain. She started IDH1 inhibitor, ivosidenib, once it was approved by the FDA (approved on August 25, 2021 and she started on September 15, 2021). In <2 months, with worsening abdominal pain, rising tumor markers, and CT showing enlarging retroperitoneal lymph nodes, the ivosidenib was discontinued. Hospice as an option was discussed with her. She insisted on attempting another treatment before making her decision on hospice. She started on ipilimumab (2.7 mg/kg to round to full vial size)+nivolumab (1 mg/kg). It was noted that all tumor markers, CEA and CA19-9, were dropping but repeat CT after the third treatment showed the retroperitoneal lymph nodes were a few mm larger. Her abdominal pain was slowly improving, and the decision was to continue her on the same treatment. Repeat CT after the fifth treatment showed no further enlargement of the retroperitoneal lymph nodes. Repeat CT after the eighth treatment showing smaller retroperitoneal lymph nodes. Her tumor markers continued to trend lower, and her abdominal pain was much improved. We concluded that her CT after the third treatment showing larger retroperitoneal lymph nodes was pseudoprogression. Treatment with dual-agent immunotherapy was continued into the ninth treatment as on June 1, 2022 (Fig. 3).

Case 3

Case 3 was a male in his late-50s with metastatic cholangiocarcinoma to liver, bone, lung, and pleura diagnosed in September 2018. The initial pathology was from a sacral bone biopsy that showed metastatic adenocarcinoma consistent with biliary primary followed by a liver biopsy to confirm the diagnosis in October 2018. After radiation to the left humerus and sacrum, he was started on cisplatin+gemcitabine from November 2018 until October 2019, with an interruption for surgery to the left humerus for an intramedullary rod fixation in February 2019. CT performed in August 2019 noted all measurable retroperitoneal lymph nodes were responding to treatment except a 5 cm liver lesion in segment 2 that had not changed with the sequential response-evaluation CT. He underwent a liver biopsy in September 2019 with pathology showing poorly differentiated hepatocellular carcinoma (HCC). Molecular profiling of the liver pathology (Caris Life Science) showed microsatellite-stable but due to scanty material, no PD-L1 was reported. He started on lenvatinib but self-discontinued after 3 weeks. He decided to take a treatment break at that time. Repeat CT on February 2020 noted a smaller segment 2 lesion, but retroperitoneal lymph nodes were progressing. He then received SBRT to the segment 2 liver lesion. Pathology from retroperitoneal lymph node biopsy in April 2020 showed adenocarcinoma consistent with the biliary origin and no HCC component. He started back on cisplatin+gemcitabine then irinotecan+oxaliplatin without response. From August to September 2020, he received a total of 3 treatments with pembrolizumab with further progression of his disease by CT in October 2020. He decided to transition to hospice care then, only to return to the cancer center clinic in December 2021 with worsening abdominal pain. By then, he was 15 months without treatment and was discharged from hospice. He desired to try another treatment if a regimen could be suggested for him. He started on ipilimumab (3 mg/kg)+nivolumab (1 mg/kg) in December 2021. His abdominal pain improved and by March 2022 repeat CT showed smaller retroperitoneal lymph nodes. By June 8, 2022, he received cycle 9 treatment with reduced ipilimumab (1 mg/kg)+nivolumab (1 mg/kg) due to mild elevation of liver enzymes. The intent was to maintain his

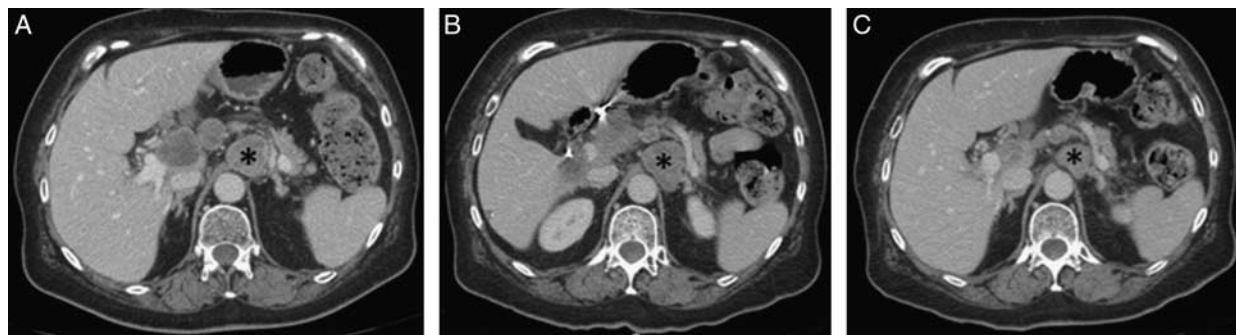

FIGURE 3. Case 2 CT scans over treatment course. A, CT on the start of dual immunotherapy initiated demonstrates multiple enlarged celiac axis lymph nodes, with index lymph node (black *) measuring 32 mm in short axis. B, Three months CT into dual immunotherapy, index lymph node demonstrated a mild increase in the size of 34 mm (black *). C, Despite slight enlargement of lymph nodes, dual immunotherapy was continued as other clinical markers improved, and 6-month follow-up demonstrated decrease in the size of index lymph node to 24 mm, suggesting prior enlargement may have been pseudoprogression.

treatment with this low-dose ipilimumab approach for as long as his response was maintained (Fig. 4).

DISCUSSION

Immune checkpoint inhibitors target cytotoxic T lymphocyte antigen 4 (CTLA-4), programmed cell death protein 1 (PD-1), and PD-L1 and are currently in wide clinical use for the treatment of many malignant diseases. The CTLA-4 is the checkpoint at the antigen-presenting phase whereas PD-1, and PD-L1 are checkpoints at the cytotoxic phase. Checkmate 064 was an open-label, randomized phase 2 study of treatment-naïve patients with unresectable stage III/IV melanoma. Patients were randomized to either nivolumab for 6 doses and then switched to ipilimumab for 4 doses or the reverse sequence. The result showed a higher response rate in the group that received nivolumab followed by ipilimumab than the reverse sequence (41% vs. 20%) at week 25.¹¹ A longer survival (not reached vs. 16.9 mo) was noted in the group that received nivolumab followed by ipilimumab in this trial as well. The authors did not provide an explanation on why a better outcome was observed with starting anti-PD-1 followed by anti-CTLA-4. The switch of checkpoint inhibitor in this trial was scheduled regardless of response. In another trial, it was shown that ipilimumab was not effective in patients with melanoma, which progressed after anti-PD-1 agents.¹²

A group of researchers from Hong Kong published results of sequential immunotherapy in HCC. Patients who progressed on either nivolumab or pembrolizumab were switched to either ipilimumab/pembrolizumab or ipilimumab/nivolumab on the basis of a prior anti-PD-1 agent. Even though the number of patients was small, N=25, the 1, 2, and 3-year survivals were 42.4%, 32.3%, and 21.6%, respectively.¹³ Preliminary results of the ongoing SWOG S1616 trial were presented at the AACR 2022 meeting. The trial randomized patients who progressed on anti-PD-1 to either single-agent ipilimumab or a combination of ipilimumab/nivolumab. Results showed a higher response rate (28% vs. 6%) and numerically longer survival in the combination arm than in the single-agent arm.¹⁴

Trials in patients with urothelial carcinoma and non-small cell lung cancer with dual-agent immunotherapy of anti-CTLA-4 and anti-PD-1 therapy upon progression on single-agent anti-PD-1 therapy [NCT03117309, NCT03177239, and NCT04151563] are ongoing.¹⁵ However, no similar clinical trials are available for patients with cholangiocarcinoma.

The first case in our series started dual immunotherapy out of desperation with a surprisingly positive outcome. The overwhelming majority of published data and ongoing trials using dual immunotherapy have a fixed cycle of ipilimumab/nivolumab followed by maintenance with single-agent nivolumab. We decided to continue the dual agent but lower the dose of ipilimumab (around 1 mg/kg). He is active in his life and without pain. We are not sure whether he would have such a

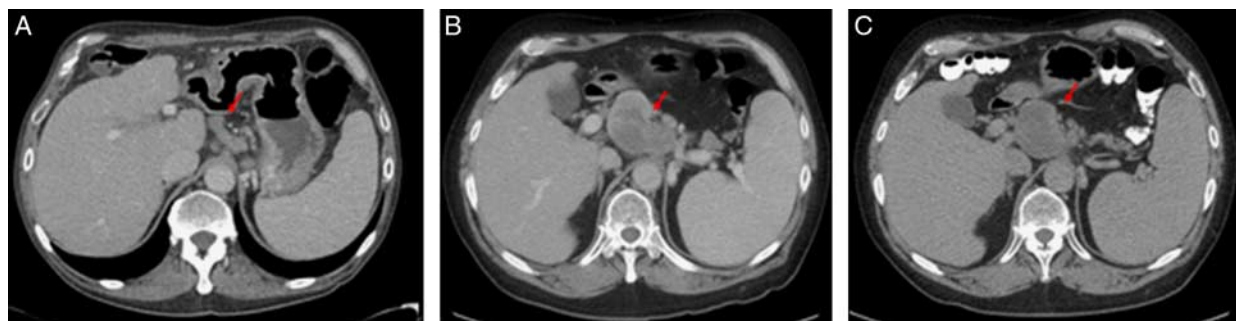


FIGURE 4. Case 3 CT scans over treatment course. A, Axial CT image demonstrates mildly enlarge gastrohepatic lymph node (red arrow) measuring 13 mm short axis on October 11, 2020, when the patient went to hospice. B, Axial CT demonstrated a significant increase in severity of lymphadenopathy after treatment lapse with the gastrohepatic lymph node short axis at 45 mm, with central hypoattenuation, possibly representing necrosis (red arrow). C, After 4 months of dual immunotherapy, the gastrohepatic lymphadenopathy seems similar or minimally decreased in size at 43 mm short axis. [full color online](#)

long continuous response if we switched him to single-agent nivolumab after the initial 4 to 6 cycles of treatment.

The second case in our series had impressive disease control with pembrolizumab alone for a total of 27 cycles before progression. Our initial target was to complete a total of 35 treatments and then place her on observation. Despite molecular studies notable for IDH1 mutation, she did not respond to ivosidenib. Her tumor markers began to drop once the dual immunotherapy was started but the CT did show slightly larger lymph nodes after the third treatment. Clinically, she was having less pain and her weight-loss stopped. This reinforced our decision to continue dual immunotherapy. She continued her steady but slow improvement in functional status with tumor markers progressively trending lower and with a CT scan showing smaller target lymph nodes after the seventh treatment, we concluded that she had pseudoprogression. On the basis of our experience from the first case, we decided to continue dual immunotherapy with a lower dose of ipilimumab for her treatment and she has completed the ninth treatment without complications.

Unlike case 2 in our series, case 3 had worsening pain, rising tumor markers, and CT showing larger lymph nodes after 3 treatments with pembrolizumab. He then enrolled in hospice but was discharged after 6 months. He returned to the clinic 15-month later without cancer-directed therapy with recurrent pain but looked well with completely independent living, in a better state than when he was enrolled in the hospice. That prompted us to ponder whether he also had pseudoprogression 15-month earlier. We also decided to continue dual immunotherapy with a lower dose of ipilimumab.

There were lessons learned and questions raised with this 3-case series.

We question the current dosing strategy of dual immunotherapy. Should we limit dual immunotherapy to only 4 to 6 treatments? Our 3 cases' experience suggests continuing dual immunotherapy can be safely done for a long duration of treatment.

All 3 cases responded to dual immunotherapy after initial anti-PD-1. Is this the proper sequential use of immunotherapy agents? Will our patients respond similarly well if we started with a dual immunotherapy regimen?

How can we properly differentiate pseudoprogression from true progression? As our cases 2 and 3 illustrated that the distinction can be hard to make.

All 3 cases do not have microsatellite instability, or high tumor mutation burden. How do we select patients that are most likely to benefit from immunotherapy (single or dual-agents)? Immunotherapy has demonstrated the most benefit when there was a significant genetic disparity between tumor and host cells.¹⁶ For example, in patients with colorectal carcinoma, it has been shown that those with a mismatch repair deficiency were more likely to respond to anti-PD-1 therapy.¹⁷ On the basis of molecular profiling, none of the 3 cases would have been predicted to respond well to treatment with immunotherapy. We believe that we need better biomarker(s) to predict response to immunotherapy than microsatellite instability alone.

It is expected that the use of immunotherapy agents upfront in patients with advanced cholangiocarcinoma will be increased with data presented on cisplatin+gemcitabine+durvalumab. Should we begin to use dual immunotherapy with chemotherapy or reserve dual immunotherapy as a sequential therapy option for our patients? A small phase II trial of gemcitabine and cisplatin plus durvalumab with or without tremelimumab suggests adding dual immunotherapy upfront

with chemotherapy may not provide additional benefits to single-agent immunotherapy agents in patients with advanced biliary tract cancer.⁷

In conclusion, we reported the first case series on the use of dual immunotherapy with cholangiocarcinoma in patients who had progressed on single-agent immunotherapy with pembrolizumab. It is proof of the concept that sequential immunotherapy can be beneficial after progression on single-agent immunotherapy. It can be the foundation to build more trials to further test on the true effectiveness of sequential therapy and the duration of dual immunotherapy combination.

REFERENCES

- Zamani Z, Fatima S. *Biliary Tract Cancer*. Treasure Island, FL: StatPearls; 2021.
- Pellino A, Loupakis F, Cadamuro M, et al. Precision medicine in cholangiocarcinoma. *Transl Gastroenterol Hepatol*. 2018;3:40.
- Lepage C, Cottet V, Chauvenet M, et al. Trends in the incidence and management of biliary tract cancer: a French population-based study. *J Hepatol*. 2011;54:306–310.
- Valle JW, Furuse J, Jital M, et al. Cisplatin and gemcitabine for advanced biliary tract cancer: a meta-analysis of two randomised trials. *Ann Oncol*. 2014;25:391–398.
- Rizvi S, Khan SA, Hallemeier CL, et al. Cholangiocarcinoma—evolving concepts and therapeutic strategies. *Nat Rev Clin Oncol*. 2018;15:95–111.
- Saeed A, Park R, Al-Jumayli M, et al. Biologics, immunotherapy, and future directions in the treatment of advanced cholangiocarcinoma. *Clin Colorectal Cancer*. 2019;18:81–90.
- Oh DY, Lee KH, Lee DW, et al. Gemcitabine and cisplatin plus durvalumab with or without tremelimumab in chemotherapy-naïve patients with advanced biliary tract cancer: an open-label, single-centre, phase 2 study. *Lancet Gastroenterol Hepatol*. 2022;7:522–532.
- Piha-Paul SA, Oh DY, Ueno M, et al. Efficacy and safety of pembrolizumab for the treatment of advanced biliary cancer: results from the KEYNOTE-158 and KEYNOTE-028 studies. *Int J Cancer*. 2020;147:2190–2198.
- Kim RD, Chung V, Alese OB, et al. A phase 2 multi-institutional study of nivolumab for patients with advanced refractory biliary tract cancer. *JAMA Oncol*. 2020;6:888–894.
- Klein O, Kee D, Nagrial A, et al. Evaluation of combination nivolumab and ipilimumab immunotherapy in patients with advanced biliary tract cancers: subgroup analysis of a phase 2 nonrandomized clinical trial. *JAMA Oncol*. 2020;6:1405–1409.
- Weber JS, Gibney G, Sullivan RJ, et al. Sequential administration of nivolumab and ipilimumab with a planned switch in patients with advanced melanoma (CheckMate 064): an open-label, randomised, phase 2 trial [published correction appears in *Lancet Oncol*. July 17, 2016 (7):e270]. *Lancet Oncol*. 2016;17:943–955.
- Wilson T, Taylor H, Winter H, et al. Sequential immunotherapy in melanoma: is it a realistic alternative to dual immunotherapy? *Melanoma Res*. 2021;31:366–370.
- Wong JSL, Kwok GGW, Tang V, et al. Ipilimumab and nivolumab/pembrolizumab in advanced hepatocellular carcinoma refractory to prior immune checkpoint inhibitors. *J Immunother Cancer*. 2021;9:e001945.
- VanderWalde AM, Moon K, Kenda K, et al. S1616: Ipilimumab plus nivolumab versus ipilimumab alone in patients with metastatic or unresectable melanoma that did not respond to anti-PD-1 therapy. *Cancer Res* 15. 2022;82(suppl 12):CT013.
- Das S, Allen A, Berlin J. Immunotherapy after immunotherapy: response rescue in a patient with microsatellite-high colorectal cancer post-pembrolizumab. *Clin Colorectal Cancer*. 2020;19:137–140.
- Seidel JA, Otsuka A, Kabashima K. Anti-PD-1 and Anti-CTLA-4 therapies in cancer: mechanisms of action, efficacy, and limitations. *Front Oncol*. 2018;8:86.
- Le DT, Uram JN, Wang H, et al. PD-1 blockade in tumors with mismatch-repair deficiency. *N Engl J Med*. 2015;372:2509–2520.