



Bilateral anterior and posterior scleritis in a patient with acute myelogenous leukemia

Pujan R. Patel^a, Maureen C. Farrell^a, Ani Peshtani^{a,1}, Meghan K. Berkenstock^{b,*}

^a Drexel University College of Medicine, Philadelphia, PA, USA

^b Wilmer Eye Institute, Johns Hopkins School of Medicine, Baltimore, MD, USA

ARTICLE INFO

Keywords:

Acute myelogenous leukemia
Anterior scleritis
Posterior scleritis
Paraneoplastic syndrome
Anti-leukemic inflammatory response

ABSTRACT

Purpose: To report a novel case of bilateral anterior and posterior scleritis in a patient with acute myelogenous leukemia (AML).

Observations: A 69-year-old African American man was admitted to the hospital for relapse of AML. After admission, but prior to induction of chemotherapy, the patient developed ocular redness and proptosis. The diagnosis of bilateral anterior and posterior scleritis was made following an ophthalmic examination, infectious and autoimmune lab work-up, and neuroimaging. The patient was administered immunosuppressive therapy, clinically monitored, and initiated on chemotherapy for AML relapse. About one week later, the patient showed clinical improvement and resolution of the scleritis and proptosis.

Conclusion: Scleritis may present during AML relapse, and it may be due to a paraneoplastic syndrome or a reactive anti-leukemic inflammatory response. Clinicians should monitor patients with AML relapse for symptoms such as ocular redness, proptosis, pain, photophobia, and decreased vision, which may indicate development of scleritis.

1. Introduction

Scleritis is a painful and potentially sight-threatening inflammation of the sclera due to a variety of etiologies including autoimmune disease, medications, prior surgery, infections, and malignancies.^{1–4} Classification of the extent of the inflammation is crucial, as posterior extension can result in retinal detachment and optic disc edema.^{3–5} Although, scleritis-like ocular inflammation has been reported in several malignancies, including lymphoma and choroidal melanoma,^{3,4} to our knowledge, there has been no report of anterior and posterior scleritis developing in a patient during relapse of acute myelogenous leukemia (AML).

2. Case report

A 69-year-old African American man was admitted for an acute relapse of AML. There was no history of chronic lymphocytic leukemia (CLL) or secondary malignancies. Ophthalmology was consulted two days post admission for evaluation of bilateral ocular redness (Fig. 1). His past medical history was significant for type 2 diabetes mellitus,

hypertension, and an autologous stem cell transplant in 2010. His past ophthalmic history was notable for unilateral glaucoma secondary to angle recession in the right eye (OD), diagnosed 17 years prior. The patient reported no pain and no change in vision. On exam, best corrected visual acuity was hand motion (HM) OD and 20/20 on the left (OS). An afferent pupillary defect was noted OD. Visual fields were full to confrontation OS and extra-ocular muscle movements were intact and symmetrical. Bedside examination revealed bilateral proptosis with diffuse, 3+ injection, non-blanching to phenylephrine 10% eyedrops. Dilated fundus exam revealed a pale disc with a cup-to-disc ratio of 0.9 in OD and a normal optic nerve with a cup-to-disc ratio of 0.3 in OS. No leukemic infiltrates or serous retinal detachments were noted. At the time, our working diagnosis was bilateral, diffuse anterior scleritis requiring further work-up to assess for posterior extension given the bilateral proptosis.

A full laboratory work-up was undertaken, which showed a white blood cell count (WBC) of $10.4 \times 10^3/\mu\text{L}$ with 87% myeloblasts. Peripheral blood and urine cultures along with a chest X-ray were negative. The remainder of the work-up was unremarkable, including Lyme titers, RPR, FTA-abs, and QuantiFERON assay. Additionally, autoimmune

* Corresponding author. Wilmer Eye Institute, 600 N. Wolfe St. Maumenee Third Floor Baltimore, MD, 21287, USA.

E-mail address: mberken2@jhmi.edu (M.K. Berkenstock).

¹ Present address/affiliation of Ani Peshtani is University Radiology LLC.

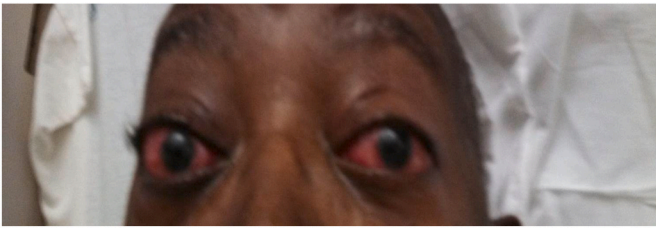


Fig. 1. Color photo demonstrating the gross findings on the patient. (For interpretation of the references to colour in this figure legend, the reader is referred to the Web version of this article.)

testing was negative for HLA-B27 and ANCA. MRI revealed a left posterior and a right anterior chronic subdural hematoma with thickening of the dura and fluid within the Tenon capsule in OS (Fig. 2). This further suggested the presence of posterior scleral inflammation. Subsequent B-scan ultrasonography (B-scan) confirmed diffuse posterior scleral thickening and a positive “T-sign” bilaterally (Fig. 3).

After discussion with the primary team, the patient underwent induction of chemotherapy three days into his hospital admission with concurrent administration of IV methylprednisolone 1g daily for 3 days. His ocular exam showed clinical improvement and resolution of the scleral injection and proptosis approximately one week after initiation of chemotherapy. His vision remained stable at HM OD and 20/20 OS.

3. Discussion

This is the first reported case of bilateral, anterior and posterior scleritis in the setting of AML. It is important to note that there was no sign of retrobulbar mass on MRI or B-scan and no intraocular metastasis on dilated fundus exam. Additionally, there was no evidence of an underlying infectious etiology on serological work-up. As the clinical presentation predated chemotherapeutic induction, medication-induced scleritis can be excluded.

Scleritis has been reported in several malignancies,^{6–15} either as masquerade or paraneoplastic syndrome. In the masquerade syndrome,

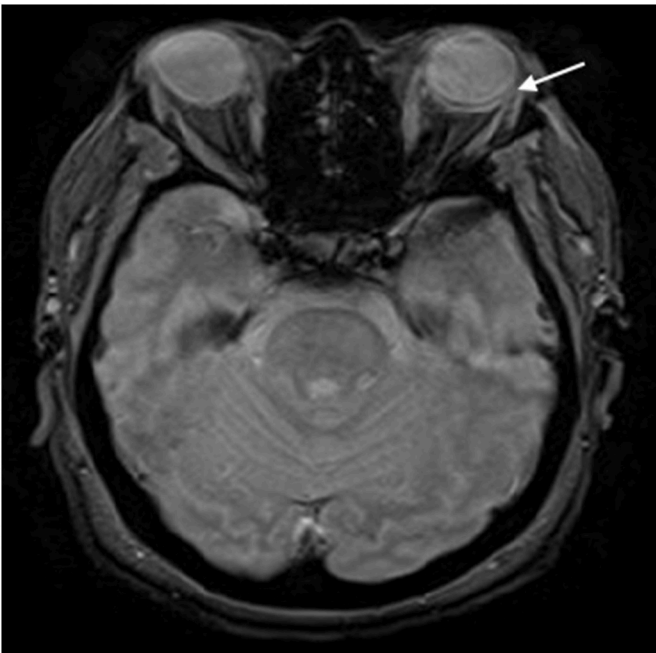


Fig. 2. Transverse MRI of the brain demonstrating fluid within the left eye's Tenon capsule (arrow). Note the increased size of the potential space behind the left globe.

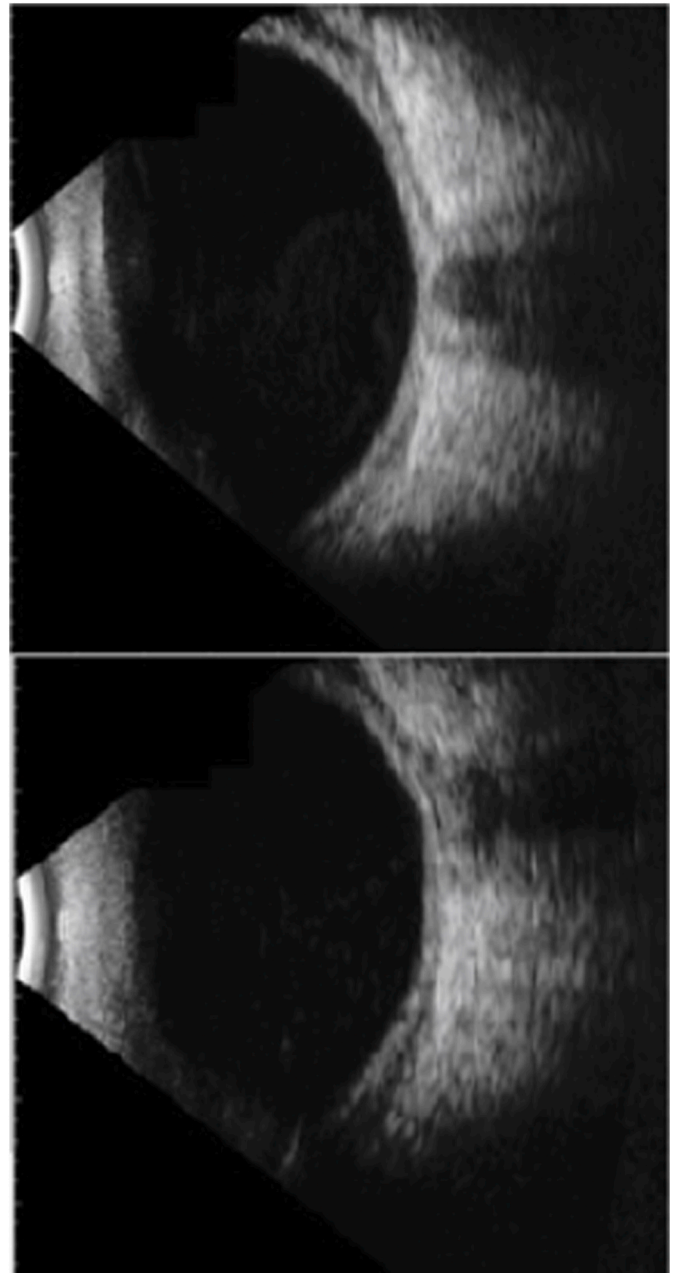


Fig. 3. B-scan ultrasonography of the right (A) and left (B) eyes. The T-sign is present bilaterally. Note the presence of fluid near the equator of both globes. In addition, there are significant hypoechoic spaces around both sclera. This represents fluid in the Tenon capsule.

an infiltrative malignant process adjacent to the sclera is misdiagnosed as scleritis.^{11–14} On the start of immunosuppressive therapy, if a sustained clinical response to treatment does not occur, this should prompt a further work-up including potential biopsy.⁴ Malignancies previously associated with the development of a masquerade syndrome include primary central nervous system (CNS) lymphoma,¹⁰ orbital lymphoma,¹¹ mucosa-associated lymphoid tissue (MALT) lymphoma,¹² peripheral T-cell lymphoma,¹³ metastatic bronchioalveolar carcinoma,¹⁴ and CLL,¹⁵ and AML.¹⁶

Scleritis has also been reported to develop as a paraneoplastic syndrome, which differs from that of masquerade syndrome where tumor cells directly infiltrate sclera.⁹ Thakker and colleagues reported the first case of paraneoplastic scleritis in a patient later diagnosed with Hodgkin's Lymphoma.⁹ They postulated that the scleral inflammation could

be due to cross-reaction of tumor-associated antigen antibodies with scleral collagen as well as chemokine production by malignant cells.⁹ It is known that AML cells display tumor antigens.^{17,18} Many have been identified, including a mutant FMS-like tyrosine kinase 3, which leads to an antileukemic immune response.^{17–19} Hence, this theory may explain the pathophysiology of scleritis in our patient.

More recently, Kalogeropoulos and colleagues reported a case of paraneoplastic scleritis in the setting of colon cancer.⁸ Their 61-year-old patient was initially diagnosed with unilateral posterior scleritis. An extensive infectious and autoimmune work-up was unremarkable; however, their patient was diagnosed with colon cancer six months later during a routine preventative colonoscopy.

Finally, Soon and Chan reported a case of bilateral posterior scleritis in a 70-year-old patient with a relapse of CLL.²⁰ Although conjunctival CLL is a known masquerader of scleritis,¹⁵ conjunctival biopsy demonstrated no direct tumor infiltration on pathologic examination. Rather, they postulated that relapse of CLL led to a reactive inflammatory immune response resulting in scleritis.

Our understanding about the pathogenesis of scleritis is limited due to its low incidence and contraindication of scleral biopsies, which would exacerbate inflammation.²¹ However, episcleral biopsies in patients with nodular non-necrotizing scleritis suggest that T-cells and macrophages are the major infiltrators of episcleral tissue.^{2,22} In addition, proinflammatory cytokines such as IL-1 β and TNF- α have been found at increased concentrations in the serum and tear fluid of patients with active scleritis.^{21,23,24} It is unknown if these inflammatory cells and cytokines are associated in paraneoplastic cases of scleritis. In addition, there was one report by Larson and colleagues describing improvement of scleritis in two patients with human T-cell lymphotropic virus type-1 associated Adult T-cell Leukemia after investigational treatment with IL-2 receptor targeted therapies.²⁵ However, it is unclear if the improvement was secondary to treatment of the malignancy or treatment of the inflammation. Larson and colleagues argued in favor of the inflammation theory because ocular improvement occurred quickly and both patients eventually experienced relapse of systemic disease.²⁵

Given the lack of leukemic infiltrates in our patient on imaging and the rapid resolution following induction of chemotherapy and intravenous corticosteroids, we believe that our patient's scleritis was a paraneoplastic manifestation of AML relapse and a consequence of the subsequent systemic inflammatory response.

4. Conclusion

Scleritis may present during AML relapse as a paraneoplastic syndrome resulting from a systemic inflammatory response. In these cases, clinicians should first rule out infectious and autoimmune causes, and have a high level of suspicion to assess for both anterior and posterior scleritis.

Patient consent

Case reports did not require local IRB approval at the time when the patient presented for care in 2014. The subsequent closure of Hahnemann University Hospital resulted in discontinuation of the electronic medical record and secured storage of all records, which precludes current contact of the patient to obtain consent.

Funding

None.

Authorship

All authors attest that they met the current ICMJE criteria.

Declaration of competing interest

The authors have no conflicts of interest to disclose.

Acknowledgements

None.

References

- Calthorpe CM, Watson PG, McCartney AC. Posterior scleritis: a clinical and histological survey. *Eye*. 1988;2(Pt 3):267–277.
- Okhravi N, Odufuwa B, McCluskey P, Lightman S. Scleritis. *Surv Ophthalmol*. 2005;50(4):351–363.
- McCluskey PJ, Watson PG, Lightman S, et al. Posterior scleritis: clinical features, systemic associations, and outcome in a large series of patients. *Ophthalmol*. 1999;106(12):2380–2386.
- Daniel Diaz J, Sobol EK, Gritz DC. Treatment and management of scleral disorders. *Surv Ophthalmol*. 2016;61(6):702–717.
- Gonzalez-Gonzalez LA, Molina-Prat N, Doctor P, et al. Clinical features and presentation of posterior scleritis: a report of 31 cases. *Ocul Immunol Inflamm*. 2014;22(3):203–207.
- Loriaut P, Charlotte F, Bodaghi B, et al. Choroidal and adnexal extranodal marginal zone B-cell lymphoma: presentation, imaging findings, and therapeutic management in a series of nine cases. *Eye*. 2013;27(7):828–835.
- Gaucher D, Bodaghi B, Charlotte F, et al. [MALT-type B-cell lymphoma masquerading as scleritis or posterior uveitis]. *J Fr Ophthalmol*. 2005;28(1):31–38.
- Kalogeropoulos D, Katsikatsos K, Mitsis M, Kalogeropoulos C. Posterior scleritis as a paraneoplastic syndrome in colon cancer: a case report. *Turk J Ophthalmol*. 2020;50(6):377–380.
- Thakker MM, Perez VL, Moulin A, Cremers SL, Foster CS. Multifocal nodular episcleritis and scleritis with undiagnosed Hodgkin's lymphoma. *Ophthalmol*. 2003;110(5):1057–1060.
- Hunyor AP, Harper CA, O'Day J, McKelvie PA. Ocular-central nervous system lymphoma mimicking posterior scleritis with exudative retinal detachment. *Ophthalmol*. 2000;107(10):1955–1959.
- Dorey SE, Clark BJ, Christopoulos VA, Lightman S. Orbital lymphoma misdiagnosed as scleritis. *Ophthalmol*. 2002;109(12):2347–2350.
- Hoang-Xuan T, Bodaghi B, Toubianc M, et al. Scleritis and mucosal-associated lymphoid tissue lymphoma: a new masquerade syndrome. *Ophthalmol*. 1996;103(4):631–635.
- Kirn TJ, Levy NB, Gosselin JJ, Rosen WJ, Zegans ME. Peripheral T-cell lymphoma presenting as sclerouveitis. *Cornea*. 2007;26(9):1147–1149.
- Yeo JH, Jakobiec FA, Iwamoto T, Brown R, Harrison W. Metastatic carcinoma masquerading as scleritis. *Ophthalmol*. 1983;90(2):184–194.
- Mohsenin A, Sinard J, Huang JJ. Necrobiotic xanthogranuloma and chronic lymphocytic leukemia of the conjunctiva masquerading as scleritis and uveitis. *Clin Ophthalmol*. 2012;6:2045–2047.
- Green W, Rao PK, Harocopos GJ. Extramedullary relapse of acute myelogenous leukemia presenting as a large serous retinal detachment. *Ocul Oncol Pathol*. 2017;3(2):95–100.
- Anguille S, Van Tendeloo VF, Berneman ZN. Leukemia-associated antigens and their relevance to the immunotherapy of acute myeloid leukemia. *Leukemia*. 2012;26(10):2186–2196.
- Anguille S, Lion E, Smits E, Berneman ZN, van Tendeloo VF. Dendritic cell vaccine therapy for acute myeloid leukemia: questions and answers. *Hum Vaccine*. 2011;7(5):579–584.
- Scholl S, Salzmann S, Kaufmann AM, Hoffken K. FLT3-ITD mutations can generate leukaemia specific neoepitopes: potential role for immunotherapeutic approaches. *Leuk Lymphoma*. 2006;47(2):307–312.
- Soon AK, Chan TY. An atypical case of bilateral posterior scleritis in a patient with chronic lymphocytic leukemia. *Can J Ophthalmol*. 2015;50(4):e60–e63.
- Vergouwen DPC, Rothova A, Berge JCT, et al. Current insights in the pathogenesis of scleritis. *Exp Eye Res*. 2020;197:108078.
- Bernauer W, Buchi ER, Daicker B. Immunopathological findings in posterior scleritis. *Int Ophthalmol*. 1994;18(4):229–231.
- Palexas GN, Puren A, Savage N, Welsh NH. Serum interleukin (IL-1 beta) in patients with diffuse scleritis. *Scand J Immunol Suppl*. 1992;11:171–172.
- Seo KY, Lee HK, Kim EK, Lee JH. Expression of tumor necrosis factor alpha and matrix metalloproteinase-9 in surgically induced necrotizing scleritis. *Ophthalmic Res*. 2006;38(2):66–70.
- Larson TA, Hu M, Janik JE, et al. Interleukin-2 receptor targeted therapy of ocular disease of HTLV-1-associated adult T-cell leukemia. *Ocul Immunol Inflamm*. 2012;20(4):312–314.