

Therapeutic effect of neoadjuvant chemotherapy combined with curettage to treat distal femoral osteosarcoma

A case report

Qi Lai, MD, Conglin Ye, MD, Tian Gao, MD, Jun Xiao, MD, An Xie, MD, Xuqiang Liu, PhD, Xiaolong Yu, MD, Jun Liu, MD, Min Dai, MD, Hucheng Liu, MD*, Bin Zhang, PhD*

Abstract

Rationale: Osteosarcoma is the most common malignant bone tumor in children and adolescents. Metastasis occurs early, the mortality rate is high, and the tumor results in a tremendous physical, mental, and economic burden on patients. Therefore, the treatment of osteosarcoma has been important for orthopedic surgeons. However, treatment has always been a difficult problem globally.

Patient concern: We present the case of a 22-year-old girl with increasing local pain in the distal left thigh.

Diagnoses: The patient was initially diagnosed as bone cancer according to computed tomography (CT) and X-ray imaging. And the patient was further diagnosed as osteosarcoma via to puncture biopsy of the left distal femur.

Interventions: Local arterial infusion chemotherapy, systemic intravenous chemotherapy, and curettage was conducted because of limb salvage program.

Outcomes: The patient was doing well with no evidence of local or distant recurrence 7 years after the surgery.

Lessons: Our case indicated that limb osteosarcoma patients can undergo a limb salvage program of local arterial infusion chemotherapy, systemic intravenous chemotherapy, and curettage.

Abbreviations: ADM = doxorubicin, CT = computerized tomography, DDP = cisplatin, IFO = isophosphate.

Keywords: curettage, local arterial infusion chemotherapy, neoadjuvant chemotherapy, osteosarcoma

1. Introduction

Osteosarcoma is a primary malignant bone tumor originating from interosseous leaf cells and is characterized by proliferation of tumor cells, which directly form immature bone or bone-like tissue. Osteosarcoma occurs in young people, and the incidence rate is about 0.3/million, accounting for about 0.2% of malignant tumors.^[1] Osteosarcoma typically occurs in boys and men, and the age of onset is between 8 and 25 years. It rarely occurs in

patients younger than 6 and older than 60 years. Therefore, osteosarcoma is a dangerous factor in the health of adolescents. It has early metastasis and a high incidence and mortality, and the treatment of osteosarcoma has become a worldwide problem. In recent years, the study of osteosarcoma treatment has become an important issue in the medical profession.

Amputation was the primary modality of therapy of osteosarcoma before the advent of chemotherapy and limb

Editor: N/A.

BZ and HL contributed equally to this work and should be considered co-corresponding authors.

QL, CY, and TG contributed equally to this work and should be considered cofirst authors.

Funding/support: This study was supported by Gan-Po Talents Project 555 of Jiangxi Province, Jiangxi Provincial Department of Science and Technology (20171BAB205059), Jiangxi provincial department of education (GJJ160127), and Jiangxi Province Postgraduate Innovation Special Funds (YC2016-S107).

The ethical approval has been received by the medical ethics committee of the First Affiliated Hospital of Nanchang University concerning the publication of this manuscript and any accompanying images. A copy of this document is available for review by the editor in chief of this journal.

The authors declare that they have no competing interests.

Department of Orthopedics, Multidisciplinary Therapy Center of Musculoskeletal Tumor and Artificial Joints Engineering Technology Research Center of Jiangxi Province, The First Affiliated Hospital of Nanchang University, Nanchang, Jiangxi, China.

* Correspondence: Bin Zhang and Hucheng Liu, No. 17 Yong Wai Zheng Street, Nanchang 330006, Jiangxi, China (e-mails: acker11@126.com; 18702508157@163.com).

Copyright © 2017 the Author(s). Published by Wolters Kluwer Health, Inc.

This is an open access article distributed under the terms of the Creative Commons Attribution-Non Commercial-No Derivatives License 4.0 (CCBY-NC-ND), where it is permissible to download and share the work provided it is properly cited. The work cannot be changed in any way or used commercially without permission from the journal.

Medicine (2017) 96:46(e8672)

Received: 10 September 2017 / Received in final form: 24 October 2017 / Accepted: 26 October 2017

<http://dx.doi.org/10.1097/MD.00000000000008672>

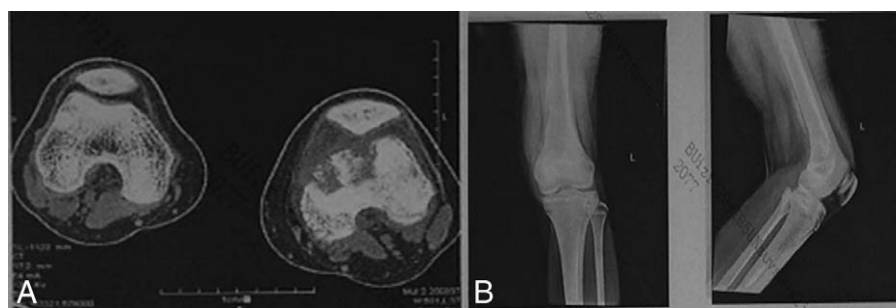

Figure 1. Computed tomography and radiographic examination of the left femur showed bone destruction, suggesting that a malignant tumor was present.

salvage. It had a very good therapeutic effect on malignant bone tumors and a strong destructive and adjuvant treatment effect. However, 80% of patients had a small metastatic interval at the time of diagnosis. The average time from surgical treatment to pulmonary metastasis was 8 months, and the overall survival rate for amputation was 10% to 20%.^[2–4] Most patients died within 1 year after diagnosis.^[5] This shows that the outcome of amputation is not optimistic; therefore, there is an urgent need for better treatment.

With the development of neoadjuvant chemotherapy, limb salvage surgery, and lung metastasis dissection in recent years, the 5-year survival rate of osteosarcoma patients has increased to 60% to 70%. However, systemic chemotherapy leads to a series of side effects, and the patient experiences pain and a poor prognosis. On the basis of these factors, we try to use neoadjuvant chemotherapy combined with surgical treatment; therefore, limb salvage surgery gradually replaced traditional amputation. We described a patient with distal osteosarcoma of the femur who underwent neoadjuvant chemotherapy combined with curettage, which had a good therapeutic effect.

2. Case presentation

In December 2009, a 15-year-old girl attended the Orthopedic Oncology Clinic at The First Affiliated Hospital of Nanchang

University (Nanchang, China) due to increasing local pain in the distal left thigh. The patient stated that these symptoms had arisen 1 month previously and intensified within 2 weeks before admittance. Although the patient had suspicion of bone cancer when she visited the county hospital, no other physical problems were reported. There was no fever or respiratory embarrassment accompanying the pain and mass. The patient had a family history of bone neoplasms. Furthermore, no history of weight loss or exposure to tuberculosis was specified.

During the initial physical examination, the passive and active range of motion of the patient's left knee joint was limited. In addition, radiography and computed tomography (Fig. 1) of the left knee revealed femoral lesions, which were thought to be malignant tumors. Radiographs of the lungs were normal. The patient underwent puncture biopsy of the left distal femur, and postoperative histological examinations revealed the presence of an osteosarcoma (Fig. 2A). The patient and her family strongly demanded limb salvage treatment, and the patient agreed to undergo local arterial infusion chemotherapy. The patient was administered 2 cycles of local arterial infusion chemotherapy (Fig. 3), as follows: cisplatin was administered at a dose of 120 mg on day 1 (DDP 120 mg + 0.9% NaCl 50 mL) and the course was repeated every 14 days.

Three weeks after the second local arterial infusion chemotherapy, the patient underwent left distal femoral tumor curettage with bone cement implantation (Fig. 4). Curettage is important for complete resection of the tumor. The tumor lesions were scraped to the maximum extent possible and pathology examination of the frozen sample from the resection margin was performed during operation to ensure that the lesion was completely scraped. During resection of the lesion in February 2010, pathological examination revealed that it was an osteosarcoma (Fig. 2B). One week after the surgery, the patient was discharged without any complications.

The patient was admitted to hospital again 3 months later for further treatment. She was administered 6 cycles of systemic intravenous chemotherapy of DDP 120 mg + 0.9% NaCl 500 mL, Intravenous drip/once daily (ivgtt/qd), for 1 day; and doxorubicin (ADM) 20 mg + 0.9% NaCl 250 mL, ivgtt/qd, for 3 days. After 2 weeks, isophosphatase (IFO) 2 g + 0.9% NaCl 500 mL, ivgtt/qd were administered for 5 days. After 2 weeks, the cycle was repeated. After the 6 cycles of systemic intravenous chemotherapy, the patient was discharged without any complications.

In June 2013, the patient was admitted to hospital again. At that time, the patient had no obvious pain in her lower limbs, and her left knee was active and feeling normal. The patient underwent bone grafting and internal fixation of the distal femur (Fig. 5). In January 2015, she was admitted to the hospital

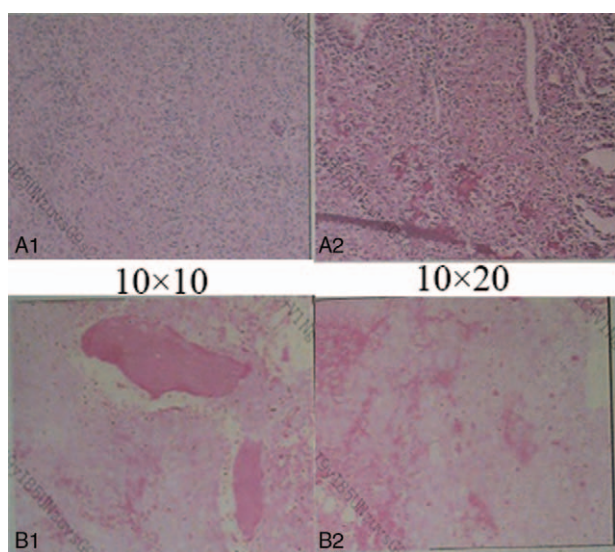


Figure 2. (A) The first examination of the puncture suggested that the pathological diagnosis was an osteosarcoma. (B) Pathology examination of the sample obtained during tumor resection surgery also suggested an osteosarcoma.

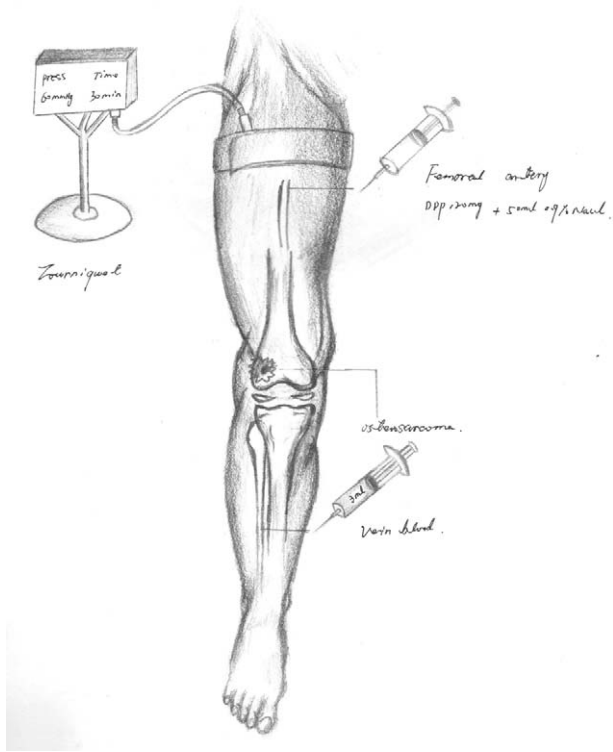


Figure 3. Illustration of local arterial perfusion chemotherapy.

to remove the internal fixation (Fig. 6). Radiography of the left femur revealed no obvious abnormalities in the bone and surrounding soft tissue. The patient was doing well with no evidence of local or distant recurrence 7 years after the surgery (Fig. 7). Approval for this study was obtained from the ethical review board of ethical committee of The First Affiliated Hospital

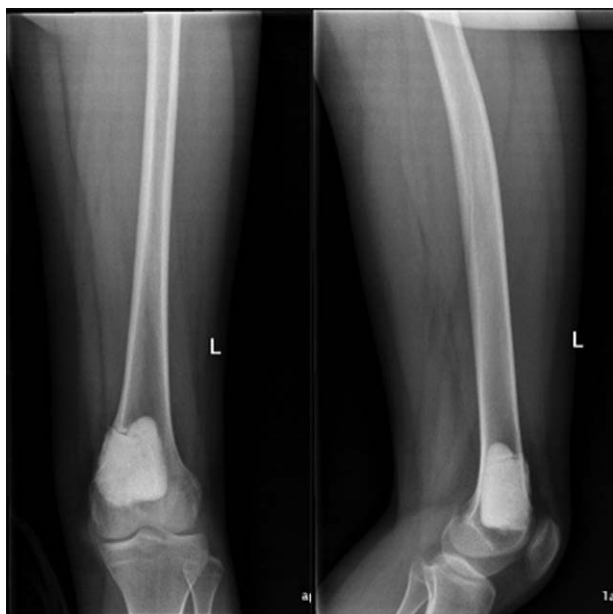

Figure 4. The patient underwent left distal femoral tumor tumorectomy with bone cement implantation in February 2010.

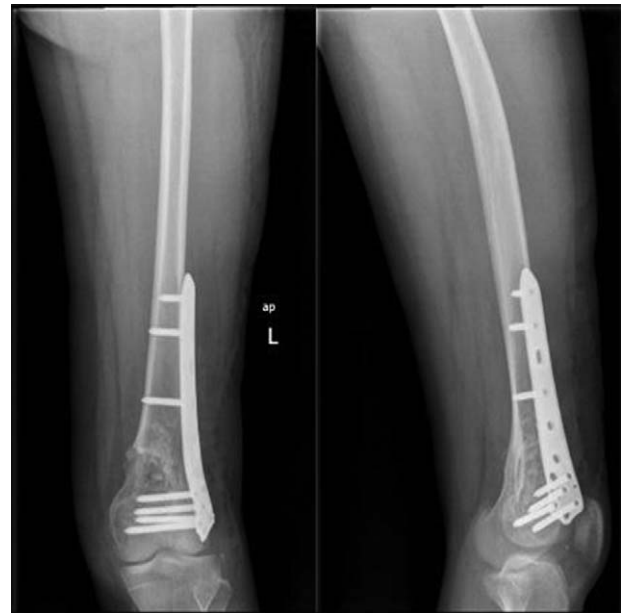

Figure 5. The patient underwent bone grafting and internal fixation of the distal femur in June 2013.

of Nanchang University, and all the investigations were conducted in conformity with the research principles of the ethical committee of The First Affiliated Hospital of Nanchang University. Informed consent was obtained from the patient for publication of the report and the accompanying images.

3. Discussion

The treatment of osteosarcoma has progressed over time. In the 1970s, the standard treatment was amputation. Amputation is one of the most important methods in the early stage of

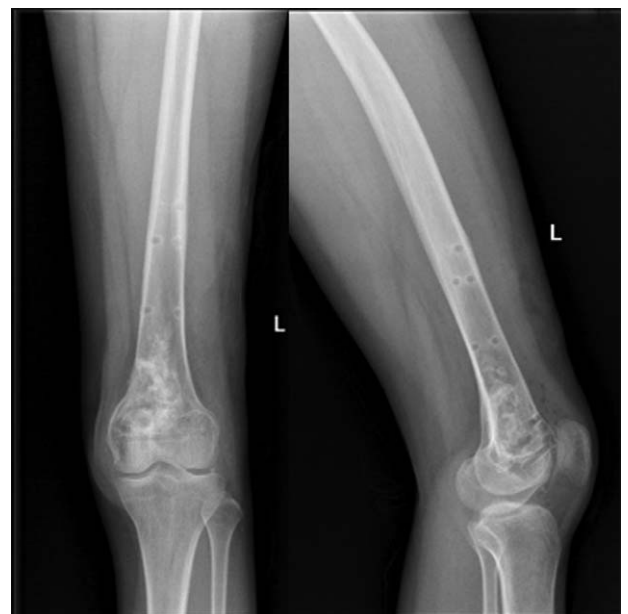

Figure 6. The patient was admitted to hospital to remove the internal fixation in January 2015.

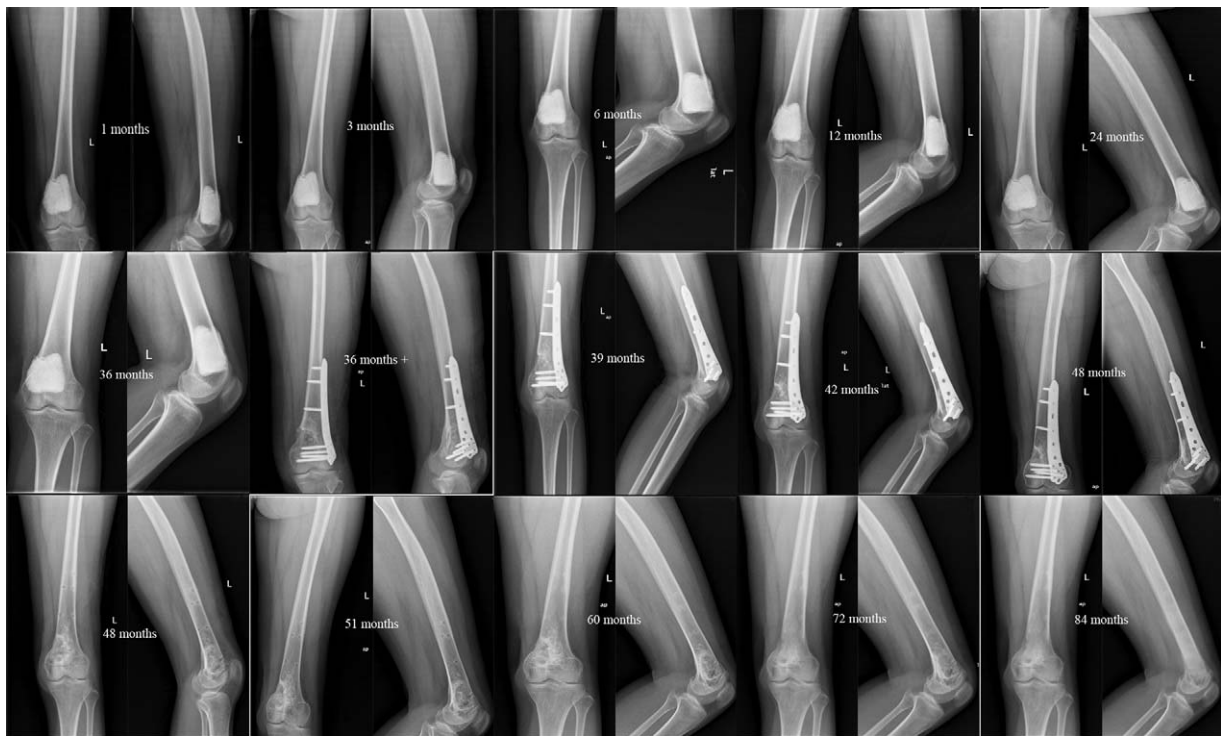

Figure 7. Seven-year follow-up imaging data.

osteosarcoma, and is a very effective treatment for malignant bone tumors. The primary objective of surgery is complete excision of the primary tumor with conservation of the limb as a secondary goal and amputation a last resort.^[6,7] In the 1980s, owing to advances in surgical techniques, effective chemotherapy drugs, preoperative and postoperative radiotherapy, adjuvant chemotherapy therapy, and neoadjuvant chemotherapy regimens, as well as improvements in surgical methods, have allowed limb salvage surgery to become the predominant alternative to amputation.^[8,9] In the 1990s, gene therapy became popular to treat osteosarcoma. Gene therapy of tumors is based on the genetic background of malignant tumors, and its aim is to introduce exogenous target genes into tumor cells or other somatic cells to correct or compensate for defective genes to achieve therapeutic goals.^[10] In the 21st century, stem cell research has become the most dynamic, influential, and promising application to life disciplines after the large-scale sequencing of the human genome. Li F et al^[11] demonstrated that stem cell transplantation plays an important role in the process of tumor metastasis, whereas hypoxia promotes the initiation of the transfer process, and the hypoxic environment of the transplanted stem cells enhances the expression of activated lysine oxidase by increasing hypoxia-inducible factor formation. Studies have confirmed that stem cells play an important role in tumorigenesis, progression, metastasis, and relapse.^[12] Osteosarcoma stem cell research is the latest advance in osteosarcoma treatment today.

Scholars have proposed a variety of treatments for osteosarcoma, but the most advanced clinical program is chemotherapy and surgery. Therefore, chemotherapy is an important adjuvant treatment for osteosarcoma. The history of chemotherapeutic treatment for osteosarcoma began in the early 1960s. In 1961, Evans^[13] used mitomycin C for metastatic osteosarcoma. In that

study, 4 patients among 17 with osteosarcoma responded to treatment. Unfortunately, some scholars later repeated the experiment without obtaining a similar result. In 1963, Sullivan et al^[14] reported that phenylalanine mustard had a certain effect on osteosarcoma, and 2 of 14 patients with osteosarcoma responded to the treatment. In the 1970s, Norman^[15] and Rosen et al^[16] combined these drugs for postoperative treatment of osteosarcoma. Rosen et al^[17] proposed neoadjuvant chemotherapy in 1982, which included preoperative chemotherapy for osteosarcoma and a postoperative chemotherapy regimen according to the sensitivity of chemotherapy and degree of tumor necrosis.

Doxorubicin, methotrexate, DDP, and ifosfamide have become the most commonly used drugs in osteosarcoma chemotherapy^[18,19] and are called the “four classic drugs of osteosarcoma chemotherapy.” On the basis of the combination of these 4 drugs, the method of chemotherapy (intravenous, arterial, and local) has also changed. Therefore, we once again proposed a chemotherapy program, which included neoadjuvant chemotherapy combined with local arterial infusion chemotherapy. Furthermore, we proposed a new program of limb salvage treatment for osteosarcoma that included high-dose local arterial infusion chemotherapy, surgery, neoadjuvant chemotherapy, and further surgery.

After the patient of the present study was diagnosed with osteosarcoma, she was administered 2 cycles of high-dose local arterial infusion chemotherapy, and the course was repeated every 14 days. Then, the patient underwent left distal femoral tumor curettage with bone cement implantation. Three months later, the patient was administered 6 cycles of neoadjuvant chemotherapy. Finally, the bone cement was completely removed, and autologous iliac implantation and internal fixation were performed. The patient achieved a good therapeutic effect. We followed her up for 7 years, and she recovered well; her vital

signs were normal and there was no indication of tumor recurrence and metastasis.

Therefore, we recommend a limb salvage program of neoadjuvant chemotherapy combined with curettage for patients with osteosarcoma. First, 2 cycles of high-dose local arterial infusion chemotherapy (Fig. 3) should be administered preoperatively. The size and boundary of the tumor in this case was significantly reduced and narrowed, which was conducive for late surgical scraping. Second, we performed limb salvage surgery, in which the tumor lesion was scraped out and filled with bone cement. This is because bone cement not only produces heat to kill tumor cells and inhibit tumor cell regeneration, but it can also temporarily bear the limb's power load. In addition, curettage is a very critical surgery, which is important to determine the success of limb salvage. Therefore, tumor lesions should be scraped to the maximum extent possible and cut edge organization with frozen pathology should be performed during the operation. After that, the osteosarcoma patient should undergo 6 cycles of neoadjuvant chemotherapy. The aim is to inactivate residual tumor cells, inhibit tumor cell regeneration, and control tumor metastasis. Finally, after the end of chemotherapy, bone tumor patients should undergo an operation consisting of tumor lesion and bone cement scraping, autogenous iliac bone grafting, and internal fixation. The purpose of the procedure is to completely remove the lesion, reconstruct the limb's structure, maintain the body's load-bearing capacity, and restore the lower limb's line of force. Regular follow-up and observation are also essential.

4. Conclusion

A 15-year-old girl with osteosarcoma successfully underwent local arterial infusion chemotherapy preoperatively, followed by curettage and postoperative neoadjuvant chemotherapy to salvage her limb. During the 7 years of follow-up, she did not have any symptoms of recurrence. In addition, the major limitation of this study is that we only collected data of a single case; therefore, we could not perform a statistical analysis. Further studies with larger populations are necessary to confirm our results. This case provides a reliable reference value to orthopedic surgeons for treating osteosarcoma with limb salvage.

Acknowledgment

We greatly appreciate the assistance of the Department of Pathology and the Department of Imaging, The First Affiliated Hospital of Nanchang University, and thank them for their efforts.

References

- [1] Botter SM, Neri D, Fuchs B. Recent advances in osteosarcoma. *Curr Opin Pharmacol* 2014;16:15–23.
- [2] Tan PX, Yong BC, Wang J, et al. Analysis of the efficacy and prognosis of limb-salvage surgery for osteosarcoma around the knee. *Eur J Surg Oncol* 2012;38:1171–7.
- [3] Ferrari S, Palmerini E, Staals EL, et al. The treatment of nonmetastatic high grade osteosarcoma of the extremity: review of the Italian Rizzoli experience. Impact on the future. *Cancer Treat Res* 2009;152:275.
- [4] Jeon DG, Song WS. How can survival be improved in localized osteosarcoma? *Expert Rev Anticancer Ther* 2010;10:1313–25.
- [5] Rosen G, Tan C, Sanmaneechai A, et al. The rationale for multiple drug chemotherapy in the treatment of osteogenic sarcoma. *Cancer* 1975;35(3 suppl):936–45.
- [6] Wittig JC, Bickels J, Priebe D, et al. Osteosarcoma: a multidisciplinary approach to diagnosis and treatment. *Am Fam Physician* 2002;65:1123–32.
- [7] Dai X, Ma W, He X, et al. Review of therapeutic strategies for osteosarcoma, chondrosarcoma, and Ewing's sarcoma. *Med Sci Monit* 2011;17:RA177–90.
- [8] Bacci G, Ferrari S, Longhi A, et al. Neoadjuvant chemotherapy for high grade osteosarcoma of the extremities: long-term results for patients treated according to the Rizzoli IOR/OS-3b protocol. *J Chemother* 2001;13:93–9.
- [9] Wallace RD, Davoudi MM, Neel MD, et al. The role of the pediatric plastic surgeon in limb salvage surgery for osteosarcoma of the lower extremity. *J Craniofac Surg* 2003;14:680–6.
- [10] Chano T, Mori K, Scotlandi K, et al. Differentially expressed genes in multidrug resistant variants of U-2 OS human osteosarcoma cells. *Oncol Rep* 2004;11:1257–63.
- [11] Li F, Tiede B, Massagué J, Kang Y. Beyond tumorigenesis: cancer stem cells in metastasis. *Cell Res* 2007;17:3–14.
- [12] O'Brien CA, Pollett A, Gallinger S, et al. A human colon cancer cell capable of initiating tumour growth in immunodeficient mice. *Nature* 2007;445:106–10.
- [13] Evans AE. Mitomycin C. *Cancer Chemother Rep* 1961;14:1–9.
- [14] Sullivan MP, Sutow WW, Taylor G. L-Phenylalanine mustard as a treatment for metastatic osteogenic sarcoma in children. *J Pediatr* 1963;63:227–37.
- [15] Norman J. Recent advances in the chemotherapy of metastatic osteogenic sarcoma. *Cancer* 1972;30:1627–31.
- [16] Rosen G, Marcove RC, CparrosF B, et al. Primary osteogenic sarcoma: the rationale for preoperative chemotherapy and delayed surgery. *Cancer* 1979;43:2163–77.
- [17] Rosen G, Caparros B, Huvos AG, et al. Preoperative chemotherapy for osteogenic sarcoma: selection of postoperative adjuvant chemotherapy based on the response of the primary tumor to preoperative chemotherapy. *Cancer* 1982;49:1221–30.
- [18] Meyers PA, Schwartz CL, Krailo MD, et al. Osteosarcoma: the addition of muramyl tripeptide to chemotherapy improves overall survival: a report from the Children's Oncology Group. *J Clin Oncol* 2008;26:633–8.
- [19] Longhi A, Ferrari S, Bacci G, et al. Long-term followup of patients with doxorubicin-induced cardiac toxicity after chemotherapy for osteosarcoma. *Anticancer Drugs* 2007;18:737–44.