

[CASE REPORT]

Successful Cord Blood Transplantation in a Werner Syndrome Patient with High-risk Myelodysplastic Syndrome

Kiyohito Hayashi¹, Taizo Tasaka^{1,2}, Toshinori Kondo¹, Yuichi Ishikawa³, Makoto Goto⁴,
Yoshiko Matsuhashi¹, Yoshito Sadahira⁵, Takashi Sugihara¹ and Hideho Wada¹

Abstract:

Werner syndrome (WS) confers a high risk of the development of neoplasias, including hematological malignancies, and curative treatment for these malignancies is difficult to achieve. A 44-year-old man with myelodysplastic syndrome was admitted to our hospital. He was diagnosed with mutation-proven WS. He underwent cord blood transplantation (CBT) following fludarabine, busulfan, and melphalan administration. A chimerism analysis of his marrow blood on day 62 showed a donor pattern >95%, which confirmed engraftment. The patient lived for 15 months while maintaining remission of MDS without treatment-related toxicity. Our case shows that CBT can be a treatment modality for WS patients with hematological malignancies.

Key words: Werner syndrome, myelodysplastic syndrome, cord blood transplantation

(Intern Med 58: 109-113, 2019)

(DOI: 10.2169/internalmedicine.0317-17)

Introduction

Werner syndrome (WS) is a rare progressive disorder characterized by accelerated aging (adult form of progeria). WS is caused by a mutation of the *WRN* gene, which is located on chromosome 8p (8p12-11.2), and is transmitted as an autosomal-recessive trait. Patients with WS suffer from a high risk of neoplasia, including hematological malignancies (1-3). The hematological malignancies reported in patients with WS include acute leukemia, myelodysplastic syndrome (MDS) (Table), and myelofibrosis (4, 5). Patients with WS are sensitive to radiation and DNA-alkylating agents, which may account for the severe adverse effects they experience after chemo-radiotherapy (6). However, at present, knowledge regarding cancer treatment in WS patients remains insufficient. Based on a few case reports that did not support this hypothesis, the practice guideline for WS in Japan recommends that no alteration to cancer treat-

ment be made because of WS, although special caution is required (7). To our knowledge, there has been no study of HSCT in patients with WS with reported complications of hematological malignancies, including MDS.

We herein report the case of a patient with WS and MDS who was successfully treated with cord blood transplantation (CBT).

Case Report

A 44-year-old man with MDS [refractory anemia with excess blasts-2 (RAEB-2)] was referred to our hospital. The patient had atrophic skin with premature wrinkling and a beaked nose that gave his face a bird-like appearance. His medical history indicated that his parents were not consanguineous, and there were no abnormalities noted in his family. He had a history of bilateral cataract surgery. A physical examination revealed that he was 155.0 cm in height (deviation value by age-rank: 22) and 28.7 kg in weight (deviation

¹Department of Hematology, Kawasaki Medical School, Japan, ²Department of Transfusion Medicine, Saitama Medical Center, Saitama Medical University, Japan, ³Department of Pathology, The Cancer Institute, Japanese Foundation for Cancer Research, Japan, ⁴Department of Rheumatology/Orthopedic Surgery, East Medical Center, Tokyo Women's Medical University, Japan and ⁵Department of Pathology, Kawasaki Medical School, Japan

Received: October 5, 2017; Accepted: April 26, 2018; Advance Publication by J-STAGE: August 24, 2018

Correspondence to Dr. Toshinori Kondo, kondot@med.kawasaki-m.ac.jp

Table. Myelodysplastic Syndrome Reported in Patients with Werner Syndrome.

Case	Sex	WS diagnostic confidence	Age at neoplasm diagnosis	Histopathologic diagnosis	Treatment	Clinical result	Reference
1	M	Possible	44	Myelodysplasia/ myelofibrosis	Etoposide	Died, sepsis	[16]
2	M	Possible	62	Myelodysplasia	Transfusion	Died, interstitial pneumonitis	[20]
3	M	Possible	61	RAEB/ myelofibrosis	Transfusion	Died, pneumonia	[21]
4	M	Probable	63	RAEB	Transfusion	Died, pneumonia	[22]
5	M	Possible	52	Myelodysplasia	Unknown	Unknown	[23]
6	M	Definite	29	RAEB-t	Unknown	Unknown	[24]
7	F	Probable	52	Myelodysplasia	Watch & wait	Unknown	[25]
8	M	Definite	43	RAEB-1	Azacitidine	Died, pneumonia	[26]
9	M	Definite	44	RAEB-2	Allo-HSCT	Complete remission	Present case

WS: Werner syndrome, M: male, F: female, RAEB: refractory anemia with excess of blast, RAEB-t: refractory anemia with excess of blast in transformation, HSCT: hematopoietic stem cell transplantation

value by age-rank: 5.5) with a body mass index of 11.9. He had scarce, gray hair, a high-pitched hoarse voice, and calcification of the Achilles' tendons; thus, he had all six of the major signs or symptoms of the WS diagnostic criteria and met four out of the seven minor criteria (8). Laboratory data showed bicytopenia with a platelet count $35 \times 10^9/L$, hemoglobin 5.7 g/dL, and white blood cell count $4.66 \times 10^9/L$.

A bone marrow examination on admission revealed markedly hypercellular marrow with 15.2% myeloblasts. Morphologic dysplasia, such as degranulated neutrophils and separated nuclear megakaryocytes, were observed. Flow cytometry revealed that the blasts were positive for CD13, CD33, CD34, CD56, and HLA-DR and negative for B and T lymphoid lineage markers. A cytogenetic analysis revealed a complex karyotype: 43, XY, add(2)(p11.2), -4, del(5)(q?), add(6)(p21), -7, del(11)(q?), -14, -17, +mar [5/20], 46, XY [15/20]. An immunohistochemical analysis of bone marrow clot sections using a polyclonal antibody against the C-terminus of WRN (Novus Biologicals, Littleton, USA) revealed that all bone marrow cells were negative for WRN; the loss of WRN expression in bone marrow sections has been demonstrated in WS patients only (9). Furthermore, a mutational analysis revealed a *WRN* gene mutation (data not shown). *WRN* gene mutation analysis was approved by the ethics committee of Kawasaki Medical School (IRB No. 2004), and the patient provided his written informed consent.

The patient achieved complete remission with hematologic improvement after his first course of induction chemotherapy, which consisted of idarubicin and cytosine arabinoside. The findings of a karyotype analysis were improved to normal; however, morphological dysplasia remained. The patient was diagnosed with high-risk MDS using the international prognostic scoring system (IPSS, score 3.0, 15.2% myeloblasts, complex karyotype, and cytopenia of 3 lineages), after which he was judged eligible for HSCT.

The patient had no intellectual disabilities. We obtained

informed consent for HSCT from him and his family. Since he did not have a suitable donor with identical human leukocyte antigen (HLA), allogeneic cord blood was selected as the stem cell source for transplantation. Although the patient had WS and a high hematopoietic cell transplantation-comorbidity index (HCT-CI) score of 3 [% of diffusing capacity of the lung Carbon monoxide (DLCO) <66%], we selected a myeloablative conditioning regimen for the CBT. After a single course of consolidation therapy, allo-HSCT was performed from 3 of eight HLA-mismatched female cord blood donors (recipient HLA: A1101/2602, B1501, Cw0303/0401, DR0405/1406; donor HLA: A1101/2402, B1501, Cw0303/0401, DR0406/0901). The conditioning regimen consisted of 180 mg/m² fludarabine (Flu) and 12.8 mg/kg intravenous injection (i.v.) busulfan (Bu) (FluBu4) plus 80 mg/m² melphalan (Mel). Anti-thymocyte globulin (1.25 mg/kg) was administered on day -2, and only tacrolimus was administered at 0.03 mg/kg/day starting on day -1 for the prophylaxis of graft-versus-host disease (GVHD). After transplantation, he developed pneumonia with alveolar hemorrhage on day 2. He was diagnosed with bacteremia on day 15. Those treatment-related toxicities were ameliorated by usual treatment and supportive care until day 39. Engraftment of neutrophils (greater than $0.5 \times 10^9/L$), red blood cells (reticulocytes greater than 1%), and platelets (greater than $20 \times 10^9/L$) was observed at day 17, day 30, and day 61, respectively. The immunostaining of bone marrow clot sections on day 30 showed that erythroblasts were positive for WRN, and TP53-positive cells were within 1% of the nucleated cell count (Figure) (9). The onset of acute GVHD was evident in the liver (stage 2) at day 18. Thereafter, the acute GVHD reached grade III with skin stage 3 and gut stage 0 at day 21. We immediately started systemic administration of 2 mg/kg methylprednisolone to gradually decrease the symptoms. A bone marrow examination on day 62 revealed normo-cellular marrow without dysplasia, and a karyotype analysis of the marrow showed a

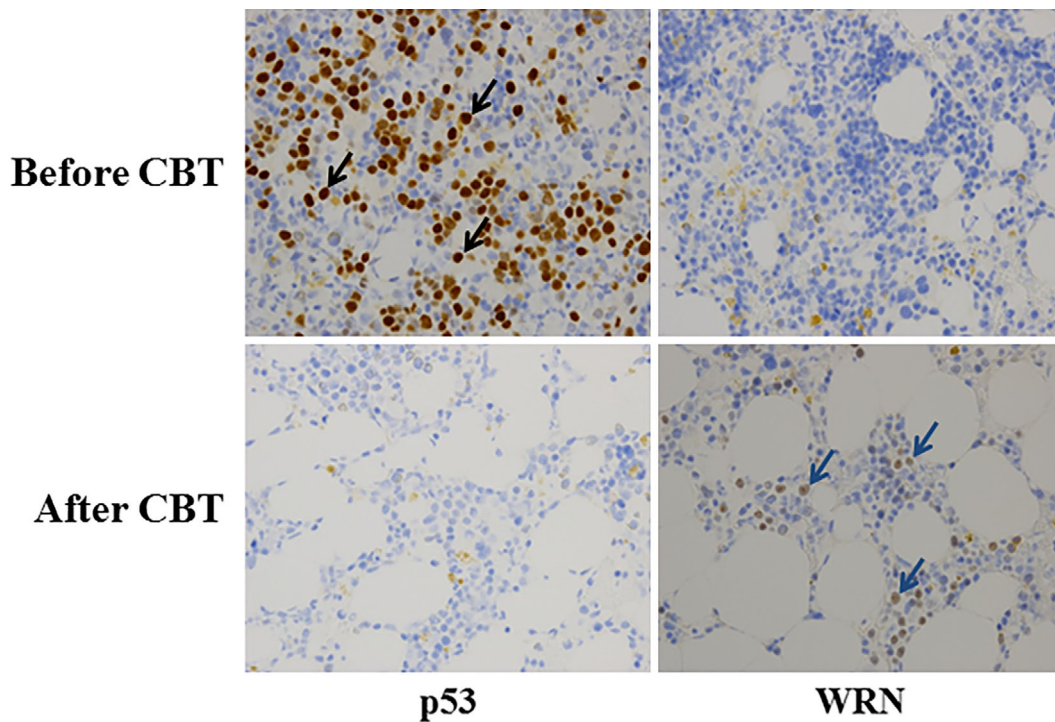


Figure. The immunohistochemical expression of p53 and WRN in a formalin-fixed, paraffin-embedded patient bone marrow clot section is shown. The antibody used for the immunostaining reacted with wild-type WRN but not with the mutated WRN of bone marrow erythroblasts. More than 30% of cells were TP53-positive (black arrows) before CBT, but TP53-positive cells were undetectable after CBT. WRN-positive cells (blue arrows) were completely absent before CBT but present after CBT. CBT: cord blood transplantation

normal female karyotype. A chimerism analysis showed complete chimerism of the donor type above 95%. The patient was discharged from our hospital on day 76 after CBT and maintained complete remission. After that, he lived for 15 months while maintaining remission of MDS, but unfortunately he ultimately died of pneumonia. No post-transplant complications like endocrine dysfunction or second malignancy were observed.

Discussion

The *WRN* gene encodes a RecQ3-DNA helicase that is necessary for DNA replication and repair. Patients with WS have elevated risks for common, clinically important, age-dependent diseases such as neoplasia and atherosclerotic cardiovascular disease, which are the most common causes of death in patients with WS, at a median of 54 years of age (10, 11). At the time of the WS diagnosis, patients have a high prevalence of cataracts (100%), osteoporosis (91%), hypogonadism (80%), diabetes mellitus (71%), neoplasia (43%), and atherosclerosis (40%) (11). Likely causes of the elevated risk of neoplasia in WS are the persistent constitutional genetic instability and DNA-damage sensitivity that are key cellular hallmarks of WS (12).

WS is diagnosed based on distinct clinical signs, but a mutational analysis of the *WRN* gene can render a definitive diagnosis. This gene analysis is laborious and expensive in a

clinical setting. We recently reported the results of an immunohistochemical analysis for the WRN protein using polyclonal serum against its C-terminus (9). The present patient satisfied all six major WS diagnostic criteria and four out of the seven minor criteria. An immunohistochemical analysis revealed that the WRN protein was completely absent in the patient's bone marrow sections, which confirmed the diagnosis of WS, and the presence of a *WRN* gene mutation in the patient's lymphocyte DNA further confirmed the diagnosis. These analyses led to an accurate diagnosis of the patient with WS and RAEB-2.

MDS is a hematologic disorder that typically presents with one or more lineage cytopenias. The therapeutic options for MDS include supportive care, various intensities of chemotherapy, or participation in a clinical trial. The patient's IPSS risk category is used in planning the therapeutic options. HSCT is a high-intensity therapy and the only method of curing MDS. Due to the fact that allogeneic HSCT was deemed necessary in our patient, we chose standard doses of induction chemotherapy to obtain early remission. The outcome of patients who receive allogeneic HSCT depends upon several factors, including their age, performance status, major comorbid conditions, and the availability of a suitable donor.

Abnormal carbohydrate metabolism, endocrine dysfunction, and arteriosclerosis in patients with WS may correspond to a higher HCT-CI score. Patients with an HCT-CI

score higher than 3 have a higher non-relapse mortality (NRM) rate, which exceeds 40% even in a young population with less-advanced disease (13). Therefore, there are more difficulties associated with performing HSCT in patients with WS than in those without WS. Recently, FluBu4 (Flu plus a myeloablative dose of 12.8 mg/m² intravenous Bu) has become widely accepted as a myeloablative regimen for allogeneic HSCT from related or unrelated donors, with acceptable regimen-related toxicities and NRM compared with other myeloablative regimens. The safety profile of Bu was strengthened by the development of an intravenous form; however, the FluBu4 regimen is associated with a relatively high relapse rate (14). In contrast, according to a recent report, the addition of Mel to the FluBu4 regimen improved the engraftment rate and decreased the relapse rate (15). Furthermore, they demonstrated that an intravenous BU/Flu+Mel or TBI regimen is feasible in CBT, and a myeloablative dose of intravenous BU does not increase NRM, even in patients with high-risk disease with old age and/or comorbidities, and may be associated with a decreased relapse rate (16). As a result, the FluBu4 regimen can accommodate a further cytotoxic agent or total-body irradiation without increasing the likelihood of NRM (17-19).

High-intensity chemotherapy is associated with a reduced risk of relapse; however, it is also associated with increased treatment-related toxicity. Therefore, there are few reports of MDS patients with WS who have received chemotherapy (Table, 20-27). In the present case, the FluBu4 plus Mel regimen was suitable as a reduced-toxicity myeloablative regimen for allogeneic HSCT. The addition of Mel might enhance antileukemic activities and improve engraftment. Thus, the FluBu4 regimen plus Mel was safely used for HSCT in a patient with WS with a high-risk HCT-CI score.

A number of cases of WRN patients with hematological malignancy have been reported, but there have been no reports of WRN patients treated with allogeneic HSCT. The findings in the present case highlight a new choice of treatment for hematological malignancies in WRN patients. Future studies should gather and compare data on various treatments according to the state of WRN patients with hematological malignancies.

In conclusion, CBT conditioned with the FluBu4 plus Mel regimen using intravenous Bu was an effective and safe conditioning regimen for an MDS patient with WS. However, knowledge concerning HSCT for patients with WS is limited, so careful observation will be needed until the long-term safety of allo-HSCT to a WRN patient can be confirmed.

The authors state that they have no Conflict of Interest (COI).

References

- Goto M, Miller RW, Ishikawa Y, et al. Excess of rare cancers in Werner syndrome (adult progeria). *Cancer Epidemiol Biomarkers Prev* **5**: 239-246, 1996.
- Ishikawa Y, Sugano H, Matsumoto T, et al. Unusual features of thyroid carcinomas in Japanese patients with Werner syndrome and possible genotype-phenotype relations to cell type and race. *Cancer* **85**: 1345-1352, 1999.
- Sugimoto M, Fruchi Y, Ide T, Goto M. Involvement of WRN helicase in immortalization and tumorigenesis by the telomeric crisis pathway (review). *Oncol Lett* **2**: 609-611, 2011.
- Björnberg A. Werner's syndrome and malignancy. *Acta Derm Venereol* **56**: 149-150, 1976.
- Sato K, Goto M, Nishioka K, et al. Werner's syndrome associated with malignancies: five case reports with a survey of case histories in Japan. *Grontology* **34**: 212-218, 1988.
- Seiter K, Qureshi A, Liu D, et al. Severe toxicity following induction chemotherapy for acute myelogenous leukemia in a patient with Werner's syndrome. *Leuk Lymphoma* **46**: 1091-1095, 2005.
- [The practice guideline for Werner syndrome] Yokote K, Ed. [Internet]. [cited 2018 Apr. 10]. Available from: <http://www.m.chiba-u.jp/dept/clin-cellbiol/files/5215/0752/8288/guideline.pdf> (in Japanese).
- Takemoto M, Mori S, Kuzuya M, et al. Diagnostic criteria for Werner syndrome based on Japanese nationwide epidemiological survey. *Geriatr Gerontol Int* **13**: 475-481, 2013.
- Sadahira Y, Sugihara T, Goto M, et al. WRN protein as a novel erythroblast immunohistochemical marker with applications for the diagnosis of Werner syndrome. *Virchows Arch* **466**: 343-350, 2015.
- Yokote K, Chanprasert S, Lee L, et al. WRN mutation update: mutation spectrum, patient registries, and translational prospects. *Hum Mutat* **38**: 7-15, 2017.
- Huang S, Lee L, Hanson NB, et al. The spectrum of WRN mutations in Werner syndrome patients. *Hum Mutat* **27**: 558-567, 2006.
- Monnat RJ Jr. Human RECQ helicases: roles in DNA metabolism, mutagenesis and cancer biology. *Semin Cancer Biol* **20**: 329-339, 2010.
- Sorror ML, Maris MB, Storb R, et al. Hematopoietic cell transplantation (HCT)-specific comorbidity index: a new tool for risk assessment before allogeneic HCT. *Blood* **106**: 2912-2919, 2005.
- Shimoni A, Hardan I, Shem-Tov N, et al. Allogeneic hematopoietic stem cell transplantation in AML and MDS using myeloablative versus reduced-intensity conditioning: the role of dose intensity. *Leukemia* **20**: 322-328, 2006.
- Yamamoto H, Uchida N, Yuasa M, et al. A novel reduced-toxicity myeloablative conditioning regimen using full-dose busulfan, fludarabine, and melphalan for single cord blood transplantation provides durable engraftment and remission in nonremission myeloid malignancies. *Biol Blood Marrow Transplant* **22**: 1844-1850, 2016.
- Yamamoto H, Uchida N, Matsuno N, et al. I.v. BU/fludarabine plus melphalan or TBI in unrelated cord blood transplantation for high risk hematological disease. *Bone Marrow Transplant* **50**: 607-609, 2015.
- Ciurea SO, Andersson BS. Busulfan in hematopoietic stem cell transplantation. *Biol Blood Marrow Transplant* **15**: 523-536, 2009.
- Abedin S, Peres E, Levine JE, et al. Double umbilical cord blood transplantation after novel myeloablative conditioning using a regimen of fludarabine, busulfan, and total lymphoid irradiation. *Biol Blood Marrow Transplant* **20**: 2062-2066, 2014.
- Sanz J, Boluda JC, Martin C, et al. Single-unit umbilical cord blood transplantation from unrelated donors in patients with hematological malignancy using busulfan, thiotepa, fludarabine, and ATG as myeloablative conditioning regimen. *Bone Marrow Transplant* **47**: 1287-1293, 2012.
- Katayama T, Saito A, Watanabe R, Kobayashi M, et al. A case of Werner's syndrome associated with myelodysplastic syndrome and myelofibrosis. *Rinsho Ketsueki* **33**: 858, 1992 (in Japanese).
- Taketomi K, Goto Y, Arai I, Ichinose M, Kinoshita K. An autopsy

- case of Werner's syndrome associated with meningioma and myelodysplastic syndrome. *To-Nyo-Byo* **33**: 180, 1990 (in Japanese).
22. Sakagami Y, Kato Y, Hatta K, Kusumi F, et al. A case of Werner's syndrome associated with RAEB and myelofibrosis. *Naika Hokan* **37**: 295, 1990 (in Japanese).
23. Mita M, Ishibashi T, Shichishima T, Maruyama Y. Myelodysplastic syndrome with multiple chromosome aberrations in a patient with Werner's syndrome. *Rinsho Ketsueki* **37**: 725-730, 1996 (in Japanese, Abstract in English).
24. Arai H, Saito Y, Uzuka Y, et al. A case of Werner's syndrome in association with leukemia. *Tohoku Igaku Zasshi* **96**: 34-39, 1983 (in Japanese, Abstract in English).
25. Undar L, Karadogan I, Artvinli M, Karpuzoglu G. Myelodysplastic syndrome in a patient with Werner's syndrome. *Acta Haematol* **92**: 150-153, 1994.
26. Ochi M, Igase M, Nagai A, et al. A case of Werner syndrome with chromosomal abnormality. *Nihon Ronen Igakkai Zasshi (Jpn J Geriatr)* **43**: 639-642, 2006 (in Japanese, Abstract in English).
27. Tamura Y, Hasegawa N, Takeda Y, et al. Azacitidine treatment for myelodysplastic syndrome in a patient with Werner syndrome. *Rinsho Ketsueki* **57**: 160, 2016 (in Japanese).

The Internal Medicine is an Open Access journal distributed under the Creative Commons Attribution-NonCommercial-NoDerivatives 4.0 International License. To view the details of this license, please visit (<https://creativecommons.org/licenses/by-nc-nd/4.0/>).