

# Laparoscopic Revision of Failed Bariatric Procedures

Constantine T. Frantzides, MD, PhD, FACS, Brad Alexander, MD, Alexander T. Frantzides

## ABSTRACT

**Background:** The main indications for revision of bariatric surgery are inadequate weight loss, weight regain, or complications. The objective of revision is to restore the restrictive component and/or add a malabsorptive component.

**Objectives:** To evaluate the effectiveness of revisional laparoscopic bariatric surgery for loss of weight and assess the risks and benefits associated with these technically demanding procedures.

**Methods:** Revision cases performed between 2001 and 2013 were identified and grouped according to the primary procedure and type of revision. A retrospective analysis was carried out for weight loss as well as perioperative morbidity and mortality.

**Results:** The total of 271 patients underwent revisional laparoscopic surgery during the study period and were categorized into four groups. Group 1 (n = 67) had an adjustable gastric band converted to gastric bypass (GBP). Group 2 (n = 128) had a dilated gastric pouch after GBP and underwent pouch reduction. Group 3 (n = 57) had a GBP and underwent pouch reduction and elongation of the biliopancreatic limb. Group 4 (n = 19) had a vertical banded gastroplasty converted to a GBP. The mean total body weight loss for Groups 1 to 4 was 35.3%, 22.9%,

39.4%, and 33.2%, respectively. The average operative times were 185, 75, 142, and 205 minutes; and the average hospitalization was 1.5, 1.0, 2.0, and 2.5 days, respectively. All cases were completed laparoscopically. Concomitant procedures were liver biopsy, cholecystectomy, partial gastrectomy, hiatal, ventral, and internal hernia repairs. Complication rates were 2.9%, 0%, 3.5%, and 5.2% for each of the groups and there were no mortalities.

**Conclusion:** Results of revisional bariatric surgery vary depending on the original procedure and the reasons for revision. In particular, if the main reason for reoperation is inadequate weight loss, then the burden is to demonstrate a surgically correctable deficiency. Revisional procedures incorporating malabsorption result in greater weight loss than gastric restriction alone.

**Key Words:** Revisional bariatric surgery; Weight loss, lap-band revision; Gastric bypass revision; Vertical banded gastroplasty revision.

Chicago Institute of Minimally Invasive Surgery, Skokie, Illinois, USA (Dr. C. Frantzides, Mr. A. Frantzides).

Presence St. Francis Hospital, Evanston, Illinois, USA (Dr. Alexander).

Financial Support: Institutional support was provided for this work.

Disclosures: none.

Conflicts of Interest: All authors declare no conflict of interest regarding the publication of this article.

Informed consent: Dr. Frantzides declares that written informed consent was obtained from the patient/s for publication of this study/report and any accompanying images.

Address correspondence to: Constantine T. Frantzides, MD, PhD, FACS, Chicago Institute of Minimally Invasive Surgery, 4709 Golf Road, Suite 1020, Skokie, IL 60076, USA. Telephone: 847-676-2200, Fax: 847-676-1813, E-mail: cfrantzides@cimis.info

DOI: 10.4293/JSLS.2018.00074

© 2019 by JSLS, *Journal of the Society of Laparoendoscopic Surgeons*. Published by the Society of Laparoendoscopic Surgeons, Inc.

## INTRODUCTION

Bariatric surgery has been shown to be a safe and effective long-term treatment for obesity. Over the past 25 years, there has been an increase in the number of primary bariatric operations in the United States. As a result of this increasing trend, revisional bariatric procedures are expected to increase.<sup>1</sup> The incidence of revisional bariatric surgery is between 3% and 60%,<sup>2</sup> depending upon the type of primary operation. Over a decade of followup, approximately 29%–39% of patients who underwent a vertical banded gastroplasty will require a revision.<sup>2–5</sup> Revision rate for patients who undergo an adjustable gastric banding is between 10.5% and 60%.<sup>6–8</sup> Of the patients who underwent a gastric bypass (GBP), 15%–35% will undergo revisional surgery.<sup>9,10</sup> There are technical and logistical challenges when performing laparoscopic revisional bariatric surgery thus preoperative, operative, and postoperative guidelines should be observed.

The indications for revisional bariatric surgery are inadequate weight loss, weight regain, or complications. Inadequate weight loss or weight regain can occur after verti-

cal banded gastroplasty, adjustable gastric banding, or GBP due to pouch or anastomotic dilation. The goals of revisional surgery for weight loss are to restore gastric restriction, add malabsorption, or both. Due to adhesive disease and altered anatomy, revisional procedures are expectedly more complex with increased morbidity compared to primary bariatric procedures.<sup>11</sup> We present our series on the outcomes of revisional bariatric surgery for weight loss.

## METHODS

Revision cases performed between 2001 and 2013 were identified and retrospectively analyzed. Patient age, sex, weight, type of primary procedure, type of revision, concomitant procedure, duration of surgery, length of stay, 30-day morbidity, and mortality were recorded.

Preoperative evaluation of the anatomy included, esophagogastroduodenoscopy, and upper gastrointestinal contrast studies. Obtaining the operative report of the prior procedure, although very important, it wasn't always feasible. The cause of failure was identified both by extensive clinical and laboratory evaluation, and the available surgical options for revision were considered. Preoperative preparation included mechanical bowel prep and oral antibiotics (modified Condon-Nichols Bowel Prep). Patients were followed up at 1 week, 1 month, 3 months, 6 months, and yearly thereafter.

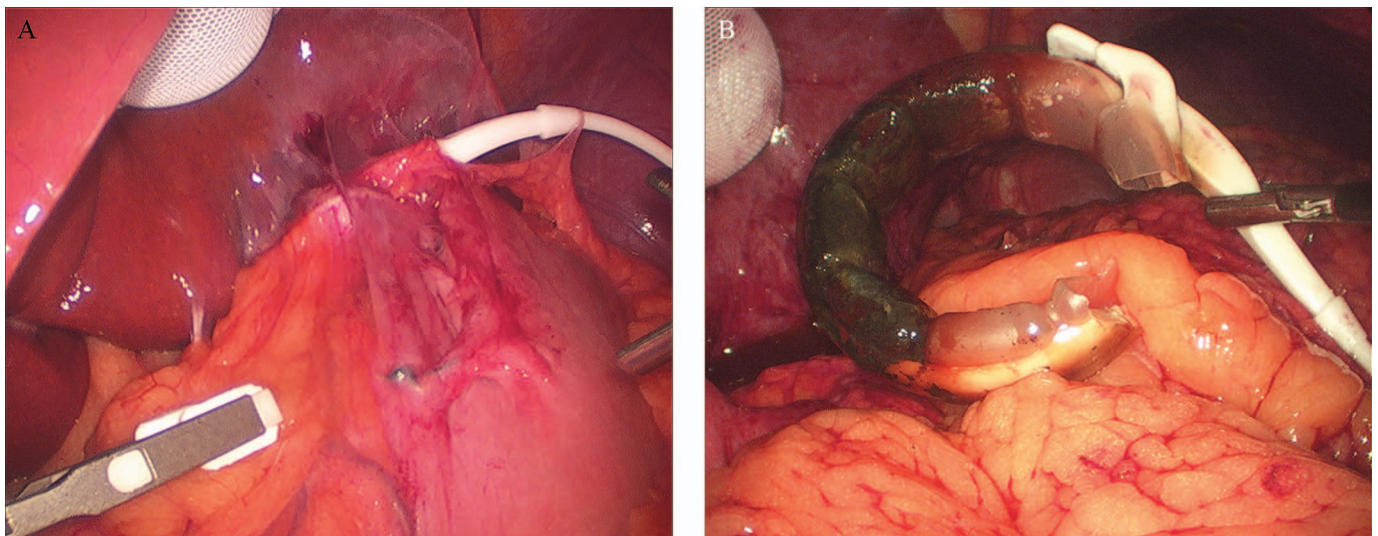
### Patients Were Categorized into Four Groups

Group 1 had an adjustable gastric band converted to gastric bypass as a single-stage operation. The primary

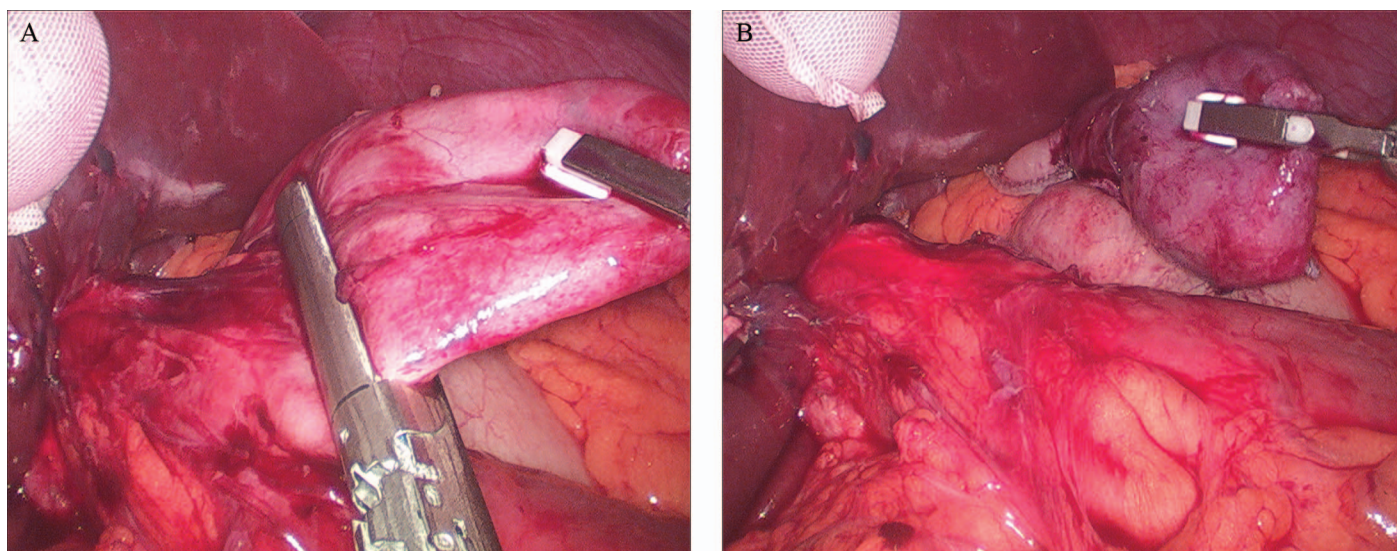
reason for revision was failure to lose weight or regain of weight. In this group there were also patients with erosion of the band into the stomach or slipped band. Invariably, from the technical point of view, dense adhesions are encountered in the area of the band and careful dissection is imperative (**Figure 1A**). Gentle traction on the tubing would lead the surgeon to the band buckle. The reactive capsule around the band is divided sharply by scissors. Energy source is sparingly used during this dissection to avoid thermal injury to the surrounding tissue. The band is then divided and removed (**Figure 1B**). The gastric tissue is evaluated for viability and a typical Roux-en-Y is constructed.<sup>12</sup> In the presence of erosion/perforation of the stomach a partial gastrectomy was performed.<sup>13</sup>

Group 2 had a dilated gastric pouch after GBP and underwent a pouch reduction. Preoperative radiologic evaluation with contrast showed enlarged pouch ( $>8 \times 12$  cm). Most of these patients had a prior side-to-side linear stapler gastrojejunostomy rather than a circular stapler anastomosis and the gastrojejunostomy was quite large. Thus combined gastric pouch and anastomotic reduction was carried out. The dilated gastric pouch is mobilized from the surrounding tissue including the bypassed stomach. A lighted bougie is introduced into the pouch and through the gastrojejunostomy and is used both for identification of anatomic landmarks as well as a measure for the reconstruction of the gastric pouch (**Figure 2A and 2B**).<sup>13</sup>

Group 3 had a GBP and underwent pouch reduction as well as elongation of the biliopancreatic limb. This procedure consists of a revision of both the gastrojeju-



**Figure 1.** (A) Laparoscopic view of slipped adjustable gastric band. (B) Appearance of eroded adjustable gastric band after removal.



**Figure 2.** (A) Reduction of a large gastric pouch along a lighted bougie. (B) Transected pouch with resultant small receptacle.

nostomy and jejunojunostomy. The pouch is reduced as described in Group 2 and the biliopancreatic limb is elongated up to 150cm to allow for more malabsorption. The Frantzides-Madan Triple-Stapling Technique<sup>14</sup> is utilized for the reconstruction of the jejunojunostomy.<sup>12,13</sup>

Group 4 had a vertical banded gastroplasty converted to GBP. All patients in this group underwent a prior open surgery and extensive intra-abdominal adhesions were encountered during the revision surgery. Following the adhesiolysis and identification of anatomic landmarks, entry into the lesser sac is accomplished through the greater curvature of the stomach by division of the short gastric vessels. Mobilization of the stomach in the area of the band can be challenging. The gastric pouch is created 5 cm distal to the gastroesophageal junction and medial to the prior staple line of the vertical banded gastroplasty. The identification of the prior staple line is of most im-

portance to avoid lateral transection of the stomach that may result in ischemia and necrosis of the tissue in between the staple lines. A partial gastrectomy is performed that includes the remnant of the fundus and part of the corpus of the stomach that contains the band.<sup>13</sup> Roux-en-Y gastric bypass is then performed.

It is important to emphasize that due to thick tissue secondary to fibrosis it was necessary to use “thick tissue staplers” in most of the patients in all groups. All procedures were performed laparoscopically and none was aborted. The type of revision was determined by extensive preoperative evaluation of the causes of failure and/or complications. Emphasis was placed on long-term postoperative care, patient compliance, and behavioral modifications.

Data were analyzed using SPSS version 21 (IBM, Chicago, IL) and significance was  $P < .05$ .

**Table 1.**  
Patient Groups and Demographics

Surgery	Conversion	Number of Patients	Median Age (Years)	Sex (% Female)	BMI (kg/m <sup>2</sup> )
Group 1	AGB→GBP	67	38	76	40 ± 2.8
Group 2	GBP pouch reduction	128	41	69	38 ± 3.2
Group 3	GBP pouch reduction and elongation of BP limb	57	46	83	47 ± 4.9
Group 4	VBG→GBP	19	67	100	46 ± 5.3

AGB, adjustable gastric banding; BMI, body mass index; BP, biliopancreatic; GBP, gastric bypass; VBG, vertical banded gastroplasty.

**Table 2.**  
Weight Losses After Revisional Bariatric Surgery

Surgery	Mean Total Body Weight Loss (%)
Group 1	35.3 ± 2.2
Group 2	22.9 ± 3.5*
Group 3	39.4 ± 2.1
Group 4	33.2 ± 3.1

\*Statistically significant ( $P < .05$ ) less weight loss compared to other groups.

## RESULTS

A total of 271 patients underwent revisional surgery during the study period and were categorized into four groups as described in Table 1. Group 1 consisted of 67 patients with a median age of 38 years and 76% were female. Group 2 consisted of 128 patients with a median age of 41 years and 69% were female. Group 3 consisted of 57 patients with a median age of 46 years and 83% were female. Group 4 consisted of 19 patients with a median age of 67 years and 100% were females. The average body mass index of the respective groups was  $40 \pm 2.8$ ,  $38 \pm 3.2$ ,  $47 \pm 4.9$ , and  $46 \pm 5.3$  kg/m<sup>2</sup>.

The mean total body weight loss results within the 3 postoperative years for Groups 1–4 were  $35.3 \pm 2.2\%$ ,  $22.9 \pm 3.5\%$ ,  $39.4 \pm 2.1\%$ , and  $33.2 \pm 3.1\%$ , respectively (Table 2). Patients in Group 2 lost significantly less weight when compared to the other three groups. The follow up ranged from 3 to 12 years with a median of 4.2 years.

The perioperative outcomes are shown in (Table 3). The average operative times were  $185 \pm 27$ ,  $75 \pm 11$ ,  $142 \pm 18$ , and  $205 \pm 31$  minutes. The average hospital stays were  $1.5 \pm 0.3$ , 1.0,  $2.0 \pm 0.5$ , and  $2.5 \pm 0.3$  days. Patients in Group 2 had significantly shorter operative time and hospitalization compared to the other three groups. All cases were completed laparoscopically. Concomitant proce-

dures were partial gastrectomy, cholecystectomy, liver biopsy, hiatal, ventral, and internal hernia repairs.

Two patients (2.9%) in Group 1 experienced a complication after surgery. One patient had a Gastrointestinal (GI) bleeding requiring 3 Units of packed red blood cells transfusion while the other patient had a trocar site wound infection. Patients in Group 2 did not experience any complications. Two patients (3.5%) in Group 3 developed a complication after surgery. One patient had GI bleeding requiring 4 U of packed red blood cell transfusion and the other developed a deep venous thrombosis. One patient (5.2%) in Group 4 developed a large abdominal wall hematoma. The overall complication rate for our series was 1.8%. None of the patients required an operative intervention and there were no mortalities.

## DISCUSSION

This study is a report of our experience with 271 patients who underwent laparoscopic revisional bariatric surgery for weight loss and with a median follow up of 4.2 years. Patients who underwent restrictive revisions alone lost significantly less weight than those who underwent mal-absorptive with or without additional restrictive procedures. The weight loss outcomes following our revisions (23%–39%) are comparable to other previously published studies.<sup>5–8</sup>

Laparoscopic revisional bariatric surgery is a complex and technically challenging surgery. The complications are generally higher than those of primary bariatric surgery.<sup>11</sup> A report of the Longitudinal Assessment of Bariatric Surgery data showed that compared to primary bariatric surgery, revisional surgery was associated with higher (odds ratio, 2.3) morbidity but similarly low (0.4%) mortality.<sup>15</sup> Careful patient selection and experience with all laparoscopic revisional surgery are key factors to minimizing morbidity. Our perioperative outcomes of 1.8% morbidity

**Table 3.**  
Perioperative Outcomes

Surgery	Duration of Surgery (Minutes)	LOS (Days)	Complication Rate (%)	Complication Description
Group 1	185 ± 27	1.5 ± 0.3	2.9	GI bleeding, wound infection
Group 2	75 ± 11	1.0 ± 0.0	0.0	None
Group 3	142 ± 18	2.0 ± 0.5	3.5	GI bleeding, DVT
Group 4	205 ± 31	2.5 ± 0.3	5.2	Abdominal wall hematoma

GI, gastrointestinal; DVT, deep venous thrombosis; LOS, length of stay.

and 0% mortality are low and comparable to more recent reports.<sup>16</sup>

In our experience, the conversion of an adjustable gastric banding to a gastric bypass can be performed as a single-stage procedure without an increased risk of an anastomotic leak. Gastrojejunostomy leaks after revisional bariatric surgery are between 0 and 12.9%<sup>16–19</sup> and the range is likely a reflection of both the surgeon's skills and experience. We believe that the choice of staplers is of most importance to avoid staple line and/or anastomotic leaks. Anastomotic disruptions may also be caused by tissue ischemia. Thus when reconstruction of anastomosis is carried out the surgeon should ensure that it is constructed on the healthiest tissue possible. Furthermore reinforcement of the anastomosis with interrupted sutures may be wise. Our leak rate was 0% and overall complication rate was at 1.8%, compared to previous reports ranging from 6% to 46.3%.<sup>17–19</sup> Two patients (0.73%) had postoperative staple line bleeding that required blood transfusion. It is possible that the bleeding was the result of the use of larger staples but this is a speculation.

The main cause of failure in GBP is pouch dilation. In our series, GBP patients who underwent pouch reduction had the lowest total body weight loss of 22.9%. However, this group had no complications, which is significant improvement compared to other studies, such as Iannelli et al<sup>20</sup> with a 30% complication rate. Another group of our patients underwent pouch reduction, in addition to elongation of the biliopancreatic limb. The combination of this type of bariatric surgery revision has not been cited in the literature. In our series, this group of patients had the highest total body weight loss of 39.4%, and a complication rate of 3.5%.

Patients who underwent vertical banded gastroplasty have the advantage of a restrictive procedure, but those who failed have demonstrated success with adding the malabsorptive component by revision to a GBP. For our series of patients, there was a successful total body weight loss of 33.2%. In this group there was only one complication (abdominal wall hematoma). This complication rate is comparable, if not better, than other studies in the literature, which range from 3.9% to 33%.<sup>21</sup> None of our morbidities were due to anastomotic leak.

This series is the largest reported cohort of laparoscopic revisional procedures, but even with these numbers the subgroups are small. Additionally, our study is retrospective and the decision on the type of revisional surgery was not controlled. Our median follow up is 4.2 years and long-term outcomes were not assessed.

In conclusion, laparoscopic revisional bariatric surgery is technically demanding but it is safe and effective when the causes of failure of the primary procedure were identified, addressed and corrected by an experienced laparoscopic team. Revisional procedures involving the addition of malabsorption result in a greater weight loss than gastric restriction alone.

### References:

1. Sudan R, Nguyen NT, Hutter MM, Brethauer SA, Ponce J, Morton JM. Morbidity, mortality, and weight loss outcomes after reoperative bariatric surgery in the USA. *J Gastrointest Surg.* 2015;19(1):171–178; discussion 178–179.
2. Jones KB Jr. Revisional bariatric surgery—Potentially safe and effective. *Surg Obes Relat Dis.* 2005;1:599–603.
3. Scozzari G, Toppino M, Famiglietti F, Bonnet G, Morino M. 10-year follow-up of laparoscopic vertical banded gastroplasty: Good results in selected patients. *Ann Surg.* 2010;252(5):831–839.
4. van Gemert WG, van Wersch MM, Greve JW, Soeters PB. Revisional surgery after failed vertical banded gastroplasty: Restoration of vertical banded gastroplasty or conversion to gastric bypass. *Obes Surg.* 1998;8(1):21–28.
5. van Wezenbeek MR, Smulders JF, de Zoete JP, Luyer MD, van Montfort G, Nienhuijs SW. Long-term results of primary vertical banded gastroplasty. *Obes Surg.* 2015;25(8):1425–1430.
6. Elnahas A, Graybiel K, Farrokhhyar F, Gmora S, Anvari M, Hong D. Revisional surgery after failed laparoscopic adjustable gastric banding: A systematic review. *Surg Endosc.* 2013;27(3):740–745.
7. Fournier P, Gero D, Jankechova A, et al. Laparoscopic Roux-en-Y gastric bypass for failed gastric banding: Outcomes in 642 patients. *Surg Obes Relat Dis.* 2016;12(2):231–239.
8. O'Brien PE, McDonald L, Anderson M, Brennan L, Brown WA. Long-term outcomes after bariatric surgery: Fifteen-year follow-up of adjustable gastric banding and a systematic review of the bariatric surgical literature. *Ann Surg.* 2013;257(1):87–94.
9. Nguyen D, Dip F, Huaco JA, et al. Outcomes of revisional treatment modalities in non-complicated Roux-en-Y gastric bypass patients with weight regain. *Obes Surg.* 2015;25(5):928–934.
10. Brolin RE, Cody RP. Adding malabsorption for weight loss failure after gastric bypass. *Surg Endosc.* 2007;21(11):1924–1926.
11. Zhang L, Tan WH, Chang R, Eagon JC. Perioperative risk and complications of revisional bariatric surgery compared to primary Roux-en-Y gastric bypass. *Surg Endosc.* 2015;29(6):1316–1320.

12. Frantzides CT, Zografakis J. In: Frantzides CT, Carlson M, eds. *Laparoscopic Roux-en-Y gastric bypass. Atlas of minimally invasive surgery*. Philadelphia, PA. Elsevier & Saunders; 2008, 74–79.
13. Frantzides CT, Zografakis J, Scott W, Ralph T. In: Frantzides CT, Carlson M, eds. *Revisional bariatric surgery. Video atlas of advanced minimally invasive surgery*. Elsevier & Saunders; 2013, 53–56. Philadelphia, PA.
14. Frantzides CT, Zeni TM, Madan AK, Zografakis JG, Moore RE, Laguna L. Laparoscopic Roux-en-Y gastric bypass utilizing the triple stapling technique. *JSLS* 2006;10(2):176–179.
15. Inabnet WB 3rd, Belle SH, Bessler M, et al. Comparison of 30-day outcomes after non-LapBand primary and revisional bariatric surgical procedures from the Longitudinal Assessment of Bariatric Surgery study. *Surg Obes Relat Dis*. 2010;6(1):22–30.
16. Aarts E, Koehestanie P, Dogan K, Berends F, Janssen I. Revisional surgery after failed gastric banding: results of one-stage conversion to RYGB in 195 patients. *Surg Obes Relat Dis*. 2014;10(6):1077–1083.
17. Mognol P, Chosidow D, Marmuse JP. Laparoscopic conversion of laparoscopic gastric banding to Roux-en-Y gastric bypass: A review of 70 patients. *Obes Surg*. 2004;14(10):1349–1353.
18. Spivak H, Beltran OR, Slavchev P, Wilson EB. Laparoscopic revision from LAP-BAND to gastric bypass. *Surg Endosc*. 2007; 21(8):1388–1392.
19. Stefanidis D, Malireddy K, Kuwada T, Phillips R, Zoog E, Gersin KS. Revisional bariatric surgery: Perioperative morbidity is determined by type of procedure. *Surg Endosc*. 2013;27(12): 4504–4510.
20. Iannelli A, Schneck AS, Hébuterne X, Gugenheim J. Gastric pouch resizing for Roux-en-Y gastric bypass failure in patients with a dilated pouch. *Surg Obes Relat Dis*. 2013;9(2): 260–267.
21. Iannelli A, Amato D, Addeo P, et al. Laparoscopic conversion of vertical banded gastroplasty (Mason MacLean) into Roux-en-Y gastric bypass. *Obes Surg*. 2008;18(1):43–46.