

Unusual Presentation of Methicillin-Resistant *Staphylococcus aureus* Colitis Complicated with Acute Appendicitis

Elias Estifan, Sushant M. Nanavati¹, Vinod Kumar², Aarohi Vora³, Moayyad Alziadat¹, Ahmed Sharaan¹, Mourad Ismail¹

Department of Medicine, St. Joseph's University Medical Center, ¹Division of Pulmonary and Critical Care, St. Joseph's University Medical Center, ²Division of Hematology and Oncology, St. Joseph's University Medical Center, ³Medical Student at St. Joseph's University Medical Center, Paterson, NJ, USA

Abstract

Clostridium difficile colitis has been the most recognized bacterial enterocolitis for years and other bacteria such as *Staphylococcus colitis* has been relegated. *Staphylococcus enterocolitis* following antibiotics had been one of the most frequent complications in surgical patients in the 1950s and 1960s and now reappear with more resistance such as methicillin-resistant *Staphylococcus aureus* (MRSA) colitis which brings a new challenge. A 32-year-old Hispanic female with a history of type I diabetes mellitus presenting with altered sensorium and a 2-day history of watery, nonbloody diarrhea, intractable emesis, and diffuse crampy abdominal pain. About a month before the presentation, the patient had a soft-tissue laceration on the left foot requiring a 7-day course of cephalexin and clindamycin that healed appropriately. On physical examination, she was tachycardic with heart rate of 110 bpm and tachypneic with respiratory rate of 28, somnolent but arousable with the Glasgow Coma Scale >12. The abdomen was soft, tender diffusely to palpation without rebound or guarding. On the biochemical analysis, her blood glucose was 968 mg/dL with anion gap metabolic acidosis (AG 46). In the intensive care unit, she initiated on intravenous (IV) fluids, insulin, and IV antibiotics for suspicion of colitis. *Clostridium difficile* testing was negative, but stool cultures grew MRSA for which she was started on vancomycin and TMP-SMX. Due to continued abdominal pain on antibiotics, computed tomography of the abdomen with contrast showed acute appendicitis with inflammatory debris and without perforation or abscess requiring laparoscopic appendectomy. Our case presented with diabetic ketoacidosis (DKA), which complicates the etiology of abdominal pain on admission for the clinician masking-MRSA colitis associated with a rare complication of appendicitis double challenge and difficult to diagnose as most DKA patients present with abdominal pain. This is the first case report describing MRSA enterocolitis in patient with DKA complicated by acute appendicitis.

Keywords: Antibiotic-associated enterocolitis, appendicitis, methicillin-resistant *Staphylococcus aureus*

INTRODUCTION

Incorrect or overprescribing of antibiotics puts patients at risk for antibiotic-associated infections, especially enterocolitis. Due to increased awareness of *Clostridium difficile* colitis, other bacterial causes of enterocolitis have been relegated or may have been overlooked, such as methicillin-resistant *Staphylococcus aureus* (MRSA) colitis. In the 1950s and 1960s, *Staphylococcal* enterocolitis was possibly the most common etiology of antibiotic-associated diarrhea and enterocolitis. We present the unique case of MRSA enterocolitis in a patient with diabetic ketoacidosis (DKA) that was complicated by acute appendicitis.

CASE REPORT

A 32-year-old Hispanic female presented with altered sensorium for the past 3–4 h. Before the presentation, she experienced a 2-day history of severe bouts of diarrhea and emesis, along with nausea and abdominal pain. Diarrhea

Address for correspondence: Dr. Elias Estifan MD,
703 Main St, Paterson, NJ 07503, USA.
E-mail: egestifan@gmail.com

This is an open access journal, and articles are distributed under the terms of the Creative Commons Attribution-NonCommercial-ShareAlike 4.0 License, which allows others to remix, tweak, and build upon the work non-commercially, as long as appropriate credit is given and the new creations are licensed under the identical terms.

For reprints contact: reprints@medknow.com

How to cite this article: Estifan E, Nanavati SM, Kumar V, Vora A, Alziadat M, Sharaan A, *et al.* Unusual presentation of methicillin-resistant *Staphylococcus aureus* colitis complicated with acute appendicitis. *J Global Infect Dis* 2020;12:34-6.

Received: 14 September 2019 **Revised:** 13 November 2019

Accepted: 06 December 2019 **Published:** 19 February 2020

Access this article online

Quick Response Code:



Website:
www.jgid.org

DOI:
10.4103/jgid.jgid_117_19

was described as nonbloody and watery, followed by diffuse and crampy abdominal pain. She has a history of type I diabetes mellitus for which she was nonadherent with her insulin regimen and an episode of DKA about 1 year before presentation. About a month before presentation, the patient had a soft-tissue laceration on the left foot requiring a 7-day course of cephalexin and clindamycin, which resulted in proper healing of wound.

Vital signs exhibited blood pressure of 126/81 mmHg, a heart rate of 110 beats/min, a respiration rate of 23 breaths/min, and no fever. Examination showed somnolence requiring voice and touch for arousal. Abdominal examination revealed a soft abdomen with hyperactive bowel sounds and diffuse tenderness, but no guarding or rebound tenderness. On the biochemical analysis, she had blood glucose 917 mg/dL and anion gap metabolic acidosis with a gap of 47. Table 1 shows additional biochemical values appropriate to the time interval.

Based on the patient's history of nonadherence with medications and immunocompromised, suspicion of colitis precipitated by DKA was high. She started on intravenous (IV) normal saline, IV insulin infusion, and admitted to the intensive care unit. Due to the severity of her presentation, piperacillin-tazobactam was added to cover Gram-negative bacteria. In addition, IV metronidazole was received for clostridium difficile. The patient's mentation improved over the next 8–12 h, her blood glucose decreased at the appropriate rate, and the anion gap improved transitioning to subcutaneous insulin, as she started to tolerate an oral liquid diet. The patient's diarrhea continued with diffuse abdominal pain. Although Clostridium difficile testing (GDH antigen/toxin and polymerase chain reaction) and stool lactoferrin were negative, stool cultures grew methicillin-resistant *Staphylococcus aureus* (MRSA). The patient was started on oral vancomycin, 500 mg every 6 h, and ciprofloxacin 500 mg, and trimethoprim 160 mg and sulfamethoxazole 800 mg, 1 tablet twice a day. Although her diarrheal frequency improved, patient continued to complain about crampy abdominal pain that hindered her ability to tolerate an oral diet. Computed tomography (CT) of the abdomen and pelvis with contrast showed acute appendicitis with inflammatory debris requiring laparoscopic appendectomy [Figure 1]. Subsequently, the patient tolerated the procedure and was discharged without any sequela on follow-up in the outpatient clinic.

DISCUSSION

Although Staphylococcal species are known to cause of antibiotic-associated colitis, MRSA colitis cases are of great concern and may pose a challenge in treatment if not diagnosed accurately and managed appropriately.^[1] An aging population, misuse of antibiotics, gastric acid suppression, hospitalization, exposure to antibiotics, and/or MRSA colonization are some of the most common risk factors.^[2,3] Whenever any risk factors promote dysbiosis among normal flora, causing staphylococcus overgrowth with toxin induction, it leads to inflammation resulting in diarrhea. A toxin-mediated mechanism causes the majority of Staphylococcus enterocolitis, mostly enterotoxins-A, B, C, D, and E, as well as TSST-1; also, Leukocidin LukE-LukD has been noted as a cause for Staphylococcus enterocolitis. In one study by Boyce and Havill of 11 patients with MRSA enterocolitis, found SEA, SEB, SED, and SEE as the main enterotoxins in nine patients and one patient positive for TSST-1.^[4] Staphylococcal leukocidin LukE-LukD also had proposed involvement in the disease process through a cytotoxic mechanism.^[5]

Majority of the patients presenting to the emergency department with antibiotic-associated diarrhea are investigated for Clostridium difficile testing; stool cultures may be delayed or not performed at all. That may explain the underdiagnosis of MRSA colitis or lack of stool culture growth and re-establishes the importance of stool culture in a timely manner on presentation of a patient with suspected colitis.

Our case presented with DKA on admission, which complicates the etiology of abdominal pain for the clinician, masking MRSA colitis that further progressed to appendicitis. There were no previous case reports of MRSA enterocolitis presenting with DKA or complication of acute appendicitis; a

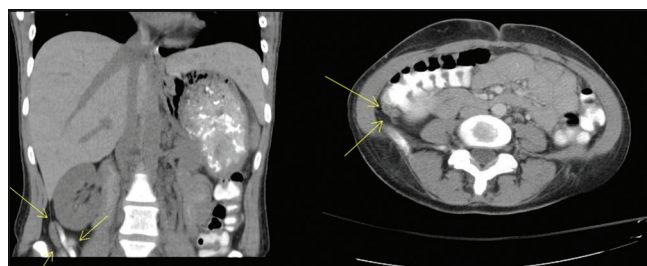


Figure 1: Computed tomography scan showing an acute appendicitis

Table 1: Additional biochemical values appropriate to the time interval

Electrolytes	T: 0 (on admission)	T: Day 2	CBC w/diff	T: 0 (on admission)	T: Day 2
Sodium (mEq/L)	136	137	WBC ($10^3/\text{mm}^3$)	19.8	6.7
Potassium (mEq/L)	4.7	3.7	Hgb (g/dl)	12.1	10.3
Chloride (mEq/L)	83	110	Platelet (K/mm^3)	360	215
Bicarbonate (mEq/L)	6	21	Neutrophils (%)	88	60
Creatinine (mg/dl)	1.75	0.64	Lymphocyte (%)	7	32
Phosphorus (mg/dl)	5.5	1.8	Monocyte (%)	5	8
Magnesium (mg/dl)	2.3	2.0	Eosinophils (%)	0	0

WBC: White blood cell, Hgb: Hemoglobin, CBC: Complete blood count

greater awareness of this possibility should be considered so appropriate diagnostic testing can be pursued. Oral vancomycin is the suggested treatment of choice for MRSA enterocolitis, although studies are limited. Our patient responded with a combination of vancomycin and TMP-SMX. Although the role in the pathogenesis of MRSA in antibiotic-associated enterocolitis remains controversial, the actual incidence with its associated complications may be underestimated due to a lack of awareness, testing, and recognition.

Declaration of patient consent

The authors certify that they have obtained all appropriate patient consent forms. In the form the patient(s) has/have given his/her/their consent for his/her/their images and other clinical information to be reported in the journal. The patients understand that their names and initials will not be published and due efforts will be made to conceal their identity, but anonymity cannot be guaranteed.

Financial support and sponsorship

Nil.

Conflicts of interest

There are no conflicts of interest.

REFERENCES

1. Iwata K, Doi A, Fukuchi T, Ohji G, Shirota Y, Sakai T, *et al.* A systematic review for pursuing the presence of antibiotic associated enterocolitis caused by methicillin resistant *Staphylococcus aureus*. BMC Infect Dis 2014;14:247.
2. Avery LM, Zempel M, Weiss E. Case of antibiotic-associated diarrhea caused by *Staphylococcus aureus* enterocolitis. Am J Health Syst Pharm 2015;72:943-51.
3. Nguyen GC, Patel H, Chong RY. Increased prevalence of and associated mortality with methicillin-resistant *staphylococcus aureus* among hospitalized IBD patients. Am J Gastroenterol 2010;105:371-7.
4. Boyce JM, Havill NL. Nosocomial antibiotic-associated diarrhea associated with enterotoxin-producing strains of methicillin-resistant *staphylococcus aureus*. Am J Gastroenterol 2005;100:1828-34.
5. Gravet A, Rondeau M, Harf-Monteil C, Grunenberger F, Monteil H, Scheffel JM, *et al.* Predominant *Staphylococcus aureus* isolated from antibiotic-associated diarrhea is clinically relevant and produces enterotoxin A and the bicomponent toxin lukE-lukD. J Clin Microbiol 1999;37:4012-9.