

# Risk Factors for Capsular Contracture: A Retrospective Study in Immediate Reconstruction versus Delayed Reconstruction

Maiko de Kerckhove, MD, PhD  
Yoshiko Iwahira, MD, PhD

**Background:** Capsular contracture is a common complication among breast implant reconstruction patients. The aim of this study was to assess the duration of and risk factors associated with capsular contracture by comparing 2 reconstruction methods.

**Methods:** The medical charts of patients who received a reconstructed breast implant and underwent a capsule revision surgery were retrospectively reviewed. We examined patients' background, skin expansion duration, time taken until capsule revision surgery, tissue expander/implant size, and postoperative complications.

**Results:** Of the total 74 breasts [42 immediate reconstruction (Immediate) and 32 delayed reconstruction (Delayed) breasts], the age at the revision surgery was significantly older in the Delayed (59 years) than in the Immediate category (50 years;  $P = 0.002$ ). The time taken until the capsule revision surgery was significantly shorter for the Immediate (63.5 months) than for the Delayed (121 months;  $P < 0.0001$ ). The postoperative complication rate after expander insertion was significantly higher in the Immediate (62.5%) than in the Delayed (21.1%;  $P < 0.0001$ ). The size of the expander and implant was significantly smaller in the Immediate (expander, 300 mL; implant, 240 mL) than in the Delayed (expander, 400 mL; implant, 300 mL) (expander,  $P = 0.008$ ; implant,  $P = 0.004$ ).

**Conclusions:** The immediate reconstruction breasts had a shorter time to capsule revision surgery than the delayed reconstruction breasts. Our study suggested that the shorter time in immediate reconstruction was affected by postoperative complications after mastectomy with expander insertion and by selection of a smaller sized expander and implant. (*Plast Reconstr Surg Glob Open* 2020;8:e2864; doi: 10.1097/GOX.0000000000002864; Published online 21 May 2020.)

## INTRODUCTION

Capsular contracture is the most common long-term complication associated with breast implants.<sup>1</sup> The Baker classification (grade I–IV) defines degrees of clinical symptoms, with obvious visible malformations and stiffness appearing at degree III, and constant pain at degree IV.<sup>1,2</sup> If patients experience a Baker grade III or IV capsule contracture, they will eventually require reoperation (capsule revision surgery). A certain amount of capsular contracture often occurs over time; however, if a severe or painful capsular contracture occurs within a relatively

short time, the patients can experience physical and mental pain as a result of the reconstruction, which defeats its purpose.

Some risk factors for capsular contracture have been proposed,<sup>3–5</sup> which include a longer duration of follow-up, subglandular implant placement, textured implant surface, minor chronic infection, hematoma formation, irradiation, patient age, and implant volume. Most reports have either discussed both augmentation and reconstruction cases or focused only on augmentation cases. Therefore, an accurate knowledge of the risk factors for capsular contracture in reconstruction remains elusive. Because the mammary gland will be absent after a mastectomy, only a thin layer of skin and subcutaneous tissue remains for the breast reconstruction. This not only makes it difficult for the surgeon to achieve natural forms and to match the reconstructed breast to the other breast, but the condition of the remaining skin and the surgical invasion also cause a higher rate of postoperative complications. Therefore, breast reconstruction is quite different

From the Breast Surgery Clinic, Tokyo, Japan.

Received for publication January 11, 2020; accepted March 26, 2020.

Copyright © 2020 The Authors. Published by Wolters Kluwer Health, Inc. on behalf of The American Society of Plastic Surgeons. This is an open-access article distributed under the terms of the [Creative Commons Attribution-Non Commercial-No Derivatives License 4.0 \(CCBY-NC-ND\)](https://creativecommons.org/licenses/by-nc-nd/4.0/), where it is permissible to download and share the work provided it is properly cited. The work cannot be changed in any way or used commercially without permission from the journal.

DOI: 10.1097/GOX.0000000000002864

**Disclosure:** The authors have no financial interest to declare in relation to the content of this article.

from breast augmentation. We believe that reconstruction and augmentation should be discussed separately to better understand capsular contracture.

Two types of 2-stage reconstruction are commonly practiced in Japan. Breast reconstruction can either be introduced immediately after a mastectomy [immediate reconstruction (Immediate)] or can be delayed for months or years [delayed reconstruction (Delayed)]. The condition of the remaining skin and tissue differed among the 2 methods. Immediate is more surgically invasive and has a higher risk for postoperative complications because of the invasion of the mastectomy and the recently devascularized skin flaps.<sup>6</sup>

In this study, we focused on reconstructed breasts and retrospectively analyzed the capsule revision surgery cases to investigate the length of time needed for capsule revision surgery and the related risk factors by comparing the 2 reconstruction methods. To minimize the study bias, cases from a single plastic surgeon were examined to reduce variations in the surgical technique. Also, follow-up was conducted by the same surgeon so that the quality of the clinical evaluation (grading capsular contracture) would be consistent. In addition, to exercise objectivity, the data were analyzed by an author who was not involved in any of the clinical procedures.

## PATIENTS AND METHODS

### Reconstruction Methods and Clinical Time Flow

In this study, an immediate reconstruction is defined as a procedure involving mastectomy and insertion of a tissue expander at the same time during the first operation. After obtaining sufficient skin expansion, the expander was removed from patients and was replaced with a permanent implant. The delayed reconstruction is defined as a procedure that starts separately from the mastectomy and can occur months or years later. The clinical time courses in this study are shown in Figure 1. For the Immediate, the mastectomy and insertion of the tissue expander were performed by various oncologic surgeons (19 surgeons belonging to 8 institutes). A single plastic surgeon (the senior author) handled the cases after the first operation and was responsible for the skin expansion

**Table 1. Types of Expander and Implant Used**

| Expander Manufacturers (Shell Surface Type) | Immediate (Total = 42 Breasts), n | Delayed (Total = 32 Breasts), n |
|---|-----------------------------------|---------------------------------|
| ALLERGAN (textured)                         | 37                                | 27                              |
| KOKEN (smooth)                              | 2                                 | 1                               |
| MENTOR (textured)                           | 0                                 | 2                               |
| PMT (smooth)                                | 1                                 | 1                               |
| Unknown                                     | 2                                 | 1                               |

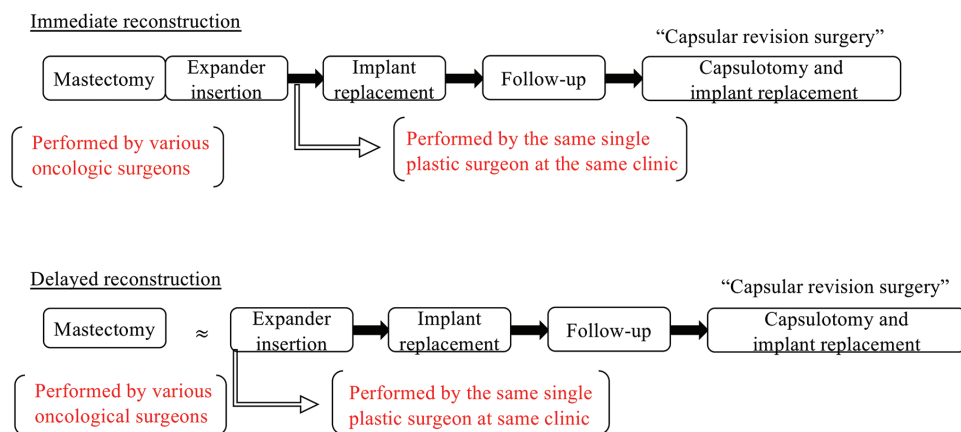
  

| Implant Manufacturers (Shell Surface, Shape) | Immediate (Total = 42 Breasts), n | Delayed (Total = 32 Breasts), n |
|--|-----------------------------------|---------------------------------|
| ALLERGAN (textured round/textured anatomic)  | 41 (5/36)                         | 27 (2/25)                       |
| MENTOR (textured anatomic)                   | 0                                 | 4                               |
| Euro Silicon (smooth round)                  | 1                                 | 0                               |
| Saline bag (smooth round)                    | 0                                 | 1                               |

and implant replacement. In contrast, for the Delayed, all reconstructive procedures were conducted by the same plastic surgeon. Most implants used in this study were anatomically shaped and had a textured surface. The characteristics of additional expanders and implants are listed in Table 1. All of the expanders and the implants were placed beneath the pectoralis major muscle. Because acellular dermal matrix is not yet approved in Japan, it was not used in this study. After the implant replacement, the same surgeon followed up all the cases by evaluating the capsular contracture and by conducting capsule revision surgeries. The degree of capsular contractures is graded by Baker grades as follows: grade III, obvious distortion and firmness of the implanted breast; grade IV, grade III symptoms with continuous pain. The capsule revision surgery included a total periprosthetic capsulectomy and replacement with a new implant.

### Patients and Data Collection

The medical charts of the patients who received a reconstructed breast implant and underwent a capsule revision surgery at the Breast Surgery Clinic in Tokyo, Japan, between July 2013 and March 2018 were retrospectively reviewed. Data were collected on the following parameters: age at



**Fig. 1.** Clinical time flow of this study (2-stage reconstruction).

the time of first implant insertion, age on capsule revision surgery, body mass index (BMI) at the start of reconstruction, Baker grade (III or IV), active smoking habit (history within 5 years), chemotherapy, hormone therapy, and irradiation. The surgical-related reconstruction items were as follows: skin expansion duration; length of time taken until the capsule revision surgery after the first implant insertion; size of the expander and implant; presence of expander- or implant-related postoperative complication; time interval between the mastectomy and the start of the Delayed; and time interval between a Baker grade III/IV capsular contracture diagnosis and the capsule revision surgery.

Regarding postoperative complications, a hematoma was judged to be present if the patient had a history of hematoma removal or a subcutaneous hemorrhage beyond the dissection area. Seroma formation occurred if fluid removal was required at least 2 times. Infection was judged to be present when the results were positive on a wound or drainage fluid culture test. Skin ischemia was judged to be present in the case of necrosis or dehiscence of the wound margin or nipple-areola regions.

#### Statistical Analysis

For all of the statistical analysis, SPSS software (ver.19; IBM Corporation, Tokyo, Japan) was used. A  $\chi^2$  test, Fisher exact, and Kaplan–Meier (log-rank test) analysis were used to compare the 2 reconstruction methods.  $P < 0.05$  was considered as significant.

## RESULTS

#### Patients' Background

Seventy-four breasts from 72 patients were chosen for this study (Table 2). An Immediate was applied to 42 breasts (Baker grade III = 34, IV = 8), and a Delayed was applied to 32 breasts (Baker grade III = 26, IV = 6). The median age at the time of the capsule revision surgery was significantly older in the Delayed (59 years with a range of 43–69 years) than in the Immediate (50 years with a range of 39–75 years,  $P = 0.002$ ). There was no significant difference in the following items: age at the first implant insertion, BMI, smoking, chemotherapy, hormone therapy, and irradiation.

**Table 2. Patient Characteristics**

| Characteristic   | Total         | Immediate    | Delayed      | <i>P</i>                  |
|--|---------------|--------------|--------------|---------------------------|
| No. patients (breasts), n (%)  | 72 (74)       | 40 (42)      | 32 (32)      | —                         |
| Median age at first implant insertion (y) (range)                            | 48 (31–69)    | 47.5 (37–69) | 51.5 (31–61) | 0.894 ( <i>t</i> test)    |
| Median age at revision surgery (y) (range)                                   | 56 (40–75)    | 51.5 (40–75) | 59.5 (43–69) | 0.005* ( <i>t</i> test)   |
| Median BMI at first reconstruction (kg/m <sup>2</sup> ) (total = 61 breasts) | 21.4 (16–30)  | 20.9 (16–30) | 22.2 (16–27) | 0.154 ( <i>t</i> test)    |
| Baker grade at revision surgery (no. breasts)                                | III 60, IV 14 | III 34, IV 8 | III 26, IV 6 | —                         |
| Active smoker (<5 y), n (%)  |               |              |              | 0.338 (Fisher exact test) |
| Yes  | 11 (15.5)     | 5 (11.9)     | 6 (20.7)     |                           |
| No   | 60 (84.5)     | 37 (88.1)    | 23 (79.3)    |                           |
| Chemotherapy, n (%)  |               |              |              | 0.628 (Fisher exact test) |
| Yes  | 30 (41.7)     | 19 (45.2)    | 11 (36.7)    |                           |
| No   | 42 (58.3)     | 23 (54.8)    | 19 (63.3)    |                           |
| Hormone therapy, n (%)   |               |              |              | 0.611 (Fisher exact test) |
| Yes  | 50 (69.4)     | 28 (66.7)    | 22 (73.3)    |                           |
| No   | 22 (30.6)     | 14 (33.3)    | 8 (30.6)     |                           |
| Radiotherapy, n (%)  |               |              |              | 0.107 (Fisher exact test) |
| Yes  | 11 (15.3)     | 9 (21.4)     | 2 (6.7)      |                           |
| No   | 61 (84.7)     | 33 (78.6)    | 28 (93.3)    |                           |

\*Indicates  $P < 0.05$ .

#### Reconstruction-related Characteristics

The median interval of time between the mastectomy and the start of the Delayed was 42 months (range, 5–279) (Table 3). The median time until the capsule revision surgery after the first implant insertion was significantly shorter (63.5 months) for the Immediate than for the Delayed (121 months;  $P < 0.0001$ ). The duration of the skin expansion with the expander was 7.0 months for the Immediate and 8.0 months for the Delayed, with no significant difference. The median size of the expander and implant was significantly smaller in the Immediate (expander, 300 mL; implant, 240 mL) than in the Delayed (expander, 400 mL; implant, 300 mL) (expander,  $P = 0.008$ ; implant,  $P = 0.004$ , ). There was a significant difference in the incidence of postoperative complications after the expander insertion between the Immediate (62.5%) and the Delayed (21.1%) ( $P = 0.001$ ). There was no significant difference in the complication rates after the implant insertion between the Immediate (16.7%) and the Delayed (18.8%). The median time interval between the Baker grade III/IV capsular contracture diagnosis and the capsule revision surgery was 1.0 years for Immediate and 1.5 years for Delayed with no significant difference. The number of postoperative complications after the expander insertion was as follows (in Immediate versus Delayed, respectively): hematoma (11, 3), seroma (7, 3) infection (1, 1), ischemic skin wound (9, 0), and exposure occurrence (1, 2) (Table 4). The complications after implant insertion were hematoma (1, 4), seroma (1, 1), infection (2, 0), ischemic skin wound (0, 1), and exposure occurrence (3, 0) (Table 4).

Overall, the following 4 items were found to be statistically significant for the Delayed when compared with the Immediate: higher age at the time of capsule revision surgery, longer time to capsule revision surgery, lower postoperative complication rate after the expander insertion, and a larger volume of expander and implant used.

## DISCUSSION

Maxwell et al<sup>7</sup> reported the incidence of Baker grade (III/IV) capsule contractures in reconstruction cases as 14.5% and that in augmentation cases as 9.2%, in the 10-year study. Despite the higher incidence of capsular contracture

**Table 3. Reconstruction-related Characteristics**

| Characteristics  | Immediate<br>(No. Breasts = 42) | Delayed<br>(No. Breasts = 32) | P                           |
|--|---------------------------------|-------------------------------|-----------------------------|
| Mean time interval between mastectomy and the launch of delayed reconstruction (mo) (range)        | —                               | 42 (5–279)                    | —                           |
| Median time until capsule revision after first implant insertion (mo) (range)                      | 63.5 (21–191)                   | 121 (26–265)                  | <0.0001* ( <i>t</i> test)   |
| Median skin expansion duration (mo) (range)  | 7.0 (4–16)                      | 8.0 (2–29)                    | 0.264 ( <i>t</i> test)      |
| Median expander size (mL) (range)  | 300 (200–800)                   | 400 (200–850)                 | 0.008* ( <i>t</i> test)     |
| Median implant size (mL)   | 240 (110–445)                   | 300 (135–520)                 | 0.004* ( <i>t</i> test)     |
| Postoperative complication after expander insertion, n (%)   |                                 |                               | 0.001* (Fisher exact test)  |
| Yes  | 30 (62.5)                       | 7 (21.1)                      |                             |
| No   | 15 (31.3)                       | 24 (72.7)                     |                             |
| Postoperative complication after Implant insertion, n (%)  |                                 |                               | 1.000 (Fisher’s exact test) |
| Yes  | 7 (16.7)                        | 6 (18.8)                      |                             |
| No   | 35 (83.3)                       | 26 (81.3)                     |                             |
| Median time interval between Baker grade III/IV diagnosis and capsule revision surgery (y) (range) | 1.0 (0–5) (n = 38)              | 1.5 (0–6) (n = 24)            | 0.175 ( <i>t</i> test)      |

\*Indicates  $P < 0.05$ .

**Table 4. Incidence of Complications following Expander or Implant Reconstruction**

|  | Immediate,<br>n (%) | Delayed,<br>n (%) | Total,<br>n (%) |
|--|---------------------|-------------------|-----------------|
| Complications after expander insertion |                     |                   |                 |
| Hematoma                               | 11 (26.2)           | 3 (9.4)           | 14 (19.0)       |
| Seroma                                 | 7 (16.7)            | 3 (9.4)           | 10 (13.5)       |
| Infection                              | 1 (2.4)             | 1 (3.1)           | 2 (2.7)         |
| Ischemic skin                          | 9 (21.4)            | 0 (0)             | 9 (12.2)        |
| Exposure                               | 2 (4.8)             | 1 (3.1)           | 3 (4.1)         |
| Complications after implant insertion  |                     |                   |                 |
| Hematoma                               | 1 (2.4)             | 4 (12.5)          | 5 (6.8)         |
| Seroma                                 | 1 (2.4)             | 1 (3.1)           | 2 (2.7)         |
| Infection                              | 2 (4.8)             | 0 (0)             | 2 (2.7)         |
| Ischemic skin                          | 0 (0)               | 1 (3.1)           | 1 (1.4)         |
| Exposure                               | 3 (7.1)             | 0 (0)             | 3 (4.1)         |

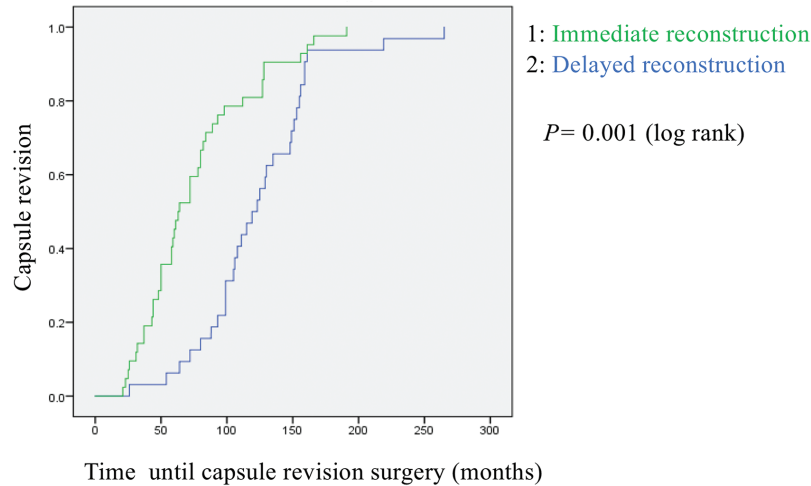
after breast reconstruction than after breast augmentation, there are few reconstruction-specific analyses.<sup>3,7,8</sup> This is because breast augmentation is overwhelmingly more common than reconstruction surgery in the world. For example, in the United States, there were over 310,000 augmentation cases and 69,000 tissue expander–implant reconstruction cases in 2018.<sup>9</sup> In Japan, in contrast, there were approximately 2000 implant-use augmentation cases and 6500 tissue expander–implant reconstruction cases in 2018.<sup>10,11</sup> Because subcutaneous tissue is originally thinner in Asian women, which causes capsular contracture to be conspicuous, there is a strong medical demand for reconstructed breast-specific analysis. Therefore, the objective of our study was to determine the risk factors for capsular contracture in reconstructed breasts by comparing the 2 reconstruction methods using a retrospective analysis of the revision cases.

Patients’ characteristics (Table 2) such as age (at first implant insertion and at capsule revision surgery), BMI, smoking habit, and adjuvant therapies were compared. A retrospective review by Marques et al<sup>8</sup> found that patients who are 54 years old and beyond are at risk for capsular contracture. In our results, age at the time of the first implant insertion had no association between the 2 reconstruction methods, whereas age at the time of the revision surgery

was significantly older in the Delayed (median, 59.5 years) than in the Immediate (median, 51.5 years). This may reflect the longer time to revision surgery in the Delayed because there was no difference in the initial reconstruction age in the 2 groups. In earlier studies, the effect of BMI and smoking habits on capsular contracture was controversial,<sup>3,4</sup> and there was no clear association in our study. Among adjuvant therapies, irradiation is a reported risk factor for capsular contracture,<sup>12</sup> and there was no clear difference in the 11 irradiated breasts in this study.

Regarding the reconstruction-related characteristics (Table 3), the Immediate had a significantly shorter time until revision surgery than the Delayed (Fig. 2). In addition, the size of the expander and implant was significantly smaller and a positive association was identified for higher postoperative complication rates in the Immediate than in the Delayed. There are several possible explanations for these results. There was no significant difference between the 2 groups for skin expansion time and the time interval between capsular contracture diagnosis and capsule revision surgery, and all of the reconstruction procedures were conducted by the same plastic surgeon except for the first operation in the Immediate. Therefore, it is likely that the capsule contracture formation is simply associated with the expander operation. In previous reports, hematoma or seroma formation (or both) after the surgery was found to contribute to capsular contracture development, and our results supported this theory.<sup>3,4,12,13</sup>

A unique insight from this study is the assessment of ischemic skin symptoms of the postoperative mastectomy wound or nipple–areola skin (Table 4). In Japanese mastectomies, even though the patients have thin subcutaneous fat tissue to begin with, the mammary gland and the surrounding subcutaneous fat tissue is completely excised, including the subclavicular region for the upper margin, medial sternal rim for the inner margin, and the inferior mammary fold for the lower margin, so that the remaining breast skin flap is often extremely thin. Because of the invasive operative procedures, the blood flow to the skin becomes more unstable and the risk for bleeding increases. The skin of the breast, especially at the mastectomy wound or at the nipple–areola area, is



**Fig 2.** Capsule revision rate of postoperative time by immediate reconstruction or by delayed reconstruction.

likely to become ischemic and necrotic. McCarthy et al<sup>14</sup> reported that for their 1170 cases of expander/implant reconstruction, the incidence of total complications was 17.6%, that of mastectomy flap necrosis was 8.7%, that of hematoma formation was 3.2%, and that of infection was 3.4%. In our results, the total complication rates after expander insertion were 12.2% for ischemic skin symptoms, 19.0% for hematoma formation, and 2.7% for infection; the total complications after implant insertion were 1.4% for ischemic skin symptoms, 6.8% for hematoma formation, and 2.7% for infection (see Table 4 for details). These findings suggest that the failure of blood flow to the skin postoperatively after the expander insertion may be an important risk factor for capsular contracture as well as hematoma and seroma formation.

Furthermore, the difference in postoperative complication rates may reflect the variation in surgical procedures and skills of the surgeons.<sup>3,5,15</sup> A 10-year study by Calobrace et al<sup>5</sup> analyzed how practice patterns of individual surgeons can have a large impact on capsular contracture risk. In this study, the mastectomy and expander insertion was performed by 19 various oncologic surgeons at 8 different institutes, and all of the surgeons placed the expanders in the subpectoral plane. As described above, the risk of hematoma, seroma, and ischemic skin is increased due to the resection of the mammary gland, and it is difficult to secure the blood flow to the skin flap. However, this is where the surgeon's experience and skills are likely to differ. An inexperienced surgeon may make a poor choice for expander size and insertion location, which could result in additional dissection and bleeding and lead to capsular contracture in a shorter time.

Next, because most of the implants used in the Immediate were textured and anatomic (Table 2), and there was no significant difference in the patients' BMI by reconstruction method, it appears that the smaller expander was chosen in the Immediate so that the skin was not burdened after the mastectomy. This result differs from the previous studies

by Dancy et al<sup>4</sup> and Henriksen et al,<sup>15</sup> who reported that larger implants (>350mL) had a greater risk for capsular contracture. However, our results corroborated the findings of Calobrace et al,<sup>5</sup> who described that very tight skin envelopes can prevent implant mobility, leading to capsular contracture.<sup>5</sup> We believe that if the chosen expander is too small for the prepared space, a dead space is created, which allows the expander to move more easily with body movement and allows hematoma and seroma to be easily formed.

There are some limitations to this study. Patients who decided against a capsule revision surgery despite suffering severe capsule contracture were excluded from the study. Despite having medical conditions that indicated a capsule revision surgery, these patients could not undergo the surgery during the study period due to a lack of overall health, mental condition, economic or family situation, and so on. Therefore, the number of indicated revision cases appears to be underreported.

## CONCLUSIONS

The goal of this study was to assess the risk factors of capsular contracture by comparing 2 reconstruction methods. The results of the retrospective review of capsular revision surgery cases identified that immediate reconstruction leads to capsule contracture in significantly less time than delayed reconstruction. In particular, this analysis corroborates previously reported risk factors for capsular contracture, which include a smaller device and complications after the mastectomy with expander insertion operation. The alleviation of postoperative complications and selection of an appropriate-sized expander and implant could extend the time until capsular contracture revision surgery in the immediate reconstruction.

*Maiko de Kerckhove, MD, PhD*  
Breast Surgery Clinic  
2-21-43 Takanaawa  
Minato-ku  
Tokyo 108-0074, Japan  
E-mail: maikokodek@gmail.com

## ACKNOWLEDGMENTS

The authors thank Daiki Kobayashi, MD, MPH, PhD, from the Graduate School of Public Health, St Luke's International University, for assistance with the statistical analysis, and Charles de Kerckhove and Enago ([www.enago.jp](http://www.enago.jp)) for their English language review.

## REFERENCES

1. Araco A, Caruso R, Araco F, et al. Capsular contractures: a systematic review. *Plast Reconstr Surg.* 2009;124:1808–1819.
2. Prantl L, Schreml S, Fichtner-Feigl S, et al. Clinical and morphological conditions in capsular contracture formed around silicone breast implants. *Plast Reconstr Surg.* 2007;120:275–284.
3. Bachour Y, Bargon CA, de Blok CJM, et al. Risk factors for developing capsular contracture in women after breast implant surgery: a systematic review of the literature. *J Plast Reconstr Aesthet Surg.* 2018;71:e29–e48.
4. Dancey A, Nassimizadeh A, Levick P. Capsular contracture—what are the risk factors? A 14 year series of 1400 consecutive augmentations. *J Plast Reconstr Aesthetic Surg.* 2012;65:213–218.
5. Calobrace MB, Stevens WG, Capizzi PJ, et al. Risk factor analysis for capsular contracture: a 10-year Sientra study using round, smooth, and textured implants for breast augmentation. *Plast Reconstr Surg.* 2018;141 (4S Sientra Shaped and Round Cohesive Gel Implants):20S–28S.
6. Sullivan SR, Fletcher DR, Isom CD, et al. True incidence of all complications following immediate and delayed breast reconstruction. *Plast Reconstr Surg.* 2008;122:19–28.
7. Maxwell GP, Van Natta BW, Bengtson BP, et al. Ten-year results from the Natrelle 410 anatomical form-stable silicone breast implant core study. *Aesthet Surg J.* 2015;35:145–155.
8. Marques M, Brown SA, Oliveira I, et al. Long-term follow-up of breast capsule contracture rates in cosmetic and reconstructive cases. *Plast Reconstr Surg.* 2010;126:769–778.
9. American Society of Plastic Surgeons. National Clearinghouse of Plastic Surgery Procedural Statistics. 2018 Plastic Surgery Statistics Report. Available at <https://www.plasticsurgery.org/documents/News/Statistics/2018/plastic-surgery-statistics-full-report-2018.pdf>. Accessed December 22, 2019.
10. Japan Society of Aesthetic Plastic Surgery. “Dainikai Zenkoku Biyouiryuu Jittachousa-saishuu Houkokusho” [Final Report for Second National Cosmetic Medical Care Survey, in Japanese]. Available at [http://www.jsaps.com/pdf/explore/explore2019\\_2.pdf](http://www.jsaps.com/pdf/explore/explore2019_2.pdf). Accessed December 22, 2019.
11. Japan Oncoplastic Breast Surgery Society. “Nyubousaikenyou Expander/Implant Nenjihoukoku to Gappeishounitsuite 2018” [Annual Report for Expander/Implant for Breast Reconstruction and Complication 2018, in Japanese]. Available at <http://jopbs.umin.jp/medical/guideline/docs/gappeisho2018.pdf>. Accessed December 22, 2019.
12. Quinn TT, Miller GS, Rostek M, et al. Prosthetic breast reconstruction: indications and update. *Gland Surg.* 2016;5:174–186.
13. Codner MA, Mejia JD, Locke MB, et al. A 15-year experience with primary breast augmentation. *Plast Reconstr Surg.* 2011;127:1300–1310.
14. McCarthy CM, Mehrara BJ, Riedel E, et al. Predicting complications following expander/implant breast reconstruction: an outcomes analysis based on preoperative clinical risk. *Plast Reconstr Surg.* 2008;121:1886–1892.
15. Henriksen TF, Fryzek JP, Hölmich LR, et al. Surgical intervention and capsular contracture after breast augmentation: a prospective study of risk factors. *Ann Plast Surg.* 2005;54:343–351.