



# How to measure a Hill–Sachs lesion: a systematic review

Marta Maio<sup>1</sup>  
Marco Sarmento<sup>2</sup>  
Nuno Moura<sup>2</sup>  
António Cartucho<sup>2</sup>

- Quantifying bone loss is important to decide the best treatment for patients with recurrent anterior glenohumeral instability. Currently, there is no standard method available to make a precise evaluation of the Hill–Sachs lesion and predict its engagement before the surgical procedure. This literature review was performed in order to identify existing published imaging methods quantifying humeral head bone loss in Hill–Sachs lesions.
- Searches were undertaken in Scopus and PubMed databases from January 2008 until February 2018. The search terms were “Hill–Sachs” and “measurement” for the initial search and “Hill–Sachs bone loss” for the second, to be present in the keywords, abstracts and title. All articles that presented a method for quantifying measurement of Hill–Sachs lesions were analysed.
- Several methods are currently available to evaluate Hill–Sachs lesions. The length, width and depth measurements on CT scans show strong inter and intra-observer correlation coefficients. Three-dimensional CT is helpful for evaluation of bony injuries; however, there were no significant differences between 3D CT and 3D MRI measurements. The on-track off-track method using MRI allows a simultaneous evaluation of the Hill–Sachs and glenoid bone loss and also predicts the engaging lesions with good accuracy.

**Keywords:** bone loss; Hill–Sachs measurement

Cite this article: *EFORT Open Rev* 2019;4:151-157.  
DOI: 10.1302/2058-5241.4.180031

## Introduction

The first anatomic description of the traumatic notch on the humeral head was made in 1855 by Malgaigne.<sup>1</sup> In 1940 two radiologists, Harold Arthur Hill and Maurice David Sachs, published a paper, in which they made the

radiographic description of lesion, naming it Hill–Sachs lesion (HSL).<sup>1</sup> Later on the glenoid rim lesions were reported.<sup>1</sup>

Quantifying bone loss is of utmost importance to decide the best treatment for recurrent anterior glenohumeral instability patients. This is the determinant factor influencing the choice of the surgical technique: soft tissue procedure or bone block procedure.<sup>2</sup> It has been extensively reported in the literature that the limit of glenoid bone loss above which an arthroscopic Bankart repair may fail is  $\geq 25\%$  of the glenoid width. This percentage is equivalent to  $\geq 20\%$  of the surface area created by a best-fit circle on the inferior surface of the glenoid.<sup>3</sup>

There is not currently a consensus on the accuracy of the available methods to make a precise evaluation of the HSL radiographically, nor to predict its engagement before surgery. Its contribution to instability depends on the size, direction, and location of the bone defect.<sup>4</sup> This difficulty may be explained by the three-dimensional aspect of the humeral sphere, its retroversion and its rotational position during imaging.<sup>1</sup> The aim of this article is to perform a review of the literature to identify current published imaging methods that quantify humeral head bone loss in HSL and to evaluate whether there is a gold standard method supported by evidence.

## Methods

A systematic review of literature was performed from a standardized study selection and evaluation. Due to heterogeneity of the methods in the articles reviewed, no meta-analysis was performed in this study. Study selection criteria were: publication after 2008, quantification by imaging methods (radiography, CT, and/or MRI) of Hill–Sachs lesion, studies in humans and English or Portuguese language. A first search was made in the Scopus database, including studies from January 2008 to February 2018 and excluding review studies. The search terms were

“Hill–Sachs” and “measurement”, to be present in the keywords, abstracts and title. This resulted in a total of 42 articles. The article selection was performed over two rounds. In the first round, selection was based on the review of titles and abstracts, excluding 26 articles: 12 because they only evaluated post-operative results, four which assessed shoulder mobility, two which were clinical reports, two which only measured glenoid defect and six articles which did not quantify the HSL. Final study selection was based on full-text evaluation. Three articles did not permit access to the full text, three reports fell within the paediatric age range and three studies did not include a quantifying method of HSL measurement, thus all were excluded.

The second search, carried out in PubMed, also included articles from 2008 to 2018. The search terms were “Hill–Sachs bone loss”, used in combination, and present in the keywords, abstracts and title, resulting in a total of 74 articles. From the first selection, upon review of the abstracts, a total of 55 articles were excluded: 14 review studies, three clinical reports, one study of paediatric patients, 21 articles which reported post-operative results, seven which evaluated only shoulder mobilities, two the recurrences, one glenoid defect and six articles describing surgical techniques. In the last selection, after analysing the complete article, six studies had already been included, for two full text was not available, in one technique was not explained, one showed a treatment algorithm, one was a biomechanical study, one only compared the identification of HSL in different methods and one only analysed glenoid bone loss, thus these were also excluded.

## Results

The initial Scopus search retrieved 42 total articles. After the initial review of titles and abstracts, 16 articles were retained. Following review of the full text, seven articles were included in the systematic review. In the second research, via PubMed, we obtained a total of 74 articles. After the first round of selection, only 19 reports remained. In the final review six were included in our work, one as a new method and the others as complementary information of the same method. The findings are summarized in Table 1.

### *Hill–Sachs measurements*

Charousset et al<sup>1</sup> evaluate two aspects of the ISIS (Instability Severity Index Score), the presence of HSL and loss of glenoid contour on AP radiograph. The quantitative measurement of the HSL depth was made using radiographs using the calculation of the P/R ratio between the maximum depth of the notch defect (P) in internal rotation and the radius (R) of the humeral head (Fig. 1). The depth

index (P/R) mean value was 0.27 (range, 0–0.8; SD = 0.21); however, no significant relation between the yes or no response to the ISIS visibility criteria and this value was demonstrated. No correlation could be established between the visibility of the HSL in external rotation and the P/R index. The inter-observer reliability was intermediate for the glenoid but low or very low for the HSL. The intra-observer reliability was good or excellent for the three observers evaluating the glenoid criteria and remained good or excellent for the two senior observers of the notch criteria, but became low for the junior observer.<sup>1</sup>

Assunção et al<sup>2</sup> assessed CT or arthro-CT scans from patients with recurrent anterior glenohumeral dislocation, independently evaluated by two examiners. These authors brought attention to the description of a new method, being the residual articular arc and percentage of articular arc bone loss. The parameters measured were: humeral residual articular arc and percentage of articular arc loss, HSL width and depth on the axial and coronal planes, and percentage of glenoid bone loss on the sagittal plane. Most of the HSL measurements displayed moderate correlation, and only the percentage of articular arc loss and HSL width on the axial plane demonstrated a strong correlation with each other ( $r = 0.83$ ). The inter-observer correlation coefficient varied from 0.410–0.731, and was good for all the measurements except HSL width and depth on the coronal plane, for which it was moderate. Assunção et al conclude that the best bone loss predictors are HSL width on axial plane and percentage of articular arc loss.<sup>2</sup>

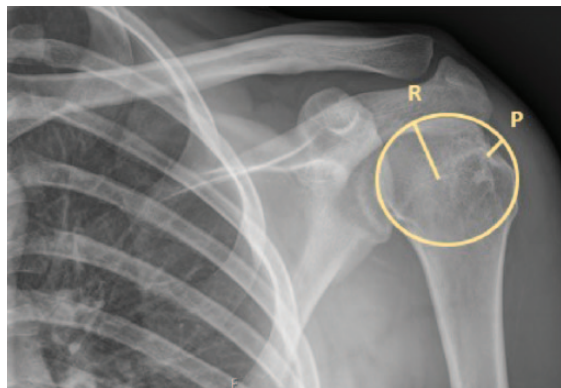
Ho et al<sup>5</sup> used nine anatomical proximal humerus bone models in which they created an HSL to investigate the accuracy and reliability of assessing HSL dimensions using 3D CT reconstructions. The length (cm), width and Hill–Sachs interval (cm) was evaluated in the 3D CT and the depth (mm) in the 2D CT. The inter-class correlation coefficient (ICC) reliability demonstrated strong agreement between all raters for all variables measured in both 2D and 3D CT reconstructions (ICC 0.856–0.975). The intra-rater reliability, for the measurements made at the two time points, was good to excellent for all raters among all variables (ICC range 0.612–0.996). In this investigation Ho et al also found that the percentage of error was significantly greater for shallow lesions when compared with deep lesions ( $P = 0.002$ ), and the small lesions had significantly greater error than larger ones ( $P = 0.040$ ). Therefore, they concluded that 3D CT imaging is a very reliable and a moderately accurate exam to evaluate HSL dimensions, having advantages over 2D imaging allowing better measurements. However, dimensional measurements in smaller lesions can be slightly underestimated, plus the orientation of the lesion was not altered between the models which is the main limitation of the study.<sup>5</sup>

**Table 1.** Hill–Sachs measurements summary

Article	Imaging method	Details of study	Quantification method	Results
Ho et al Laboratory study (2018)	3D CT	Nine anatomically shaped bone models of Hill–Sachs lesions were created. 3D CT images of each bone model. Six observers of varying clinical experience reviewed each bone model. All measurements were performed again two weeks later by all observers.	Interclass correlation coefficient (ICC) for inter-rater reliability and for intra-rater reliability. 3D CT: length (cm); width (cm) and Hill–Sachs interval (cm). 2D CT: depth (mm).	ICC: Length (cm) 0.880; 0.646–0.970 Width (cm) 0.975; 0.938–0.993 Hill–Sachs interval (cm) 0.856; 0.633–0.962 Depth (mm) 0.823; 0.609–0.950 Strong agreement between all raters for all variables measured.
Stillwater et al Prospective study (2017)	3D CT versus 3D MRI	Twelve shoulders with glenohumeral instability or recurrent dislocations were imaged using both CT and MRI. Measurements were obtained on each MRI and CT 3D osseous reconstruction: humeral head height, humeral head width, Hill–Sachs lesion size, percentage humeral head loss.	Maximal humeral head height (A) Residual humeral head width (B) Percentage humeral head bone loss = $[(A-B)/A]*100$	Measurement differences from the 3D CT and 3D MR post processed images were not statistically significant for humeral head width, Hill–Sachs size, or percentage humeral head loss. The measurement differences for humeral head height were borderline statistically significant. Percentage humeral head loss $12.7 \pm 4.1\%$ (CT); $12.6 \pm 4.1\%$ (MRI)
Assunção et al Retrospective study (2017)	CT or arthro- CT scans	Fifty shoulders. All parameters were independently measured by two observers, who were blinded to the clinical history and physical examination.	Humeral residual articular arc and percentage of articular arc loss; Hill–Sachs lesion (HSL) width and depth.	Inter-examiner correlation coefficients (ICC): Residual articular arc 0.610, 0.449–0.731 Articular arc bone loss 0.676, 0.492–0.803 Axial width HSL 0.682, 0.500–0.806 Axial depth HSL 0.731, 0.570–0.838 Coronal width HSL 0.410, 0.151–0.616 Coronal depth HSL 0.442, 0.189–0.640 The percentage of articular arc loss and HSL lesion width on the axial plane were the only measurements that exhibited strong correlation ( $r = 0.83$ ; $P < 0.001$ ).
Burns et al Laboratory study (2016)	CT scans	Twelve cadaveric shoulders First, made a baseline CT scan in neutral position and a diagnostic arthroscopy. Created bipolar lesion and then obtained CT scans in neutral position and with 60° of glenohumeral abduction and 90° of external rotation.	Engaging on the CT in neutral position was assessed by the on-track off-track method. On the CT in abduction and external rotation the lesion was considered engaging if a portion of the HSL lay anterior to the intact or osteotomized anterior glenoid. Created a new parameter, intact articular angle defect (IAAA), defined as the angle between the anterior margin of the humeral head articular surface and the medial margin of the HSL in the axial plan.	The abduction and external rotation CT classified correctly engagement lesion in accordance with the on-track off-track model in 96%. The sensibility for detecting engagement was 92% and specificity 100% and the inter-observer agreement was 100%. The inter-observer agreement with IAAA was good (ICC(1,1) = 0.73; $P = 0.002$ ) with a good correlation with the Hill–Sachs interval (Pearson correlation coefficient, $r = 20.75$ ; $P = 0.005$ )
Gyftopoulos et al Retrospective study (2015)	MRI scans	Seventy-six MRI studies independently evaluated by two fellowship-trained musculoskeletal radiologists and compared with arthroscopic findings of engagement.	Used the on-track off-track method. Glenoid track is $0.83 D - d$ . D is the diameter of the intact glenoid (mm) and d the amount of glenoid bone loss (mm). The Hill–Sachs interval represents the width of the HSL (mm) plus the width of the intact bone bridge (mm) between the rotator cuff attachment and the lateral margin of the HSL. Lesions were considered engaging, or off-track, if the Hill–Sachs interval exceeded the glenoid track and non-engaging, or on-track, if the Hill–Sachs interval was less than the glenoid track. And then compared with the corresponding arthroscopic findings of engagement.	The on-track off-track method had a sensitivity of 72.2% and a specificity of 87.9%. And a positive predictive value of 65.0% and negative predictive value of 91.1%. The intra-reader correlation coefficient was 0.86 for measurement of the HSL and inter-reader correlation coefficient agreement was 0.79 for the HSL.
Ozaki et al Retrospective study (2014)	3D CT scans	One hundred and thirty-five patients (142 shoulders) who underwent arthroscopic Bankart repair for traumatic anterior shoulder instability.	Measured the length and width on 3D CT scans reconstructed with elimination of the scapula, while the depth was measured on axial images obtained perpendicular to the longitudinal axis of the humeral shaft. Hill–Sachs lesions confirmed at arthroscopy were re-examined by the observer who performed the first evaluation.	No false-positive results of CT, but there were 28 false-negative results. Correlation coefficients for the relations between measurements obtained at initial examination and re-examination ranged from 0.92 to 0.94 (length: 0.94, width: 0.92, depth: 0.93; $P < 0.001$ ).

**Table 1. (Continued)**

Article	Imaging method	Details of study	Quantification method	Results
Cho et al Cohort study (2011)	3D CT scans and CT scans	One hundred and four patients (107 shoulders) who underwent arthroscopic Bankart repair for traumatic anterior shoulder instability. Diagnostic arthroscopic determination of engagement was performed as definitive diagnostic data point of the study.	On the axial CT image, a virtual circle that included the articular surface of the humeral head was drawn. The width was defined as the distance between both ends of the Hill–Sachs lesion where the bone defect was located on the circle. The depth was defined as the longest length between the bottom of the lesion and the corresponding arc. Each measurement was divided by the diameter of the humeral head and recorded as a percentage (100%). As indices for orientation of the Hill–Sachs lesion, the angle between the lines was measured and defined as the Hill–Sachs angle on 3D CT. The angle between the line connecting the centre of the humeral head to the centre of the bicipital groove and the line connecting the centre of the humeral head to the centre of the Hill–Sachs lesion was measured and defined as the bicipital angle.	Intra-observer correlation coefficient of repeated measurements ranged from 0.845 to 0.998 for single measurement and from 0.916 to 0.999 for average measurement. The inter-observer correlation coefficient ranged from 0.629 to 0.992 for single measurement and from 0.772 to 0.996 for average measurement. The mean HSL angle was $25.6^\circ \pm 7.4$ in engaging HSL and $13.8^\circ \pm 6.2$ in non-engaging lesions. The HSL angle was significantly larger in engaging lesions than in non-engaging lesions ( $P < 0.001$ ). The mean bicipital angle was $114.6^\circ \pm 10.1$ in engaging Hill–Sachs lesions and $118.8^\circ \pm 10.5$ in non-engaging lesions.
Charoussat et al Multicentre Clinical study (2010)	X-rays	Thirty-six files were used to analyse the HSL defect.	Three AP images in rotation: internal (hand on the stomach), neutral (condensation of the internal side of the lesser tubercle visible on the external third of the metaphysis), and maximal external (relief of the lesser tubercle extending outside the external cortex of the metaphysis). Evaluation of the depth of the lesion was based on the P/R index calculation where P measures the depth of the notch and R the radius of the humeral head on the internal rotation x-rays.	Inter-observer: First reading: 0.30 Second reading: 0 ( $P = 0.8$ ) Intra-observer: Reader D: 0.92 Reader E: 0.49 Reader F: 0.06 ( $p = 0.7$ ). The inter-observer reliability was low or very low for the HSL.

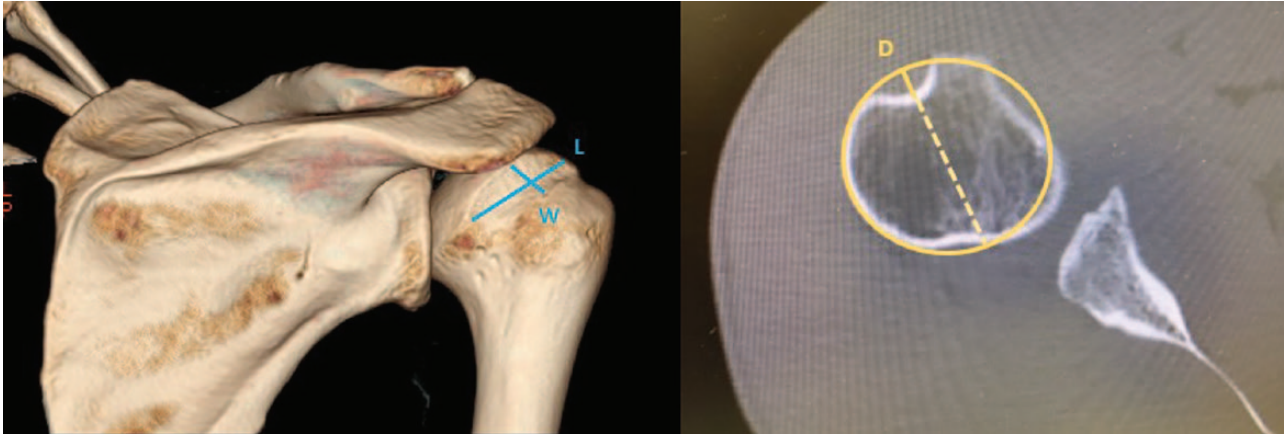


**Fig. 1** Calculation of the P/R ratio.

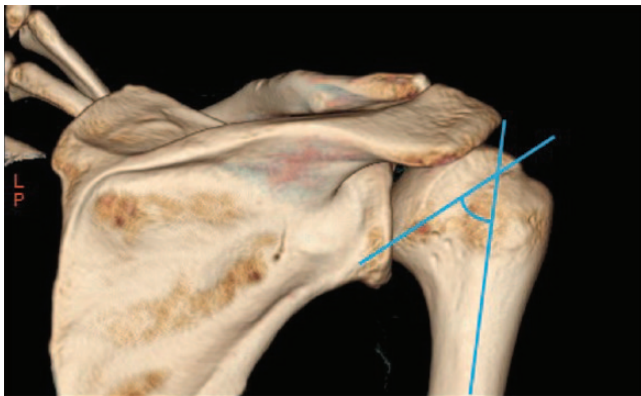
The principal objective of Ozaki et al<sup>6</sup> was to analyse the accuracy of 3D-reconstructed CT images in evaluating the prevalence and size of HSL in comparison with arthroscopic measurements. They assessed the size of the lesions by performing length and width measurements on 3D CT scan reconstructions, with elimination of the scapula, while the depth was measured on axial images obtained perpendicular to the longitudinal axis of the humeral shaft (Fig. 2). At the first evaluation the observers were blinded

to the arthroscopic findings and, in the re-examination, they had the information and arthroscopy video. Hill–Sachs lesions were detected in 90 shoulders (63.4%) by the initial CT examination whereas in arthroscopy HSL were found in 118 shoulders (83.1%). There were no false-positives and 28 false-negatives on the CTs, the sensibility of the CTs was 76.3% and the specificity 100%. The correlation coefficients between measurements obtained at initial examination and re-examination were strong (length: 0.94, width: 0.92, depth: 0.93;  $P < 0.001$  for all). The authors concluded that three-dimensional reconstructed CT was a valuable imaging modality for evaluation of osseous HSL.<sup>6</sup>

Stillwater et al<sup>7</sup> elaborated a prospective study with the aim of assessing whether 3D MRI and 3D CT are equivalent methods in quantifying bone loss in patients with glenohumeral instability or recurrent shoulder dislocations. Both 3D CT and MRI were performed on all patients, the measurements on both exams were: glenoid height, glenoid width, humeral head height, humeral head width, HSL size, percentage humeral head loss, size of glenoid bone loss and percentage glenoid bone loss. The CT and MRI measurements were performed separately and were blinded. The maximal humeral head height (A) was



**Fig. 2** Measurement of the Hill–Sachs lesion width and depth on an axial section plane.



**Fig. 3** Hill–Sachs angle.

determined by drawing a line in the centre of the head parallel to the orientation of the Hill–Sachs lesion, followed by a line perpendicular to the humeral head height to determine the residual humeral head width (B). Thus the width of the humeral head defect could be determined (A–B), as well as the percentage of humeral head bone loss  $[(A-B/A)*100]$ . The results were  $12.7 \pm 4.1\%$  (CT);  $12.6 \pm 4.1\%$  (MRI). The authors concluded that 3D MRI and 3D CT measurements are equivalent.<sup>7</sup>

Cho et al<sup>4</sup> published a cohort study where they preoperatively obtained a 3D CT for all patients and evaluated the size (width and depth measured on axial and coronal images), orientation (Hill–Sachs angle), and location (bicipital and vertical angles) of the HSL. The final diagnosis of engagement was obtained by arthroscopy. The Hill–Sachs angle was defined as the angle between the line passing through the deepest groove of the HSL and the longitudinal axis of the humeral shaft on the true posteroanterior on 3D CT. The bicipital angle was used for the location of the HSL and was defined as the angle between the line connecting the centre of the humeral

head to the centre of the bicipital groove and the line connecting the centre of the humeral head to the centre of the HSL on the axial CT image (Fig. 3). The results demonstrated good to excellent intra-observer reproducibility and inter-observer reliability. They also found that the size of engaging HSL was significantly larger than the size of non-engaging lesions. The Hill–Sachs angle was also significantly larger in engaging than in non-engaging lesions. The bicipital angle and vertical angle did not show statistically significant differences. The conclusion of this study was that the engaging HSL were bigger and more horizontally oriented to the humeral shaft than non-engaging lesions on CT with 3D reconstruction images.<sup>4</sup> Gyftopoulos et al also studied the correlation between the bicipital angle and the engaging HSL and no statistically significant difference was found; nevertheless the angle was larger in the engaging group.<sup>8</sup>

Di Giacomo<sup>9</sup> in 2014 introduced the on-track off-track method using CT with 3D reconstructions where lesions were considered engaging, or off-track, if the Hill–Sachs interval exceeded the glenoid track. The glenoid track consists of the contact area between the humeral head and glenoid during shoulder abduction and external rotation and it represents approximately 83% of the glenoid width. The Hill–Sachs interval represents the width of the HSL in millimetres plus the width of the intact bone bridge in millimetres between the rotator cuff attachment and the lateral margin of the HSL. Di Giacomo's method consists of four evaluation steps: the first measures the diameter (D) of the inferior glenoid using the perfect circle method, the second measures the amount of glenoid anterior bone loss (d), then the third calculates the width of the glenoid track (GT) =  $0.83D-d$ , and the last measures the width of the Hill–Sachs interval (HSI), which is the width of the HSL plus the width of the bone bridge (BB). If  $HSI > GT$ , the lesion is off-track; if  $HSI < GT$ , it is on-track.<sup>9,10</sup>

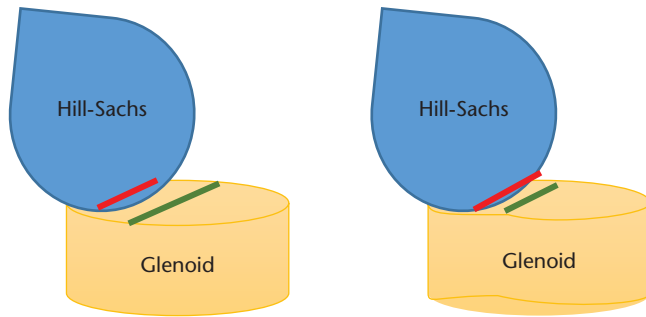


Fig. 4 On-track and off-track lesion.

Gyftopoulos et al<sup>11</sup> studied the on-track off-track method using MRI and evaluated whether this method could predict engagement (Fig. 4). The glenoid track and the Hill–Sachs interval was measured using MRI and compared to the results of engagement in arthroscopy. The authors found a moderate to high accuracy of this method using MRI with an overall accuracy of 84.2%, a sensibility of 72.2% and a specificity of 87.9%. Their results also suggest that the Hill–Sachs interval is the most important component of this method. They concluded that the on-track off-track method can be used in MRI to evaluate the bipolar bone loss in shoulder instability and predict the presence of engaging lesion, or off-track lesions and can be used pre-operatively to plan and choose the most suitable treatment method.<sup>11</sup>

Schneider et al<sup>12</sup> compared the inter-observer and intra-observer reliability of the on-track off-track method and the treatment algorithm described by Di Giacomo and found poor levels of inter-observer agreement for both variables. Less intra-observer variability was found but overall was similarly poor. These results were explained by the difficulty of defining the medial margin of HSL and the humeral cuff insertion.<sup>12</sup> Shaha et al<sup>13</sup> performed a study to clinically validate this method. A retrospective review of military patients treated with isolated arthroscopic Bankart repair was performed. The defects were classified according to the on-track off-track method. The results demonstrated that applying the concept to daily practice may help to guide the treatment of these patients.<sup>13</sup>

Burns et al,<sup>14</sup> developed an investigation of cadaveric shoulders. They created a bipolar lesion and obtained CT scans in neutral position and with 60° of glenohumeral abduction and 90° of external rotation. The engagement on the CT in neutral position was assessed by the Di Giacomo on-track off-track method. On the CT, in abduction and external rotation, the lesion was classified as engaging if a portion of the HSL lay anterior to the intact or osteotomized anterior glenoid. They also created a new parameter, the intact articular angle defect (IAAA), defined

as the angle between the anterior margin of the humeral head articular surface and the medial margin of the HSL in the axial plan. These two new methods were then compared with the glenoid track method. A good correlation between these techniques was found. The authors concluded that the CT scan in 60° of abduction and 90° of external rotation and the IAAA are simple and effective in predicting engaging HSL.<sup>14</sup>

## Conclusion

Our systematic review has summarized the current evidence of imaging techniques to quantify HSL bone loss. To our knowledge, radiography has a low inter-observer reliability and has not been shown to have the accuracy required for pre-operative planning. However, it may play a role in screening patients. Measuring the depth and width of axial slices of a CT scan has good reliability, although 3D CT has been reported to be more accurate than 2D imaging.

Several methods are currently available to evaluate and quantify HSL. The length, width and depth measurement on CT reconstructions are shown in all studies to have strong inter and intra-observer correlation coefficients. Lesions that are bigger and more horizontally oriented to the humeral shaft have more probability of being engaging HSL.

3D CT is the gold standard for evaluation of HSL. However, one of the studies showed no significant differences between 3D CT and 3D MRI measurements, therefore the radiation dose associated with CT exam could potentially be avoided. Surgeons may take into account the high prevalence of young patients and MRI could provide sufficient information about the bone loss. The on-track off-track method has shown a good level of accuracy in predicting engagement, being nowadays the best technique to plan shoulder instability surgery.

### AUTHOR INFORMATION

<sup>1</sup>Department of Orthopaedics and Traumatology, Centro Hospitalar de Trás os Montes e Alto Douro, Vila Real, Portugal.

<sup>2</sup>Shoulder and Elbow Unit, Orthopaedics Department, Hospital CUF Descobertas, Lisboa, Portugal.

Correspondence should be sent to: Marta Maio, Department of Orthopaedics and Traumatology, Centro Hospitalar de Trás os Montes e Alto Douro, Av. Noruega, Lordelo, 5000–508 Vila Real, Portugal.  
Email: martadml.maio@gmail.com

### ICMJE CONFLICT OF INTEREST STATEMENT

None declared.

**FUNDING STATEMENT**

No benefits in any form have been received or will be received from a commercial party related directly or indirectly to the subject of this article.

**LICENCE**

© 2019 The author(s)

This article is distributed under the terms of the Creative Commons Attribution-Non Commercial 4.0 International (CC BY-NC 4.0) licence (<https://creativecommons.org/licenses/by-nc/4.0/>) which permits non-commercial use, reproduction and distribution of the work without further permission provided the original work is attributed.

**REFERENCES**

- Charousset C, Beauthier V, Bellaïche L, et al.** Can we improve radiological analysis of osseous lesions in chronic anterior shoulder instability? *Orthop Traumatol Surg Res* 2010;96:S88–S93.
- Assunção JH, Gracitelli ME, Borgo GD, et al.** Tomographic evaluation of Hill–Sachs lesions: is there a correlation between different methods of measurement? *Acta Radiol* 2017;58:77–83.
- Saliken DJ, Bornes TD, Bouliane MJ, Sheps DM, Beaupre LA.** Imaging methods for quantifying glenoid and Hill–Sachs bone loss in traumatic instability of the shoulder: a scoping review. *BMC Musculoskelet Disord* 2015;16:164.
- Cho SH, Cho NS, Rhee YG.** Preoperative analysis of the Hill–Sachs lesion in anterior shoulder instability: how to predict engagement of the lesion. *Am J Sports Med* 2011;39:2389–2395.
- Ho A, Kurdziel MD, Koueiter DM, Wiater JM.** Three-dimensional computed tomography measurement accuracy of varying Hill–Sachs lesion size. *J Shoulder Elbow Surg* 2018;27:350–356.
- Ozaki R, Nakagawa S, Mizuno N, Mae T, Yoneda M.** Hill–Sachs lesions in shoulders with traumatic anterior instability: evaluation using computed tomography with 3-dimensional reconstruction. *Am J Sports Med* 2014;42:2597–2605.
- Stillwater L, Koenig J, Maycher B, Davidson M.** 3D-MR vs. 3D-CT of the shoulder in patients with glenohumeral instability. *Skeletal Radiol* 2017;46:325–331.
- Gyftopoulos S, Yemin A, Beltran L, Babb J, Bencardino J.** Engaging Hill–Sachs lesion: is there an association between this lesion and findings on MRI? *AJR Am J Roentgenol* 2013;201:W633–W638.
- Di Giacomo G, Itoi E, Burkhart SS.** Evolving concept of bipolar bone loss and the Hill–Sachs lesion: from ‘engaging/non-engaging’ lesion to ‘on-track/off-track’ lesion. *Arthroscopy* 2014;30:90–98.
- Di Giacomo G, de Gasperis N, Scarso P.** Bipolar bone defect in the shoulder anterior dislocation. *Knee Surg Sports Traumatol Arthrosc* 2016;24:479–488.
- Gyftopoulos S, Beltran LS, Bookman J, Rokito A.** MRI Evaluation of bipolar bone loss using the on-track off-track method: a feasibility study. *AJR Am J Roentgenol* 2015;205:848–852.
- Schneider AK, Hoy GA, Ek ET, et al.** Interobserver and intraobserver variability of glenoid track measurements. *J Shoulder Elbow Surg* 2017;26:573–579.
- Shaha JS, Cook JB, Rowles DJ, et al.** Clinical validation of the glenoid track concept in anterior glenohumeral instability. *J Bone and Joint Surg [Am]* 2016;98:1918–1923.
- Burns D, Chahal J, Shahrokhi S, et al.** Diagnosis of engaging bipolar bone defects in the shoulder using 2-dimensional computed tomography. *Am J Sports Med* 2016;44:2771–2777.