

Pacman flap for oncologic reconstruction of soft-tissue defects after tumor resection

A retrospective case series

Guangxue Li, MD, Lan Mu, MD*, Ye Bi, MD, Kai Yang, MD, Yan Liu, MD, Zhe Peng, MD, Yi Zhu, MD, Huiran Zang, MD, Saisai Cao, MD, Peiyang Zhang, MD, Youlei Qian, MD

Abstract

Introduction: The Pacman flap is a novel modality for repairing round soft-tissue defects after tumor resection. This modality provides a robust blood supply without microsurgical tissue rearrangement. This article reviews the authors' experience with Pacman flap for reconstruction of round soft-tissue defects. The safety and effectiveness of the Pacman flap are investigated.

Methods: Here, we describe a method for oncologic reconstruction of round soft-tissue defects with a Pacman flap after tumor resection. Fourteen consecutive patients (6 males and 8 females, median age of 60 years, range, 18–87 years) who received Pacman flaps for oncologic reconstruction during the period from April 2015 to April 2017 were included in the present study.

Results: In total, 15 Pacman flaps (including 1 bilateral Pacman flap) were created to provide coverage after resection of a tumor from the face (n = 11), chest (n = 1), or extremities (n = 2). One patient had twice previously undergone tumor resection. Median defect size was 25.5 × 25 mm (range, 9 × 9–100 × 90 mm). Median flap size was 35 × 27 mm (range, 12 × 10–120 × 110 mm). Median duration of follow-up was 10 months (range, 6–22 months). No local or distal tumor was observed during the follow-up period. All flaps survived without partial or complete necrosis, infection, or other complications. All patients were satisfied with their aesthetic outcomes. A hematoma formed in 1 patient and was successfully treated with debridement.

Conclusions: The Pacman flap enables the surgeon to achieve tension-free round defect closure after tumor resection, with good functional and aesthetic outcomes. This modality is a reliable and effective reconstructive surgical technique for oncologic reconstruction of round soft-tissue defects.

Abbreviations: CHD = coronary heart disease, KIPF = keystone island perforator flap, PCOS = polycystic ovarian syndrome.

Keywords: oncologic reconstruction, Pacman flap, soft-tissue defect, tumor resection

1. Introduction

Tumor resection frequently results in round soft-tissue defects. Numerous reconstructive procedures have been proposed for the repair of soft-tissue defects after tumor resection, including primary closure, skin grafting, and use of a local random flap or free flap. Primary closure remains the first choice for round defects after tumor resection, but excessive tension and/or distortion of adjacent tissue can lead to dehiscence. Skin graft

increases the likelihood of donor-site morbidity, color differences, and more time needed for dressing and fixation. Rotational flaps are most commonly used to cover round soft-tissue defects after tumor resection; these include the rhomboid flap,^[1,2] double-opposing skin flap,^[3] double-helix rotation flap,^[4] pinwheel flap,^[5] double-scalpel flap,^[6] Limber flap,^[7,8] and reading-man flap. These flaps were designed to take advantage of laxity in the surrounding tissue and optimize aesthetic outcomes. Flap size and capacity for movement must be sufficient to maintain blood supply and tension-free closure. Such flaps require the excision of additional tissue, in order to adjust the round defect and avoid dog-ear formation. Flaps used to cover round defects include the V-Y advancement flap^[9] and keystone island perforator flap (KIPF).^[10,11] Such flaps make full use of laxity in surrounding tissue. However, the V-Y advancement flap requires incision of proximal tissue, in order to cover the round defect. KIPF is used to cover an elliptical defect and require additional excision for shape adjustment. The perforator flap has become a common option for defect reconstruction after tumor resection.^[12–16] The perforator flap achieves satisfactory aesthetic and functional results; however, the complex microsurgical skills required, prolonged operative time, and steep technical learning curve have limited its widespread use. Therefore, local rotational flaps and bilateral or unilateral V-Y advancement flaps are often used to close round soft-tissue defects.^[9] Remaining challenges in the pursuit of good aesthetic and functional results include matching skin coloration, preserving muscle function and

Editor: Kou Yi.

This research did not receive any specific grants from funding agencies in the public, commercial, or not-for-profit sectors.

The authors have no conflicts of interest to disclose.

Department of Plastic and Reconstructive Surgery, Peking University People's Hospital, Beijing, PR China.

* Correspondence: Lan Mu, Department of Plastic and Reconstructive Surgery, Peking University People's Hospital, Beijing 100044, PR China (e-mail: mulan666@aliyun.com).

Copyright © 2018 the Author(s). Published by Wolters Kluwer Health, Inc. This is an open access article distributed under the terms of the Creative Commons Attribution-Non Commercial License 4.0 (CCBY-NC), where it is permissible to download, share, remix, transform, and buildup the work provided it is properly cited. The work cannot be used commercially without permission from the journal.

Medicine (2018) 97:25(e11114)

Received: 30 November 2017 / Accepted: 23 May 2018

<http://dx.doi.org/10.1097/MD.0000000000001114>

contour, and preserving sensitivity, especially in locations with limited skin mobility and high tension.

The modified V-Y advancement flap does not require incision of the 2 distal sections of tissue, resulting in a shape reminiscent of “Pacman,” from the popular video game. In 2001, this flap was introduced by Mithat et al^[17] as the bilateral Pacman flap for closure of pressure sores. The technique was then modified in 2007 by Aoki and Hyakusoku^[18] to a unilateral Pacman flap for soft-tissue defects. Universal muscular perforators extend from the base of the flap, allowing the Pacman flap to provide robust vascularity and relative ease of local tissue rearrangement. The Pacman flap is thus potentially suitable for use anywhere on the body. Compared with the traditional V-Y advancement flap, the Pacman flap provides similar coverage, with less advancement. Other advantages of this flap include sacrificing less of the donor site, reduced operation time, increased reproducibility of the results, convenience of use, and improved functional and aesthetic outcomes (achieved by covering defects with adjacent tissue). In the present report, we describe the results of a case series using the Pacman flap for round soft-tissue reconstruction after tumor resection, in an attempt to evaluate the safety and effectiveness of the Pacman flap.

2. Materials and methods

2.1. Subjects

Consecutive patients undergoing reconstruction with a Pacman flap at our institution, during the period from April 2015 to April 2017, were included, without consideration of age or comorbidity. Inclusion criteria were: sufficient relaxation of surrounding tissue; existence of a round defect that was difficult to suture for direct closure and/or defects located proximal to important organs, in areas where direct suture might lead to organ dislocation (e.g., eyelid, eyebrow, nasal alar, lip). No patient who met these inclusion criteria was excluded from the study. Ultimately, 14 consecutive patients (6 males and 8 females) with 15 Pacman flaps (1 bilateral Pacman flap) for coverage of round soft-tissue defects after tumor resection were included in the study (Table 1). This study was performed in accordance with the Declaration of Helsinki and was approved by the Ethics Committee of Peking University People’s Hospital (Beijing,

China). Written consent to participate in this study was obtained from all participants.

2.2. Operative technique

All operations were performed under local anesthesia, except for case 4, which required systemic anesthesia. Tumor resection was performed according to the nature of the tumor. The excision margins for mucinous carcinoma, squamous cell carcinoma, basal cell carcinoma, and other benign disorders were 2 cm, 1 cm, 5 mm, and 1 to 2 mm, respectively. Reconstruction was initiated when the tumor had been classified as benign or the margins had been declared clear. The decision to use a unilateral or bilateral Pacman flap was made based on the proximity of vital structures, tissue laxity, and skin texture. Flaps were designed to be slightly larger than the skin defect. The island flap included areas of subdermal plexus and subcutaneous fat tissue.^[9,19] Muscular perforators provided the main blood supply. Skin was incised down to the deep fascia. Two regions of proximal tissue were undermined in the deep fascial plane; in some cases, other parts of the flap required undermining for advancement. The base of the flap was designed to be larger than the surface layer, which included definite perforators to ensure a robust blood supply. For the unilateral flap, 2 proximal areas of tissue were used to create a single flap, which was then advanced to cover the defect. For the bilateral flap, 2 proximal areas of tissue were exchanged and advanced to cover the defect.

3. Results

A total of 15 flaps were completed in 14 patients. One patient received bilateral thoracic flaps. Patient age ranged from 18 to 87 years, with median age of 60 years. Defects were located on the face (n=11), chest (n=1), and extremities (n=2). One patient had twice previously undergone tumor resection. Five patients presented with comorbid conditions, including hypertension, coronary heart disease (CHD), polycystic ovarian syndrome (PCOS), lung cancer, and allergic rhinitis. Three of the patients were smokers. None of the patients underwent chemotherapy or radiotherapy before or after the procedure. None of the patients required re-excision related to the pathologic diagnosis. Histopathologic diagnoses are summarized in Table 1.

Table 1

Patient and flap characteristics.

Patient No.	Sex F/M	Age (yr)	Defect location	Defect size (mm)	Flap size (mm)	Comorbidities	Histopathologic diagnosis	Follow-up (mo)	Complications
1	M	67	Upper lip	18 × 18	25 × 20	None	BCC	19	None
2	M	87	Temple	26 × 25	34 × 26	Hypertension	BCC	7	None
3	F	62	Malar	15 × 13	16 × 14	None	Junctional nevus	10	None
4	M	61	Chest	100 × 90	120 × 110	Lung cancer	Mucinous carcinoma	22	None
5	F	61	Upper lip	20 × 20	28 × 24	None	BCC	10	None
6	F	52	Lateral brow	22 × 20	30 × 26	None	Keratoacanthoma	6	None
7	F	18	Lateral orbital	14 × 12	20 × 17	None	Intradermal nevus	9	None
8	M	60	Thigh	60 × 50	80 × 60	Allergic rhinitis	SCC, microinvasive Bowen disease	6	None
9	F	60	Infraorbital	24 × 18	32 × 24	Hypertension, CHD	BCC	15	MWD
10	F	34	Lateral orbital	40 × 30	48 × 36	PCOS	BCC	18	None
11	F	25	Nasal alar	9 × 9	12 × 10	None	Junctional nevus	8	None
12	M	53	Temple	22 × 22	25 × 23	None	Seborrheic keratosis	9	None
13	F	65	Malar	25 × 25	36 × 28	None	SCC	10	None
14	M	35	Forearm	31 × 31	40 × 32	None	Junctional nevus	6	None

BCC=basal cell carcinoma, CHD=coronary heart disease, MWD=minor wound dehiscence, PCOS=polycystic ovarian syndrome, SCC=squamous cell carcinoma.

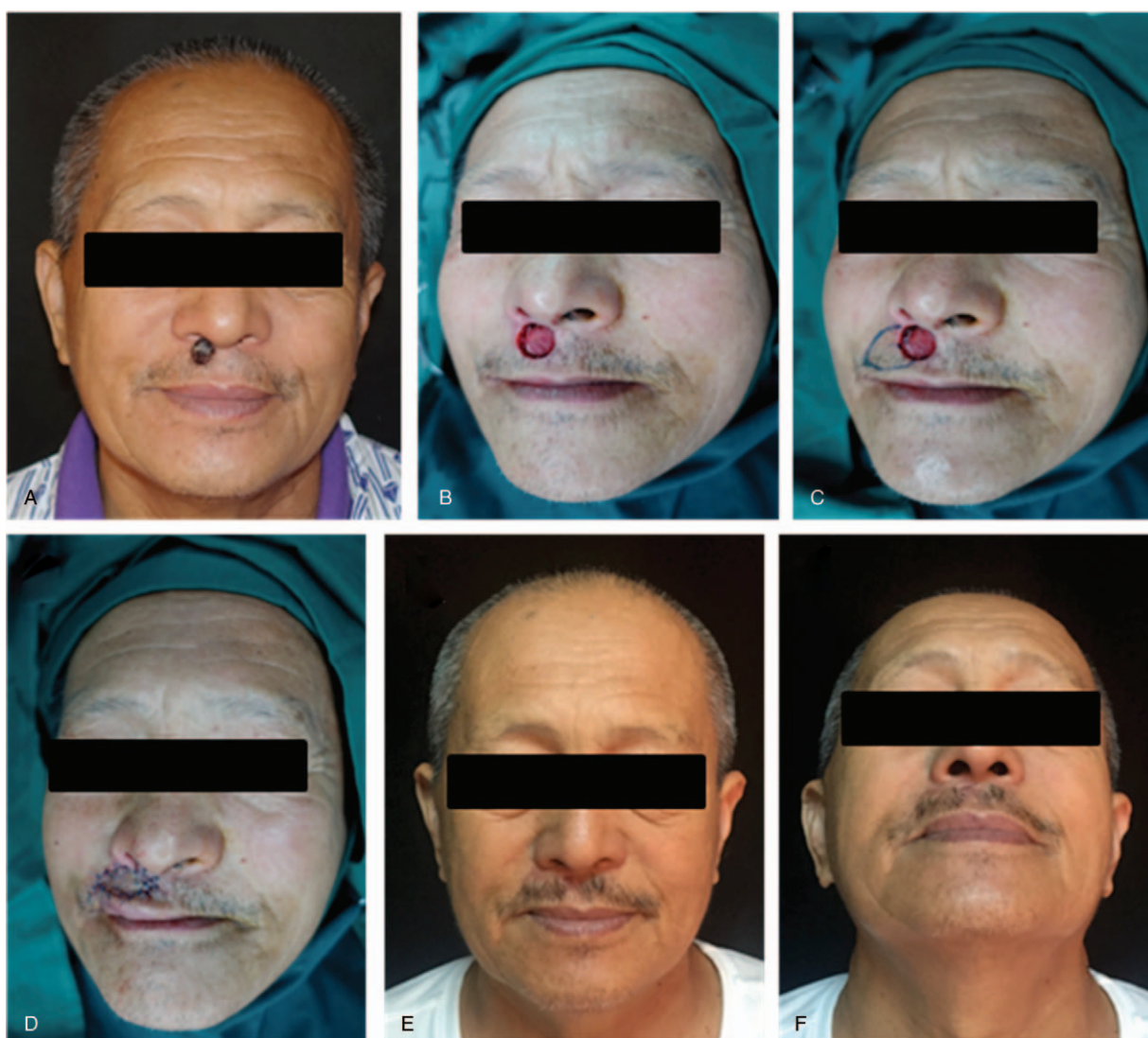

Figure 1. Patient 1. A, A 63-year-old male patient with a lesion on the right upper lip. B, C, Excisional defect and surgical plan. D, Immediate postoperative view. E, F, Postoperative view at 8 months after surgery.

All defects were well covered with the unilateral or bilateral Pacman flap. All donor sites were closed primarily without any skin graft or other flap. Median defect size was 25.5×25 mm (range, 9×9 to 100×90 mm). Median flap size was 35×27 mm (range, 12×10 to 120×110 mm). Median follow-up time was 10 months (range, 6–22 months). No local or distal tumor recurrence was observed during the follow-up period. One complication (hematoma requiring debridement) occurred in 1 patient. The hematoma was successfully treated after debridement. All flaps survived completely without partial or complete necrosis, infection, or other complications. All patients were satisfied with their aesthetic outcomes.

4. Case reports

4.1. Case 1

A 63-year-old male patient presented with a lesion that had been growing on his right upper lip for 2 years (Fig. 1A). This basal cell carcinoma was excised with the patient under local anesthesia

with 1% lidocaine (with a 5-mm free margin). The round defect was 18×18 mm (Fig. 1B). The defect was closed with a lateral Pacman flap (25×20 mm) (Fig. 1C, D). There was no recurrence or distal metastasis. The scar was deemed acceptable 8 months postoperatively (Fig. 1E, F). An excellent aesthetic outcome was achieved without displacement of the nasal base of the upper lip, with no change in the position of the patient's beard. The patient was extremely satisfied with the aesthetic outcome.

4.2. Case 2

A 34-year-old female patient presented with a lesion that had been growing on the lateral side of her left eye for 2 years (Fig. 2A). With the patient under local anesthesia with 1% lidocaine, the basal cell carcinoma was excised with a 5-mm free margin. The resulting 36×28 -mm lesion was scheduled for closure with a Pacman flap (Fig. 2B). Tension-free closure was achieved by advancing the flap, without unnecessary excision of healthy skin or dog-ear formation (Fig. 2C). At 7 months postoperatively, the results achieved were extremely satisfactory (Fig. 2D).

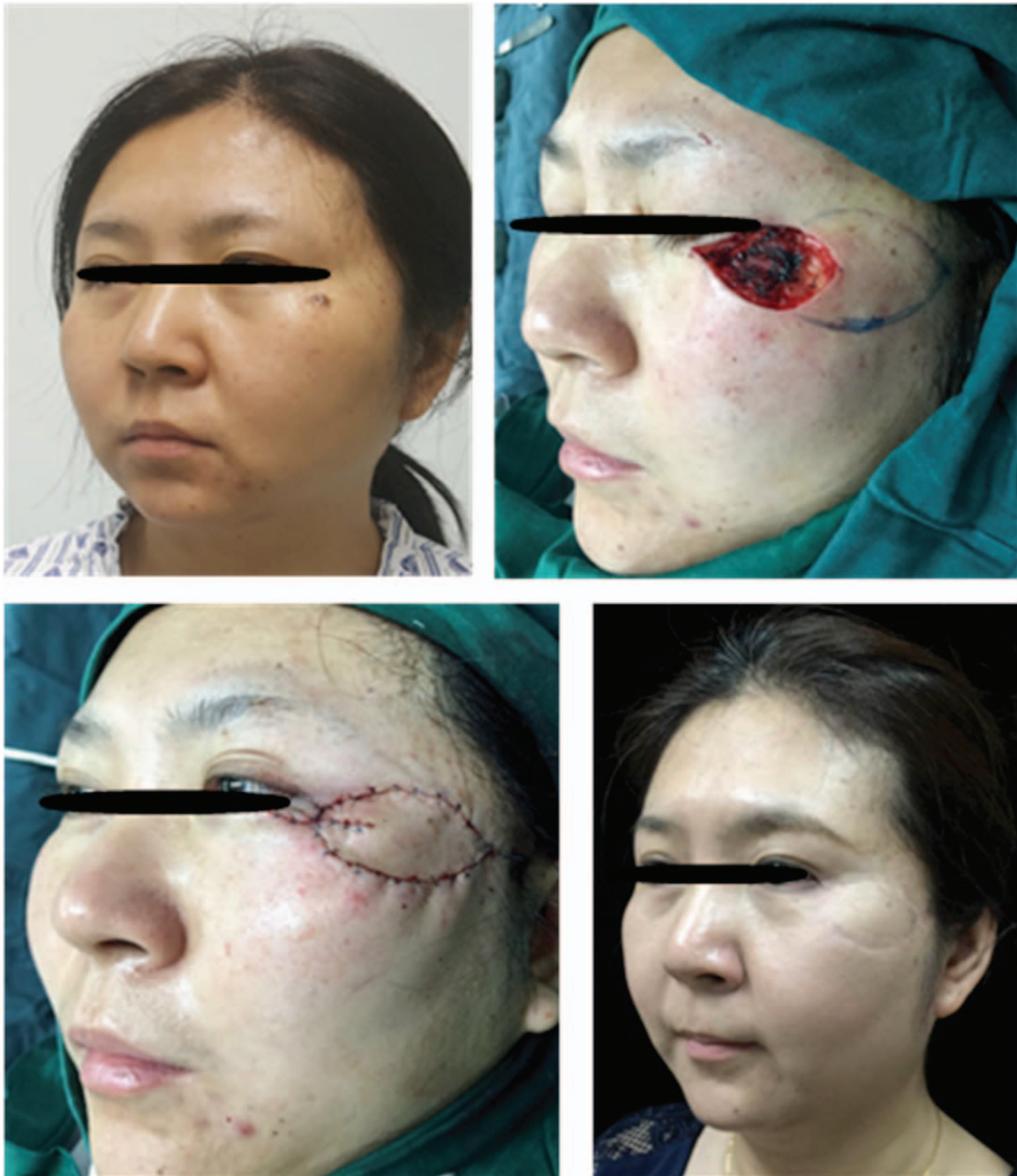

Figure 2. Patient 4. A, A 34-year-old female patient with a lesion on the lateral side of her left eye. B, Excisional defect and surgical plan. C, Immediate postoperative view. D, Postoperative view at 7 months after surgery.

4.3. Case 3

A 61-year-old male patient presented with a 5-year history of recurring mucinous carcinoma along the chest midline (Fig. 3A). The lesion was excised (with a 20-mm free margin) under systemic anesthesia. The resulting 100 × 90-mm defect was closed with a bilateral Pacman flap (Fig. 3B, C). Tension-free closure was achieved by advancing the flap, without dog-ear formation or the need to excise healthy skin (Fig. 3D). The results achieved at 5 and 11 months postoperatively were extremely satisfactory (Fig. 2E, F).

5. Discussion

This study describes use of the Pacman flap to surgically treat 14 cases of round soft-tissue defect after tumor resection. This series of 14 cases involved the creation of small and intermediate-size flaps in the head region and large flaps for the chest. This series demonstrates the versatility of the Pacman flap in the reconstruction of soft-tissue defects.

The Pacman flap was introduced to repair excisional round soft-tissue defects. The Pacman technique advances adjacent tissue from 1 or 2 sides of the defect, to an extent depending on

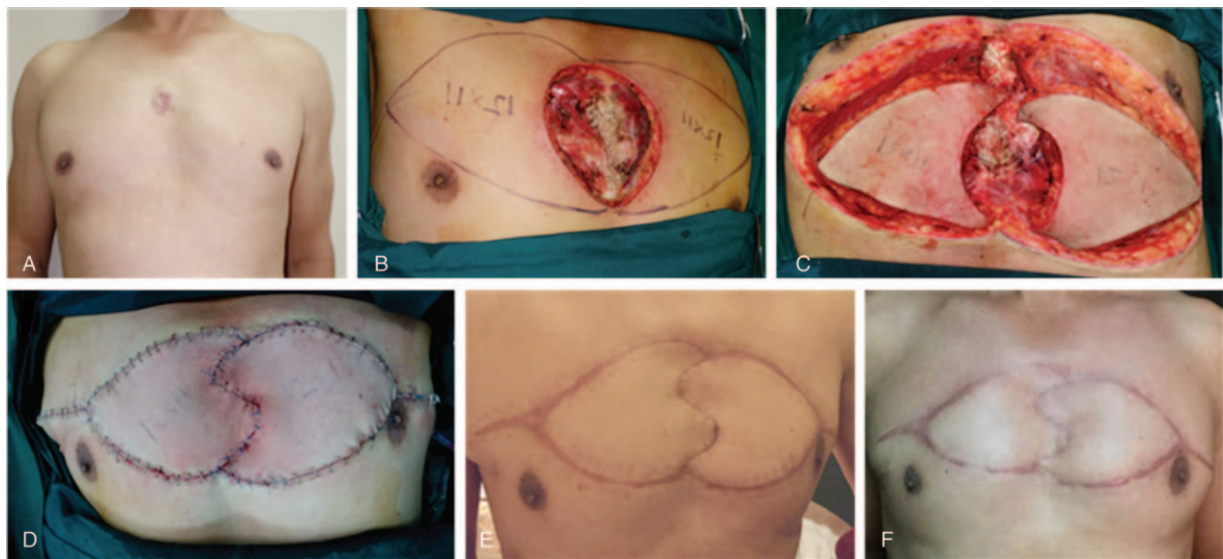


Figure 3. Patient 10. A, A 61-year-old male patient with a lesion on the chest. B, Excisional defect and surgical plan. C, Elevation of flap. D, Immediate postoperative view. E, F, Postoperative view at 5 and 11 months after surgery.

the size of the defect and the characteristics of adjacent tissue. With use of a single flap, the circular proximal portion of the flap is advanced to cover the round defect, without the need for additional excision after closure of the distal area. In cases requiring 2 flaps, these are located on either side of the defect. After dissection, both flaps were medialized to cover the defect. The 2 distal triangles were arranged to cover the round defect without distortion of anatomical landmarks.

Tumor resection often results in a round soft-tissue defect.^[20] Reconstruction of the round soft-tissue defect must be balanced with both aesthetic and functional considerations. Compared with a traditional V-Y advancement flap, the proximal portion of which is removed to adjust the round defect, the Pacman flap makes full use of 2 proximal triangle portions (as an integral flap). This approach serves to minimize advancement distance and flap pedicle dissection, so that robust blood supply and easy defect closure can be achieved simultaneously.^[18] With use of a unilateral Pacman flap, a round shape is used to cover the defect, without any additional excision. This reflects the principle that shapes should be repaired with similar shapes. The bilateral island Pacman flap makes full use of the adjacent tissue and replaces the middle linear scar of an opposite V-Y advancement flap with a zig-zag scar, thus avoiding excessive tension at the donor site. The final scar is round, and flap tension is distributed to the adjacent tissue. The flap can be used in various locations and avoids distortion of vital structures such as lips, nasal ala, eyelids, and eyebrows.

In the design and manipulation of a Pacman flap for the reconstruction of a round defect, several points should be considered. First, deep fascia must be undermined and cut to achieve mobility sufficient for flap advancement; this should include as much base as possible, in order to provide a robust blood supply. Second, to ensure flap survival, the surgeon should include definite perforator vessels when designing a large flap, in order to cover large defects in the trunk and extremities. Kim et al^[21] reported use of a perforator-based Pacman flap to repair a plantar region defect after tumor resection. Theoretically, a perforator Pacman flap should provide superior mobility and

advancement. The flap should also be $\leq 20\%$ wider than the defect.^[18] This holds especially in the facial area; however, the flap should be large enough to ensure mobility if the surrounding tissue is tight. Finally, a bilateral Pacman flap can be used to repair round defects along the midline. Mithat et al^[17] described the use of bilateral Pacman flaps to close a large defect in the caudal area after debridement of a pressure sore.

As a local flap, the Pacman flap has certain limitations, including the creation of dog-ears in the center of the flap. However, with stretch from peripheral tissue, the dog-ear is not obvious in most cases, especially those involving the facial area. The formation of dog-ears can be minimized by creating a small angle between distal portions of the flap during closure. Application of the flap must rely on the surrounding tissue as the donor site is advanced to cover the defect. If the surrounding tissue is too tight, advancement of the flap would be difficult, resulting in excessive tension at the flap suture, flap necrosis, and distortion of vital structures.

6. Conclusion

The Pacman flap is useful for the repair of round soft-tissue defects after tumor resection. Use of the Pacman flap enables the surgeon to achieve tension-free closure of a round defect after tumor resection, with satisfactory functional and aesthetic outcomes. The Pacman flap is a reliable, practical, and effective reconstructive surgical technique for oncologic reconstruction of round soft-tissue defects.

Acknowledgments

The authors thank medjaden (www.medjaden.com) for English language editing and publication support.

Author contributions

Data curation: Guangxue Li.

Investigation: Guangxue Li.

Methodology: Guangxue Li.

Resources: Guangxue Li, Kai Yang, Yan Liu, Lan Mu, Ye Bi.

Supervision: Lan Mu.

Writing – original draft: Guangxue Li.

Writing – review & editing: Guangxue Li, Yan Liu, Zhe Peng, Yi Zhu, Huiran Zang, Saisai Cao, Peiyang Zhang, Youlei Qian.

References

- [1] Wu HL, Le SJ, Zheng SS. Double opposing-rhomboid flaps for closure of a circular facial defect in a special position. *Aesthetic Plast Surg* 2009;33:523–6.
- [2] McGeorge BC. Modified rhombic flap for closure of circular or irregular defects. *J Cutan Med Surg* 1998;3:74–8.
- [3] Nel CP, Daya M. Buttock reconstruction in sarcoma surgery: an esthetic sigmoidplasty closure for large circular defects using double opposing skin flaps. *Plast Reconstr Surg Glob Open* 2016;4:e1039.
- [4] Preda TC, Ashford BG. Double helix flap to close a massive circular soft-tissue defect. *J Plast Reconstr Aesthet Surg* 2011;64:955–7.
- [5] Simsek T, Eroglu L. Versatility of the pinwheel flap to reconstruct circular defects in the temporal and scalp region. *J Plast Surg Hand Surg* 2013;47:97–101.
- [6] Kerem H, Bali U, Manavbasi YI, et al. The double scalpel flap: a new technique for the closure of circular skin defects. *J Craniofac Surg* 2013;24:2059–63.
- [7] Shim JH, Hwang NH, Yoon ES, et al. Closure of myelomeningocele defects using a limberg flap or direct repair. *Arch Plast Surg* 2016;43:26–31.
- [8] Pavlidis L, Spyropoulou GA. Limberg flap is rhombic, not rhomboid. *Plast Reconstr Surg* 2016;138:564e–5e.
- [9] Kwon KH, Dong GL, Su HK, et al. Usefulness of V-Y advancement flap for defects after skin tumor excision. *Arch Plast Surg* 2012;39:618–25.
- [10] Kostopoulos E, Agiannidis C, Konofaos P, et al. Keystone perforator island flap as an alternative reconstructive option for partial thickness alar defects up to 1.5 centimeters. *J Craniofac Surg* 2016;27:1256–60.
- [11] Kostopoulos E, Casoli V, Agiannidis C, et al. The keystone perforator island flap in nasal reconstruction: an alternative reconstructive option for soft tissue defects up to 2 cm. *J Craniofac Surg* 2015;26:1374–7.
- [12] Lombardo GA, Tamburino S, Tracia L, et al. Lateral nasal artery perforator flaps: anatomic study and clinical applications. *Arch Plast Surg* 2016;43:77–83.
- [13] Yu S, Zang M, Xu L, et al. Perforator propeller flap for oncologic reconstruction of soft tissue defects in trunk and extremities. *Ann Plast Surg* 2016;77:456–63.
- [14] Durgun M, Ozakpinar HR, Selcuk CT, et al. Repair of full-thickness nasal alar defects using nasolabial perforator flaps. *Ann Plast Surg* 2015;75:414–7.
- [15] Ruiz-Moya A, Lagares-Borrego A, Infante-Cossio P. Propeller facial artery perforator flap as first reconstructive option for nasolabial and perinasal complex defects. *J Plast Reconstr Aesthet Surg* 2015;68:457–63.
- [16] D'Arpa S, Pirrello R, Toia F, et al. Reconstruction of nasal alar defects with freestyle facial artery perforator flaps. *Facial Plast Surg* 2014;30:277–86.
- [17] Mithat AI, Sungur N, Ozdemir R, et al. Pac Man" flap for closure of pressure sores. *Ann Plast Surg* 2001;46:421–5.
- [18] Aoki R, Hyakusoku H. Pacman flap method. *Plast Reconstr Surg* 2007;119:1799–802.
- [19] Sugg KB, Cederna PS, Brown DL. The V-Y advancement flap is equivalent to the Mustardé flap for ectropion prevention in the reconstruction of moderate-size lid-cheek junction defects. *Plast Reconstr Surg* 2013;131:28e–36e.
- [20] Iorio ML, Ter Louw RP, Kauffman CL, et al. Evidence-based medicine: facial skin malignancy. *Plast Reconstr Surg* 2013;132:1631–43.
- [21] Kim H, Pyon JK, Lim SY, et al. Perforator-based Pacman flap in the plantar region. *J Foot Ankle Surg* 2011;50:747–50.