



A Factorial Analysis on Visual Outcomes of Transsphenoidal Surgery for Pituitary Macroadenoma

Ben Chat Fong Ng¹ Calvin Hoi-Kwan Mak¹ Chong Shing Yee Steffi¹ See Ka Wing¹ Tse Tat Shing¹
Cheung Fung Ching¹

¹Department of Neurosurgery, Queen Elizabeth Hospital, Hong Kong, China

Address for correspondence Ben Chat Fong Ng, MBBS, MRCS, Department of Neurosurgery, Queen Elizabeth Hospital, Hong Kong 999077, China (e-mail: stargazertheone@gmail.com).

AJNS 2022;17:280–285.

Abstract

Objective Sellar lesions are possible reversible causes of vision loss. This study is to provide quantitative objective measurement of efficacy of surgery for non-functioning pituitary adenoma and discuss different factors that could affect visual outcome of non-functioning pituitary adenoma.

Method This is a single centre, retrospective study conducted at a tertiary neurosurgery referral centre. 108 cases of sellar tumors which underwent surgery during the 3-year period from early June 2015 to late May 2018 were reviewed. Pituitary adenoma that were non-functioning and without apoplexy at initial presentation were selected for the study. We have analyzed the correlation of different factors with the visual outcome, including the extent of vertical decompression in terms of change in tumor height post operation and the extent of lateral decompression in terms of change in Knosp grading. Visual outcome was represented by the visual impairment score (VIS), an integrated measurement of visual acuity and visual field deficit.

Results Preoperative absolute tumor height and supracarotid height correlated with preoperative VIS scale ($p \leq 0.01$). Absolute Knosp grading correlates significantly with VA ($p = 0.001$) and VF ($p \leq 0.001$) of that particular eye. Although most patients had an objective improvement in visual acuity (VA) (88%) and visual field (VF) (99%) after operation, a larger reduction in tumor height and successful Knosp downgrading after surgery is associated with better VIS improvement. ($p = 0.025$) Change in supracarotid height shows trend in correlating with change in VIS ($p = 0.084$).

Conclusion Height of tumor measured from genu of cavernous ICA correlates better with visual outcome than absolute tumor height. The extent of both vertical and lateral decompression of non-functioning pituitary adenoma are important determinants that lead to better visual outcome. As endoscopic approach is able to achieve a greater degree of lateral decompression, it is a preferred approach in pituitary surgery to achieve a better visual outcome.

Keywords

- ▶ visual outcomes
- ▶ transsphenoidal surgery
- ▶ pituitary macroadenoma

DOI <https://doi.org/10.1055/s-0042-1751011>.
ISSN 2248-9614.

© 2022. Asian Congress of Neurological Surgeons. All rights reserved.

This is an open access article published by Thieme under the terms of the Creative Commons Attribution-NonDerivative-NonCommercial-License, permitting copying and reproduction so long as the original work is given appropriate credit. Contents may not be used for commercial purposes, or adapted, remixed, transformed or built upon. (<https://creativecommons.org/licenses/by-nc-nd/4.0/>)

Thieme Medical and Scientific Publishers Pvt. Ltd., A-12, 2nd Floor, Sector 2, Noida-201301 UP, India

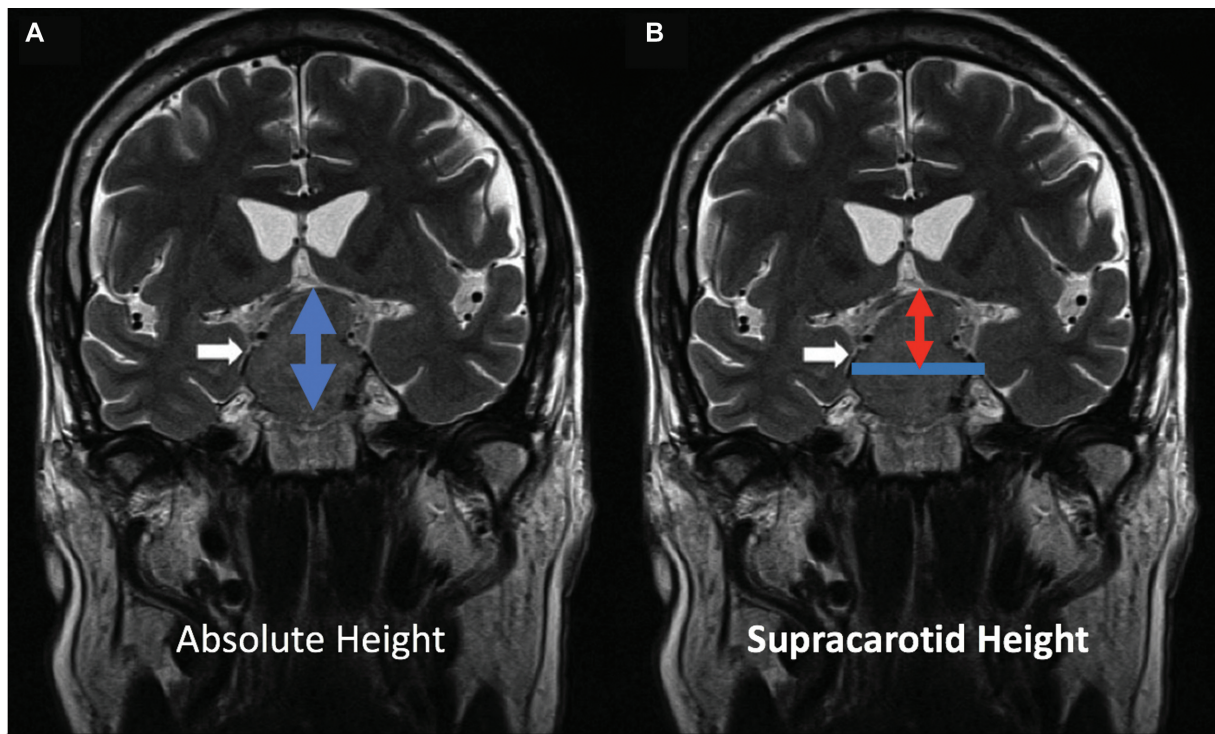


Fig. 1 (A and B) Measurement for the vertical compression representing chiasmal compression. (A) The absolute height that is measured from the most caudal to the most cranial part of the tumor. *White arrow* indicates the tumor whereas the *blue arrow* indicates the absolute tumor height. (B) The supracarotid height that is measured from the most cranial part of the tumor to the midpoint joining both genu of internal carotid artery. The *white arrow* indicates the tumor whereas the *blue line* indicates the midpoint joining both genu of internal carotid artery. The *red arrow* indicates the supracarotid height.

Introduction

Pituitary tumors are benign tumors arising from the pituitary gland. Given its location, it could exert a local mass effect onto optic nerves and optic chiasm when it grows, affecting the patient's vision. Transsphenoidal surgeries, either microscopic or endoscopic, effectively decompress the optic apparatus and regain visual function. With the advancement of endoscopes, it could achieve better gross total resection and better visual function.^{1,2} Vision can improve immediately after operations, at 3 months, and over many years.^{2,3} Factors including age, the extent of resection, Knosp grading, duration of preoperative visual field (VF) defect, and preoperative peripapillary retinal nerve fiber layer (pRNFL) thickness have been proposed to affect the visual outcomes.²⁻⁴ However, there is a lack of quantitative studies to study the degree of tumor compression and modes of surgeries on visual outcomes.

Objective

The aim of the study is to provide quantitative objective measurement of the efficacy of surgery for pituitary macroadenoma and to discuss different factors that could affect visual outcomes of pituitary macroadenoma.

Study Design

This is a single-centered retrospective study conducted at a tertiary neurosurgical referral center. One-hundred eight con-

secutive cases of pituitary macroadenomas that underwent surgeries between June 2015 and May 2018 were reviewed. Patient demographics including age, sex, percentage of apoplexy on presentation, excision methods, percentage of gross total excision, and cerebrospinal fluid (CSF) leak rate were recorded. Preoperative magnetic resonance imaging (MRI) scans of the pituitary gland were retrieved and studied. The extent of vertical compression, both absolute height and supracarotid height, was recorded, signifying chiasmal compression (→ **Fig. 1**). The absolute height of the tumor was defined as the distance from the most caudal portion to the most cranial portion of the tumor. In contrast, the supracarotid height was the distance measured from the midpoint joining both genu of the cavernous internal carotid artery to the most cranial portion of the tumor.⁵ On the other hand, the extent of lateral compression, measured by Knosp grading, was recorded, signifying optic nerve compression.⁶ Postoperative visual outcomes were assessed with visual acuity (VA), VF, and visual impairment scale (VIS). Visual impairment scale is a quantitative tool, ranging from 0 to 100, commonly employed by ophthalmologists to assess visual function. The scale combined VA and VF defect of both eyes quantitatively. The values of VIS correlate with the severity of visual function impairment.^{7,8}

Methods and Statistics

Data were analyzed using Statistical Product and Service Solutions (SPSS) version 15. Linear regression analysis was

Table 1 Basic demographics

Gender (female:male)	1:1.5
Age	59.1 ± 12.9
Percentage of apoplexy on presentation (%)	9
Modes of surgeries (%)	Endoscopic: 87% Microscopic: 13%
Percentage of gross total resection (%)	Endoscopic: 43.6% Microscopic: 35.7%
Overall postoperative CSF leak rate (%)	4.6%

Abbreviation: CSF, cerebrospinal fluid.

used to study the relationship between VA, VIS, tumor height, and Knosp grading. Independent sample *t*-test and chi-square test were used to study the effect of Knosp grading, modes of surgeries, VA, VF, and VIS.

Results

Basic Demographics

Pituitary macroadenomas were resected via transsphenoidal surgeries, either microscopic or endoscopic. Basic demographics are summarized in ►Table 1. The total number of female patients was similar to male patients (1:1.5). The mean age was 59 years old. Among them, 9% presented with pituitary apoplexy. The majority of macroadenomas (87%) were resected by endoscopic transsphenoidal surgery. The gross total excision rate was higher in the endoscopic arm (43.6%) than the microscopic arm (35.7%) ($p = 0.58$). Overall postoperative CSF leak rate was 4.6%.

Vertical Compression

There is a linear relationship between VIS and supracarotid (β coefficient = 0.48, $p < 0.01$) and absolute height (β coefficient = 0.54, $p < 0.01$). Patients with larger tumors will have a worse visual function (higher VIS). A decrease in absolute height does not correlate significantly with VIS, while the decrease in supracarotid height shows a trend in correlation with improvement in VIS ($p = 0.084$) (►Fig. 2).

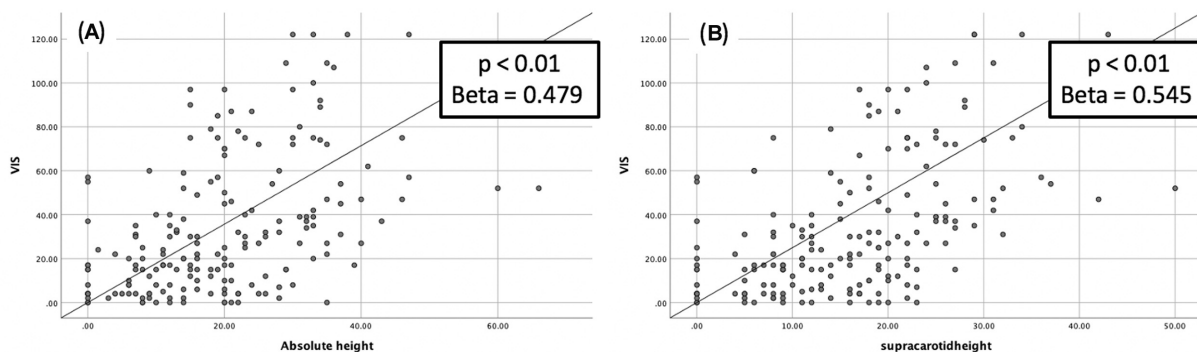


Fig. 2 (A) The linear relationship between absolute height and visual impairment scale (VIS). (B) The linear relationship between supracarotid height and VIS.

Lateral Compression

Absolute Knosp grading correlates significantly with VA ($p = 0.001$) and VF ($p < 0.001$) of the same laterality (►Fig. 3). With transsphenoidal surgeries, the parasellar portion of pituitary macroadenomas can be debulked. Knosp grading was measured from postoperative MRI and compared with preoperative Knosp grading. Downgrading of Knosp grading after surgeries was associated with better VA improvement ($p = 0.025$) (►Fig. 4) and more VF improvement ($p = 0.027$).

Modes of Surgeries

Concerning the modes of surgeries, there is no significant difference in vertical decompression in both microscopic and endoscopic arms in terms of absolute and supracarotid height. Therefore, both surgical approaches are equally effective in decompressing optic chiasm. On the other hand, the endoscopic approach results in greater Knosp downgrading, that is, lateral decompression. Therefore, the endoscopic approach is more effective in decompressing the optic nerves than the microscopic arm ($p = 0.03$) (►Fig. 5).

Discussion

In the last few decades, different authors reported their experience on pituitary adenoma surgeries and analyzed prognostic factors for postoperative visual outcomes.^{9–14} In 2011, Barzaghi et al concluded that preoperative visual function, young age, and low craniocaudal diameter predict a complete visual recovery.¹⁵ Suprasellar extension of pituitary adenoma was considered an essential factor for visual outcomes in the series of Luomaranta et al.¹⁶ In 2017, Sun et al published a meta-analysis on predictive factors of visual function recovery after pituitary adenoma resection.⁴ Preoperative VF defect, symptom duration, patient age, and preoperative pRNFL thickness are the dominant predictive factors of the postoperative recovery of the VF for patients with pituitary adenoma. However, there is a lack of quantitative preoperative imaging studies on postoperative visual outcomes.

Our study showed the efficacy of endoscopic transsphenoidal surgeries on visual outcomes in patients with pituitary adenoma, consistent with the literature. In a recent meta-analysis by

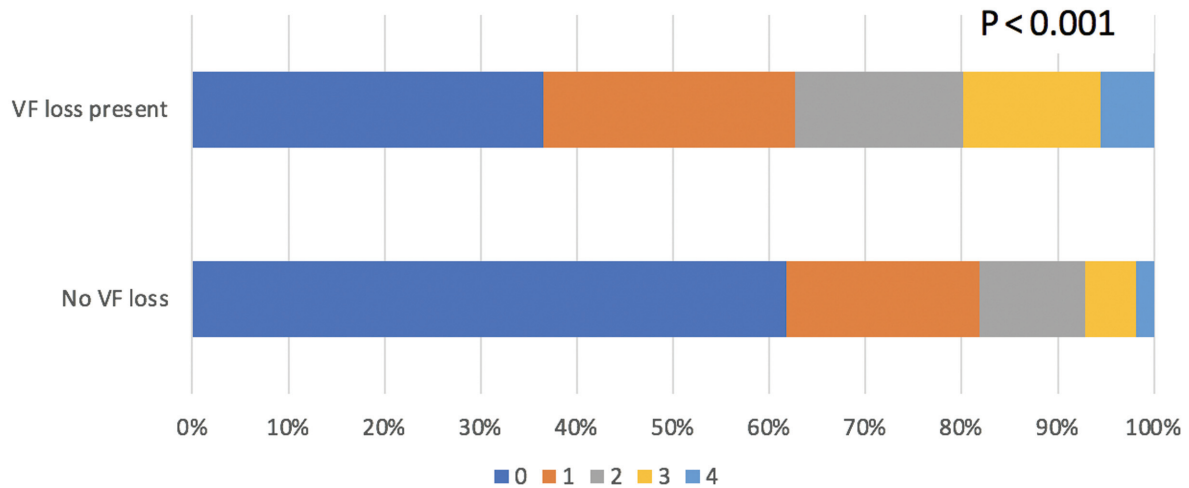


Fig. 3 The percentage of patients with visual field loss in different Knosp grading. Patients with high Knosp grading are more likely to develop visual field (VF) loss.

Guo et al comparing microscopic and endoscopic transsphenoidal surgeries for pituitary adenoma, the endoscopic group achieves a better gross total resection rate and visual improvement.¹ Anatomy of the tumor on preoperative MRI correlates with preoperative visual impairment. Absolute and supracarotid height on preoperative MRI shows a linear relationship with VIS, whereas the decrease in supracarotid height correlates with improvement in visual impairment. Knosp grading is also helpful in correlating preoperative visual impairment and VF defect. It should be emphasized that vertical compression signifying optic chiasm compression is different from lateral compression signifying optic nerve compression. Therefore, they are investigated separately in this study. In our study,

both vertical and lateral decompression were essential for good visual outcomes. Both microscope and endoscope are equally effective in achieving chiasmal decompression. In contrast, the endoscope can achieve better lateral decompression and better visual outcomes than the microscopic arm. It is attributed to the technological advancement of the endoscope and endoscopic instruments, conferring a better visualization and broader angles of viewing and manipulation.¹⁷

For the limitations of this study, it is a retrospective single-centered study. It involved multiple surgeons so that the surgeon's experiences could not be taken into account. The chronicity of optic nerve compression could not be standardized. These confounding factors could potentially affect the

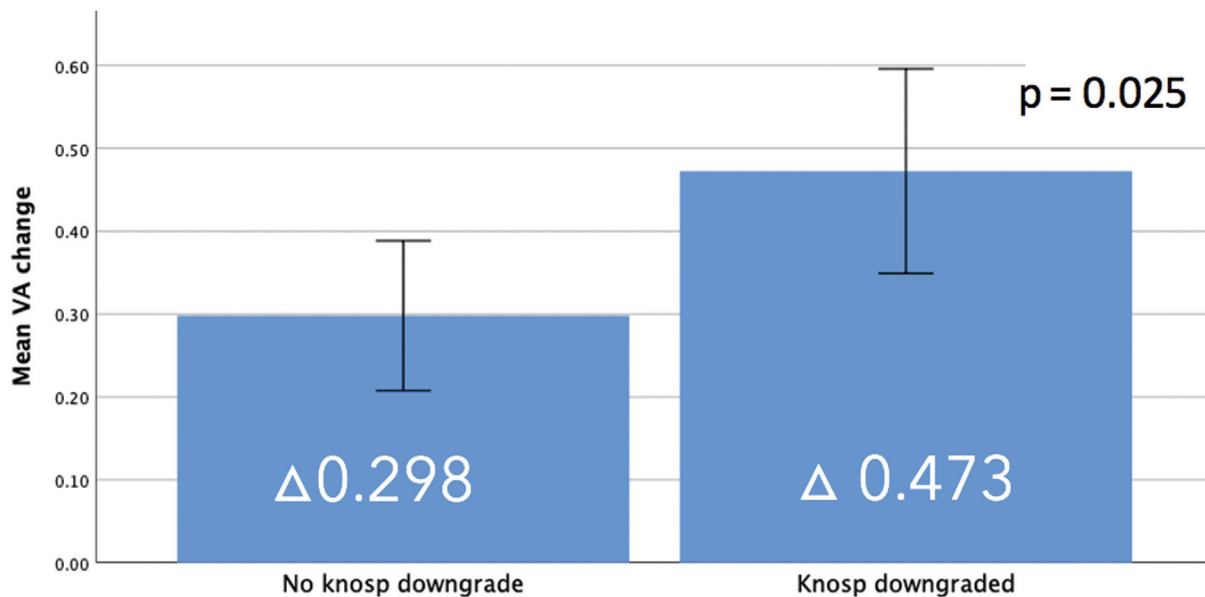


Fig. 4 The bar chart showing the mean change of visual acuity (VA) in patients with or without Knosp grading downgraded after surgeries. Patients with Knosp downgraded have a bigger improvement of VA.

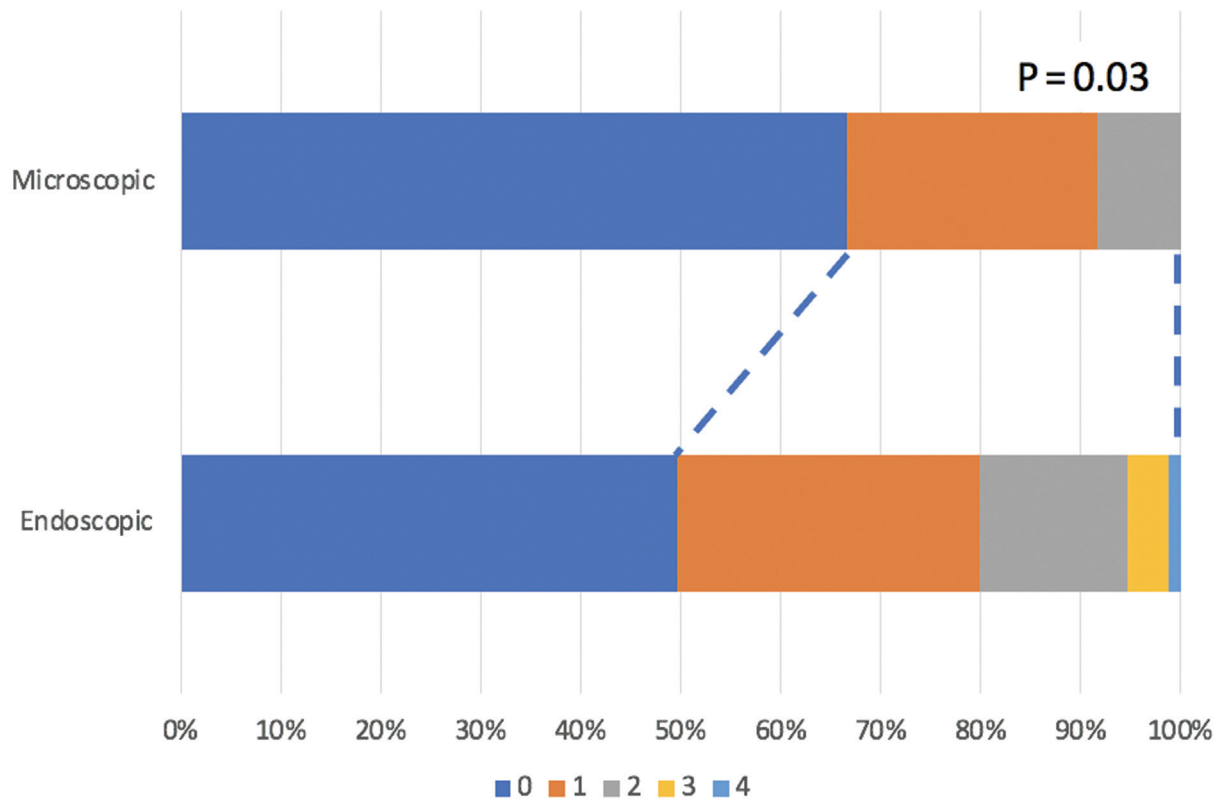


Fig. 5 The difference in Knosp grading before and after surgeries. Endoscopic approach results in greater Knosp downgrading.

visual outcomes of the patients. There were also no objective measures of optic nerve dysfunction (e.g., optical coherence tomography). These may be valuable tools that warrant further studies to predict visual outcomes.¹⁸

Conclusion

The extent of both vertical and lateral decompression of pituitary macroadenoma is essential for achieving better visual outcomes. Height of tumor measured from genu of cavernous ICA correlates better with the visual outcome than the absolute tumor height. As the endoscopic approach can achieve a greater degree of lateral decompression, it is preferred in pituitary surgery to achieve a better visual outcome.

Note

This paper was presented at the ACNS at ACNS-YNS Autumn Web Seminar 2021 on November 20, 2021.

Funding

None.

Conflict of Interest

None declared.

References

- Guo S, Wang Z, Kang X, Xin W, Li X. A meta-analysis of endoscopic vs. microscopic transsphenoidal surgery for non-functioning and functioning pituitary adenomas: comparisons of efficacy and safety. *Front Neurol* 2021;12:614382. Doi: 10.3389/fneur.2021.614382
- Møller MW, Andersen MS, Glinborg D, et al. Endoscopic vs. microscopic transsphenoidal pituitary surgery: a single centre study. *Sci Rep* 2020;10(01):21942. Doi: 10.1038/s41598-020-78823-z
- Gnanalingham KK, Bhattacharjee S, Pennington R, Ng J, Mendoza N. The time course of visual field recovery following transphenoidal surgery for pituitary adenomas: predictive factors for a good outcome. *J Neurol Neurosurg Psychiatry* 2005;76(03):415–419
- Sun M, Zhang ZQ, Ma CY, Chen SH, Chen XJ. Predictive factors of visual function recovery after pituitary adenoma resection: a literature review and meta-analysis. *Int J Ophthalmol* 2017. Published. Doi: 10.18240/ijo.2017.11.17
- Yang Y, Bao Y, Xie S, et al. Identification of the extradural and intradural extension of pituitary adenomas to the suprasellar region: classification, surgical strategies, and outcomes. *Front Oncol* 2021;11:723513. Doi: 10.3389/fonc.2021.723513
- Knosp E, Kitz K, Steiner E, Matula C. Pituitary adenomas with parasellar invasion. *Acta Neurochir Suppl (Wien)* 1991;53:65–71
- Yu F, Afifi AA. Descriptive statistics in ophthalmic research. *Am J Ophthalmol* 2009;147(03):389–391
- Fahlbusch R, Schott W. Pterional surgery of meningiomas of the tuberculum sellae and planum sphenoidale: surgical results with special consideration of ophthalmological and endocrinological outcomes. *J Neurosurg* 2002;96(02):235–243
- Cohen AR, Cooper PR, Kupersmith MJ, Flamm ES, Ransohoff J. Visual recovery after transsphenoidal removal of pituitary adenomas. *Neurosurgery* 1985;17(03):446–452
- Lee GI, Park KA, Oh SY, Kong DS. Parafoveal and peripapillary perfusion predict visual field recovery in chiasmal compression due to pituitary tumors. *J Clin Med* 2020;9(03):697. Doi: 10.3390/jcm9030697
- Lachowicz E, Lubiński W. The importance of the electrophysiological tests in the early diagnosis of ganglion cells and/or optic

- nerve dysfunction coexisting with pituitary adenoma: an overview. *Doc Ophthalmol* 2018;137(03):193–202
- 12 Muskens IS, Zamanipoor Najafabadi AH, Briceno V, et al. Visual outcomes after endoscopic endonasal pituitary adenoma resection: a systematic review and meta-analysis. *Pituitary* 2017;20(05):539–552
 - 13 Goudakos JK, Markou KD, Georgalas C. Endoscopic versus microscopic trans-sphenoidal pituitary surgery: a systematic review and meta-analysis. *Clin Otolaryngol* 2011;36(03):212–220
 - 14 Sturges I, Rudd AG, Shilling J. Unrecognized visual problems amongst residents of Part III Homes. *Age Ageing* 1994;23(01):54–56
 - 15 Barzaghi LR, Medone M, Losa M, Bianchi S, Giovanelli M, Mortini P. Prognostic factors of visual field improvement after trans-sphenoidal approach for pituitary macroadenomas: review of the literature and analysis by quantitative method. *Neurosurg Rev* 2012;35(03):369–378, discussion 378–379
 - 16 Luomaranta T, Raappana A, Saarela V, Liinamaa MJ. Factors affecting the visual outcome of pituitary adenoma patients treated with endoscopic transsphenoidal surgery. *World Neurosurg* 2017;105:422–431
 - 17 Jean W, Deklotz TR. Endoscopic Endonasal Approach for Pituitary Tumor Resection. *CSurgeries* 2016. Published. Doi: 10.17797//bdxmmst16
 - 18 Cennamo G, Solari D, Montorio D, et al. Early vascular modifications after endoscopic endonasal pituitary surgery: the role of OCT-angiography. *PLoS One* 2020;15(10):e0241295. Doi: 10.1371/journal.pone.0241295