

# Ultrasonographic Measurement of Upper Eyelid Thickness in Korean Children with Epicanthus

Ho-Sun Lee, MD, Helen Lew, MD, Young-Soo Yun, MD

Department of Ophthalmology, Pochun CHA University College of Medicine, Pundang CHA Hospital, Sungnam, Korea

**Purpose:** Upper eyelid thickness was measured to determine whether there is a difference in the thickness of the upper eyelids in children with and without epicanthus.

**Methods:** Children were enrolled into the epicanthus group or non-epicanthus (control) group. The children with epicanthus were classified into four subgroups according to the Duke-Elder's classification. The thickness of the upper eyelid was measured at five points with A-scan ultrasonography.

**Results:** There was no significant difference in upper eyelid thickness between the epicanthus group and control group ( $P>0.05$ ) or between the subgroups of the epicanthus group ( $P>0.05$ ).

**Conclusions:** This result suggests that the etiology of epicanthus may not be hypertrophy of soft tissue. *Korean Journal of Ophthalmology 20(2):79-81, 2006*

**Key Words:** A-scan ultrasonography, Epicanthus, Eyelid thickness

Epicanthus is characterized by a bilateral vertical fold of skin adjacent to the eyelid margin, which is rolled in toward the globe.<sup>1</sup> In patients with epicanthus the eyelid tends to be puffy and more prominent medially. It is usually associated with inversion of eyelashes and resultant ocular irritation. If the epicanthus becomes symptomatic, it may be managed by surgical treatment.<sup>1-3</sup>

Epicanthus is caused by a combination of hypertrophied muscle and an extra skin fold.<sup>4</sup> Some authors believe that epicanthus can be caused by redundant skin and growth retardation of the skull, especially the nasal bone.<sup>4</sup> Epicanthus may resolve without treatment as facial development expands the nasal bridge and midface.<sup>4</sup> Blepharophimosis-ptosis-epicanthus inversus syndrome (BPES) occurs sporadically or as an autosomal dominant disorder.<sup>5</sup> The congenital condition epiblepharon has been attributed to a Z-shaped kink in the orbicularis fibers and the absence of levator aponeurotic attachment to the orbicularis and skin.<sup>6</sup> In contrast the etiology of epicanthus development is not known, and there are no reports on the thickness of the upper eyelids in cases of epicanthus. The present study compares the upper eyelid thickness of children with and without epicanthus to determine whether epicanthus is associated with a difference

in the thickness of the upper eyelids.

## Materials and Methods

The study included 100 eyes of 50 children with epicanthus and 100 eyes of 50 children without epicanthus. There was no history of previous eyelid surgery, BPES and other ophthalmological problem.

The epicanthus patients were classified into four groups according to Duke-Elder's classification (Fig. 1A).<sup>2,4</sup> In epicanthus supraciliaris the epicanthal fold arises from the region of the eyebrow and runs toward the tear sac or the nostrils. In epicanthus palpebralis the epicanthal fold arises from the upper lid, above the tarsal region, and extends to the lower margin of the orbit (Fig. 1B). In epicanthus tarsalis the epicanthal fold arises from the tarsal fold and is lost in the skin close to the inner canthus (Fig. 1C). Epicanthus inversus differs greatly from the first three cases, with a small epicanthal fold arising in the lower eyelid and extending upward, partially covering the inner canthus (Fig. 1D).

The anterior segments of the eyes were examined with a slit-lamp to rule out the possibility of conjunctival inflammation, swelling, or a mass, that may change the thickness of the upper eyelid. The thickness of the upper lid was measured in mm by A-scan ultrasonography with a 10.0 MHz probe (A/B scan system, Humphrey instruments, INC., USA) (Fig. 2, 3). Three measurements were taken at each of five points by one investigator and the average values were used for data analysis. The five points of measurement in the upper lid were as follows; first point (I) - 3 mm upper point above the ciliary line on the middle line of the horizontal

Received: July 11, 2005 Accepted: January 16, 2006

Reprint requests to Helen Lew MD, Department of Ophthalmology, Pochun CHA University College of Medicine, #351 Yatap-dong, Bundang-gu, Sungnam, Gyeonggi-do 463-712, Korea. Tel: 82-31-780-5330, Fax: 82-31-780-5333, E-mail: eye@cha.ac.kr

\* This study was presented in part at the 89th annual meeting of the Korean Ophthalmology Society, on October 10, 2003.

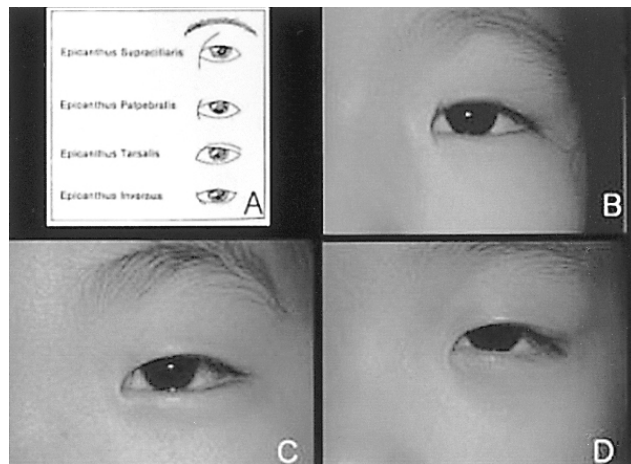


Fig. 1. A. Classification of epicanthus; B. Epicanthus palpebralis; C. Epicanthus tarsalis; D. Epicanthus inversus.

eyelid, second point (II) - 3 mm upper point on the superior border of tarsal plate on the middle line of the horizontal eyelid, third point (III) - 3 mm lower point below the orbital rim on the middle line of the horizontal eyelid, fourth point (IV) - 3 mm upper point above the ciliary line at the medial canthal lid margin, fifth point (V) - 3 mm upper point above the ciliary line at the lateral canthal lid margin.

SPSS for Windows Ver. 11.0 was used to compute routine statistics, including proportions, independent t-test, and ANOVA. The significance level used for all statistical tests was 0.05.

## Results

The mean age of the group with epicanthus was  $6.30 \pm 2.46$  years (range 3 to 12 years) and there were 58 males and 42 females. The mean age of the group without epicanthus was  $6.40 \pm 2.62$  years (range 2 to 15 years) and there were 43 males and 47 females. The two groups were not statistically different with respect to age or gender ( $P > 0.05$ ).

The mean thickness of the upper lids of children with epicanthus was greater than that of children without epicanthus ( $4.39 \pm 0.34$  mm and  $4.36 \pm 0.35$  mm respectively); however, this difference was not significant ( $P > 0.05$ , Table 1). According to the Duke-Elder classification, this study population contained no cases in the epicanthus supraciliaris group (0%), 9 in the epicanthus palpebralis group (18%), 34 in the epicanthus tarsalis group (68%), and 7 in the epicanthus inversus group (14%). There was no statistical difference between the groups in eyelid thickness at the measured five points ( $P > 0.05$ , Table 2).

## Discussion

Epicanthus is reported to be common in oriental infants, with the prevalence decreasing with aging.<sup>1</sup> Epicanthal folds, the most prevalent feature, were also found in patients with

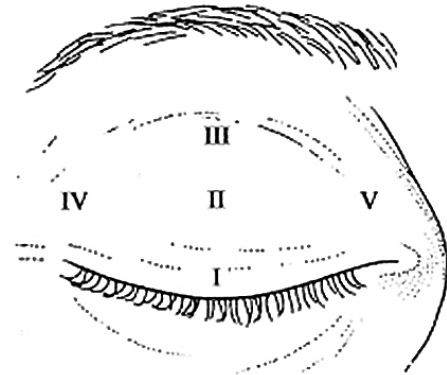


Fig. 2. Five points were measured with A-scan ultrasonography.

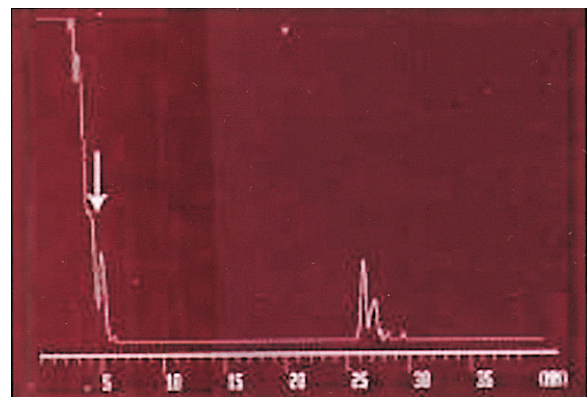


Fig. 3. A-scan ultrasonography. The arrow indicates the lid thickness of the upper eyelid.

Down syndrome.<sup>7</sup> There is no sexual predilection and bilateral involvement is common.<sup>4</sup> Most children have no symptoms although some complain of tearing, discharge, itching, foreign body sensation or frequent blinking of the eye due to the exaggerated puffy fold of skin.

The medical treatment for epicanthus involves the application of artificial tears into the eyes and observation. Surgical treatment of epicanthus is disputed because the symptoms may not be severe and generally improve with age.<sup>2,3</sup> The authors usually waited to decide on surgery until the patient reached pre-school age and performed the operation only on patients with severe irritable symptoms and cosmetic problems.

The pathogenesis of epicanthus is not known. The upper eyelids of epicanthus usually appear very puffy and bulky, especially in the medial area; however, there were no previous reports on the thickness of the eyelid in epicanthus. The present study showed that there was no statistical difference in the upper lid thickness of children with and without epicanthus. This result suggests that the etiology of epicanthus is not the hypertrophy of soft tissue. It is possible that histological differences of the eyelid retractors and orbicularis growth retardation of the skull, especially the

**Table 1.** Comparison of upper lid thickness in children with and without epicanthus (mm)

Location of upperlid	Without epicanthus	With epicanthus	P-value
I	4.24±0.43	4.31±0.45	0.467
II	4.27±0.45	4.30±0.45	0.561
III	4.52±0.51	4.50±0.52	0.942
IV	4.42±0.52	4.53±0.54	0.864
V	4.34±0.43	4.29±0.45	0.519
Total	4.36±0.35	4.39±0.34	0.544

**Table 2.** Comparison of upper lid thickness among subtypes of epicanthus group (mm)

Location of upper lid	Subtype of epicanthus			P-value
	Epicanthus palpebralis	Epicanthus tarsalis	Epicanthus inversus	
I	4.24±0.41	4.32±0.44	4.40±0.53	0.587
II	4.28±0.47	4.34±0.46	4.16±0.33	0.381
III	4.48±0.48	4.50±0.56	4.49±4.51	0.986
IV	4.63±0.51	4.50±0.56	4.52±0.44	0.662
V	4.35±0.36	4.30±0.49	4.18±0.45	0.559
Total	4.40±0.30	4.39±0.38	4.35±0.17	0.917

nasal bone, may be related to epicanthus.

There are few technologies available to image and measure the upper eyelid in vivo. Ultrasonography is commonly used in the treatment of eyelid disease and evaluation of the structure of the eyelid.

Mair et al<sup>8</sup> used orbital sonography to evaluate the swelling of the eyelid in orbital cellulitis patients with a 5-12 MHz probe. Schrom et al<sup>9</sup> visualized the tarsal plate in the upper eyelid and measure the diameter and the curvature of the upper eyelid implants with ultrasonography through a 7.5 MHz probe. In the present study upper lid thickness was measured by A-scan ultrasonography with a 10.0 MHz probe that had a resolution high enough to measure the thickness of the whole upper eyelid. Despite our best efforts it is possible that inevitable pressure to the eyelid may have resulted in some errors. Although A-scan sonography can be

used to reliably measure eyelid thickness, ultrasound biomicroscopy is more accurate. Hosal et al<sup>10</sup> recently used ultrasound biomicroscopy (50 MHz) to measure the thickness of the levator aponeurosis in ptosis patients. High resolution sonography is considered the method of choice to investigate eyelid structures and movement associated with epicanthus and other eyelid abnormalities.

The results of this study indicate that further studies of eyelid morphology and histology are warranted to elucidate the pathogenesis of epicanthus.

## References

1. Nesi FA, Lisman RD, Levine MR. *Smith's ophthalmic plastic and reconstructive surgery*, 2nd ed. St. Louis: Mosby, 1998:982-7.
2. Johnson CC. Epicanthus and Epiblepharon. *Arch Ophthalmol* 1978;96:1030-3.
3. Wu W, Xu J, He B. Correction of severe congenital epicanthus using the modified square-flap method. *Br J Plast Surg* 2000;53:667-8.
4. Duke-Elder S. *System of ophthalmology*, Vol 3, St. Louis: Mosby, 1964:851-6.
5. Cha SC, Jang YS, Lee JH. Mutational analysis of forkhead transcriptional factor 2 (FOXL2) in Korean patients with blepharophimosis-ptosis-epicanthus inversus syndrome. *Clin Genet* 2003;64:485-90.
6. Yang SW, Choi WC, Kim SY. Refractive changes of congenital entropion and epiblepharon on surgical correction. *Korean J Ophthalmol* 2001;15:32-7.
7. Kim JH, Hwang JM, Kim HJ, et al. Characteristic ocular findings in Asian children with Down syndrome. *Eye* 2002;16:710-4.
8. Mair MH, Geley T, Judmaier W, et al. Using orbital sonography to diagnose and monitor treatment of acute swelling of the eyelids in pediatric patients. *Am J Roentgenol* 2002;179:1529-34.
9. Schrom T, Bloching M, Wernecke K, et al. Measurement of upper eyelid implants curvature by ultrasound. *Laryngoscope* 2005;115:884-8.
10. Hosal BM, Ayer NG, Zilelioglu G, Elhan AH. Ultrasound biomicroscopy of the levator aponeurosis in congenital and aponeurotic blepharoptosis. *Ophthalm Plast Reconstr Surg* 2004;20:308-11.