

# “Reverse” Bypass Using a Naturally Formed “Bonnet” Superficial Temporal Artery in Symptomatic Common Carotid Artery Occlusion: A Case Report

Naoki OTANI,<sup>1</sup> Kojiro WADA,<sup>1</sup> Fumihiko SAKAKIBARA,<sup>1</sup> Kimihiro NAGATANI,<sup>1</sup> Satoru TAKEUCHI,<sup>1</sup> Satoshi TOMURA,<sup>1</sup> Hideo OSADA,<sup>1</sup> Daisuke MIZOKAMI,<sup>2</sup> Takuji YAMASHITA,<sup>2</sup> Akihiro SHIOTANI,<sup>2</sup> and Kentaro MORI<sup>1</sup>

*Departments of <sup>1</sup>Neurosurgery and <sup>2</sup>Otolaryngology, National Defense Medical College, Tokorozawa, Saitama*

## Abstract

We herein describe a patient with symptomatic common carotid artery occlusion who underwent a reverse superficial temporal artery (STA)-middle cerebral artery (MCA) single bypass using a naturally formed “bonnet” STA. The surgical procedure was performed without difficulty, and no further neurological deterioration was observed after surgery. In practice, this case highlights that the reverse STA-MCA bypass can be achieved safely and less invasively using a naturally formed “bonnet” STA.

Key words: superficial temporal artery-middle cerebral artery bypass, artery occlusion, transient ischemic attack

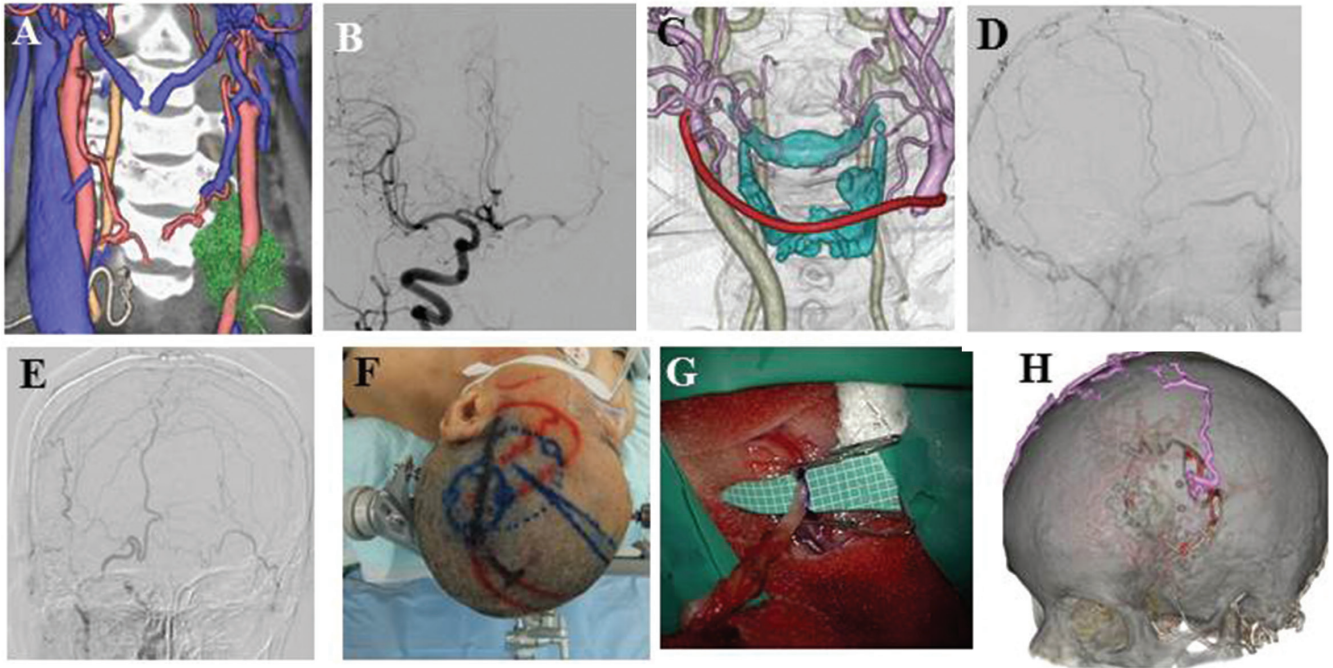
## Introduction

Hemodynamic cerebral ischemia results in the development of ischemic symptoms in common carotid artery (CCA) occlusion. In these cases, the blood flow of the ipsilateral superficial temporal artery (STA) to the occluded CCA is usually poor, therefore, “bonnet” bypass using a radial artery (RA) or saphenous vein graft is usually considered.<sup>1–3)</sup> However, if a spontaneously formed “bonnet” STA with sufficient retrograde blood flow from the contralateral STA is available, a so-called “reversed” arterial bypass should be considered, because this surgical procedure can, therefore, be both safely and less invasively achieved.

## Case Report

A 76-year-old female was admitted to our hospital because of a left thyroid tumor involving the left CCA (Fig. 1A). Preoperative digital subtraction angiography (DSA) showed that there was cross-flow from the contralateral side through the anterior communicating artery filling the middle cerebral artery (MCA) territory. The balloon occlusion test (BOT) showed that she could tolerate a 30-minute

occlusion (Fig. 1B). However, the stump pressure of the external carotid artery (ECA) sustained low value of 45 mmHg as a stump pressure at 110 mmHg of systolic pressure during the BOT. The thyroid tumor was resected with the left CCA due to its involvement, and reconstructive ECA-CCA bypass using an RA graft was performed (Fig. 1C). The histological findings showed a malignant tumor. Recurrent transient ischemic attacks manifesting as hemiparesis and dyesthesia of the right hand started to occur from 2 weeks after the operation. A CT perfusion study showed an increase of cerebral vascular volume (CBV), and a prolongation of the mean transit time (MTT) and time to peak (TTP) in the extent frontal lobe and -left side (Fig. 2A–I). Postoperative three dimensional-computed tomography angiography (3D-CTA) showed that the reconstructive ECA-CCA bypass has occluded. Postoperative DSA showed that the left STA was filling in a retrograde fashion from the right STA over the midline of the head (Fig. 1D, E). A reversed single STA-MCA bypass was performed using a naturally formed “bonnet” STA (Fig. 1F). The left STA was anastomosed to a cortical artery in the left frontal lobe so that the cerebral blood flow in the left STA was supplied in a retrograde fashion (Fig. 1G). Postoperative 3D-CTA showed that the anastomosed bonnet STA perfused the MCA territory (Fig. 1H). The postoperative course was uneventful. Postoperative



**Fig. 1** A: Preoperative 3D-CTA showed a left thyroid tumor involving the left CCA. B: Preoperative DSA showed that there was cross-flow through the anterior communicating artery filling the MCA territory. C: The thyroid tumor was resected with reconstructive ECA-RA-CCA bypass using an RA graft. D, E: Postoperative DSA showed that the left STA was filling in a retrograde fashion from the right STA over the midline of the head. F: A reversed single STA-MCA bypass was performed using a naturally formed “bonnet” STA. G: The left STA was anastomosed to a cortical artery in the left frontal lobe so that the cerebral blood flow in the left STA was supplied in a retrograde fashion. H: Postoperative 3D-CTA showed that the anastomosed bonnet STA perfused the MCA territory. CCA: common carotid artery, DSA: digital subtraction angiography, ECA: external carotid artery, MCA: middle cerebral artery, RA: radial artery, STA: superficial temporal artery, 3D-CTA: three dimensional-computed tomography angiography.

computed tomography (CT) showed small cerebral infarction at the frontal lobe. Postoperative CT perfusion study showed a decrease of CBV, and a normalization of MTT and TTP in the extent frontal lobe and -left side (Fig. 2J–R). As of 6 months after surgery, the patient has been doing well.

## Discussion

In 1980, Spetzler et al.<sup>3)</sup> reported the first “bonnet bypass” from the contralateral STA to the ipsilateral MCA using a saphenous vein graft in a patient with CCA occlusion because of the unavailability of an ipsilateral donor artery. Several authors<sup>1,2)</sup> have developed an elongation technique for the contralateral STA to reach the proximal segment of the ipsilateral MCA with an RA interposition graft for the aggressive resection of cranial base tumors involving the CCA. On the other hand, the “bonnet bypass” is associated with additional complications caused by the long superficial trajectory, which increases the vulnerability of patients to head injuries, and scalp shifting can result in a massive subdural hematoma and obstruction of the donor artery.

Ausman et al.<sup>4)</sup> described the first reversed STA-MCA bypass surgery, wherein the proximal segment of the STA was anastomosed to a cortical branch of the MCA. Reconstituted flow of the ipsilateral STA via the contralateral STA collateral branches proved adequate to relieve the patient’s ischemic episodes. In addition, Aso et al.<sup>5)</sup> reported a patient with symptomatic CCA occlusion who underwent arterial bypass surgery using a spontaneously formed bonnet STA. In the present case, the patient underwent reverse STA-MCA single bypass using a naturally formed “bonnet” STA for a symptomatic CCA occlusion. We recommend that contralateral selective external angiography should be performed in such patients to confirm enough retrograde blood flow from the contralateral STA. Thereafter, if an adequately formed STA is demonstrated, then this unique anastomosis can be considered as a viable option for definitive treatment.

## Conflicts of Interest Disclosure

The authors have no personal, financial, or institutional interest in any of drugs, materials, or devices in the article. All authors who are members of The Japan Neurosurgical

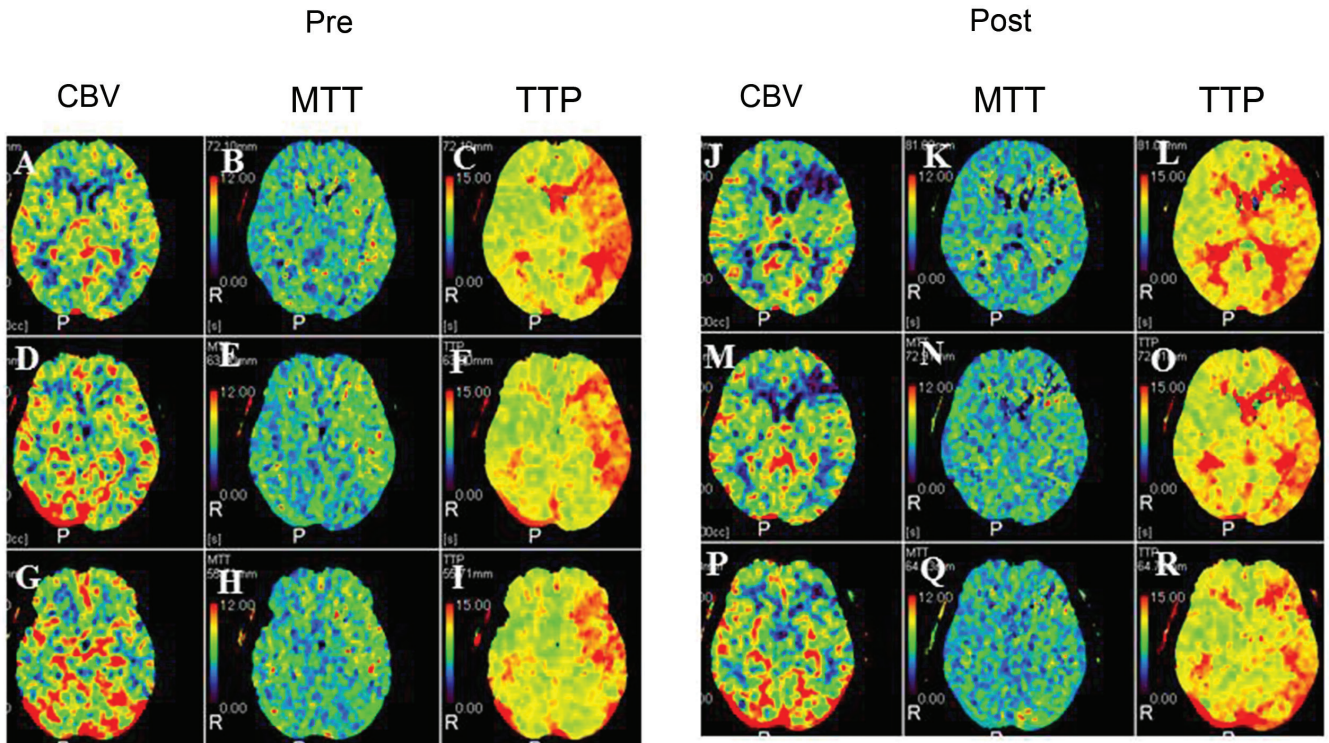


Fig. 2 A computed tomography (CT) perfusion study after removal of the thyroid tumor with common carotid occlusion showed an increase of cerebral vascular volume (CBV), and a prolongation of the mean transit time (MTT) and time to peak (TTP) in the extent frontal lobe and -left side (A–I). After reverse single bypass, postoperative CT perfusion showed a decrease of CBV, a normalization of MTT and TTP in the extent frontal lobe and -left side (J–R).

Society (JNS) have registered online Self-reported COI Disclosure Statement Forms through the website for JNS members.

## References

- 1) Deshmukh VR, Porter RW, Spetzler RF: Use of “bonnet” bypass with radial artery interposition graft in a patient with recurrent cranial base carcinoma: technical report of two cases and review of the literature. *Neurosurgery* 56(1 Suppl): E202; discussion E202, 2005
- 2) Sanada Y, Kamiyama H, Iwaisako K, Yoshimine T, Kato A: “Bonnet” bypass to proximal trunk of middle cerebral artery with a radial artery interposition graft: technical note. *Minim Invasive Neurosurg* 53: 203–206, 2010
- 3) Spetzler RF, Roski RA, Rhodes RS, Modic MT: The “bonnet bypass”. Case report. *J Neurosurg* 53: 707–709, 1980
- 4) Ausman JI, Tiel RL, Mehta BA, Fuentes JD, Pearce JE, Diaz FG: “Reverse” superficial temporal artery-middle cerebral artery bypass. *Surg Neurol* 23: 614–616, 1985
- 5) Aso K, Ogasawara K, Kobayashi M, Yoshida K: Arterial bypass surgery using a spontaneously formed “bonnet” superficial temporal artery in a patient with symptomatic common carotid artery occlusion: case report. *Neurosurgery* 67(3 Suppl Operative): onsE316–317, 2010

Address reprint requests to: Naoki Otani, MD, Department of Neurosurgery, National Defense Medical College, 3-2 Namiki, Tokorozawa, Saitama 359-8513, Japan.  
e-mail: naotani@ndmc.ac.jp