

# Scurvy in the Intensive Care Unit

Journal of Investigative Medicine High  
Impact Case Reports  
Volume 9: 1–3  
© 2021 American Federation for  
Medical Research  
DOI: 10.1177/23247096211067970  
journals.sagepub.com/home/hic



Amarah Baluch, MD<sup>1</sup>  and David Landsberg, MD<sup>2</sup> 

## Abstract

Scurvy, caused by vitamin C deficiency, is a forgotten disease in the modern era of medicine. The prevalence of vitamin C deficiency in the United States is reported to be 7.1%. We present a case of a 56-year-old man with a history of chronic alcohol use who was admitted to the intensive care unit due to sepsis. He was found to have a rash on his hands and feet which consisted of palpable lesions as well as petechiae. Work up of the patient's skin pathology revealed ascorbic acid deficiency, also known as scurvy. This case highlights the importance of considering severe nutritional deficiency in patients with underlying alcohol use who present with skin findings that may mimic those of a vasculitis. Although rare, vitamin C deficiency still exists, and it is important to be aware of presenting signs and identify those who are at risk.

## Keywords

dermatology, nutrition, other, pulmonary critical care

## Introduction

Vitamin C is a water-soluble vitamin that is required in the synthesis of collagen. The prevalence of vitamin C deficiency in the United States is reported to be 7.1%. The recommended dietary allowance is 90 mg per day in adult men and 75 mg per day in adult women.<sup>1</sup> When such dietary needs are not met acutely, the condition is known as scurvy. Symptoms can appear in as little as 1 month and can initially manifest as fatigue and generalized malaise; with time, collagen synthesis is affected leading to the characteristic petechiae, ecchymoses, and poor wound healing.<sup>1</sup> If left untreated, the condition can be fatal.

## Case Presentation

A 56-year-old man with a past medical history of type 2 diabetes mellitus, chronic obstructive pulmonary disease, obstructive sleep apnea, coronary artery disease, heart failure with preserved ejection fraction, tobacco abuse disorder, and alcohol use disorder presented to a tertiary center critical care unit with septic shock secondary to left lower extremity osteomyelitis. He was found unresponsive, and he was intubated to protect his airway. He was found in his apartment by his significant other. His significant other reported that the patient would drink about 5 beers daily on weekdays nearly every day, and about 5 to 10 on weekends. This had been ongoing for a few years but had increased over the last 3 months. She also noted he would mostly stay in and eat frozen meals and had been doing so for the last 3 months as well.

His blood cultures on presentation were positive for methicillin-sensitive *Staphylococcus aureus* and he was treated

with appropriate antibiotic coverage. Vascular surgery was also consulted for osteomyelitis who recommended no surgical intervention, and infectious diseases were also on board for antibiotic management. He was admitted to the intensive care unit for management of his septic shock and was managed with pressor support and antibiotic treatment.

Notably so, the patient was found to have a peculiar rash on presentation; he had a combination of petechiae and palpable hemorrhagic lesions, which resembled those of a vasculitis. This rash involved the dorsal surfaces of his hands and plantar surfaces of his feet. There was also involvement of his legs, lips, and gingiva. This rash was present prior to initiation of antibiotics and did not change with antibiotic treatment.

His complete blood count (CBC) on presentation showed a normal white blood cell count of 10.6  $\mu$ L (4.1–11.0  $\mu$ L); his hemoglobin was found to be slightly low at 8.7 g/dL (13.5–18.0 g/dL). His mean corpuscular volume (MCV) was also found to be near normal at 79.6 fL (80.0–95.0 fL). His platelet count was within normal parameters at 283  $\mu$ L (150–450  $\mu$ L). His complete metabolic panel on presentation was most consistent with an elevated creatinine of 1.42 mg/dL (0.80–1.30 mg/dL).

<sup>1</sup>Department of Medicine, SUNY Upstate Medical University, Syracuse, NY, USA

<sup>2</sup>Crouse Irving Memorial Hospital, Syracuse, NY, USA

Received October 30, 2021. Revised November 18, 2021. Accepted November 26, 2021.

## Corresponding Author:

Amarah Baluch, MD, Department of Medicine, SUNY Upstate Medical University, 750 E. Adams Street, Syracuse, NY 13210, USA.  
Email: amarahbaluch@hotmail.com



His coagulation factors were also within normal parameters. He was found to have both an elevated erythrocyte sedimentation rate (ESR) of 136 mm/h (0-20 mm/h) and C-reactive protein of 15.8 mg/dL (0.0-0.5 mg/dL).

Given the nature of his rash and his elevated inflammatory markers, an immunologic work up was pursued for a suspected vasculitis. An antinuclear antibody (ANA) was ordered which was negative, antineutrophil cytoplasmic antibody (ANCA) IgG was  $<1:20$  (ref range 1:20), Complement C3 was elevated at 205 mg/dL (90-180 mg/dL) and complement C4 was normal at 33 mg/dL (10-40 mg/dL). HIV and hepatitis panel were negative for active infection. His immunologic work up was not remarkable enough to fit a single unifying diagnosis for the findings of his skin.

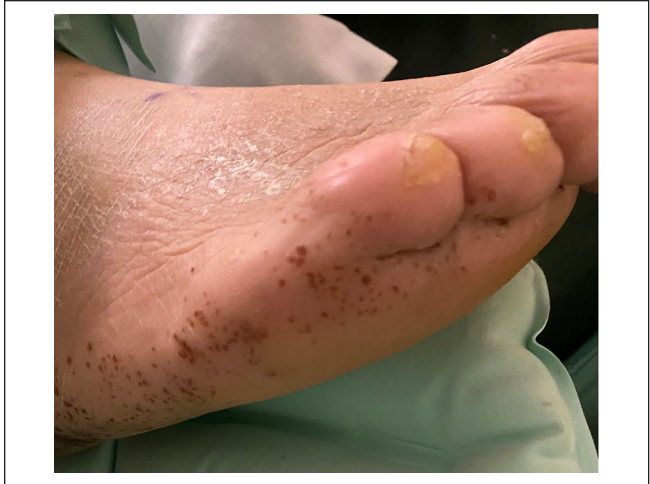The patient had a known history of significant alcohol use; as such, a nutritional deficiency was considered as the etiology of his rash. The patient's plasma vitamin C levels were drawn and he was empirically started on 500 mg IV vitamin C daily. His plasma vitamin C levels returned as significantly low at 10  $\mu\text{mol/L}$  (23-114  $\mu\text{mol/L}$  reference range), confirming a diagnosis of ascorbic acid deficiency, also known as scurvy. Several days into treatment his skin findings started to show signs of improvement. Interestingly so, his mentation also improved, though this improvement was likely multifactorial with treatment of his underlying sepsis. Appropriate treatment of sepsis also resulted in resolution of his inflammatory markers and elevated creatinine.

## Discussion

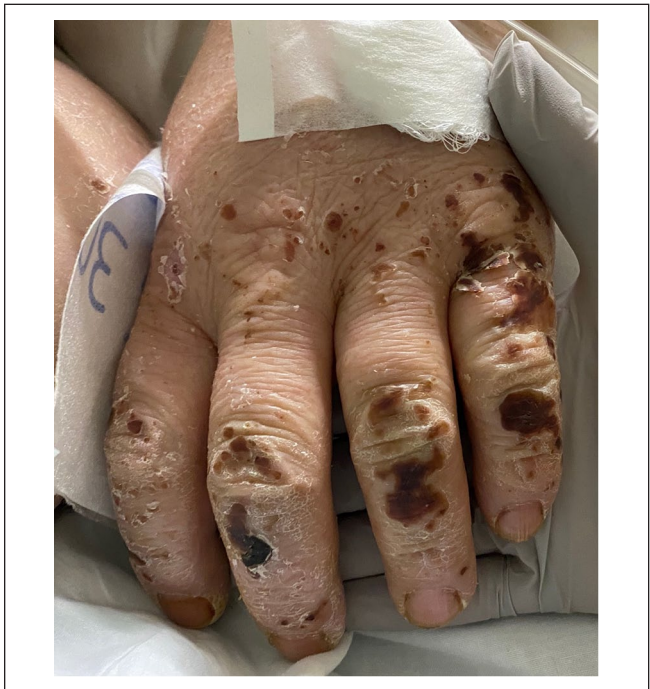Vitamin C is essential for collagen synthesis and is used as a cofactor in the hydroxylation process during synthesis of collagen. The disruption of this process is what is responsible for the presenting signs and symptoms of scurvy. The absence of this hydroxylation renders collagen unstable and results in blood vessel fragility as well as impaired wound healing.<sup>1,2</sup>

Vitamin C deficiency rates vary across the world, but the prevalence in the United States is reported to be 7.1%.<sup>3</sup> Scurvy occurs either due to decreased intake or impaired absorption of vitamin C. For this disease to manifest, an individual must entirely eliminate vitamin C from their diet for 2 to 3 months.<sup>2</sup> Symptoms of scurvy occur when the plasma concentration of ascorbic acid is less than 0.2 mg/dL (11  $\mu\text{mol/L}$ ).<sup>4</sup> In our patient, the plasma vitamin C level was 10  $\mu\text{mol/L}$ . This was prior to treatment with high-dose vitamin C, but after tube feeds were started (the formula for which contained vitamin C), and so the true value is expected to have been even lower than 10  $\mu\text{mol/L}$ .

The most common manifestations of scurvy are petechiae (present in our patient as seen in Figure 1), ecchymoses, hyperkeratosis (present in our patient), perifollicular hemorrhage, gingival hemorrhage, and classically, corkscrew hairs.<sup>5</sup> The petechiae confluence into large ecchymoses or palpable purpura due to blood vessel fragility, as seen in our patient (Figure 2).<sup>2</sup> Other symptoms include joint pain,



**Figure 1.** Petechiae on the plantar surface of the feet.



**Figure 2.** Palpable lesions on the dorsum of the hand.

myalgias, and dry skin. In rare cases, patient may have vasomotor instability leading to death.<sup>3</sup>

The diagnosis is primarily clinical but is confirmed with serum vitamin C levels less than 11  $\mu\text{mol/L}$ .<sup>5</sup> Treatment is increased vitamin C intake with a suggested dose of 100 mg 3 times daily; in our patient, we elected to treat with 500 mg daily.<sup>2</sup> There is typically rapid resolution of the fatigue and pain (within hours); the skin findings tend to improve over 2 to 4 weeks with complete recovery after 3 months of treatment.<sup>2</sup>

Humans cannot synthesize vitamin C and so they must obtain their intake via diet or supplements.<sup>6</sup> The recommended dietary intake of vitamin C per the Food and Drug Administration

is 90 mg per day in men, and 75 mg per day in women.<sup>1,6</sup> For reference, a single orange contains 50 mg of vitamin C.<sup>2</sup>

## Conclusions

Nutritional deficiencies are very rarely on the differential when considering skin pathologies of unknown etiology. This case reflects why it is important to consider a vitamin C deficiency, especially in patients with alcohol use disorder. The clinical suspicion for such a deficiency is often extremely low given the rarity of vitamin C deficiency in developed countries. Such may not be the case in patients with impaired absorption of vitamin C. Other patients in whom the risk of vitamin C deficiency is higher include those with gastrointestinal diseases, patients with a history of bariatric surgery, patients receiving chemotherapy, and the elderly population.<sup>6</sup> Patients with end stage renal disease (ESRD) are also at risk due to losses during hemodialysis.<sup>2</sup> It is therefore important to consider vitamin C deficiency in high-risk groups as it is very easily treated.

## Declaration of Conflicting Interests

The author(s) declared no potential conflicts of interest with respect to the research, authorship, and/or publication of this article.

## Funding

The author(s) received no financial support for the research, authorship, and/or publication of this article.

## Ethics Approval


Our institution does not require ethical approval for reporting individual cases or case series.

## Informed Consent

Written informed consent was obtained from the patient(s) for their anonymized information to be published in this article.

## ORCID iDs

Amarah Baluch  <https://orcid.org/0000-0003-4337-1277>

David Landsberg  <https://orcid.org/0000-0002-4838-9057>

## References

1. National Institutes of Health Office of Dietary Supplements. Vitamin C. <https://ods.od.nih.gov/factsheets/VitaminC-HealthProfessional/>. Published 2021. Accessed October 12, 2021.
2. Olmedo JM, Yiannias JA, Windgassen EB, Gornet MK. Scurvy: a disease almost forgotten. *Int J Dermatol*. 2006;45:909-913.
3. Callus CA, Vella S, Ferry P. Scurvy is back. *Nutr Metab Insights*. 2018;11:1-2.
4. Pazirandeh S, Burns DL. Overview of water soluble vitamins. In: Kunins L, ed. *Uptodate*; 2020. Wolters Kluwer.
5. Elfeki MA, Scheiwsow T, Jawa Z. Scurvy: old, but still relevant. *Cleve Clin J Med*. 2020;87:478-479.
6. Levavasseur M, Becquart C, Pape E, et al. Severe scurvy: an underestimated disease. *Eur J Clin Nutr*. 2015;69(9):1076-1077.