

Totally percutaneous endovascular repair of HeartMate 3 ventricular assistive device outflow graft pseudoaneurysm

Mark D. Balceniuk, MD, MPH,^a Daniel Ziazadeh, MD, MSc,^b Doran S. Mix, MD,^a Sunil Prasad, MD,^b and Michael C. Stoner, MD,^a Rochester, NY

ABSTRACT

The rate of heart failure and subsequent placement of left ventricular assistive devices (LVADs) has been increasing. The extra-anatomic placement of the LVAD and outflow graft presents a challenging problem for repair when complications arise. The present report describes a case of a 63-year-old man who had presented with acute pseudoaneurysm of the outflow graft of his recently placed LVAD. Percutaneous access of the left subclavian artery and percutaneous, transthoracic access of the outflow graft was obtained to allow for sheath placement and stent deployment within the outflow graft. The patient underwent successful endovascular repair of the defect without complications. (*J Vasc Surg Cases and Innovative Techniques* 2020;6:505-8.)

Keywords: Endovascular; HeartMate 3; LVAD; Perforation; Stenting

A dramatic increase has occurred in the rate of the use of durable mechanical support and left ventricular assistive devices (LVADs) for end-stage heart failure during the past decade, with ~2000 devices placed annually.¹ This increase in the use of circulatory support has also been accompanied by an increase in expected and unexpected complications.² Because of the nature of the compromised physiology and altered anatomy, the repair of these complications can be challenging, especially in the setting of a hostile mediastinum. The purpose of the present report was to describe the totally percutaneous repair of a pseudoaneurysm of a LVAD outflow graft. The present patient provided written informed consent for the report of his case.

CASE REPORT

A 63-year-old man with a history of chronic kidney disease, hypertension, hyperlipidemia, and heart failure after multiple previous LVAD placements (HeartMate II [Abbott Laboratories, Chicago, Ill] placed in March 2017 and subsequently exchanged to the HeartMate 3 in January 2020 because of persistent ventricular tachycardia due to a malpositioned inflow cannula) had presented urgently to the hospital with acute-onset

substernal chest pain, hypotension, and a rapidly increasing subcutaneous fluid collection after working with physical therapy earlier in the day (Fig 1). A computed tomography angiography scan of the chest and abdomen demonstrated a focal defect and pseudoaneurysm (PSA) of the outflow graft at the level of the subxiphoid region with an expanding hematoma extending to the anterior abdominal and chest wall (Fig 2). The patient was hemodynamically stable and mentating appropriately, with no signs of end-organ malperfusion. Owing to the concern for exsanguination with an open repair in the setting of multiple previous sternotomies, we decided to pursue an endovascular approach for the repair of the outflow graft defect.

The patient was intubated in a supine position in the vascular surgery hybrid operating suite with cardiopulmonary bypass on standby should conversion to an open procedure be necessary. Percutaneous access of the left subclavian artery with a micropuncture needle was obtained. This access was upsized to a 7F sheath, and a ProGlide (Abbott Laboratories) closure device was placed to close the arteriotomy at the end of the case, which is our standard technique. Using ultrasound guidance, we then used a micropuncture system to access the outflow graft directly through a percutaneous, right-sided transthoracic approach at approximately the fourth intercostal space to the right of the sternum. The needle and wire were passed in an antegrade direction within the outflow graft (Fig 3).

From the left-sided subclavian access site, we used a snare to exteriorize the conduit wire in a flossing-wire technique (Fig 4 A). This wire was pulled tight, and we were then able to advance a 12F Gore DrySeal Introducer Sheath (WL Gore and Associates, Flagstaff, Ariz) through the subclavian artery access site into the conduit up to the level of the right transthoracic outflow graft access site. Using a modified buddy wire technique, a separate J-tip Amplatz wire (Cook Medical, Bloomington, Ind) was passed beyond the known outflow graft defect just into the orifice of the HeartMate 3 pump housing, with care taken not to impact the magnetically levitated pump rotor.^{3,4} Fluoroscopy

From the Division of Vascular Surgery,^a and Division of Cardiac Surgery,^b University of Rochester Medical Center.

Author conflict of interest: none.

Correspondence: Michael C. Stoner, MD, Division of Vascular Surgery, Department of Surgery, University of Rochester Medical Center, 601 Elmwood Ave, Box 652, Rochester, NY 14642 (e-mail: michael_stoner@urmc.rochester.edu).

The editors and reviewers of this article have no relevant financial relationships to disclose per the Journal policy that requires reviewers to decline review of any manuscript for which they may have a conflict of interest.

2468-4287

© 2020 The Authors. Published by Elsevier Inc. on behalf of Society for Vascular Surgery. This is an open access article under the CC BY-NC-ND license (<http://creativecommons.org/licenses/by-nc-nd/4.0/>).

<https://doi.org/10.1016/j.jvscit.2020.09.001>

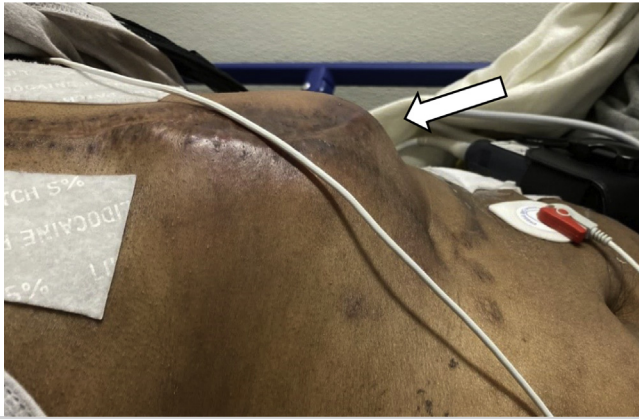


Fig 1. Enlarging subcutaneous fluid collection, concerning for hematoma (arrow).

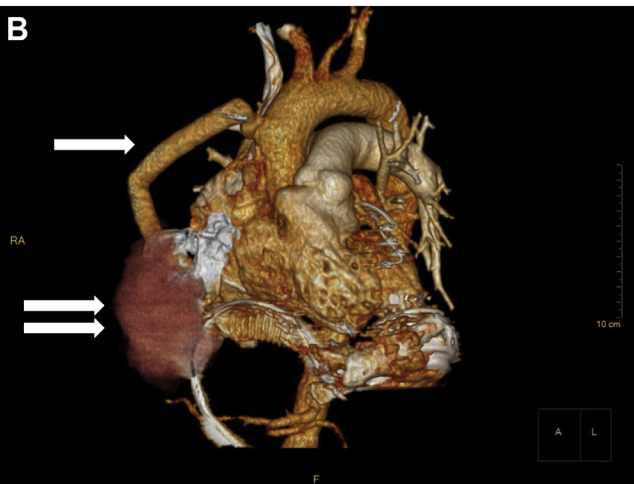
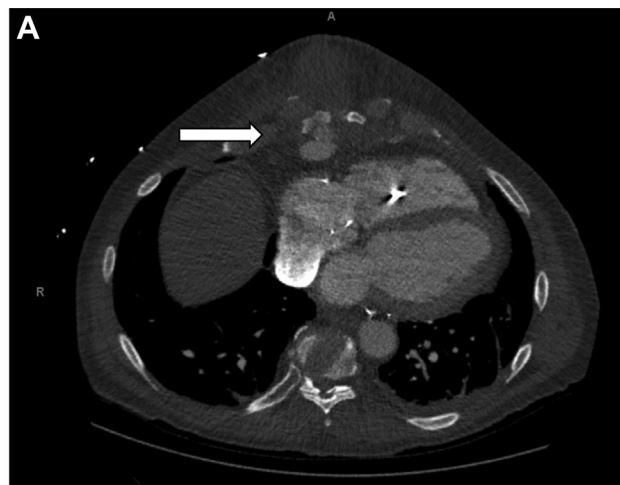

Fig 2. A, Axial view of outflow graft pseudoaneurysm (arrow). **B,** Three-dimensional reconstruction of outflow graft (single arrow) and pseudoaneurysm (double arrows).

was used to precisely place the wire in the graft just before the pump rotor (Fig 4 B). Placement of the wire into the rotor pump would have been disastrous, causing potential damage to, and

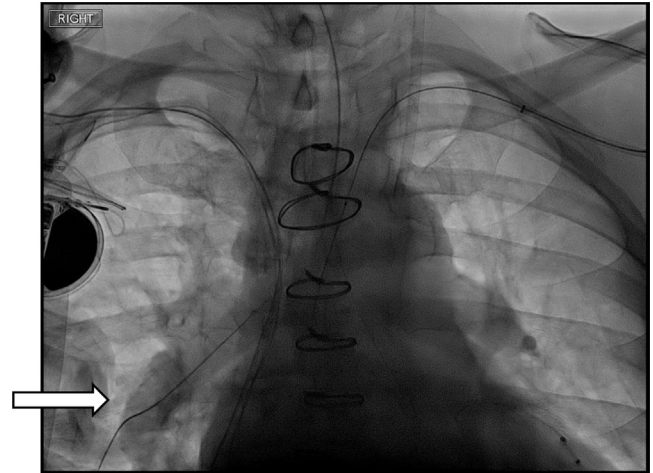


Fig 3. Fluoroscopic image demonstrating retrograde subclavian access and antegrade access through outflow graft (white arrow).

embolization of, pieces of the wire and damage and stopping of the pump, which would have caused sudden cardiac failure and the need for emergent cardiopulmonary bypass.

The uniform inner diameter of the LVAD outflow graft is 14 mm; therefore, we delivered a 16- × 13.5-mm Gore Excluder (WL Gore and Associates) iliac limb without difficulty, bridging across the outflow graft defect that had been identified on a computed tomography angiography scan (Fig 4 C). To control the right-sided transthoracic access site, a second 16- × 13.5-mm Gore Excluder iliac limb (WL Gore and Associates) was aligned and deployed, with 1 cm overlapping the terminal end to the previous limb (Fig 4 D). This adequately controlled the access site in the right chest wall.

Completion digital subtraction angiography was performed and demonstrated successful exclusion of the LVAD outflow graft defect with no extravasation of contrast (Fig 5). The wires, catheters, and sheaths were withdrawn in standard fashion, and the left-sided subclavian artery access site was controlled with the ProGlide device (Abbott Laboratories). A completion digital subtraction angiography of the access site also showed no evidence of hemorrhage or occlusive complications. A decision was made by the surgical and anesthesia team to keep the patient intubated overnight for closer observation and monitoring in the cardiac intensive care unit. The next day, the patient underwent washout of the hematoma, debridement of the sternum, and closure of the chest with the cardiac surgery team. The sternum was debrided to minimize any further stress on the outflow graft. He was discharged home on postoperative day 8. He was subsequently evaluated in the outpatient clinic 1 month after discharge with no adverse sequelae from the endovascular repair. The patient was alive with no complications and no concerns for infection from his repair 6 months later.

DISCUSSION

Anatomic complications of LVADs are rare, with PSAs among the most often reported.^{5,6} Classically, these

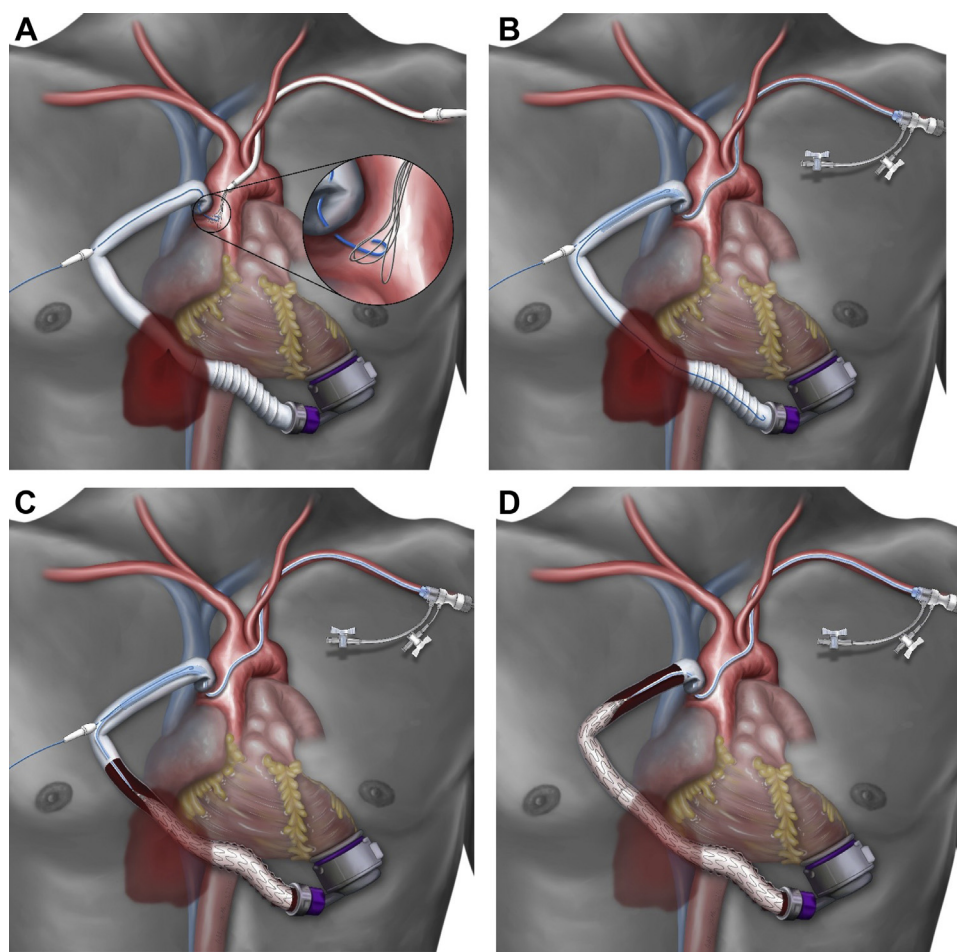


Fig 4. Steps in endovascular repair of left ventricular assistive device (LVAD) outflow graft. **A**, Snaring of the antegrade wire through the outflow graft. **B**, Guiding of retrograde sheath into the outflow graft using modified buddy wire. **C**, Deployment of the first iliac limb to cover the graft defect. **D**, Deployment of the second iliac limb to cover the outflow graft access site.

complications have been repaired through an open approach with repeat sternotomy and selective cardiopulmonary bypass.⁵ However, studies have demonstrated endovascular repair of outflow graft complications. Ganapathi et al⁷ demonstrated endovascular repair with a covered stent of a graft PSA. In that case, they performed a cut down of the left axillary artery and had had to turn off the LVAD to cannulate the graft. In another report, Dhesei et al⁸ described angioplasty and stenting of an outflow graft kink using a left axillary cut down approach.

When discussing operative intervention for the present patient between the cardiac and vascular surgery teams, the hypothesized etiology for the PSA of the outflow graft was shear stress of the outflow graft against the inferior aspect of the xiphoid bone as it tunneled into the mediastinum. This thinking resulted from the proximity of the PSA to the xiphoid. We had had multiple concerns with open surgical repair. First, in the setting of multiple redo sternotomies, the mediastinum would

have proved hostile and dissection very difficult. Second, an incision to access the outflow graft defect would have required traversing the anterior abdominal and chest wall hematoma, which was tamponading and controlling the hemorrhage and could have resulted in exsanguination. Finally, placing our patient on peripheral cardiopulmonary bypass would have been challenging because cannulation of either an axillary or a femoral artery would have led to flow reversal down the LVAD outflow graft and continued to bleed through the defect and, potentially, cause left ventricular distention. As such, an initial attempt at endovascular management was pursued.

We have described a totally percutaneous endovascular approach using a modified buddy wire system to exclude a defect in the LVAD outflow graft, without having to turn off the durable mechanical support. This technique allowed for precise placement and deployment of the iliac excluder limb within the outflow graft. The buddy wire technique also provided a stronger and

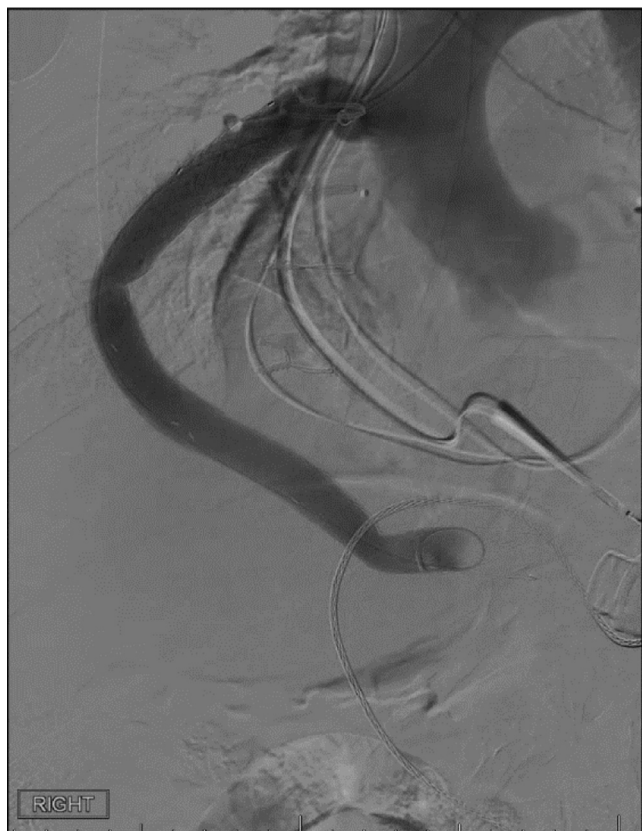

Fig 5. Completion angiogram demonstrating graft repair without complications.

more stable platform that allowed us to overcome kinking of the outflow graft just proximal to its anastomosis to the ascending aorta on the computed tomography scan (Fig 2 B). We were able to safely cannulate the outflow graft and carry our guidewire to the level of the HeartMate 3 pump housing (Abbott Laboratories), without disruption to the anastomosis or damage to the magnetically levitated rotor, while excluding the PSA. Similar to previous case reports, we selected the 16-mm diameter iliac excluder limb because it provides acceptable oversizing of the 14-mm-diameter HeartMate 3 Dacron outflow graft (Abbott Laboratories).

CONCLUSION

The presented case is the first report, to the best of our knowledge, of a totally percutaneous approach to endovascular repair of a HeartMate 3 (Abbott Laboratories) outflow graft PSA, while maintaining operation of the LVAD pump throughout the case. The findings from the present report serve to demonstrate the safety and feasibility of a modified buddy wire technique for safe deliverance of the Gore DrySeal Sheath and Gore iliac excluder limb (WL Gore Associates) and accomplish an endovascular repair of a HeartMate 3 (Abbott Laboratories) LVAD outflow graft defect.

REFERENCES

1. Feldman D, Pamboukian SV, Teuteberg JJ, Birks E, Lietz K, Moore SA, et al. The 2013 International Society for Heart and Lung Transplantation Guidelines for mechanical circulatory support: executive summary. *J Heart Lung Transpl* 2013;32:157-87.
2. Salerno CT, Sundareswaran KS, Schleeter TP, Moanie SL, Farrar DJ, Walsh MN. Early elevations in pump power with the HeartMate II left ventricular assist device do not predict late adverse events. *J Heart Lung Transpl* 2014;33:809-15.
3. Mitomo S, Demir OM, Latib A, Colombo A. Buddy-wire technique during rotational atherectomy: simple and effective solution to achieve strong back-up support. *Catheter Cardiovasc Interv* 2019;93:436-9.
4. Vijayvergiya R, Swamy A, Grover A. Buddy wire technique: a simple technique for treating calcified lesion during percutaneous coronary intervention: a case report. *J Invasive Cardiol* 2006;18:E129-30.
5. Knosalla C, Weng Y, Buz S, Loebe M, Hetzer R. Pseudoaneurysm of the outflow graft in a patient with Novacor N100 LVAD system. *Ann Thorac Surg* 2000;69:1594-6.
6. Maeda T, Tanoue Y, Nakashima A, Tominaga R. Atypical presentation of an apical pseudoaneurysm in a patient on prolonged left ventricular mechanical support. *Interact Cardiovasc Thorac Surg* 2010;10:350-1.
7. Ganapathi AM, Andersen ND, Prastein DJ, Hashmi ZA, Rogers JG, Milano CA, et al. Endovascular stent grafting of a left ventricular assist device outflow graft pseudoaneurysm. *Circ Heart Fail* 2013;6:e16-8.
8. Dhesi P, Sadiq I, Gluck J. Endovascular repair of a HeartMate II left ventricular assist device. *J Heart Lung Transpl* 2014;33:1198-9.

Submitted Jul 21, 2020; accepted Sep 5, 2020.