

# Metachronous Ovarian Metastases in a Patient with Primary Colorectal Cancer. A Case Report and Review of the Literature

Authors' Contribution:  
Study Design A  
Data Collection B  
Statistical Analysis C  
Data Interpretation D  
Manuscript Preparation E  
Literature Search F  
Funds Collection G

AG 1 **Daniel Paramythiotis**  
BCDEFG 1 **Patroklos Goulas**  
ABDEFG 1 **Moysis Moysidis**  
EF 1 **Anestis Karakatsanis**  
BDG 2 **Valentini Tzioufa-Asimakopoulou**  
D 3 **Sotiris Sotiriou**  
AG 1 **Antonios Michalopoulos**

1 First Propaedeutic Surgery Department, AHEPA University Hospital of Thessaloniki, Thessaloniki, Greece  
2 Department of Pathology, Medical School, Aristotle University of Thessaloniki, Thessaloniki, Greece  
3 Center for Individualized Medicine, Mayo Clinic Minnesota, Rochester, MN, USA

**Corresponding Author:** Moysis Moysidis, e-mail: [moysisdoc@gmail.com](mailto:moysisdoc@gmail.com)  
**Conflict of interest:** None declared

**Patient:** Female, 66  
**Final Diagnosis:** Metachronous ovarian metastasis  
**Symptoms:** No symptoms  
**Medication:** —  
**Clinical Procedure:** —  
**Specialty:** Surgery

**Objective:** Unusual clinical course





**Background:** Metachronous ovarian metastasis from primary colorectal cancer (CRC) is a rare condition that is diagnosed after the treatment of CRC. In most cases, ovarian metastases present without specific symptoms or signs and are usually diagnosed during follow-up imaging. A rare case is presented of metachronous ovarian metastasis from primary CRC, diagnosed on follow-up by computed tomography (CT) and magnetic resonance imaging (MRI), and includes a review of the literature.

**Case Report:** A 66-year-old woman recently underwent a left hemicolectomy for a stage T3, N0, M0 primary adenocarcinoma of the sigmoid colon, which was completely excised. Three years later, follow-up CT and MRI imaging showed a right ovarian cyst. She underwent exploratory laparotomy and bilateral salpingo-oophorectomy, which identified tumor in the right ovary. Histopathology and immunohistochemistry confirmed metachronous ovarian metastasis from CRC. The patient was referred for further treatment.

**Conclusions:** Newly-diagnosed ovarian metastasis from primary colorectal cancer (CRC) is challenging to diagnose and manage, and may initially be incorrectly diagnosed as malignancy of primary ovarian origin. This case demonstrated that it is important to confirm the diagnosis with imaging, histology, and the appropriate use of tumor markers. Because ovarian metastases do not respond favorably to chemotherapy, the treatment of choice is surgery. However, for women who are treated for CRC, the use of prophylactic oophorectomy remains controversial.

**MeSH Keywords:** Colorectal Neoplasms • Krukenberg Tumor • Neoplasm Metastasis • Ovariectomy

**Full-text PDF:** <https://www.amjcaserep.com/abstract/index/idArt/917957>

 1851   4  26



## Background

Worldwide, colorectal cancer (CRC) is the third most commonly diagnosed malignancy and the fourth leading cause of cancer mortality [1]. At the time of diagnosis, about 20% of patients with CRC have already developed metastatic disease, with the liver, lungs, bones, and brain being the most affected organs [2,3]. Less frequent metastatic sites include intraabdominal organs (pancreas, spleen, kidneys or ovaries) and non-abdominal organs (thyroid or breast).

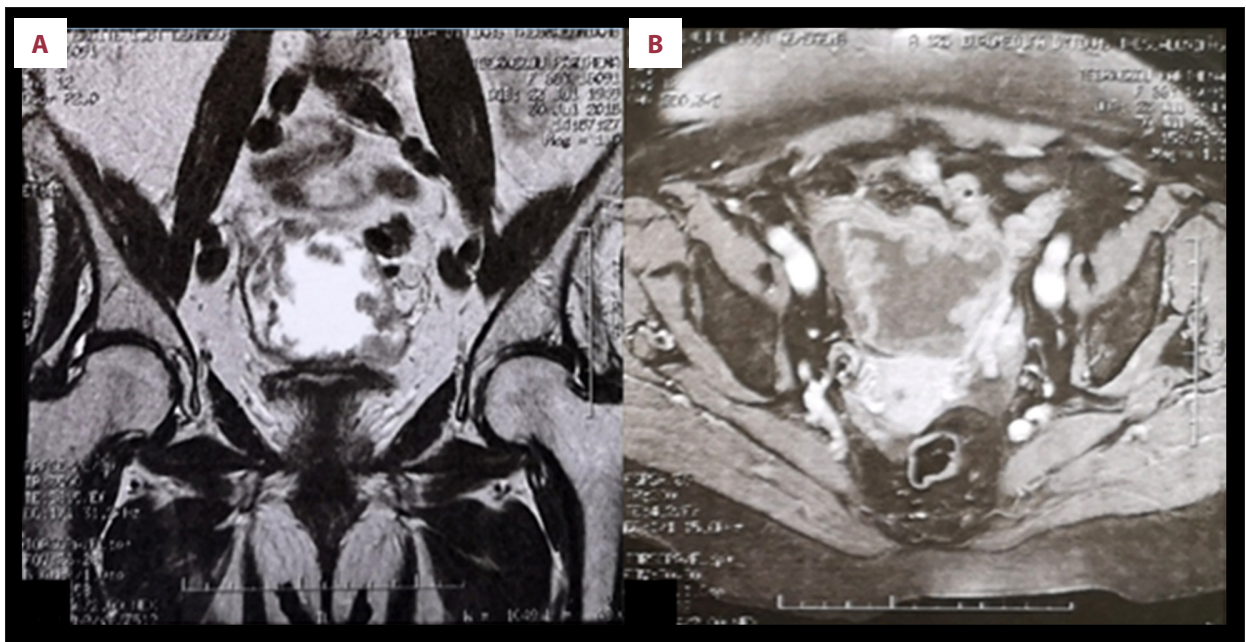
Between 15–20% of all malignant ovarian tumors are metastatic, with the most common primary tumor sites reported to be the large intestine, the breast, the uterine corpus, the uterine cervix, and the stomach [4]. Metastases originating from primary gastrointestinal tumors are also known as Krukenberg tumors, named after Friedrich Ernst Krukenberg (1871–1946) who described five cases of in 1896 while he was a student in Germany [5,6].

Ovarian metastases usually present with pain and abdominal distention, which are attributed either to ascites or to the abdominal mass. In most cases, ovarian metastases present without specific symptoms or signs and are usually diagnosed during follow-up imaging [4]. A rare case is presented of metachronous ovarian metastasis from primary CRC, diagnosed on follow-up by computed tomography (CT) and magnetic resonance imaging (MRI), and includes a review of the literature.

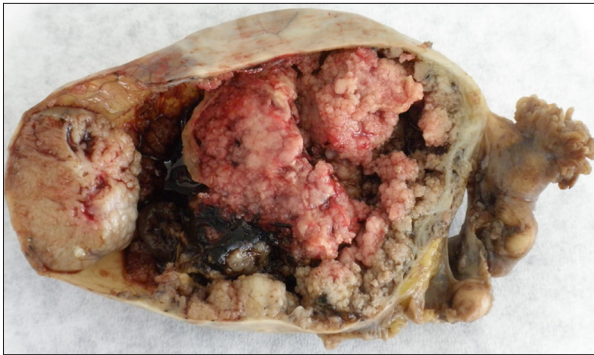## Case Report

A 66-year-old woman was admitted to our department with a diagnosis of a cystic lesion in her right ovary, which was identified at follow-up computed tomography (CT) scan, three years following a left hemicolectomy for adenocarcinoma of the sigmoid colon. Magnetic resonance imaging (MRI) of the pelvis (Figure 1A, 1B) was performed to characterize the mass further, and showed an 8.6×5.6 cm cystic tumor of the right ovary. The tumor had clear margins, and there was no invasion into the uterus or bladder. The patient was asymptomatic, and there were no significant findings at previous routine follow-up visits, and no tumor recurrence or metastatic disease had previously been identified.

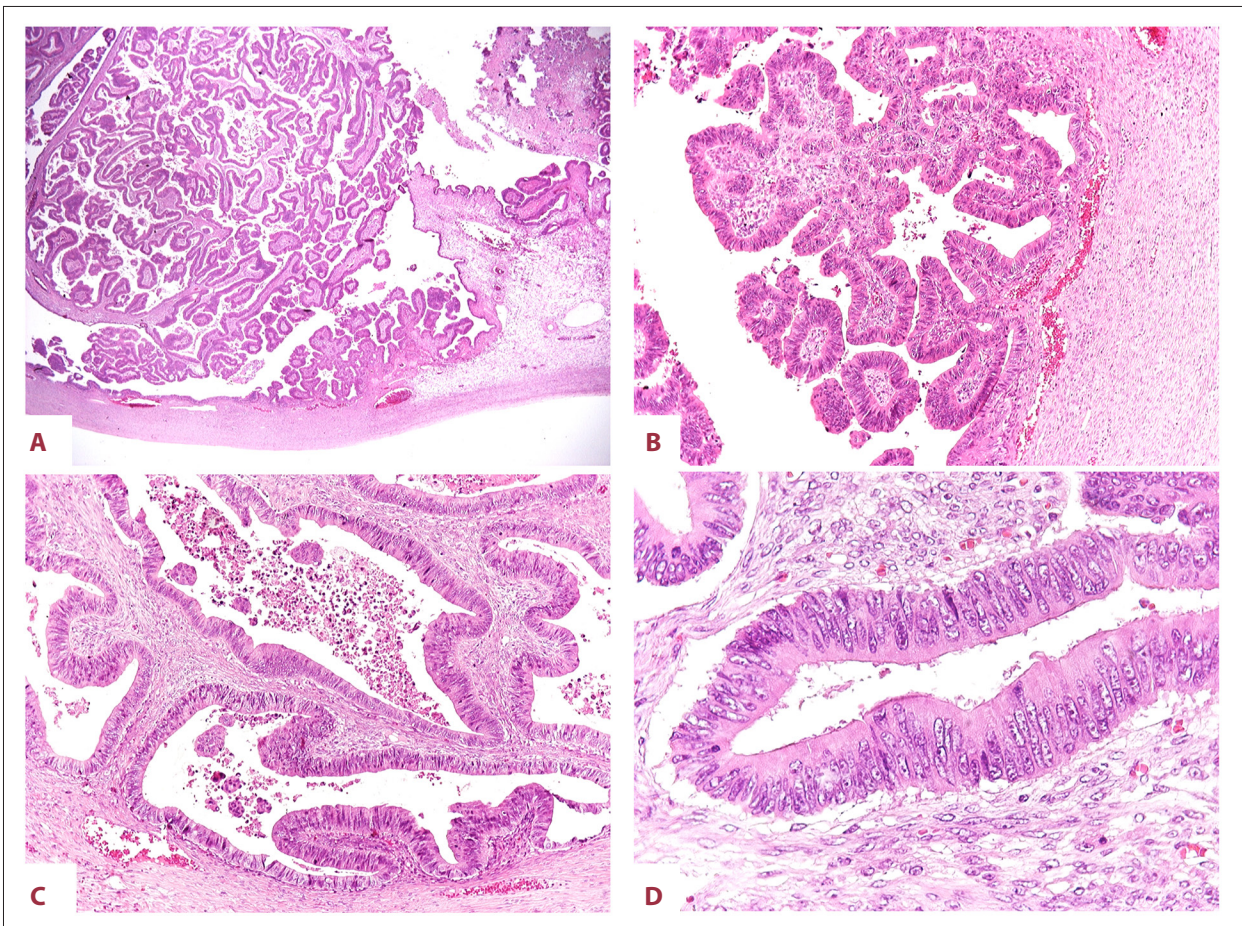
On this admission, her blood tests were normal, with serum carcinoembryonic antigen (CEA) level of 3.74 ng/ml (normal, <3.3 ng/ml), and a serum CA-125 of 27.87  $\mu$ /ml (normal range, 0–35  $\mu$ /ml). Clinical examination of the cardiovascular and respiratory systems was normal. Three years previously, she underwent a left hemicolectomy for adenocarcinoma of the sigmoid colon, and the diagnosis was confirmed with histopathology, and the tumor was staged as a pT3, N0, M0 adenocarcinoma. After the case was discussed at the multidisciplinary team meeting, no adjuvant therapy was given to the patient at that time.



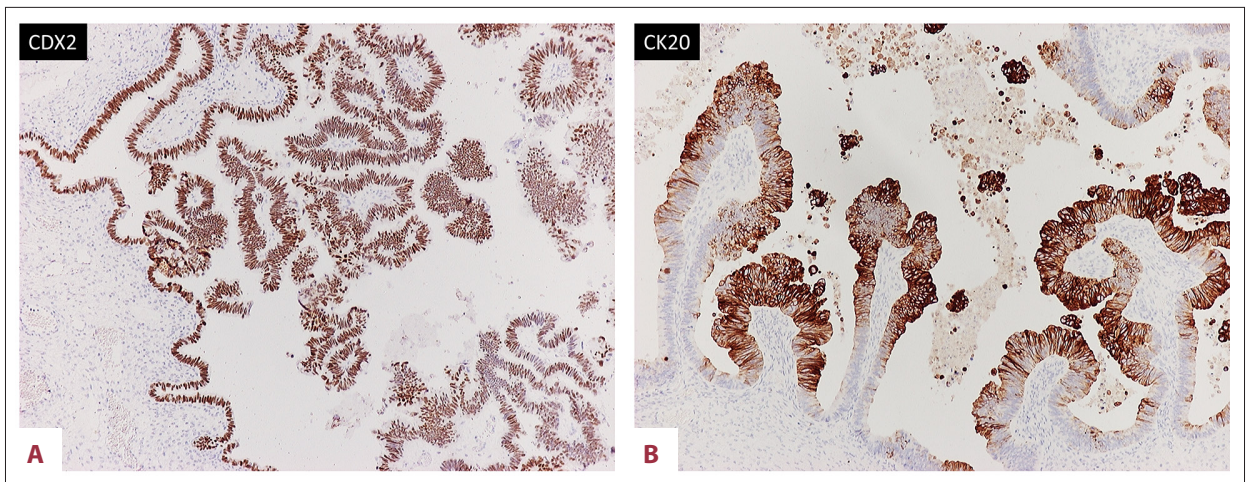
**Figure 1.** Magnetic resonance imaging (MRI) in a 66-year-old woman with metachronous ovarian metastases diagnosed three years after left hemicolectomy for colorectal carcinoma (CRC). (A) T2-weighted magnetic resonance imaging (MRI) sequence, coronal view. (B) T1-weighted MRI sequence, axial view. A cystic mass is shown in the right ovary measuring 8.6×5.6 cm, with irregular thickening of the cyst wall. The mass is anterior to the uterus, and has clear margins with no invasion of the surrounding tissues.



**Figure 2.** Macroscopic appearance of the ovary following salpingo-oophorectomy in a 66-year-old woman with metachronous ovarian metastases diagnosed three years after left hemicolectomy for colorectal carcinoma (CRC). The macroscopic appearance of the ovarian tumor shows cystic and solid areas that have a mainly papillary architecture with foci of hemorrhage.



**Figure 3.** Photomicrographs of the histopathology of the ovarian tumor in a 66-year-old woman with metachronous ovarian metastases diagnosed three years after left hemicolectomy for colorectal carcinoma (CRC). (A) Low power photomicrograph of the ovarian tumor tissue shows solid areas consisting mainly of papillary structures and few glands that are covered by a layer of malignant epithelial cells. Hematoxylin and eosin (H&E). Magnification  $\times 20$ . (B) Photomicrograph of the ovarian tumor shows glands filled with necrotic debris. The malignant cells are columnar with eosinophilic cytoplasm and atypical nuclei and nucleoli. H&E. Magnification  $\times 100$ . (C) Photomicrograph of the ovarian tumor shows glands filled with necrotic debris. The malignant cells are columnar with eosinophilic cytoplasm and atypical nuclei and nucleoli. H&E. Magnification  $\times 100$ . (D) High power photomicrograph shows columnar malignant cells with eosinophilic cytoplasm and atypical nuclei and nucleoli, H&E. Magnification  $\times 400$ .



**Figure 4.** Photomicrographs of the immunohistochemistry for CDX2 and cytokeratin 20 of the ovarian tumor in a 66-year-old woman with metachronous ovarian metastases diagnosed three years after left hemicolectomy for colorectal carcinoma (CRC). (A) Photomicrograph of the immunohistochemical staining for CDX2 shows positive (brown) tumor cells. Immunoperoxidase counterstained with hematoxylin. Magnification  $\times 100$ . (B) Photomicrograph of the immunohistochemical staining for cytokeratin 20 shows positive (brown) staining. Immunoperoxidase counterstained with hematoxylin. Magnification  $\times 100$ .

On the current admission, the patient underwent an exploratory laparotomy through a midline incision. A cystic lesion of the right ovary was found intra-operatively with macroscopic characteristics consistent with malignancy. Total hysterectomy and bilateral salpingo-oophorectomy were performed, and no residual tumor was found within the abdominal cavity. The macroscopic appearance of the tumor showed cystic, solid, and papillary areas with foci of hemorrhage (Figure 2). The histology showed a mainly papillary tumor with few glands that were covered by a layer of neoplastic epithelial cells (Figure 3A, 3B). The glands within the tumor contained necrotic debris (Figure 3C). The neoplastic cells were columnar with eosinophilic cytoplasm, atypical nuclei and nucleoli (Figure 3D). The mitotic index was high. Immunohistochemistry showed that the malignant cells were positive for CDX2 (Figure 4A) and cytokeratin 20 (CK20) (Figure 4B), and negative for cytokeratin 7 (CK7), estrogen receptor (ER), and progesterone receptor (PR), which supported the origin of the tumor in the right ovary from the colon. The patient recovered well, and the postoperative course was uneventful. She was further referred to the oncology department, and adjuvant treatment was commenced.

## Discussion

Metachronous metastasis is defined as occurring more than three months after the diagnosis of malignancy at another site. This report is of a rare case of metachronous ovarian metastasis from a primary colorectal carcinoma (CRC), or Krukenberg tumor, in a 66-year-old woman, diagnosed three years after surgical resection. The ovarian tumor was diagnosed at

follow-up by computed tomography (CT) and magnetic resonance imaging (MRI). Previous studies from single centers have reported the incidence of synchronous ovarian metastases in 0–9% of women with colorectal cancer (CRC), and metachronous ovarian metastasis in 0.9–7% [4,9,10]. A Swedish population-based study estimated the incidence of metachronous ovarian metastasis as 0.8% in women treated for CRC [11]. Metachronous ovarian metastases were identified at a median of 16 months after resection of the primary tumor [11]. This previous study also showed that there was a significant difference between the incidence of metachronous ovarian metastases in women with primary adenocarcinoma of the colon (1.1%) compared with women with primary adenocarcinoma of the rectum (0.1%) ( $P < 0.001$ ) [11]. Adenocarcinoma of the rectum was less likely to present with metastases, as the diagnosis was usually made at an early stage, and was more likely to be treated with radiotherapy, which prevents micrometastases [11]. Also, radiotherapy may induce ovarian atrophy and impair the ovarian blood supply, which reduces the risk of hematogenous tumor spread to the ovaries [11]. Also, in this previous study, women with metachronous ovarian metastases were younger than women who did not develop metastatic disease, indicating that reduced hematogenous spread may occur in older women with ovarian atrophy [11].

In a study by Ojo et al., the incidence of metachronous ovarian metastases from CRC was similar was 0.76%, with the diagnosis made at a median of 23.5 months after the primary tumor diagnosis [12]. In 75% of the cases of metachronous ovarian metastasis, the primary tumor was located in the proximal colon [12]. Unlike the case described in this report, none of the patients with metachronous tumors had isolated

ovarian metastases at the time of presentation, and they were younger, with a median age of 49 years [12]. Tan et al. reported the incidence of metachronous ovarian metastases from CRC as 0.4%, with the diagnosis made at a median of 15 months after the primary diagnosis of CRC [13]. Bilateral ovarian metastatic disease, synchronous or metachronous, was more common, while 44% of patients had only unilateral ovarian involvement [13]. Further studies have confirmed the low incidence of metachronous ovarian metastases originating from CRC, and the higher prevalence of ovarian metastases from CRC in women of younger age [4,5,14–18].

The routes of metastatic spread of CRC may include hematogenous, lymphatic, direct, and transperitoneal spread. However, for CRC and spread to the ovary, the hematogenous route is most likely. Peritoneal involvement is usually absent at the time of diagnosis, and the external surface of the ovaries often lack tumor seedings, or adhesions [19]. Vascular imaging studies have shown vascular communication between both ovaries through the fundic arterial branches [20], which also explains why ovarian metastases from CRC tends to be bilateral, and even when unilateral, there is a high probability that the contralateral ovary, if not removed, will develop metastases [4,5,13,16]. The reduced risk of ovarian metastases in postmenopausal women indicates the protective role of reduced ovarian vascularity [11]. However, retrograde lymphatic spread after malignant obstruction of the lymphatics, or the direct implantation of malignant cells may still occur.

Abdominal pain is the most common symptom in patients presenting with ovarian metastases from CRC, followed by a change in bowel habit, and abdominal distension due to ascites or an abdominal mass [4]. Measurement of serum tumor markers, including carcinoembryonic antigen (CEA) and CA-125, are commonly used in the diagnosis of in CRC and ovarian cancer. CA-125 levels are commonly increased in epithelial ovarian cancer, and serum CA-125 is a useful prognostic marker in patients with ovarian metastases from the gastrointestinal tract (Krukenberg tumors), and levels >75 IU/ml are associated with a reduced 5-year survival rate [14]. Also, a preoperative increase in serum CA-125 usually decreases after resection of the tumor, which makes it a useful marker for successful tumor resection, and tumor recurrence [20–22]. Also, in patients with an ovarian mass who present with raised serum CA-125 levels, clinicians should always exclude a primary CRC and other gastrointestinal malignancy before diagnosing a primary ovarian cancer, as ovarian metastases have been reported as the initial manifestation in 51% of these patients [22]. There may also be a role in using both serum CEA and CA-125 in postoperative follow-up of female patients with CRC who have not had bilateral oophorectomy [13]. However, further studies are needed to support the benefit of this management approach.

The imaging characteristics of ovarian masses on computed tomography (CT), a smooth margin and cystic elements, similar to the current case, favors the presence of colonic metastases rather than a primary ovarian neoplasm [23]. Also, the presence of calcification may be associated with a metastatic mucinous carcinoma [23]. The difficulty in differentiating between primary and metastatic tumors of the ovary has been well described by Herrera et al. [20], and Skirmisdottir et al. [22]. Both studies concluded that there is still difficulty in diagnosing metastatic ovarian tumors, which continue to be misdiagnosed as primary ovarian tumors [20,22]. To distinguish between ovarian metastases due to CRC and primary ovarian carcinoma, immunohistochemical staining can support a definitive diagnosis. Positive immunostaining for cytokeratin 20 (CK20) and negative immunostaining for cytokeratin 7 (CK7) support a diagnosis of ovarian metastases from primary CRC [5,24,25].

The ovary has been described as a sanctuary for metastatic cells, as metastatic ovarian tumors do not respond favorably to chemotherapy [4,5,12]. Therefore, the only realistic option for the treatment of ovarian metastases remains oophorectomy, although the outcome remains poor. The presence of ovarian metastases indicates that the primary malignant disease has progressed, and poor prognosis can be expected [15]. Surgery may improve survival in selected patients who are younger (<50 years) and those who have only ovarian metastases [14]. Even in these cases, the 5-year survival has been estimated at around 9%, with a median survival of between 19 and 29.6 months [12]. For patients with disseminated disease, optimal cytoreduction, when feasible, offers a significant survival advantage compared with patients who have residual malignancy [4]. However, most patients die within one year from the diagnosis of ovarian metastases [26].

Finally, in female patients with primary CRC, or other gastrointestinal malignancy, there has been interest in the use of prophylactic oophorectomy, which could be easily performed at the time of primary surgery, without additional morbidity or mortality, to reduce the likelihood of ovarian metastases. However, given that metastatic ovarian cancer has a higher incidence in premenopausal women, oophorectomy may not be an option. Therefore, clinicians should offer female patients with primary gastrointestinal malignancy a range of options explaining in detail the advantages, limitations, and consequences of the procedure, because, currently, there are no consensus guidelines or recommendation regarding the use of prophylactic oophorectomy in CRC [11,13,15,16,22].

## Conclusions

Newly-diagnosed ovarian metastasis from primary colorectal cancer (CRC) is challenging to diagnose and manage, and

may be initially incorrectly diagnosed as malignancy of primary ovarian origin. This case demonstrated that it is important to confirm the diagnosis with imaging, histology, and the appropriate use of tumor markers. Because ovarian metastases do not respond favorably to chemotherapy, the treatment of choice is surgery. However, for women who are treated for CRC, the use of prophylactic oophorectomy remains controversial.

## References:

1. Ferlay J, Soerjomataram I, Dikshit R et al: Cancer incidence and mortality worldwide: sources, methods and major patterns in GLOBOCAN 2012. *Int J Cancer*, 2015; 136(5): E359–86
2. Cook AD, Single R, McCahill LE: Surgical resection of primary tumors in patients who present with stage IV colorectal cancer: An analysis of surveillance, epidemiology, and end results data, 1988 to 2000. *Ann Surg Oncol*, 2005; 12: 637–45
3. Qiu M, Hu J, Yang D et al: Pattern of distant metastases in colorectal cancer: A SEER based study. *Oncotarget*, 2015; 36: 38658–66
4. Kim DD, Park IJ, Kim HC et al: Ovarian metastases from colorectal cancer: A clinicopathological analysis of 103 patients. *Colorectal Dis*, 2009; 11: 32–38
5. Fujiwara A, Noura S, Ohue M et al: Significance of the resection of ovarian metastasis from colorectal cancers. *J Surg Oncol*, 2010; 102: 582–87
6. Yada-Hashimoto N, Yamamoto T, Kamiura S et al: Metastatic ovarian tumors: A review of 64 cases. *Gynecol Oncol*, 2003; 89(2): 314–17
7. Woodruff JD, Novak ER: The Krukenberg tumor: Study of 48 cases from the ovarian tumor registry. *Obstet Gynecol*, 1960; 15: 351–60
8. Al-Agha OM, Nicastrì AD: An in-depth look at Krukenberg tumor. An overview. *Arch Pathol Lab Med*, 2006; 130: 1725–30
9. Sakakura C, Hagiwara A, Yamazaki J et al: Management of postoperative follow-up and surgical treatment for Krukenberg tumor from colorectal cancers. *Hepatogastroenterology*, 2004; 51: 1350–53
10. Hanna NN, Cohen AM: Ovarian neoplasms in patients with colorectal cancer: Understanding the role of prophylactic oophorectomy. *Clin Colorectal Cancer*, 2004; 3: 215–22
11. Segelman J, Floter-Radestad A, Hellborg H et al: Epidemiology and prognosis of ovarian metastases in colorectal cancer. *Br J Surg*, 2010; 97: 1704–9
12. Ojo J, De Silva S, Han E et al: Krukenberg tumors from colorectal cancer: Presentation, treatment and outcomes. *Am Surg*, 2011; 77: 1381–85
13. Tan K-L, Tan W-S, Lim J-F, Eu K-W: Krukenberg tumors of colorectal origin: A dismal outcome – experience of a tertiary center. *Int J Colorectal Dis*, 2010; 25: 233–38
14. Challa VR, Goud YGB, Rangappa P et al: Ovarian metastases from colorectal cancer: Our experience. *Indian J Surg Oncol*, 2015; 6: 95–98
15. Omranipour R, Abasahl A: Ovarian metastases in colorectal cancer. *Int J Gynecol Cancer*, 2009; 19: 1524–28
16. Erroi F, Scarpa M, Angriman I et al: Ovarian metastasis from colorectal cancer: Prognostic value of radical oophorectomy. *J Surg Oncol*, 2007; 96: 113–17
17. Chung TS, Chang HJ, Jung KH et al: Role of surgery in the treatment of ovarian metastases from colorectal cancer. *J Surg Oncol*, 2009; 100: 570–74
18. Garrett CR, George B, Viswanathan C et al: Survival benefit associated with surgical oophorectomy in patients with colorectal cancer metastatic to the ovary. *Clin Colorectal Cancer*, 2012; 3: 191–94
19. Al-Agha OM, Nicastrì AD: An in-depth look at Krukenberg tumor. An overview. *Arch Pathol Lab Med*, 2006; 130: 1725–30
20. Herrera LO, Ledesma EJ, Natarajan N et al: Metachronous ovarian metastases from adenocarcinoma of the colon and rectum. *Surg Gynecol Obstet*, 1982; 154: 531–33
21. Sakakura C, Hagiwara A, Yamazaki J et al: Management of postoperative follow-up and surgical treatment for Krukenberg tumor from colorectal cancers. *Hepatogastroenterology*, 2004; 91: 1543–50
22. Skirnisdottir I, Garmo H, Holmberg L: Non-genital tract metastases to the ovaries presented as ovarian tumors in Sweden 1990–2003: Occurrence, origin and survival compared to ovarian cancer. *Gynecol Oncol*, 2007; 105(1): 166–71
23. Choi HJ, Lee JH, Kim YH et al: Computed tomography findings of ovarian metastases from colon cancer: Comparison with primary malignant ovarian tumors. *J Comput Assist Tomogr*, 2005; 29: 69–73
24. Bayrak R, Yenidunya S, Haltas H: Cytokeratin 7 and cytokeratin 20 expression in colorectal adenocarcinomas. *Pathol Res Pract*, 2011; 207: 156–60
25. Park SY, Kim HS, Hong EK, Kim WH: Expression of cytokeratins 7 and 20 in primary carcinomas of the stomach and colorectum and their value in the differential diagnosis of metastatic carcinomas to the ovary. *Hum Pathol*, 2002; 33: 1078–85
26. Yada-Hashimoto N, Yamamoto T, Kamiura S et al: Metastatic ovarian tumors: A review of 64 cases. *Gynecol Oncol*, 2003; 89: 314–17

## Conflict of interest

None.