

Molecular survey on the occurrence of avian haemosporidia, *Coxiella burnetii* and *Francisella tularensis* in waterfowl from central Italy

Valentina Virginia Ebani^{a,*}, Simona Nardoni^a, Marinella Giani^a, Guido Rocchigiani^a, Talieh Archin^b, Iolanda Altomonte^a, Alessandro Poli^a, Francesca Mancianti^a

^a Department of Veterinary Science, University of Pisa, viale delle Piagge 2, 56124, Pisa, Italy

^b Department of Microbiology, College of Veterinary Medicine, Urmia University, Urmia, Iran

ARTICLE INFO

Keywords:

Waterfowl
Leucocytozoon spp.
Plasmodium spp.
Haemoproteus spp.
Coxiella burnetii
Francisella tularensis

ABSTRACT

The aim of the present study was to evaluate the occurrence of some avian Haemosporidia, *Coxiella burnetii* and *Francisella tularensis* in waterfowl from Tuscany wetlands. One-hundred and thirty-three samples of spleen were collected from regularly hunted wild birds belonging to 13 different waterfowl species. DNA extracted from each sample was submitted to PCR assays and sequencing to detect the pathogens. Thirty-three samples (24.81%) were positive with PCR for at least one pathogen: 23 (17.29%) for *Leucocytozoon* spp., 6 (4.51%) for *Plasmodium* spp., 4 (3%) for *C. burnetii*, 2 (1.5%) for *Haemoproteus* spp. No specific *F. tularensis* amplifications (0%) were detected. To the best of our knowledge, this study firstly reports data about haemosporidian and *C. burnetii* infections in waterfowl from Italy.

1. Introduction

Avian haemosporidia are a group of protozoan parasites, among which *Plasmodium*, *Haemoproteus* and *Leucocytozoon* genera are encountered. These parasites are transmitted by blood sucking dipteran vectors, with birds acting as intermediate hosts (Valkiunas, 2005). In detail, after the inoculation of sporozoite stages by the vectors during the bloodmeal, exoerythrocytic schizonts develop in different tissues (i.e. spleen, liver, lungs, heart, brain ...) giving gametocytes into the blood cells. These latter stages are infective for the vectors.

Haemosporidians occur worldwide except in Antarctica (Beadell et al., 2009) and most infections are relatively benign, probably due to long-term host parasites evolutionary associations (Bennet et al., 1993). The occurrence of these protozoa has been reported from several birds' species (Schmid et al., 2017; Dimitrov et al., 2018; Ferreira-Junior et al., 2018; Valkiunas et al., 2019; Schumm et al., 2019) and from dipteran species (Ionică et al., 2017; Žiegytė et al., 2017; Martin et al., 2019; Schoener et al., 2019).

Domestic *Anatidae* are highly susceptible to haemosporidia (Valkiunas, 2005) and wild waterfowl have been reported as infected in several countries (Loven et al., 1980; Reeves et al., 2015; Ramey et al., 2015; Meixell et al., 2016).

To the best of our knowledge, a unique survey by Sacchi and Prigioni (1986) evaluating occurrence of haemosporidia in wild

waterfowl by microscopy in Italy yielded no positive results.

Coxiella burnetii is the etiologic agent of Q fever, a worldwide zoonotic bacterial disease. Even though domestic ruminants are considered as the main reservoirs for this pathogen, several wild mammals have been found to be hosts of this microorganism. *C. burnetii* has been found in birds (Babudieri and Moscovici, 1952; Stein and Raoult, 1999; Ebani et al., 2016), too, but little is known about the transmission patterns among avian populations. Animals as well as humans usually become infected through oral and inhalation routes, but the transmission of *C. burnetii* is also possible via tick bites (Porter et al., 2011).

Francisella tularensis is the causative agent of the severe zoonotic disease tularemia. It is a Gram negative bacterium, with a wide range of hosts including invertebrates and mammals. Birds have been experimentally infected with *F. tularensis* (Mörner and Mattsson, 1988) and naturally acquired infections have been reported in different avian species (Green and Wade, 1929; Green and Shillinger, 1932; Nakamura, 1950; Stahl et al., 1969; Mörner and Mattsson, 1983). However, studies about tularemia in avian populations were conducted many years ago and updated information is not available. Moreover, symptoms and lesions in birds are not known and some authors suggested that these animals may acquire the infection without developing disease (Mörner and Mattsson, 1988).

The transmission of *F. tularensis* may occur through haematophagous arthropods, as well as through direct or indirect contact with

* Corresponding author. Dept. Veterinary Science, University of Pisa, Viale delle Piagge, 2, 56124, Pisa, Italy.

E-mail address: valentina.virginia.ebani@unipi.it (V.V. Ebani).

Table 1
PCR primers and conditions employed in the assays for the detection of each pathogen.

Pathogens	Amplicons (target gene)	Primers sequence (5' – 3')	PCR conditions	References
*	617 bp (cytochrome b)	HAEMNFI (CATATATTAAGAGAATTATGGAG)	94 °C - 30 s	[Hellgren et al., 2004]
		HAEMNR3 (ATAGAAAAGATAAAGAAATACCATTC)	50 °C–30 s 72 °C–45 s (20 cycles)	
**	480 bp (cytochrome b)	HAEMF (ATGGTGCTTTTCGATATATGCATG)	94 °C - 30 s	[Bensch et al., 2000]
		HAEMR2 (GCATTATCTGGATGTGATAATGGT)	50 °C–30 s 72 °C–45 s (35 cycles)	
**	478 bp (cytochrome b)	HAEMFL (ATGGTGTTTTAGATACTTACATT)	94 °C - 30 s	[Hellgren et al., 2004]
		HAEMR2L (CATTATCTGGATGAGATAATGGTGC)	50 °C–30 s 72 °C–45 s (35 cycles)	
<i>Coxiella burnetii</i>	687 bp (IS1111a)	Trans-1 (TATGTATCCACCGTAGCCAGT)	95 °C–30 s	[Berri et al., 2009]
		Trans-2 (CCCAACAACACCTCCTTATTC)	64 °C–1 min 72 °C–1 min	
<i>Francisella tularensis</i>	400 bp (TUL4)	TUL4-435 (TCGAAGACGATCAGATACCGTCG)	96 °C–1 min	[Milutinović et al., 2008]
		TUL4-863 (TGCCTTAAACTTCCTTGGGAT)	60.5 °C–1 min	
			72 °C–1 min	

*Primary amplification; ** Secondary amplification.

Table 2
Number of specimens and detail of positive reactions for *Coxiella burnetii*, *Haemoproteus* spp., *Leucocytozoon* spp. and *Plasmodium* spp. in relation to the tested avian species.

Animal species	No. tested specimen	Positive reactions
<i>Anseriformes</i>		
<i>Anas crecca</i>	63	15 <i>Leucocytozoon</i> spp. 3 <i>C. burnetii</i> 2 <i>Plasmodium</i> spp.
<i>Anas platyrhynchos</i>	21	1 <i>Haemoproteus</i> spp.
<i>Anas penelope</i>	19	3 <i>Leucocytozoon</i> spp. 4 <i>Plasmodium</i> spp. 1 <i>C. burnetii</i>
<i>Anas clypeata</i>	10	2 <i>Leucocytozoon</i> spp.
<i>Anas acuta</i>	3	2 <i>Leucocytozoon</i> spp.
<i>Aythya ferina</i>	3	Negative
<i>Tadorna tadorna</i>	2	Negative
<i>Anas strepera</i>	2	1 <i>Leucocytozoon</i> spp.
<i>Anas querquedula</i>	1	Negative
<i>Aythya fuligula</i>	1	Negative
<i>Anser anser</i>	1	Negative
<i>Charadriiformes</i>		
<i>Gallinago gallinago</i>	6	1 <i>Haemoproteus</i> spp.
<i>Gruiformes</i>		
<i>Fulica atra</i>	1	Negative
Total	133	35

infected animals.

In view of the scant data available about the spreading of Haemosporidia, *C. burnetii* and *F. tularensis* among avian population in Italy, the aim of the present study was to investigate the occurrence of these pathogens among wild waterfowl hunted in Tuscany (Central Italy) wetlands.

2. Material and methods

2.1. Animals

The study was performed on 133 wild birds belonging to 13 different waterfowl species of the Orders *Anseriformes*, *Charadriiformes* and *Gruiformes*. More in detail, the analysis were executed on 63 common teals (*Anas crecca*), 21 mallards (*Anas platyrhynchos*), 19 eurasian wigeons (*Anas penelope*), 10 northern shovelers (*Anas clypeata*), 6 common snipes (*Gallinago gallinago*), 3 pintails (*Anas acuta*), 3 common pochards (*Aythya ferina*), 2 common shelducks (*Tadorna tadorna*), 2 gadwalls (*Anas strepera*), 1 garganey (*Anas querquedula*), 1 tufted duck (*Aythya fuligula*), 1 greylag goose (*Anser anser*), and 1 eurasian coot (*Fulica atra*).

All animals were regularly hunted during the 2016 and 2017

hunting seasons (September–January) in the Province of Pisa, in the wetland “Padule di Fucecchio” (43°48'N 10°48'E/43.8°N 10.8°E43.8), located on the migration route of waterfowls. All the animals were intended for human consumption, so the carcasses were immediately refrigerate until processing (about within 24 h). Bird's carcasses were submitted to assessment of body condition and examined for ectoparasites. Viscera were removed from each bird, maintained at 4 °C and sent to the laboratories. Impression smears were prepared from spleen of each animal for microscopical examination. The remaining portions were stored at –20 °C for molecular analysis. It was not possible to obtain blood specimens to investigate blood stage parasites and sellers allowed us to collect spleens, only. However this tissue was reported as sensitive in detecting haemosporidian parasites (Scaglione et al., 2016; Valkiunas and Iezhova, 2017). Spleen allows the detection of *C. burnetii* and *F. tularensis*, too, because hematogenous spread of these bacteria lead to involvement of several organs including this one (Bell, 1980; Maurin and Raoult, 1999).

2.2. Microscopical examination

The spleen impression smears were prepared on glass slide, fixed in methanol and stained with modified Wright's solution. Each smear was examined through 100 fields at low magnification (400X), then at least 100 fields were observed at high magnification (1000X).

2.3. Molecular analysis

Extraction of total DNA was carried out from up to 10 mg of each spleen sample using the DNeasy® Blood & Tissue kit (QIAGEN, Milano, Italy) and following the manufacturer's instructions. DNA specimens were stored at 4 °C until used as template for the PCR assays.

Different PCR protocols were carried out to detect DNA of pathogens. *Haemoproteus* spp., *Plasmodium* spp., *Leucocytozoon* spp. DNA were detected, with a nested PCR protocol, according to Hellgren et al. (2004) and Bensch et al. (2000). The extracted DNA was first subjected to an amplification common to *Leucocytozoon*, *Haemoproteus* and *Plasmodium*, and then, its product was submitted to two parallel PCRs, one amplifying both *Haemoproteus* and *Plasmodium* while the another one amplifying *Leucocytozoon* only.). *C. burnetii* and *F. tularensis* DNA were investigated, using primers and procedures previously described, respectively (Milutinović et al., 2008; Berri et al., 2009). Target genes, primers sequences and PCR conditions are summarized in Table 1.

PCR amplifications were performed using the EconoTaq PLUS 2x Master Mix (Lucigen Corporation, Middleton, Wisconsin, USA) and an automated thermal cycler (GeneAmp PCR System 2700, Perkin Elmer, Norwalk, Connecticut, USA).

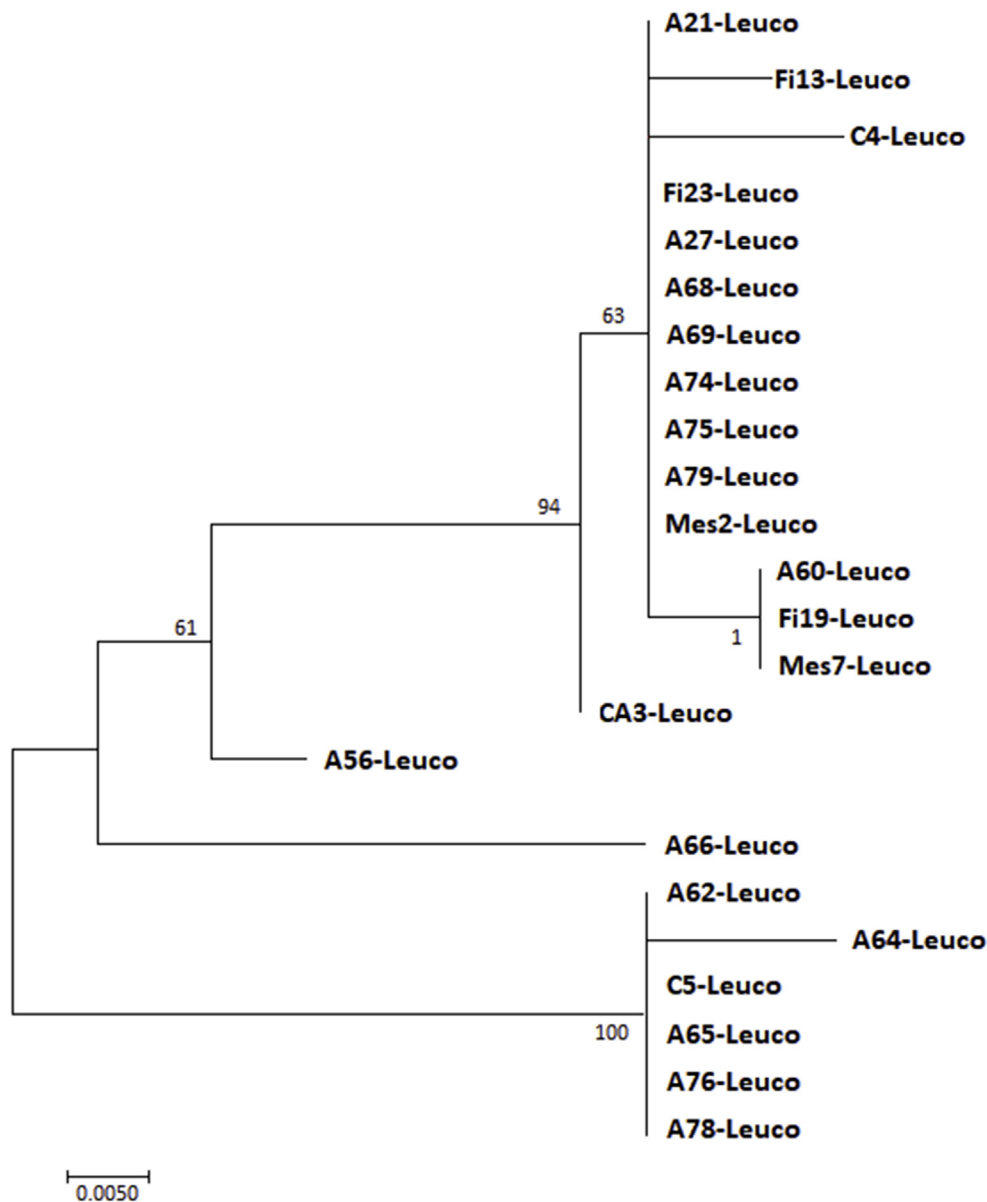


Fig. 1. Phylogenetic tree showing the *Leucocytozoon* sequencing results.

PCR products were analysed by electrophoresis on 1.5% agarose gel at 100 V for 45 min; gel was stained with ethidium bromide and observed. SharpMass™ 100 Plus Ladder (Euroclone, Milano, Italy) was used as DNA marker.

Samples resulted positive for *Haemoproteus* spp., *Plasmodium* spp. and *Leucocytozoon* spp. were sequenced on both strands by the commercial laboratory BMR-Genomics (Padua, Italy), using the inner primers. The sequence obtained was assembled and corrected by visual analysis of the electropherogram using Bioedit v.7.0.233 and compared with those available in GenBank[®] 4 using the BLASTn[®] program (<http://www.ncbi.nlm.nih.gov/BLAST>). Sequences obtained by overlapping both sense and antisense strands were exclusively used in the article.

3. Results

All animals of the study were in good nutrition conditions and no lesions and ectoparasites were observed during the carcasses' manipulation. No microorganisms or parasite stages were observed in smears.

Among the 133 tested samples, 33 (24.81%) were PCR positive for

at least one pathogen. More in details, 23 (17.29%) birds were positive for *Leucocytozoon* spp., 6 (4.51%) for *Plasmodium* spp., 4 (3%) for *C. burnetii*, 2 (1.5%) for *Haemoproteus* spp. No specific *F. tularensis* amplifications (0%) were detected (Table 2).

Sequence analysis for *Leucocytozoon* spp. revealed that the majority of the isolates fell in two broad groups.

One group (here called *Leucocytozoon* “lineage duck 1”) was composed of 9 isolates, showing 100% homology with parasites sequenced from previous studies (L. K vleu MG593842; L; L. TS-2014a voucher MN-08-A-0235, KJ577823; L. MMSL02, KU295418; L. TUSW04 JQ314223).

The other group (*Leucocytozoon* “lineage duck 2”) was composed of 6 isolates, exhibiting 100% homology with different parasites sequenced (DUCK 18, KM386326; L. BWTE20, KU363710).

Six isolates showed 99% homology with haplotype duck 1, with two mismatches maximum.

One isolate exhibited 100% identity with L. DUCK40 KM386348.

One isolate exhibited 98% homology with L.duck. Duck32 KM386340 e Duck34 KM386342. The phylogenetic tree in Fig. 1 illustrates the leucocytozoon sequencing results.

Table 3
–Sequencing analysis results of the samples resulted PCR positive for Haemosporidia.

Host species	Parasite genus	Number bp	% homology	GenBank sequences
<i>Anas crecca</i>	<i>Leucocytozoon</i>	514	100	L.Kvleu; L.TS-2014a vouch MN-08B-0298; L.TS-2014 ^a vouch MN-08-A-0235; L.MMSL02; TUSW04
<i>Anas crecca</i>	<i>Leucocytozoon</i>	501	100	L.DUCK18; L.BWTE20
<i>Anas crecca</i>	<i>Leucocytozoon</i>	344	100	L.DUCK18; L.BWTE20
<i>Anas crecca</i>	<i>Leucocytozoon</i>	504	100	L.DUCK18; L.BWTE20
<i>Anas crecca</i>	<i>Leucocytozoon</i>	518	100	L.DUCK40
<i>Anas crecca</i>	<i>Leucocytozoon</i>	444	100	L.Kvleu; L.TS-2014a vouch MN-08B-0298; L.TS-2014 ^a vouch MN-08-A-0235; L.MMSL02; TUSW04
<i>Anas crecca</i>	<i>Leucocytozoon</i>	511	100	L.Kvleu; L.TS-2014a vouch MN-08B-0298; L.TS-2014 ^a vouch MN-08-A-0235; L.MMSL02
<i>Anas crecca</i>	<i>Leucocytozoon</i>	466	100	L.Kvleu; L.TS-2014a vouch MN-08B-0298; L.TS-2014 ^a vouch MN-08-A-0235; L.MMSL02; TUSW04
<i>Anas crecca</i>	<i>Leucocytozoon</i>	439	100	L.Kvleu; L.TS-2014a vouch MN-08B-0298; L.TS-2014 ^a vouch MN-08-A-0235; L.MMSL02; TUSW04
<i>Anas crecca</i>	<i>Leucocytozoon</i>	443	100	L.DUCK18; L.BWTE20
<i>Anas crecca</i>	<i>Leucocytozoon</i>	515	100	L.DUCK18; L.BWTE20
<i>Anas crecca</i>	<i>Leucocytozoon</i>	507	100	L.Kvleu; L.TS-2014a vouch MN-08B-0298; L.TS-2014 ^a vouch MN-08-A-0235; L.MMSL02; TUSW04
<i>Anas acuta</i>	<i>Leucocytozoon</i>	495	100	L.DUCK18; L.BWTE20
<i>Anas penelope</i>	<i>Leucocytozoon</i>	502	100	L.Kvleu; L.TS-2014a vouch MN-08B-0298; L.TS-2014 ^a vouch MN-08-A-0235; L.MMSL02; TUSW04
<i>Anas clypeata</i>	<i>Leucocytozoon</i>	518	100	L.Kvleu; L.TS-2014a vouch MN-08B-0298; L.TS-2014 ^a vouch MN-08-A-0235; L.MMSL02; TUSW04
<i>Anas clypeata</i>	<i>Leucocytozoon</i>	496	100	L.Kvleu; L.TS-2014a vouch MN-08B-0298; L.TS-2014 ^a vouch MN-08-A-0235; L.MMSL02; TUSW04
<i>Anas crecca</i>	<i>Leucocytozoon</i>	509	99	L.Kvleu; L.TS-2014a vouch MN-08B-0298; L.TS-2014 ^a vouch MN-08-A-0235; L.MMSL02; TUSW04; TUSW03
<i>Anas crecca</i>	<i>Leucocytozoon</i>	508	99	L.Kvleu; L.TS-2014a vouch MN-08B-0298; L.TS-2014 ^a vouch MN-08-A-0235; L.MMSL02; TUSW04; TUSW03
<i>Anas acuta</i>	<i>Leucocytozoon</i>	496	99	L.Kvleu; L.TS-2014a vouch MN-08B-0298; L.TS-2014 ^a vouch MN-08-A-0235; L.MMSL02; TUSW04; TUSW03
<i>Anas strepera</i>	<i>Leucocytozoon</i>	503	99	L.Kvleu; L.TS-2014a vouch MN-08B-0298; L.TS-2014 ^a vouch MN-08-A-0235; L.MMSL02; TUSW04; TUSW03
<i>Anas penelope</i>	<i>Leucocytozoon</i>	489	99	L.Kvleu; L.TS-2014a vouch MN-08B-0298; L.TS-2014 ^a vouch MN-08-A-0235; L.MMSL02; TUSW04; TUSW03
<i>Anas penelope*</i>	<i>Leucocytozoon</i>	355	99	L.Kvleu; L.TS-2014a vouch MN-08B-0298; L.TS-2014 ^a vouch MN-08-A-0235; L.MMSL02; TUSW04; TUSW03
<i>Anas crecca</i>	<i>Leucocytozoon</i>	455	98	LDUCK32; LDUCK34
<i>Anas crecca</i>	<i>Plasmodium</i>	527	100	<i>Plasmodium circumflexum</i>
<i>Anas crecca</i>	<i>Plasmodium</i>	64	100	<i>Plasmodium polare</i>
<i>Anas penelope</i>	<i>Plasmodium</i>	290	100	<i>Plasmodium circumflexum</i>
<i>Anas penelope</i>	<i>Plasmodium</i>	462	100	P.Sybor2
<i>Anas penelope*</i>	<i>Plasmodium</i>	421	100	<i>Plasmodium circumflexum</i>
<i>Anas penelope</i>	<i>Plasmodium</i>	145	99	P. Sybor2
<i>Gallinago gallinago</i>	<i>Haemoproteus</i>	497	100	H230
<i>Anas platyrhynchos</i>	<i>Haemoproteus</i>	478	100	H230

Legend - *: one *Anas penelope* scored positive to *Leucocytozoon* and *Plasmodium circumflexum*.

Table 4

PCR results for pathogen, lineage and host species. In each square it is indicated the number of animal scored positive for each pathogen with the percentage of sequence homology.

Animal species	L. "lineage duck 1"	L. "lineage duck 2"	L. duck 40	L. duck 32	<i>P. polare</i>	<i>P. circumflexum</i>	P. sybor 2	H 230
<i>Anas crecca</i>	6 (100%) 2 (99%)	5 (100%)	1 (100%)	1 (98%)	1 (100%)	1 (100%)		
<i>Anas acuta</i>	1 (99%)	1 (100%)						
<i>Anas penelope</i>	2 (100%) 1(99%)					2 (100%)	1 (100%) 1 (99%)	
<i>Anas clypeata</i>	2 (100%)							
<i>Anas streptera</i>	1 (99%)							
<i>Gallinago gallinago</i>								1 (100%)
<i>Anas platyrhynchos</i>								1 (100%)

Sequences analysis for *Plasmodium* found 100% homology with *Plasmodium circumflexum* for 3 samples and *Plasmodium polare* for one sample; one specimen scored 100% similar to P. Sybor2 isolate. One sample showed 99% homology with the sequence P. Sybor2. Two amplicons were identified as *Haemoproteus* spp.

A mixed infection by *Leucocytozoon* and *P. circumflexum* was observed in one *A. penelope* whereas a mixed infection by *Leucocytozoon* and *C. burnetii* was detected in one *A. crecca*.

More detailed data about hosts and agents are reported in Tables 3 and 4.

4. Discussion

The investigated subjects showed a 23.3% prevalence of infection by haemosporidia, with *Leucocytozoon* being the most abundant parasite detected via PCR (17.29%). In similar investigations this genus was the more frequently encountered in *Anseriformes*, both domestic (Ramey et al., 2012) and wild (Ramey et al., 2015; Reeves et al., 2015; Smith et al., 2016; Seimon et al., 2016). The L. "lineage duck 1" showed

100% identity with parasites detected from *Anser domesticus* (L. Kvleu MG593842, Turkey), *Anser indicus* (L. TS-2014a voucher MN-08-A-0235, KJ577823, Mongolia) *A. platyrhynchos* (L. MMSL02, KU295418, Alaska) and *Cygnus colombianus* (L. TUSW04 JQ314223, Alaska). The "lineage duck 2" exhibited 100% identity with isolates coming from *Anas* sp.(L. DUCK 18, KM386326, Pacific America) and *Anas discors* (L. BWTE20, KU363710, North America). These findings suggest that the lineages observed in the present study are well adapted to *Anatidae* birds. Additionally, since the same lineages were observed also in other continents, the isolates described in Italy don't seem to be confined only in Europe. Such findings needs further studies to strengthen this hypothesis.

Plasmodium was identified in 6 animals (4.51%), 2 *A. crecca* and 4 *A. penelope*. In these animals 2 species and different sequences were recognized. This haemosporidian genus, in contrast with *Leucocytozoon* and *Haemoproteus*, is not considered as a host specific parasite (Reeves et al., 2015; Smith et al., 2016). *P. circumflexum* has been recorded to have a low host specificity (Dimitrov et al., 2015), and in the present study was reported in a mixed infection with *Leucocytozoon*. *P. polare*

was identified in one specimen from *A. crecca*. This haemosporidian species has been previously isolated from great tits (*Parus major*), from Switzerland (Rooyen et al., 2013). *Haemoproteus* was identified only in 2 samples (1.5%), from a *G. gallinago* and a *A. platyrhynchos*; however, isolated sequences did not allow us to recognize the species.

Data from Italy are scanty and consist of a study, carried out by microscopy, in which *Leucocytozoon* and *Haemoproteus* were not detected in *Anatidae* and *Charadriidae* from North Italy (Sacchi and Prigioni, 1986). At the best of our knowledge, this is the first report of haemosporidian infection in *A. penelope*, *A. strepera*, *A. querquedula*, *T. tadorna* and *G. gallinago*.

Similar studies have been conducted on waterfowl in the USA (Ramey et al., 2015; Reeves et al., 2015; Meixell et al., 2016) in a lower number of bird species and in injured birds from Japan (Inumaru et al., 2017). Nevertheless, the above mentioned authors reported higher prevalence values in respect to the present study. Different results obtained in literature could be due to both extrinsic and intrinsic factors, such as methods used. The season in which the study is performed is important, because in dry environment the prevalence of infection would be lower (Smith and Ramey, 2015), even if in the present study sampling was conducted during autumn/winter seasons. The present investigation detected four animals (3 *A. crecca* and 1 *A. penelope*) positive (3%) for *C. burnetii*, whereas no *F. tularensis*-positive reactions were found. *C. burnetii* and *F. tularensis* may be transmitted by haematophagous arthropods, mainly ticks, but other transmission routes are possible. *C. burnetii*-positive birds could have contracted the pathogen by ticks' bite, but it is easier to consider the oral route. In fact, waterfowl may travel large distances per day and reach areas where infected animals, wild and domestic, are present. Birds infected by *C. burnetii* play a relevant epidemiological role, because they can disperse the bacteria in the environment through their feces and they may be source of coxiellae for ticks during the blood meal.

On the basis of previous epidemiological studies in mammals and data relative to human infections, *F. tularensis* seems to not be largely present in Italy (Pascucci et al., 2015; Ebani et al., 2016, 2017; Graziani et al., 2016; Rocchigiani et al., 2018), thus the negative results of the tested waterfowl could reflect the true epidemiological status. *F. tularensis* has been proven to be able to infect different avian species, thus birds could be cause of infection for humans. Hunters are more at risk of infection having direct or indirect contact with wild birds, as suggested by Padeshki et al. (2010), who reported a case of tularemia with typical ulceroglandular form in a hunter who acquired the infection through a nail scratch from a buzzard (*Buteo buteo*).

Data about the transmission of *C. burnetii* and *F. tularensis* among avifauna are scant in scientific literature. Two studies have been carried out on ticks collected from birds in Italy: Toma et al. (2014) detected *C. burnetii* DNA in 42/127 analysed ticks collected from migratory birds of different species, but not waterfowl; Pajoro et al. (2018) did not detect *C. burnetii* and *F. tularensis* in any ticks collected from 124 wild birds. A recent investigation has been carried out on fecal samples collected from 673 migratory birds along the Mediterranean – Black Sea flyway and bacteriological and molecular analyses found neither *F. tularensis* nor *C. burnetii* (Najdenski et al., 2018).

5. Conclusions

The present study firstly reports data about haemosporidia and *C. burnetii* infections in waterfowl from Italy. In particular, these findings would add more data about haemosporidia species and strains circulating in avian population. Moreover, it has been confirmed the involvement of wild birds in the epidemiology of *C. burnetii*, suggesting that these animals may be direct and indirect source of infection for people. In fact, humans could be at risk when manipulating infected live birds or carcasses, as well as they could contract the infection because of the environment contamination with coxiellae excreted through birds' droppings.

Funding

This work was supported by the University of Pisa.

Conflicts of interest

All authors disclose any financial and personal relationships with other people or organizations that could inappropriately influence their work.

References

- Babadieri, B., Moscovici, L., 1952. Experimental and natural infection of birds by *Coxiella burnetii*. *Lancet* 169, 195–196.
- Beadell, J.S., Covas, R., Gebhard, C., Ishtiaq, F., Melo, M., Schmidt, B.K., Perkins, S.L., Graves, G.R., Fleischer, R.C., 2009. Host associations and evolutionary relationships of avian blood parasites from West Africa. *Int. J. Parasitol.* 39, 257e266.
- Bell, F., 1980. Tularemia. In: Steele, J.H. (Ed.), *CRC Handbook Series in Zoonoses. Section A: Bacterial, Rickettsial, and Mycotic Diseases*. CRC Press, Boca Raton, Florida, pp. 161–163.
- Bennett, G.F., Peirce, M.A., Ashford, R.W., 1993. Avian hematozoa—mortality and pathogenicity. *J. Nat. Hist.* 27, 993–1001.
- Bensch, S., Stjernman, M., Hasselquist, D., Ostman, O., Hansson, B., Westerlund, H., Pinheiro, R.T., 2000. Host specificity in avian blood parasites: a study of *Plasmodium* and *Haemoproteus* mitochondrial DNA amplified from birds. *Proc. R. Soc. Lond. B.* 267, 1583–1589.
- Berri, M., Rekiki, A., Boumedine, A., Rodolakis, A., 2009. Simultaneous differential detection of *Chlamydomydia abortus*, *Chlamydomydia pecorum*, and *Coxiella burnetii* from aborted ruminant's clinical samples using multiplex PCR. *BMC Microbiol.* 9, 130. <https://doi.org/10.1186/1471-2180-9-130>.
- Dimitrov, D., Ilieva, M., Ivanova, K., Brlik, V., Zehindjiev, P., 2018. Detecting local transmission of avian malaria and related haemosporidian parasites (Apicomplexa, Haemosporida) at a Special Protection Area of Natura 2000 network. *Parasitol. Res.* 117, 2187–2199.
- Dimitrov, D., Palinauskas, V., Iezhova, T.A., Bernotienė, R., Ilgūnas, M., Bukauskaitė, D., Zehindjiev, P., Ilieva, M., Shapoval, A.P., Bolshakov, C.V., Markovets, M.Y., Bensch, S., Valkiūnas, G., 2015. *Plasmodium* spp.: an experimental study on vertebrate host susceptibility to avian malaria. *Exp. Parasitol.* 148, 1–16.
- Ebani, V.V., Bertelloni, F., Mani, P., 2016. Molecular survey on zoonotic tick-borne bacteria and chlamydiae in feral pigeons (*Columba livia domestica*). *Asian Pac. J. Trop. Med.* 9, 324–327.
- Ebani, V.V., Rocchigiani, G., Nardoni, S., Bertelloni, F., Vasta, V., Papini, R.A., Verin, R., Poli, A., Mancianti, F., 2017. Molecular detection of tick-borne pathogens in wild red foxes (*Vulpes vulpes*) from Central Italy. *Acta Trop.* 172, 197–200.
- Ferreira-Junior, F.C., de Angeli Dutra, D., Silveira, P., Pacheco, R.C., Witter, R., de Souza Ramos, D.G., Pacheco, M.A., Escalante, A.A., Braga, É.M., 2018. A new pathogen spillover from domestic to wild animals: *Plasmodium juxtannulare* infects free-living passerines in Brazil. *Parasitology* 145, 1949–1958.
- Graziani, C., Duranti, A., Morelli, A., Busani, L., Pezzotti, P., 2016. Zoonoses in Italy in the Period 2009–2013. *Istituto Superiore di Sanità, Rapporti ISTISAN* 16/1, pp. 72.
- Green, R.C., Shillinger, J.E., 1932. A natural infection of the sharp-tailed grouse and the ruffed grouse by *Pasteurella tularensis*. *PSEBM (Proc. Soc. Exp. Biol. Med.)* 30, 284–287.
- Green, R.C., Wade, E.M., 1929. A natural infection of quail by *Bacterium tularense*. *PSEBM (Proc. Soc. Exp. Biol. Med.)* 26, 626–627.
- Hellgren, O., Waldenstrom, J., Bensch, S., 2004. A new PCR assay for simultaneous studies of *Leucocytozoon*, *Plasmodium*, and *Haemoproteus* from avian blood. *J. Parasitol.* 90, 797–802.
- Inumaru, M., Murata, K., Sato, Y., 2017. Prevalence of avian haemosporidia among injured wild birds in Tokyo and environs, Japan. *Int. J. Parasitol. Parasites Wildl.* 6, 299–309.
- Ionică, A.M., Zittra, C., Wimmer, V., Leitner, N., Votýpka, J., Modrý, D., Mihalca, A.D., Fuehrer, H.P., 2017. Mosquitoes in the Danube Delta: searching for vectors of filarial helminths and avian malaria. *Parasites Vectors* 10 (1), 324. <https://doi.org/10.1186/s13071-017-2264-8>.
- Loven, J.S., Bolen, E.G., Cain, B.W., 1980. Blood parasitemia in a south Texas wintering waterfowl population. *J. Wildl. Dis.* 16, 25–28.
- Martin, E., Chu, E., Shults, P., Golnar, A., Swanson, D.A., Benn, J., Kim, D., Schneider, P., Pena, S., Culver, C., Medeiros, M.C.I., Hamer, S.A., Hamer, G.L., 2019. *Culicoides* species community composition and infection status with parasites in an urban environment of east central Texas, USA. *Parasites Vectors* 12 (1), 39. <https://doi.org/10.1186/s13071-018-3283-9>.
- Maurin, M., Raoult, D., 1999. Q fever. *Clin. Microbiol. Rev.* 12 (4), 518–553.
- Meixell, B.W., Arnold, T.W., Lindberg, M.S., Smith, M.M., Runstadler, J.A., Ramey, A.M., 2016. Detection, prevalence, and transmission of avian hematozoa in waterfowl at the Arctic-sub-Arctic interface: co-infections, viral interactions, and sources of variation. *Parasites Vectors* 9 (1), 390. <https://doi.org/10.1186/s13071-016-1666-3>.
- Milutinović, M., Masuzawa, T., Tomanović, S., Radulović, Z., Fukui, T., Okamoto, Y., 2008. *Borrelia burgdorferi* sensu lato, *Anaplasma phagocytophilum*, *Francisella tularensis* and their co-infections in host-seeking *Ixodes ricinus* ticks collected in Serbia. *Exp. Appl. Acarol.* 45, 171–183.
- Mörner, T., Mattsson, R., 1983. Tularemia in a rough-legged buzzard (*Buteo lagopus*) and

- a Ural owl (*Strix uralensis*). J. Wildl. Dis. 19, 360–361.
- Mörner, T., Mattsson, R., 1988. Experimental infection of five species of raptors and of hooded crows with *Francisella tularensis* biovar *paleartica*. J. Wildl. Dis. 24, 15–21.
- Najdenski, H., Dimova, T., Zaharieva, M.M., Nikolov, B., Petrova-Dinkova, G., Dalakchieva, S., Popov, K., Hristova-Nikolova, I., Zehtindjiev, P., Peev, S., Trifonova-Hristova, A., Carniel, E., Panferova, Y.A., Tokarevich, N.K., 2018. Migratory birds along the mediterranean – Black Sea flyway as carriers of zoonotic pathogens. Can. J. Microbiol. 64, 915–924.
- Nakamura, M., 1950. Tularemia in the red-tailed hawk (*Buteo jamaicensis calurus*). Auk 67, 383–384.
- Padeshki, P.I., Ivanov, I.N., Popov, B., Kantardjiev, T.V., 2010. The role of birds in dissemination of *Francisella tularensis*: first direct molecular evidence for bird-to-human transmission. Epidemiol. Infect. 138, 376–379.
- Pajoro, M., Piston, D., Varotto Boccazzi, I., Mereghetti, V., Bandi, C., Fabbri, M., Scattorin, F., Sasseria, D., Montagna, M., 2018. Molecular screening for bacterial pathogens in ticks (*Ixodes ricinus*) collected on migratory birds captured in northern Italy. Folia Parasitol. 65, 008. <https://doi.org/10.14411/fp.2018.008>.
- Pascucci, I., Di Domenico, M., Dall'Acqua, F., Sozio, G., Cammà, C., 2015. Detection of Lyme disease and Q fever agents in wild rodents in central Italy. Vector Borne Zoonotic Dis. 15, 404–411.
- Porter, S.R., Czaplicki, G., Mainil, J., Guattéo, R., Saegerman, C., 2011. Q Fever: current state of knowledge and perspective of research of a neglected zoonosis. Internet J. Microbiol. 2011, 248418. <https://doi.org/10.115572011/248418>.
- Ramey, A.M., Ely, C.R., Pearce, J.M., Schmutz, J.A., Heard, D.J., 2012. Molecular Detection of Hematozoa Infections in Tundra Swans Relative to Migration Patterns and Ecological Conditions at Breeding Grounds. USGS Alaska Science Center, 4210 University Drive, Anchorage, AK 99508, USA.
- Ramey, A.M., Schmutz, J.A., Reed, J.A., Fujita, G., Scotton, B.D., Casler, B., Fleskes, J.P., Konishi, K., Uchida, K., Yabsley, M.J., 2015. Evidence for intercontinental parasite exchange through molecular detection and characterization of hematozoa in northern pintails (*Anas acuta*) sampled throughout the North Pacific Basin. Int. J. Parasitol. Parasites Wildl. 4, 11–21.
- Reeves, A.B., Smith, M.M., Meixell, B.W., Fleskes, J.P., Ramey, A.M., 2015. Genetic diversity and host specificity varies across three genera of blood parasites in ducks of the Pacific Americas Flyway. PLoS One 10 (2). <https://doi.org/10.1371/journal.pone.0116661>. e0116661.
- Rocchigiani, G., Ebani, V.V., Nardoni, S., Bertelloni, F., Bascherini, A., Leoni, A., Mancianti, F., Poli, A., 2018. Molecular survey on the occurrence of arthropod-borne pathogens in wild brown hares (*Lepus europaeus*) from Central Italy. Infect. Genet. Evol. 59, 142–147.
- Rooyen, J.V., Lalubin, F., Glaizot, O., Christe, P., 2013. Altitudinal variation in haemosporidian parasite distribution in great tit populations. Parasites Vectors 6, 139. <https://doi.org/10.1186/1756-3305-6-139>.
- Sacchi, L., Prigioni, C., 1986. Avian parasites in Ticino Park and in other Italian regions. Ann. Istituto Super. Sanita 22, 111–116.
- Scaglione, F.E., Cannizzo, F.T., Pregel, P., Perez Rodriguez, A.D., Bollo, E., 2016. Blood parasites in hooded crows (*Corvus corone cornix*) in Northwest Italy. Vet. Ital. 52 (2), 111–116.
- Schmid, S., Fachet, K., Dinkel, A., Mackenstedt, U., Woog, F., 2017. Carrion crows (*Corvus corone*) of southwest Germany: important hosts for haemosporidian parasites. Malar. J. 16 (1), 369. <https://doi.org/10.1186/s12936-017-2023-5>.
- Schoener, E.R., Harl, J., Himmel, T., Fragner, K., Weissenböck, H., Fuehrer, H.P., 2019. Protozoan parasites in *Culex pipiens* mosquitoes in Vienna. Parasitol. Res. 118 (4), 1261–1269.
- Schumm, Y.R., Wecker, C., Marek, C., Wassmuth, M., Bentele, A., Willems, H., Reiner, G., Quillfeldt, P., 2019. Blood parasites in Passeriformes in central Germany: prevalence and lineage diversity of Haemosporidia (*Haemoproteus*, *Plasmodium* and *Leucocytozoon*) in six common songbirds. Peer J. 6, e6259.
- Seimon, T.A., Gilbert, M., Neabore, S., Hollinger, C., Tomaszewicz, A., Newton, A., Chang, T., McAloose, D., 2016. Avian hemosporean parasite lineages in four species of free-ranging migratory water birds from Mongolia, 2008. J. Wildl. Dis. 52, 682–687.
- Smith, M.M., Ramey, A.M., 2015. Prevalence and genetic diversity of haematzoa in South American waterfowl and evidence for intercontinental redistribution of parasites by migratory birds. Int. J. Parasitol. Parasites Wildl. 4, 22–28.
- Smith, M.M., Van Hemert, C., Merizon, R., 2016. Haemosporidian parasite infections in grouse and ptarmigan: prevalence and genetic diversity of blood parasites in resident Alaskan birds. Int. J. Parasitol. Parasites Wildl. 5, 229–239.
- Stahl, I.W., Schnurrenserger, P.R., Martin, R.J., 1969. Water related cases of tularemia in Illinois. Ill. Med. J. 136, 276–277.
- Stein, A., Raoult, D., 1999. Pigeon pneumonia in Provence: a bird-borne Q Fever outbreak. Clin. Infect. Dis. 29, 617–620.
- Toma, L., Mancini, F., Di Luca, M., Cecere, J.G., Bianchi, R., Khoury, C., Quarchioni, E., Manzia, F., Rezza, G., Ciervo, A., 2014. Detection of microbial agents in ticks collected from migratory birds in central Italy. Vector Borne Zoonotic Dis. 14, 199–205.
- Valkiunas, G., 2005. Avian Malaria Parasites and Other Haemosporidia. CRC Press, Boca Raton, Florida, USA.
- Valkiūnas, G., Iezhova, T.A., 2017. Exo-erythrocytic development of avian malaria and related haemosporidian parasites. Malar. J. 16 (1), 101.
- Valkiūnas, G., Ilgūnas, M., Bukauskaitė, D., Chagas, C.R.F., Bernotienė, R., Himmel, T., Harl, J., Weissenböck, H., Iezhova, T.A., 2019. Molecular characterization of six widespread avian haemoproteids, with description of three new *Haemoproteus* species. Acta Trop. 197, 1050–1051.
- Žiegytė, R., Markovets, M.Y., Bernotienė, R., Mukhin, A., Iezhova, T.A., Valkiūnas, G., Palinauskas, V., 2017. The widespread biting midge *Culicoides impunctatus* (Ceratopogonidae) is susceptible to infection with numerous *Haemoproteus* (Haemoproteidae) species. Parasites Vectors 10 (1), 397. <https://doi.org/10.1186/s13071-017-2317-z>.