

## Psoriatic arthritis – new perspectives

Przemysław Krakowski<sup>1</sup>, Agnieszka Gerkowicz<sup>2</sup>, Aldona Pietrzak<sup>2</sup>, Dorota Krasowska<sup>2</sup>, Andrzej Jurkiewicz<sup>1</sup>, Mieczysław Gorzelak<sup>3</sup>, Robert A. Schwartz<sup>4</sup>

<sup>1</sup>Orthopaedic Department, Independent Public District Hospital, Łęczna, Poland

<sup>2</sup>Chair and Department of Dermatology, Venereology and Pediatric Dermatology, Medical University of Lublin, Lublin, Poland

<sup>3</sup>Chair and Department of Rehabilitation and Orthopedics, Medical University of Lublin, Lublin, Poland

<sup>4</sup>Dermatology Rutgers New Jersey Medical School Rutgers, The State University of New Jersey, USA

**Submitted:** 1 May 2018

**Accepted:** 18 July 2018

Arch Med Sci 2019; 15 (3): 580–589

DOI: <https://doi.org/10.5114/aoms.2018.77725>

Copyright © 2018 Termedia & Banach

**Corresponding author:**

Aldona Pietrzak MD, PhD

Chair and Department

of Dermatology,

Venereology and

Pediatric Dermatology

Medical University

of Lublin

13 Radziwiłłowska St

20-080 Lublin, Poland

Phone: +48 607 305 501

E-mail: [aldonkapietrzak@o2.pl](mailto:aldonkapietrzak@o2.pl)

### Abstract

Psoriatic arthritis (PsA) is a seronegative arthropathy with many clinical manifestations, and it may affect nearly a half of patients with psoriasis. PsA should be diagnosed as early as possible to slow down joint damage and progression of disability. To improve the diagnosis of PsA, physicians should look for peripheral inflammatory pain, axial inflammatory pain, dactylitis, and buttock and sciatic pain. In most patients with PsA, pharmacologic treatment with non-steroidal anti-inflammatory drugs, disease-modifying anti-rheumatic drugs, and biologic agents is effective. However, when pharmacological treatment fails, patients with PsA may benefit from orthopedic surgery, which can improve both joint function and quality of life. Total hip arthroplasty, total knee arthroplasty, and arthroscopic synovectomy of the knee are the most common surgical procedures offered to patients with PsA. The management of PsA requires the care of a multidisciplinary team, which should include dermatologists, rheumatologists, physiotherapists, and orthopedic surgeons.

**Key words:** psoriatic arthritis, hip arthroplasty, knee arthroplasty, foot diseases, orthopedic procedures, psoriasis arthropatica.

### Introduction

Psoriatic arthritis (PsA) is a debilitating seronegative arthropathy with many different clinical and radiographic manifestations [1]. Psoriatic arthritis is typically diagnosed in people aged 40 to 50 years, but it also occurs in younger adults and children [2]. Psoriatic arthritis affects 7% to 48% of patients with psoriasis [2, 3]. Usually, PsA follows the onset of psoriasis, but sometimes it develops before psoriatic skin lesions [2]. Notably, patients with psoriasis and without PsA may have subclinical bone changes, such as bone formation in joint entheses [4].

Psoriatic arthritis is diagnosed according to the Classification Criteria for Psoriatic Arthritis (CASPAR) [5]. In Europe and North America, the diagnosis of PsA is missed in more than one-third of patients with psoriasis [6]. Physicians should diagnose PsA early because delaying diagnosis, even by 6 months, increases the risks of joint erosions and poor long-term physical function [7]. Early diagnosis enables prompt treat-

ment initiation, which improves clinical outcomes and reduces both disease severity and joint damage [5]. To improve the detection of PsA, one can evaluate the four following symptoms: peripheral inflammatory pain, axial inflammatory pain, dactylitis, and buttock and sciatic pain. In particular, one might focus on those patients with psoriasis with nail dystrophy, scalp involvement, extensive skin involvement, and intergluteal or perianal lesions [5].

Symptoms of PsA are heterogeneous [8]. Table I presents different clinical subtypes of PsA, including enthesitis [8–15]. In up to 60% of patients, PsA begins with oligoarthritis ( $\leq 4$  joints), but it may affect more joints as the disease progresses (polyarthritis,  $\geq 5$  joints) [10]. Dactylitis is characteristic of PsA; it affects feet more often than hands (65% vs. 24%). Only 12% of patients with PsA have dactylitis both in feet and hands [13]. Dactylitis carries a risk of more aggressive disease in the affected fingers [14]. Patients with PsA often have inflamed entheses (enthesitis) [10]. Evidence supports the hypothesis that PsA-associated inflammation begins in entheses [15], which are exposed not only to biochemical stress, but also to repeated micro-trauma [4]. In genetically pre-

disposed individuals, micro-trauma to entheses may lead to inflammation [1], which then spreads to surrounding structures, particularly to the nail matrix and synovium [1, 15].

Clinical examination is crucial to diagnose PsA. On clinical examination, joints affected by PsA are usually painful and tender, but swelling does not always occur. Moreover, patients often have morning stiffness [9, 10]. In addition to clinical examination, new imaging techniques can now be used in daily practice to improve the diagnosis of PsA (Table II) [8, 9, 14, 16].

Because patients with PsA have heterogeneous symptoms, they often need the care of many specialists. When joint inflammation precedes psoriasis, PsA might be difficult to diagnose. Imaging and laboratory studies can help rule out rheumatoid arthritis, spondyloarthritis, osteoarthritis, and reactive arthritis [17–19]. Analysis of synovial fluid can help diagnose gout, chondrocalcinosis, and septic arthritis [17–19].

Patients with psoriasis often seek assistance in orthopedic clinics. Among patients with PsA, Haque *et al.* reported that 36% of orthopedic operations and ~10% of diagnostic arthroscopies were done before the diagnosis of PsA [20].

Table I. Subtypes of PsA and enthesitis [8–15]

Subtype of psoriatic arthritis	Characteristics
Symmetrical polyarthritis	<ul style="list-style-type: none"> <li>• <math>\geq 5</math> joints are involved</li> <li>• Symmetrical joint involvement</li> <li>• Occurs typically in small joints of hands and feet</li> <li>• Less common in large joints</li> <li>• More common in women</li> </ul>
Asymmetrical oligoarthritis	<ul style="list-style-type: none"> <li>• Asymmetric joint involvement of <math>&lt; 5</math> joints</li> <li>• Occurs in distal interphalangeal joints, large joints, feet</li> <li>• Typical early knee involvement</li> <li>• More common in men</li> </ul>
Distal interphalangeal predominant arthritis	<ul style="list-style-type: none"> <li>• Symmetric or asymmetric</li> <li>• Affects few or many distal interphalangeal joints</li> <li>• <math>&gt; 50\%</math> of all affected joints are distal interphalangeal joints</li> <li>• Leads to progressive bony lesions</li> </ul>
Arthritis mutilans	<ul style="list-style-type: none"> <li>• The most severe and destructive form of psoriatic arthritis</li> <li>• Finger shortening with severe osteolysis on imaging studies</li> <li>• Pencil-in-cup changes, total joint erosion, ankylosis, subluxation</li> <li>• Leads to irreversible deformity and loss of functional independence</li> </ul>
Predominant spondyloarthropathy	<ul style="list-style-type: none"> <li>• Degenerative changes and inflammation of sacroiliac joints and apophyseal joints of the spine</li> <li>• Radiographic sacroiliitis</li> <li>• Typically localized in lumbar spine</li> <li>• Inflammatory backache</li> </ul>
Enthesitis	<ul style="list-style-type: none"> <li>• Present in 23% to 53% of patients with psoriatic arthritis, prominent in 38% of patients</li> <li>• More frequent in lower extremities</li> <li>• Might be asymptomatic in the early stages of psoriatic arthritis</li> <li>• Can cause severe, disabling pain, particularly in lower extremities</li> <li>• Tenderness over entheses or occasional soft tissue swelling may be found on physical examination</li> <li>• Typically localized in Achilles tendon, plantar fascia, greater trochanter</li> </ul>

**Table II.** Radiologic findings in PsA [8, 9, 14, 16]

Radiologic findings in psoriatic arthritis	
X-ray	<ul style="list-style-type: none"> <li>• Soft tissue swelling – sausage fingers</li> <li>• New bone formation with “fuzzy” appearance</li> <li>• Periostitis</li> <li>• Periarticular osteoporosis</li> <li>• Joint destruction with erosions</li> <li>• Joint space narrowing</li> <li>• Ankylosis</li> <li>• Distal phalanx bone resorption</li> </ul>
Ultrasound	<ul style="list-style-type: none"> <li>• Synovitis</li> <li>• Tenosynovitis</li> <li>• Subcutaneous soft tissue thickening</li> <li>• Inflammation of entheses</li> <li>• Thickening and erosions of entheses</li> </ul>
Magnetic resonance imaging	<ul style="list-style-type: none"> <li>• Cartilage degeneration</li> <li>• Bone erosions</li> <li>• Synovial proliferation</li> <li>• Synovitis</li> <li>• Tenosynovitis</li> <li>• Bone marrow edema</li> </ul>

Moreover, the involvement of large joints, such as the hip and knee, impairs activities of daily living in patients with PsA. To maintain daily function, patients need individualized therapy, which may include surgical management [20].

Here, we review current data regarding orthopedic management of diseases of the lower extremities in patients with PsA.

### Orthopedic interventions in PsA

At first, PsA was considered to be a less severe disease than rheumatoid arthritis, but we know now that PsA is more aggressive than initially thought. Structural damage in PsA includes not only bone erosions and cartilage loss but also new bone formation and joint remodeling. Severe osteolysis leads to the development of arthritis mutilans [20, 21]. In most patients, PsA is treated pharmacologically with non-steroidal anti-inflammatory drugs (NSAIDs), disease-modifying anti-rheumatic drugs (DMARDs), and biologic agents [22]. In PsA, biologic therapy improves the control of inflammation, inhibits both the formation of joint erosions and joint destruction, and improves joint function [8, 21]. When pharmacological treatment is insufficient, patients with degenerative joint changes may benefit from surgical treatment, which can improve quality of life and restore or maintain joint function. However, surgery does not change the natural course of PsA. Patients receiving DMARDs alone or combined with tumor necrosis factor  $\alpha$  (TNF- $\alpha$ ) inhibitors may need orthopedic intervention at some stage of the disease [20].

In PsA, joint destruction involves cartilage, ligaments, synovium, and bones [8, 20]. Because cartilage has a very limited healing ability, surgeons

should preserve hyaline cartilage [23]. Operations preserving joints aim to restore normal joint axis and joint stability. They involve correction of both intra-articular and extra-articular abnormalities. Total joint arthroplasty is the best treatment for end-stage arthritis in the hip and knee joints; it improves the range of motion and reduces joint pain. Due to limited evidence, we do not know what surgery to choose in particular patients with PsA (Table III) [20, 24–35]. Qualifying patients with PsA for surgery needs an individualized approach and the involvement of dermatologists, rheumatologists, and orthopedic surgeons. Joints that are most painful or most functionally important should be corrected first. Adequate surgical correction of lower extremity joints can restore ambulation and improve pain in patients with PsA.

When planning surgery in patients with PsA, one must remember that injury and stress related to the procedure may lead to a psoriatic outbreak or exacerbations [8, 22, 33]. There are limited data about the Koebner phenomenon after surgery [8, 22, 33]. Postoperative infections can be avoided with adequate skin preparation before surgery [35]. Because post-operative sepsis after Charnley low-friction arthroplasty was more frequent in patients with psoriasis ( $n = 38$ ) than in patients with osteoarthritis, prophylactic antibiotic therapy was recommended [32]. It is recommended not to operate through psoriatic plaques [8]. Postoperative infections and impaired wound-healing are a concern in patients who receive biologic agents, methotrexate, or cyclosporine. Recommendations for perioperative adjustment of pharmacological treatment in patients with PsA are listed in Table IV [36–39].

### Hip

Psoriatic hip arthropathy is uncommon, but it is associated with an early onset of PsA [29]. Patients often have bilateral hip arthropathy and, due to rapid joint destruction, need hip arthroplasty at a young age [29, 39]. Haque *et al.* [20] and Michet *et al.* [29] observed that the mean duration of PsA at the time of arthroplasty was about 5–5.5 years. However, Zangger *et al.* reported that the need for surgical intervention increases with disease progression [25]. Total hip arthroplasty (THA) is the most common joint-sacrificing procedure in PsA, and it is recommended in patients with end-stage arthritis and significant disability [20, 25, 27]. Total hip arthroplasty reduces pain and improves joint function (Figure 1 A, B) [8].

Among patients with PsA, indications for THA include severe joint damage assessed with the Steinbrocker grading system, a higher number of actively involved joints, and severe pain at rest or when walking [8, 25, 30]. Total hip arthroplasty is performed most commonly in patients with polyar-

**Table III.** Orthopedic procedures in lower extremities in patients with PsA or psoriasis, including indications, likely outcomes, and potential complications [20, 24–33]

Procedure	Indications	Benefits	Potential complications
Synovectomy [20, 24, 25]	Synovitis, persistent joint effusion	Removal of inflammatory synovium, decrease in proinflammatory cytokines, and effusion control	Side effects were not reported [20, 24, 25] Potential complications include infection, hematoma, and joint contractures [26]
Osteotomy [27]	Joint malalignment	Restoration of mechanical properties of joints	Complications were not reported in patients with psoriatic arthritis [27] Potential complications include infection, hematoma, persistent pain, over- and undercorrection [26]
Debridement [28]	Loose bodies, degenerative changes of labrum, menisci, or articular cartilage	Decrease in proinflammatory cytokines	Complications were not reported in patients with psoriatic arthritis [28]. Potential complications include infection, hematoma, iatrogenic joint destruction [26]
Tissue reconstruction [20] (ligaments, menisci, labrum, cartilage)	Ligament insufficiency, chondral defects, labral tears, meniscus tears	Restoration of mechanical properties of joints	Complications were not reported in patients with psoriatic arthritis [20]. Potential complications include infection, hematoma, iatrogenic joint destruction
Arthrodesis [20, 25, 29]	Painful end-stage arthrosis in patients with contraindications to arthroplasty	Painless weight-bearing joints	The following have been reported: delayed bone union, nonunion of arthrodesis, Koebner phenomenon [25, 28]. Potential surgical side effects include loss of motion in adjacent joints, infection, malalignment, hematoma, persistent pain, deep venous thrombosis [26]
Arthroplasty [29–33]	Painful end-stage arthrosis	Restoration of painless range of motion in joints	Reported complications [32, 33] include infection, pulmonary embolism, paralytic ileus, deep venous thrombosis, exacerbation of psoriasis (similar risk as in the general population). Potential complications include periprosthetic fractures, hematoma, implant failure, osteolysis, dislocation [26]

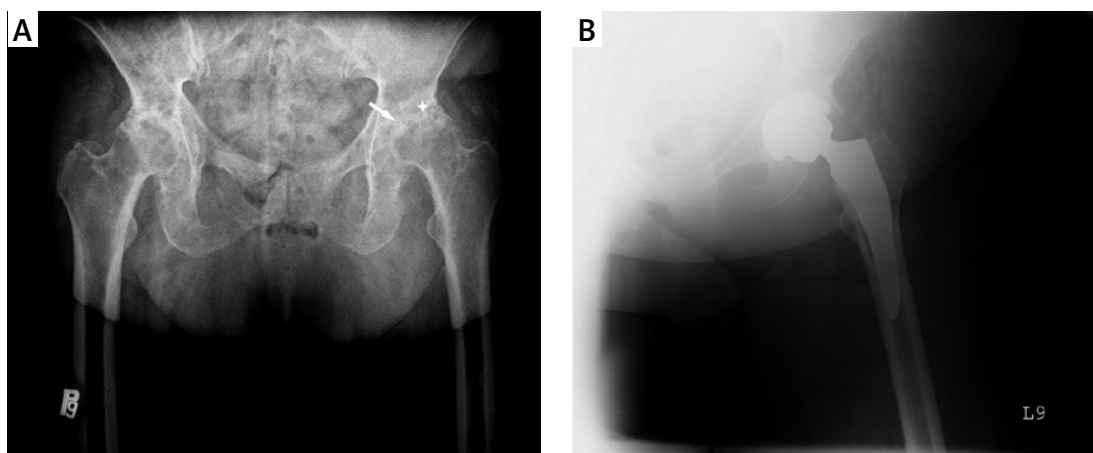
ticular PsA, but also in patients with oligoarticular PsA [20, 27] or spondylitis predominant PsA [20, 29].

In patients with PsA, joint pain might be caused by conditions other than PsA, particularly by osteoarthritis (OA). Osteoarthritis coexists with psoriasis, particularly in patients aged > 70 years, and these patients require specific treatment protocols [31, 32, 40]. Mandl *et al.* analyzed data of patients who underwent THA, including 63 patients with PsA, 153 patients with psoriasis, and 915 patients with OA who served as controls [31]. There were no differences in preoperative and postoper-

ative WOMAC pain scores (Western Ontario and McMaster Universities OA Index) between the three groups. Thus, it seems that neither PsA nor psoriasis are independent risk factors for poor postoperative function or joint pain after THA [21]. In contrast, previous studies reported that postoperative outcomes after THA were worse in patients with PsA than in other patients [27, 40]. Hip surgery is performed increasingly often in young patients, which could be due to improper qualification of patients. Patients with polyarticular PsA or with spondylitis-predominant PsA

**Table IV.** Recommendations for medication adjustment before orthopedic surgery in patients with PsA

Study	Medication			
Smith <i>et al.</i> [36]	Discontinuation of biologic therapy prior to surgery			
	Infliximab 4–6 weeks	Adalimumab 6–8 weeks	Etanercept 2 weeks	Ustekinumab 12 weeks
	Therapy may be restarted postoperatively when there is no evidence of infection and wound healing is satisfactory			
Ohtsuki <i>et al.</i> [37]	Surgery feasible after a necessary time from last dose			
	Infliximab 4 weeks	Adalimumab 2 weeks	Etanercept no data	Ustekinumab 8 weeks
	Therapy may be restarted postoperatively when there is no evidence of infection and the wound has healed			
Ossorio <i>et al.</i> [38]	Discontinuation of biologic therapy prior to surgery			
	Infliximab 6 weeks	Adalimumab 2 weeks	Etanercept 1 week	Golimumab/ certolizumab/ tocilizumab 4 weeks
	Therapy may be restarted postoperatively when there is no evidence of infection and the wound has healed			
	Cyclosporine A should be stopped one week before orthopedic surgery and reintroduced 2 weeks after the surgery			
Sreekumar <i>et al.</i> [39]	Methotrexate should not be stopped before elective orthopedic surgery in patients with disease controlled on methotrexate before surgery			



**Figure 1.** A – Preoperative radiograph of a 65-year-old woman admitted to the hospital for total hip replacement shows severe joint space narrowing (white arrow), bone erosions (white star), and migration of femoral head. There are no osteophytes, which are characteristic of osteoarthritis. B – Radiograph obtained after total hip arthroplasty

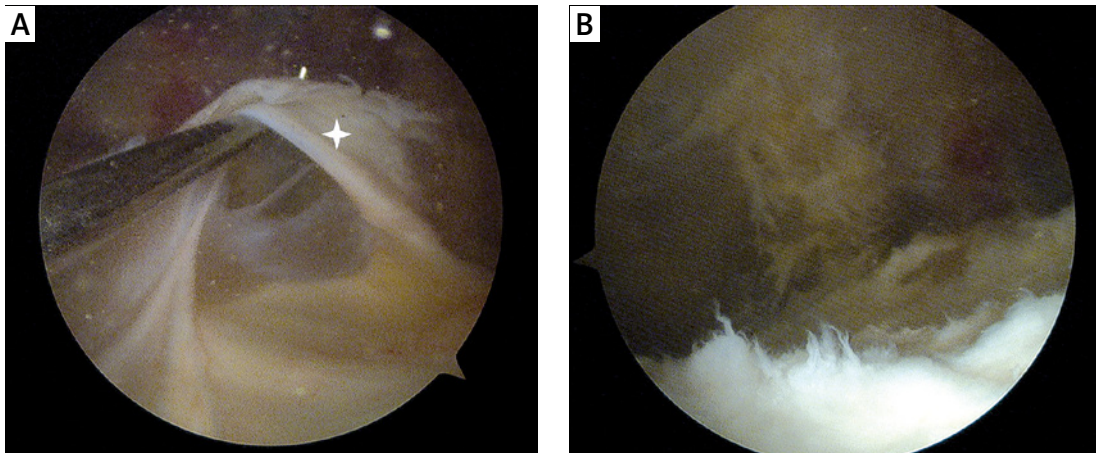
should be assessed for radiographic joint changes and loss of joint function to reduce the need for surgery [20].

### Knee

With the aging of the population, the number of patients with osteoarthritis of the knee has increased dramatically [41]. In patients with PsA, the knee might be affected early, particularly in patients with asymmetric oligoarthritis or polyarthritis [10, 24]. Knee involvement causes severe pain, restricted movement, instability, and pro-

gressive loss of joint function. After hip surgery, knee surgery is the most common orthopedic procedure in patients with PsA [8, 20, 25, 27].

Arthroscopic synovectomy is recommended to minimize surgical trauma in patients with severe knee pain and symptoms of joint inflammation. Arthroscopic synovectomy is feasible in patients with both short- and long-lasting knee joint synovitis, radiographic Larsen grades I–II, and different degrees of cartilage damage [24, 40, 42]. Arthroscopic synovectomy is safe. Combined with pharmacological therapy, it can preserve knee



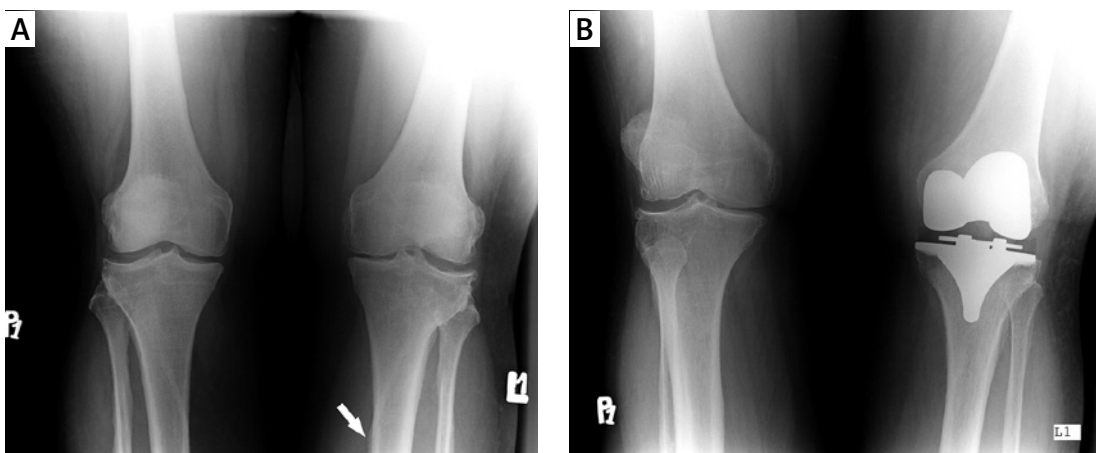
**Figure 2.** **A** – A 22-year-old man with pain in the patellofemoral joint. Arthroscopic appearance of a thickened fibrous synovial fold (white star) in the suprapatellar pouch, which conflicted with the patella. **B** – Arthroscopic view after removal of the synovial fold. After surgery, the patient regained a full pain-free range of movement in the affected knee

joint motion range and reduce local joint inflammation in patients with PsA [24, 42]. Moreover, good long-term outcomes were observed in patients with PsA with severe cartilage damage in the knee [24]. Long-term outcomes of arthroscopic synovectomy in PsA have not been assessed in large studies. However, arthroscopic synovectomy seems promising because it reduces pain, slows down disease progression, and delays the need for total knee replacement (Figures 2 A, B) [24, 40].

Total knee arthroplasty (TKA) is indicated in patients with end-stage knee destruction, severe pain, and disability [8]. Michet *et al.* suggested that patients with severe hip arthropathy are more likely to undergo TKA compared with patients without hip involvement [29]. Total knee arthroplasty is done most commonly in patients with asymmetric oligoarthritis, followed by patients with symmetric polyarthritis and peripheral or axial PsA. The mean duration of PsA

at the time of TKA is about 8 years [20]. Studies evaluating long-term outcomes of TKA in PsA are few and were done more than two decades ago [43]. It is difficult to compare TKA outcomes between early and recent studies because the enrolled patients differ in local disease severity, type of surgical procedure, and pharmacological treatment [20].

Intra-articular injuries need prompt orthopedic management in patients with PsA. In a meta-analysis, Edd *et al.* [44] found that intra-articular trauma induces inflammation in joints. This can lead to or accelerate osteoarthritic changes, particularly in patients with predisposing factors, such as inflammatory diseases [36]. Thus, articular damage can progress fast in patients with PsA. Certain conditions, such as rupture of the anterior cruciate ligament or torn meniscus, need faster surgical treatment in patients with PsA compared with healthy people [44] (Figures 3 A, B).



**Figure 3.** **A** – An anterior-posterior radiograph obtained in a 69-year-old woman with severe osteoarthritis of the left knee. There is “fuzzy” bone proliferation in the tibial shaft (white arrow). **B** – The same view after total knee replacement. Postoperatively, the pain-free range of movement in the knee was 0–120°

In patients with PsA and knee involvement, surgery is considered when optimal medical therapy has failed or when knee injury occurs. Patients after THA need careful monitoring because they are prone to develop severe knee arthritis, which might require TKA. It is worth adding that some patients with PsA have been treated effectively with a hyaluronic acid based formula [45].

### Foot and ankle

Foot abnormalities are observed in 50% to 70% of patients with PsA [46]. Moreover, foot abnormalities, such as dactylitis, tenosynovitis, enthesitis, and joint inflammation, might be the first symptoms of PsA. In the study of Bezza *et al.* [46], 53% of patients with PsA had isolated hindfoot involvement, and 14% had isolated forefoot involvement. In patients with isolated hindfoot involvement, pain in the inferior or posterior parts of the heel is typical. Clinical manifestations of forefoot involvement include inflammatory metatarsal pain, claw toe deformity, and arthritis mutilans of the toe [46]. Dactylitis is an important symptom of PsA, and it affects feet more commonly than hands [13, 46]. In patients with PsA, dactylitis carries the risk of being a more aggressive disease [14].

There are no clear indications for orthopedic interventions in patients with PsA who have foot abnormalities. Foot orthoses or corrective footwear might help prevent formation of foot deformities. Both in patients with rheumatoid arthritis and those with PsA, splints can stabilize and immobilize the hindfoot and ankle, particularly in patients with arthritis or enthesitis. Functional foot orthoses might correct foot deformities, protect foot joints, and reduce mechanical stress in soft tissues. Enthesitis is treated pharmacologically with NSAIDs, DMARDs, and biologic agents [47]. Moreover, steroids can be injected under ultrasound

guidance into the site of the most pronounced inflammation [47].

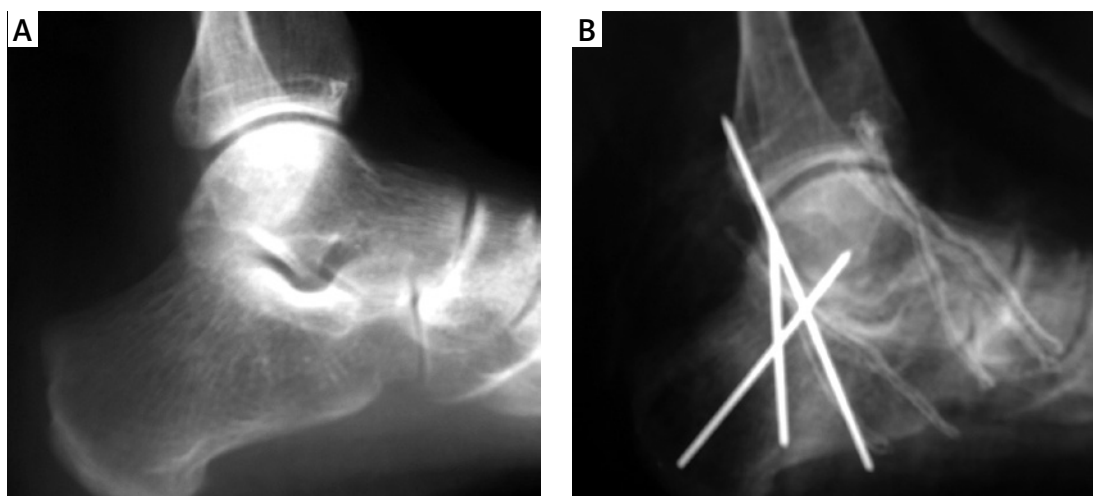
Surgery can be considered in patients with PsA and foot abnormalities who do not respond well to conservative treatment or have persistent pain. Arthrodesis is the most common surgery used to treat patients with ankle arthropathy. Arthroplasty is indicated in patients with involvement of the forefoot or toe joints (Figures 4 A, B) [8].

There is little evidence regarding orthopedic operations in patients with PsA who have ankle and foot involvement. In the study of Haque *et al.*, over a 14-year period of observation, only 2 patients with PsA had ankle prostheses, and 40 patients underwent joint-preserving surgery due to foot and hand abnormalities [20]. Hicken *et al.* [28], during a 15-year period, observed 17 patients with PsA who underwent multiple foot and ankle operations, among which forefoot arthroplasty was the most common. In that study, 89% of the patients were satisfied with surgery outcomes. Moreover, the patients did not have clinical disease progression and did not need additional interventions [28].

Foot or ankle involvement rarely requires surgical intervention in patients with PsA. Among patients with PsA, those with symmetric polyarthritis are more likely to benefit from foot or ankle surgery [27]. In patients with psoriasis, foot involvement might be the first manifestation of PsA, and the development of foot abnormalities requires a change in treatment.

### Physiotherapy

Physiotherapy is important in the management of PsA. It may be used in addition to pharmacological treatment, particularly in patients with enthesitis and axial disease [22]. The main goals of physiotherapy are to reduce pain and stiffness, prevent or delay deformity, and restore function



**Figure 4.** A – Subtalar sclerotisation in 30-year old man, B – postoperative lateral radiograph shows Kirchner wires used to preserve articular surface after arthrodesis

in the affected joints. To date, few studies have assessed the place of physiotherapy in PsA [48]. Different exercise regimens aim to restore muscle strength and reduce joint deformity. Different patients with PsA need different physiotherapy approaches [48]. For patients with predominant peripheral PsA, Lubrano *et al.* proposed a rehabilitation scheme that includes exercises to improve muscle strength and general fitness. The scheme also includes stretching exercises, occupational therapy, and patient education. In patients with predominant axial involvement, postural and breathing exercises are recommended [48].

### Pharmacological treatment

Discovery of novel immunologic pathways important for the development of psoriasis or PsA

resulted in many new therapies that target those pathways (Table V) [49–52]. These new therapies are considered safe, with common side effects including injection-site reactions and infections (e.g. for adalimumab, etanercept, infliximab), *Candida* infections (e.g. for ixekizumab, secukinumab) or weight loss and diarrhea (for apremilast) [52]. However, there are still patients with PsA who do not achieve the ACR 20 composite joint outcome [49]. It cannot be excluded that in the future, similar to rheumatoid arthritis, novel therapies will be directed toward molecular and cellular targets [53].

### Summary

Management of PsA should be individualized for each patient. NSAIDs, DMARDs, and biologic agents are the mainstay of treatment for patients with PsA.

**Table V.** Novel therapeutic options for PsA (biological medicinal products) [49–52]

Agent	Mechanism of action	Indications	Outcomes
Etanercept	dimeric p75 TNF- $\alpha$ receptor Fc fragment fusion protein	Severe peripheral PsA in patients with erosive disease and functional limitation	Limit joint damage, restore joint function Reduce radiographic progression
Adalimumab	human monoclonal antibody against TNF- $\alpha$	Moderate to severe axial disease Severe dactylitis affecting many digits or with functional limitation	Comparable efficiency of all conventional TNF-inhibitors Therapy can be switched from one to another TNF inhibitor
Infliximab	human/mouse chimeric anti-TNF- $\alpha$ antibody	Enthesitis	
Certolizumab pegol	Pglylated Fab fragment of humanized anti-TNF monoclonal antibody	Choice of agent based on patient's preferences for drug administration	
Golimumab	Fully human anti-TNF IgG monoclonal antibody		
Secukinumab	Human anti-IL17A monoclonal antibody	Peripheral arthritis resistant to TNF inhibitor Enthesitis and dactylitis	Reduces radiographic progression compared with placebo Reduces the frequency of enthesitis and dactylitis
Ixekizumab	Anti-IL-17A monoclonal antibody	Recommended for plaque psoriasis Efficiency for PsA demonstrated in several clinical trials	Reduces radiographic progression; improves physical function Improves skin lesions
Ustekinumab	Human monoclonal antibody to the shared p40 subunit of IL-12 and IL-23	Peripheral and axial PsA resistant to initial TNF inhibitor Enthesitis, dactylitis	Effective and safe Reduces radiographic progression of joint injury and improve joint function
Tofacitinib	Inhibitor of Janus kinase (JAK)	PsA in patients with inadequate response or intolerance to MTX or other DMARDs Peripheral arthritis	Improves physical function
Abatacept	CTLA4-Ig a selective T-cell costimulation modulator	PsA Recommended when other drugs have failed or are contraindicated	Improves changes in MRI of affected joints in the hands or feet
Apremilast	Phosphodiesterase-4 inhibitor	PsA and nonerosive inflammatory arthritis with multiple comorbidities Early stage of enthesitis and dactylitis Recommended for patients who prefer oral drug administration	Good safety profile Not recommended for patients with erosive arthritis



Surgical treatment can be beneficial in patients with severe and progressive pain, disability, restricted hip movements, hip or knee joint instability, and progressive loss of functional independence. Orthopedic procedures should be considered only when the best medical treatment has failed. Dermatologists, rheumatologists, and orthopedic surgeons should work together to ensure that patients with PsA receive the best possible treatment.

### Acknowledgments

This paper was supported by Medical University of Lublin grant DS-168.

### Conflict of interest

The authors declare no conflict of interest.

### References

1. FitzGerald O, Haroon M, Giles JT, Winchester R. Concepts of pathogenesis in psoriatic arthritis: genotype determines clinical phenotype. *Arthritis Res Ther* 2015; 17: 115.
2. Liu JT, Yeh HM, Liu SY, Chen KT. Psoriatic arthritis: epidemiology, diagnosis, and treatment. *World J Orthop* 2014; 5: 537-43.
3. Feldmann SR. 2015 Epidemiology, clinical manifestations, and diagnosis of psoriasis. [WWW document]. Available from <http://www.uptodate.com/contents/epidemiology-clinical-manifestations-and-diagnosis-of-psoriasis> [accessed on 01. January 2017].
4. Simon D, Faustini F, Kleyer A, et al. Analysis of periarticular bone changes in patients with cutaneous psoriasis without associated psoriatic arthritis. *Ann Rheum Dis* 2016; 75: 660-6.
5. Villani AP, Rouzaud M, Sevrain M, et al. Symptoms dermatologists should look for in daily practice to improve detection of psoriatic arthritis in psoriasis patients: an expert group consensus. *J Eur Acad Dermatol Venereol* 2014; 28 Suppl 5: 27-32.
6. Mease PJ, Gladman DD, Papp KA, et al. Prevalence of rheumatologist-diagnosed psoriatic arthritis in patients with psoriasis in European/North American dermatology clinics. *J Am Acad Dermatol* 2013; 69: 729-35.
7. Haroon M, Gallagher P, FitzGerald O. Diagnostic delay of more than 6 months contributes to poor radiographic and functional outcome in psoriatic arthritis. *Ann Rheum Dis* 2015; 74: 1045-50.
8. Day MS, Nam D, Goodman S, Figgie M. Psoriatic arthritis. *J Am Acad Orthop Surg* 2012; 20: 28-37.
9. Strauss EJ, Alfonso D, Baidwan G, Di Cesare PE. Orthopedic manifestations and management of psoriatic arthritis. *Am J Orthop (Belle Mead NJ)* 2008; 37: 138-47.
10. Dhir V, Aggarwal A. Psoriatic arthritis: a critical review. *Clin Rev Allergy Immunol* 2013; 44: 141-8.
11. Acosta Felquer ML, FitzGerald O. Peripheral joint involvement in psoriatic arthritis patients. *Clin Exp Rheumatol* 2015; 33 (Suppl 93): S26-30.
12. Sakkas LI, Alexiou I, Simopoulou T, Vlychou M. Enthesitis in psoriatic arthritis. *Semin Arthritis Rheum* 2013; 43: 325-34.
13. Brockbank JE, Stein M, Schentag CT, Gladman DD. Dactylitis in psoriatic arthritis: a marker for disease severity? *Ann Rheum Dis* 2005; 64: 188-90.
14. Healy PJ, Groves C, Chandramohan M, Helliwell PS. MRI changes in psoriatic dactylitis-extent of pathology, relationship to tenderness and correlation with clinical indices. *Rheumatology (Oxford)* 2008; 47: 92-5.
15. McGonagle D. Enthesitis: an autoinflammatory lesion linking nail and joint involvement in psoriatic disease. *J Eur Acad Dermatol Venereol*. 2009; 23 Suppl 1: 9-13.
16. Greenspan A. *Orthopedic Imaging: A Practical Approach*. Fifth North American Edition, 2<sup>nd</sup> Polish Edition (Sąsiadek M. eds), Warszawa, Wolters Kluwer, 2011.
17. Wu IB, Schwartz RA. Reiter's syndrome: the classic triad and more. *J Am Acad Dermatol* 2008; 59: 113-21.
18. Majewski S, Wydrzynska A, Owczarek W, Schwartz RA. Reactive arthritis-like pattern in HIV-positive patient with psoriasiform dermatitis. *HIV AIDS Rev* 2011; 10: 44-6.
19. Napolitano M, Caso F, Scarpa R, et al. Psoriatic arthritis and psoriasis: differential diagnosis. *Clin Rheumatol* 2016; 35: 1893-901.
20. Haque N, Lories RJ, de Vlam K. Orthopaedic interventions in patients with psoriatic arthritis: a descriptive report from the SPAR cohort. *RMD Open* 2016; 2: e000293
21. Gladman DD, Antoni C, Mease P, Clegg D, Nash P. Psoriatic arthritis: epidemiology, clinical features, course, and outcome. *Ann Rheum Dis* 2005; 64 Suppl 2: 14-7.
22. Ritchlin CT, Kavanaugh A, Gladman DD, et al. Treatment recommendations for psoriatic arthritis. *Ann Rheum Dis* 2009; 68: 1387-94.
23. Cibere J, Sayre EC, Guermazi A, et al. Natural history of cartilage damage and osteoarthritis progression on magnetic resonance imaging in a population-based cohort with knee pain. *Osteoarthritis Cartilage* 2011; 19: 683-8.
24. Fiocco U, Cozzi L, Rigon C, et al. Arthroscopic synovectomy in rheumatoid and psoriatic knee joint synovitis: long-term outcome. *Br J Rheumatol* 1996; 35: 463-70.
25. Zangger P, Gladman DD, Bogoch ER. Musculoskeletal surgery in psoriatic arthritis. *J Rheumatol* 1998; 25: 725-9.
26. Azar FM, Canale T, Beatty JH. *Campbell's Operative Orthopaedics*. 13<sup>th</sup> edition. Elsevier 2016.
27. Zangger P, Esufali ZH, Gladman DD, Bogoch ER. Type and outcome of reconstructive surgery for different patterns of psoriatic arthritis. *J Rheumatol* 2000; 27: 967-74.
28. Hicken GJ, Kitoaka HB, Valente RM. Foot and ankle surgery in patients with psoriasis. *Clin Orthop Relat Res* 1994; 300: 201-6.
29. Michet CJ, Mason TG, Mazlumzadeh M. Hip joint disease in psoriatic arthritis: risk factors and natural history. *Ann Rheum Dis* 2005; 64: 1068-70.
30. Maejima H, Watarai A, Taniguchi T, Katsuoka K. Onset of psoriatic arthritis at the hip joint without spondylitis. *Acta Derm Venereol* 2014; 94: 110-1.
31. Mandl LA, Zhu R, Huang WT, et al. Short-term total hip arthroplasty outcomes in patients with psoriatic arthritis or psoriatic skin disease compared to patients with osteoarthritis. *Arthritis Rheumatol* 2016; 68: 410-7.
32. Menon TJ, Wroblewski BM. Charnley low-friction arthroplasty in patients with psoriasis. *Clin Orthop Relat Res* 1983; 176: 127-8.
33. Beyer CA, Hanssen AD, Lewallen DG, Pittelkow MR. Primary total knee arthroplasty in patients with psoriasis. *J Bone Joint Surg Br* 1991; 73: 258-9.
34. Gordon A, Hosam M, Wilkinson MM. Hip and Knee Arthroplasty in the Patient with Inflammatory Arthritis in Arthroplasty – Update (Plamen Kinov eds.), 2013, InTech, DOI: 10.5772/54743. Available from: <https://www.intechopen.com/books/arthroplasty-update/>

- hip-and-knee-arthroplasty-in-the-patient-with-inflammatory-arthritis (last accessed 30 May 2017).
35. Jadon DR, McHugh NJ. Other seronegative spondyloarthropathies. *Medicine* 2014; 42: 257-61.
  36. Smith CH, Anstey AV, Barker JN, et al. British Association of Dermatologists' guidelines for biologic interventions for psoriasis. *Br J Dermatol* 2009; 161: 987-1019.
  37. Ohtsuki M, Terui T, Ozawa A, et al. Biologics Review Committee of the Japanese Dermatological Association. Japanese guidance for use of biologics for psoriasis (the 2013 version). *J Dermatol* 2013; 40: 683-95.
  38. Ossorio JS, Peregrina-Palomares M, O'Valle Ravassa F, Hernandez-Cortes P. Perioperative management of non-biological and biological therapies in rheumatic patients undergoing orthopedic surgery. In: *Challenges in Rheumatology*, (Harjacek M. eds). InTech, 2011: 145-54. Available from <https://www.intechopen.com/books/challenges-in-rheumatology/perioperative-management-of-non-biological-and-biological-therapies-in-rheumatic-patients-undergoing> (last accessed 30 May 2017).
  39. Sreekumar R, Gray J, Kay P, Grennan DM. Methotrexate and postoperative complications in patients with rheumatoid arthritis undergoing elective orthopaedic surgery: a ten year follow-up. *Acta Orthop Belg* 2011; 77: 823-6.
  40. Lofin J, Levine B, Badlani N, Klein GR, Jaffe WL. Psoriatic arthritis and arthroplasty: a review of the literature. *Bull NYU Hosp Jt Dis* 2008; 66: 41-8.
  41. Liu Y, Meng F, Yang G, Kong L, Shen Y. Comparison of intra-articular versus intravenous application of tranexamic acid in total knee arthroplasty: a meta-analysis of randomized controlled trials. *Arch Med Sci* 2017; 13: 533-40.
  42. Linschoten NJ, Krackov KA. Psoriatic arthritis of the knee treated with synovectomy. *Orthopedics* 1993; 16: 1268-70.
  43. Stern SH, Insall JN, Windsor RE, Inglis AE, Dines DM. Total knee arthroplasty in patients with psoriasis. *Clin Orthop Relat Res* 1989; 248: 108-10.
  44. Edd SN, Giori NJ, Andriacchi TP. The role of inflammation in the initiation of osteoarthritis after meniscal damage. *J Biomech* 2015; 48: 1420-6.
  45. Chen LH, Xue JF, Zheng ZY, Shuhaidi M, Thu HE, Husain Z. Hyaluronic acid, an efficient biomacromolecule for treatment of inflammatory skin and joint diseases: a review of recent developments and critical appraisal of preclinical and clinical investigations. *Int J Biol Macromol* 2018; 116: 572-584.
  46. Bezza A, Niamane R, Amine B, El Maghraoui A, Bensabbah R, Hajjaj-Hassouni N. Involvement of the foot in patients with psoriatic arthritis. A review of 26 cases. *Joint Bone Spine* 2004; 71: 546-9.
  47. Siddle H, Heliwell DM. Involvement of the foot and ankle in psoriatic arthritis. *CML Rheum* 2009; 28: 49-55.
  48. Lubrano E, Spadaro A, Parsons WJ, Attenu M, Ferrara N. Rehabilitation in psoriatic arthritis. *J Rheumatol Suppl* 2009; 83: 81-2.
  49. Ritchlin CT, Krueger JG. New therapies for psoriasis and psoriatic arthritis. *Curr Opin Rheumatol* 2016; 28: 204-10.
  50. Gladman DD, Ritchlin CT. Treatment of psoriatic arthritis. UpToDate, 2018. available at: <https://www.uptodate.com/contents/treatment-of-psoriatic-arthritis> (accessed: 17.07.2018).
  51. Olszewska B, Adamski Z, Czarnecka-Operacz M. Quo vadis, biological treatment for psoriasis and psoriatic arthritis? *Adv Dermatol Allergol* 2018; 35: 231-7.
  52. Ritchlin CT, Colbert RA, Gladman DD. Psoriatic arthritis. *N Engl J Med* 2017; 376: 957-70.
  53. Sakthiswary R. Novel therapeutic targets in rheumatoid arthritis. *Med Health* 2018; 13: 12-9.