

# Laparoscopic Detorsion and Fertility Preservation in Twisted Ischemic Adnexa – A Single-Center Prospective Study

Devi Balasubramaniam\*, Kavitha Yogini Duraisamy, Malathi Ezhilmani

Department of Endogynecology, GEM Hospital and Research Centre, Coimbatore, Tamil Nadu, India

## Abstract

**Objective:** This study aimed to analyze our experience about the salvageability of ovary in cases of adnexal torsion by laparoscopy, irrespective of the grade of necrosis and number of twists, and to assess the subsequent ovarian viability.

**Materials and Methods:** This is a prospective study conducted in a tertiary care laparoscopic institute. All the cohorts of intraoperative diagnosis of adnexal torsion were included irrespective of the age group from January 2015 to January 2018 over the period of 3 years after obtaining approval from the institute's human ethics committee. Their demographic details and clinical and operative findings were entered after obtaining an informed written consent. All patients underwent laparoscopy except those with a suspicious diagnosis of malignancy. Postoperatively, ovarian viability was assessed by ultrasound Doppler in terms of vascularity and follicular development at 1, 6, and 12 months.

**Results:** A total of 84 patients were included in the study. Acute abdominal pain (71.4%) was the main presenting symptom in all age groups. The total number of cases of adnexal torsion was 69. Adnexal torsion was mainly diagnosed in young and adolescent girls. Out of 46 attempted detorsion, 45 ovaries were preserved (97.8%). Most of the pathologies were benign. All the preserved ovaries were showing follicles and vascularity during ultrasound follow-up.

**Conclusion:** Laparoscopic detorsion of the ovary is the best treatment modality irrespective of the grade of ischemia. Ovarian structure and follicles were preserved following detorsion in all the cases, even in gravely ischemic ovaries.

**Keywords:** Adnexal torsion, detorsion, laparoscopy, ovarian preservation

## INTRODUCTION

Adnexal torsion is the most common surgical emergency in young and reproductive age. The exact incidence is unknown; various studies have reported incidence between 0.3 and 3.5 cases per year.<sup>[1]</sup> Conventionally, the management of choice is excision of the torsed adnexa. The advantage of detorsion of adnexa is clear as it helps to preserve the ovarian function and fertility and reduces the risk of premature ovarian failure. Laparoscopy adds the advantages of improved diagnosis, enhanced patient recovery, and short hospital stay. The main objective of this study was to present and

analyze our experience in preserving the adnexa following laparoscopic detorsion despite apparent severe ischemia.

## MATERIALS AND METHODS

This study was carried out at a tertiary-level laparoscopic center, in the department of endogynecology over a period of 3 years (January 2015–January 2018) after obtaining approval from the official ethical committee of the institution. Ethical approval for this study (GEM/REC/2014) was provided by the

**Address for correspondence:** Dr. Devi Balasubramaniam, GEM Hospital and Research Centre, 45A, Pankaja Mills Road, Ramanathapuram, Coimbatore - 641 045, Tamil Nadu, India.  
E-mail: devibalasubramaniam@gmail.com

### Article History:

Received 31 March 2019

Received in revised form 20 August 2019

Accepted 25 September 2019

Available online 23 January 2020

### Access this article online

#### Quick Response Code:



**Website:**  
www.e-gmit.com

**DOI:**  
10.4103/GMIT.GMIT\_20\_19

This is an open access journal, and articles are distributed under the terms of the Creative Commons Attribution-NonCommercial-ShareAlike 4.0 License, which allows others to remix, tweak, and build upon the work non-commercially, as long as appropriate credit is given and the new creations are licensed under the identical terms.

**For reprints contact:** reprints@medknow.com

**How to cite this article:** Balasubramaniam D, Duraisamy KY, Ezhilmani M. Laparoscopic detorsion and fertility preservation in twisted ischemic adnexa – A single-center prospective study. *Gynecol Minim Invasive Ther* 2020;9:24-8.

Research Ethics Committee of GEM Hospitals and Research Institute, on November 19, 2014. Informed written consent was obtained from all the patients. Patients of all age groups with adnexal torsion were included in the study. Patients with clinical and ultrasound features of torsion, which were not confirmed by surgery, were excluded from the study.

Data regarding patients' demographic details, previous history of pelvic surgery, previous adnexal torsion, triggering factors, duration of symptoms, ultrasonographic (USG) findings, tumor markers, time from the onset of symptoms to surgery, and admission to surgery interval were recorded. Intraoperative findings such as site, side of torsion, grading of ischemia or necrosis, and number of twists were noted. Most of the twisted adnexa were carefully untwisted using nontraumatic instruments irrespective of the grade of ischemia. The ovary was punctured to relieve congestion; if there was any associated pathology, it was surgically removed. Perspective of the grade of ischemia and viability after detorsion was assessed. In selective cases who were liable for recurrent torsion, unilateral or bilateral oophoropexy was done by plication of the ovarian ligament and fixing the ovary to the posterior surface of the uterus using No. 2-0 PDS/Prolene. To reduce the subjective operator bias, surgeries were performed by two laparoscopic gynecologists. All perimenopausal women ( $\geq 40$  years) and patients with preoperative suspicion of malignancy underwent removal of the torsed adnexa irrespective of the grade of ischemia. All patients underwent laparoscopy except for patients with preoperative suspicion of malignancy and with huge ovarian cyst not fitting into the endobag who were taken up for laparotomy.

Grading of ischemia was done based on Parelkar grading, as follows:<sup>[2]</sup>

- Grade 1: Slightly discolored, normal-sized ovary which promptly reverted to normal color after detorsion
- Grade 2: Dark red to brown, mildly enlarged ovary, which became hyperemic with multiple pinpoint petechiae after detorsion
- Grade 3: Brown to black, grossly enlarged ovary with hematoma with slight improvement in color, with small pinpoint oozing after detorsion and hematoma evacuation
- Grade 4: Completely black, grossly enlarged ovary with hematoma and no improvement in color after detorsion and hematoma evacuation.

Following surgery, all the patients were clinically assessed for pain, need for analgesics in the first 24–48 h, and any postoperative complications such as sepsis and thromboembolism.

The main outcome measurement of this study was the rate of salvageability of the ovary following detorsion of the twisted

adnexa irrespective of the grading of ischemia. The secondary outcome measures included were:

- a. Any intraoperative or postoperative complications following laparoscopic detorsion
- b. Postoperatively assessing the viability of ovary with color Doppler in ultrasound.

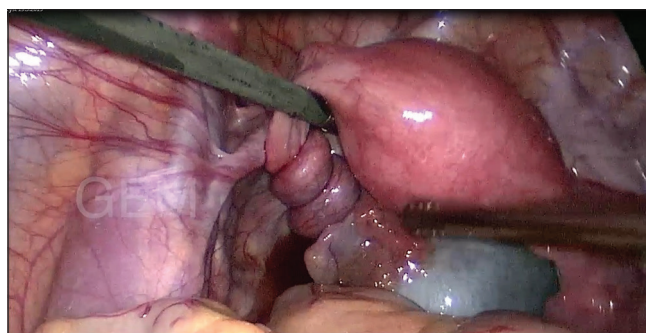
The ovarian viability and structure were assessed by USG with color Doppler in terms of restoration of normal blood flow, normal ovarian volume, and follicular development at 1-, 6-, and 12-month follow-up. If any patient underwent subsequent surgery for unrelated cause, evidence of viability of ovary was assessed by intraoperative documentation of normal appearance of the ovary.

## RESULTS

A total of 84 cohorts with intraoperative diagnosis of torsion were included [Figure 1]. Of these, 69 were adnexal torsion and 15 were isolated fallopian tube torsion. Preoperatively, torsion was not diagnosed in 17 patients. In all age groups, clinical diagnosis was superior to ultrasound in detecting torsion. In age  $<20$  years, 13 were premenarchal and 17 were postmenarchal. Thirty-two cases were in the age group of 20–39 years and 22 cases were aged  $\geq 40$  years [Table 1].

Detorsion was not attempted in all the 22 patients aged  $\geq 40$  years irrespective of the grade of ischemia and cyst size. Among them, two patients had granulosa cell tumor of ovary and three patients who underwent staging laparotomy for preoperative diagnosis of suspicious malignant ovarian tumor had borderline mucinous tumor [Table 2]. The total number of torsion in  $<40$  years' age group was 62, of which, 12 were isolated fallopian tube torsion and the remaining 50 were adnexal torsion. Detorsion was attempted in 46 patients irrespective of the grade of ischemia which succeeded in 45 patients (97.8%) except in one patient for whom intraoperatively the adnexa were completely necrotic with gelatinous appearance and loss of normal architecture. In the remaining four patients, adnexectomy was done in view of a huge ovarian cyst with suspicion of malignancy.

Cystectomy was done along with detorsion in 39 patients, out of which six patients had Grade 4 ischemia with cyst



**Figure 1:** Left adnexal torsion with multiple twists

**Table 1: Clinical details, ultrasonographic findings, and operative data**

Data	<i>n</i>	
Age (years), mean±SD	28.14±12.95	
Married ( <i>n</i> )	48	
Unmarried ( <i>n</i> )	36	
Nullipara ( <i>n</i> )	2	
Associated risk factors		
PCOS	5	
Obesity	3	
Previous history of torsion	2	
Previous history of pelvic surgery		
LSCS	14	
Sterilization	9	
Posthysterectomy	1	
Symptoms		
Acute abdomen±vomiting	60	
Chronic abdominal pain (>7 days)	12	
Fever	10	
Asymptomatic	12	
Clinical diagnosis of torsion ( <i>n</i> )	67	
USG diagnosis of torsion ( <i>n</i> )	17	
USG findings		
Diameter of the cyst (cm), mean±SD	9.255±4.56	
USG Doppler		
Normal vascularity	28	
Low peripheral vascularity	4	
Absent blood flow	6	
CT/MRI done ( <i>n</i> )	9 (torsion diagnosis was confirmed in 2)	
Associated pathology (intraoperative), <i>n</i> (%)	77 (91.6)	
Normal adnexa, <i>n</i> (%)	7 (8.33)	
Time from the onset of symptoms to surgery (days), mean±SD	5.27±15.09	
Time from hospital admission to surgery (h), mean±SD	6.99±21.25	
Intraoperative findings ( <i>n</i> )		
Side of torsion		
Right side	42	
Left side	42	
Number of twists range	partial to 6	
Site of torsion	69	
Ovary		
Isolated fallopian tube	15	
Grading of ischemia		
Grade 1, 2	47	
Grade 3, 4	34	
Gangrenous and friable mass	3	
<b>Salvageability (<i>n</i>)</b>	<b>Detorsion attempted (<i>n</i>=54)</b>	<b>Preserved (%)</b>
Adnexa	46	45 (97.8)
Fallopian tube	9	3 (33.3)

SD: Standard deviation, PCOS: Polycystic ovary syndrome, USG: Ultrasonography, CT: Computed tomography, MRI: Magnetic resonance imaging, LSCS: Lower segment cesarean section

size of 5–10 cm and eight patients had a huge ovarian cyst of >10 cm with low-grade ischemia.

Oophoropexy was done in 37 patients. Bilateral oophoropexy was done in 24 patients which included children, adolescents, and patients with polycystic ovary syndrome. There was no recurrent ovarian torsion in our study. Out of 15 patients with isolated fallopian tube torsion, six underwent salpingectomy even with low-grade ischemia as they have completed their family. Among the remaining nine patients, three tubes with low-grade ischemia were preserved, and we could not preserve the tube for six patients who had Grade 3 and Grade 4 ischemia. There were no intraoperative or postoperative complications, and none had conversion to laparotomy [Figure 2].

Out of 45 salvaged ovaries, ovarian viability was assessed in terms of normal ovarian blood flow, normal ovarian volume, and follicular development with ultrasound Doppler for 44 patients at 1-week, 44 patients at 1-month, 36 patients at 6-month, and 21 patients at 1-year follow-up. All were having normal follicular development and vascularity. Four patients conceived during the follow-up. Six patients underwent subsequent laparoscopy for other benign unrelated cause and intraoperative findings suggestive of healthy normal-sized ovaries.

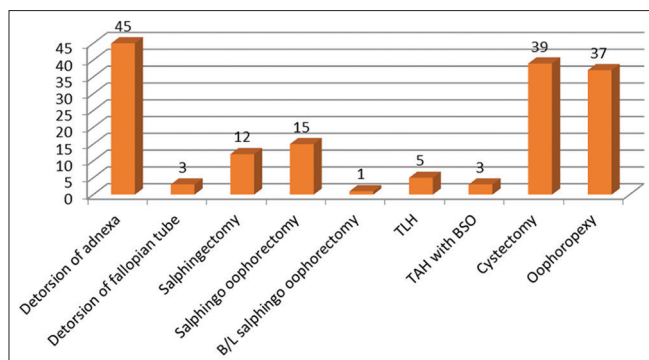
## DISCUSSION

Many recent studies are endorsing detorsion with or without oophoropexy as the treatment of choice for adnexal torsion.<sup>[3,4]</sup> In this prospective study, among the 46 cohorts, we have preserved 97.8% of the ovaries following laparoscopic detorsion. Fady and Shawky in their study showed 100% preservation of twisted ovaries irrespective of ischemia and number of twists, even with apparently necrotic adnexa.<sup>[5]</sup>

In the present study, normal vascularity in Doppler was noted in 60% of the cases similar to the study of Sasaki and Miller.<sup>[4]</sup> A grossly black hemorrhagic adnexa of Grade 4

**Table 2: Histopathology**

Histopathology	Number of patients
Benign cyst	32
Mucinous cyst	7
Serous cyst	8
Endometriosis	2
Corpus luteal cyst	4
Borderline mucinous	3
Dermoid teratoma	2
Paratubal cyst	4
Hydrosalpinx	10
Granulosa cell tumor	2
Hemorrhagic cyst	1



**Figure 2:** Operative procedures

ischemia were seen in six patients; we managed to preserve all the ovaries. Even though the ovarian surface appears necrotic and friable in those cases, we could do the detorsion meticulously with extreme care with evacuation of hematoma and de-roofing the cavity. There were no postoperative complications in our study. Parelkar *et al.* also preserved all the necrotic ovaries and also stated that almost all patients had functioning ovary during follow-up ultrasound in spite of grave ischemia.<sup>[2]</sup> Hence, adnexectomy should not be tried immediately as the ovary revives from central to periphery and blood supply can still be obtained from the ovarian or uterine artery and complete arterial occlusion does not occur usually.

In our study, there is a lack of correlation between the onset of symptoms and ovarian infarction, and the range varies from one day to 120 days. We have preserved an ovary in a 16-year-old girl who presented with chronic abdominal pain of 4 months with intraoperative Grade 4 ischemia of the right adnexa with four twists. Similar to the study of Fady *et al.*, the present study also proves that duration of pain cannot predict the ovarian salvageability. Recall of pain is highly subjective and unreliable, especially in children and adolescents. Better surgical outcomes are noted if surgical intervention occurs early according to many authors.<sup>[6,7]</sup> These data imply that prolonged duration of symptoms should not interfere prompt imaging and urgent surgical intervention.

Associated pathology was seen in majority of our cases (77 [91.6%]), and cystectomy was done in all patients with Grade 1 and 2 ischemia. Even though some authors suggest that cystectomy has to be done at later date along with repeat imaging,<sup>[8]</sup> we have done concurrent cystectomy (complete or partial) along with detorsion. During follow-up imaging, there was no persistent cyst; hence, interval cystectomy was not required in any of our patients, similar to the study by Adeyemi-Fowode *et al.*<sup>[1]</sup> In the present study, severe ischemia of Grade 4 was seen in six patients; in these patients, getting a plane between the cyst wall was difficult due to the friability and edema

and also excision of this cyst may cause removal of undue amount of ovarian tissue. Hence, we have done cyst aspiration and partial peeling of the cyst wall in those cases for histopathological diagnosis. All huge cysts that underwent torsion had low-grade ischemia; hence, cystectomy was done successfully without difficulty. A high occurrence of a normal ovary undergoing torsion is seen in young adolescents in our study due to various anatomical variations.<sup>[9]</sup> We have observed adnexal torsion in two young girls with Turner's syndrome and two patients with a supernumerary ovary.

Because of the rarity of malignancy in younger women with adnexal torsion (1%–4%), there should not be any delay in the surgical intervention.<sup>[10-12]</sup> In the current study, three patients had borderline mucinous ovarian tumor, two patients had adult granulosa cell tumor, and all were more than 35 years of age. We could not confirm any additional benefit of adding computed tomography/magnetic resonance imaging for preoperative diagnosis of adnexal torsion, similar to other studies.<sup>[13]</sup>

Our data showed follicles in all ischemic ovaries during follow-up ultrasound. Unfortunately, there is no reliable way to predict ovarian salvage, and it is necessary to have long-term follow-up with serial ultrasound to confirm ovulation, ovarian size, and follow-up of oocytes, and subsequent pregnancies will indicate the fully preserved ovarian function.<sup>[14]</sup> Our study also confirms that leaving the necrotic ovary will not cause any deleterious effect to the patient.

The role of oophoropexy, after detorsion to reduce the recurrence, is not clear.<sup>[15,16]</sup> Following detorsion, bilateral oophoropexy can be offered to children, adolescents, normal looking ovaries with anatomical abnormality, bilateral adnexal torsion, polycystic ovaries and during pregnancy due to high risk of recurrent torsion in these groups. We have followed the same principle and have not come across any recurrence. Several methods of oophoropexy have been described such as fixing the ovarian and round ligaments, fixing the ovary to the pelvic wall or uterosacral ligament or to the posterior surface of the uterus, and shortening the ovarian ligament. We have done a combined method of fixing the ovary to the posterior uterine surface and plicating the ovarian ligament with No. 2-0 PDS or prolene. We prefer this as there is anatomical conservation and surgical feasibility. The impact of oophoropexy on subsequent fertility merits further study.

In our study, we did not come across any recurrence or any postoperative complications except one patient who required readmission after 5 months of surgery in view of recurrent ovarian cyst with abdominal pain on the operated side. Laparoscopic cystectomy was done intraoperatively with no evidence of torsion. Histopathology came out to be a benign mucinous cyst.



The limitation of our study is that only surgically proven cases of adnexal torsion were included, and we may have missed few patients with atypical presentation who did not undergo surgery. Nevertheless, this is one of the very few prospective studies with a large number of patients in adolescent and reproductive age group with successful preservation of 97.8% of torsed ovaries.

## CONCLUSION

Ovarian salvage can be done irrespective of the delayed presentation, number of twists, and the grade of ischemia, and we found that ovarian structure and follicles were preserved following detorsion in all the cases. Laparoscopic management of adnexal torsion is safe and feasible and facilitates enhanced patient recovery.

## Acknowledgments

We sincerely acknowledge the support given by our colleagues and our institution in publishing this article.

## Financial support and sponsorship

This study was financially supported by GEM Hospital and Research Centre, Coimbatore.

## Conflicts of interest

There are no conflicts of interest.

## REFERENCES

- Adeyemi-Fowode O, McCracken KA, Todd NJ. Clinical recommendation: Adnexal torsion. *J Pediatr Adolesc Gynecol* 2018;31:333-8.
- Parelkar SV, Mundada D, Sanghvi BV, Joshi PB, Oak SN, Kapadnis SP, *et al.* Should the ovary always be conserved in torsion? A tertiary care institute experience. *J Pediatr Surg* 2014;49:465-8.
- Tsafiri Z, Azem F, Hasson J, Solomon E, Almog B, Nagar H, *et al.* Risk factors, symptoms, and treatment of ovarian torsion in children: The twelve-year experience of one center. *J Minim Invasive Gynecol* 2012;19:29-33.
- Sasaki KJ, Miller CE. Adnexal torsion: Review of the literature. *J Minim Invasive Gynecol* 2014;21:196-202.
- Fady M, Shawky M. Adnexal torsion: Management controversy: A case series. *Middle East Fertil Soc J* 2017;22:156-9.
- Ghandehari H, Kahn D, Glanc P. Ovarian torsion: Time limiting factors for ovarian salvage. *Emerg Med* 2015;5:273.
- Wang Y, Xie Y, Wu X, Li L, Ma Y, Wang X, *et al.* Laparoscopic management of pedicle torsion of adnexal cysts. *Oncol Lett* 2013;5:1707-9.
- Piper HG, Oltmann SC, Xu L, Adusumilli S, Fischer AC. Ovarian torsion: Diagnosis of inclusion mandates earlier intervention. *J Pediatr Surg* 2012;47:2071-6.
- Briganti V, Gulia C, Signore F, Zangari A, Tursini S, Gigli S, *et al.* Ovarian torsion in pediatric patients: A single-institution case series and mini review of the literature. *Obstet Gynecol Int J* 2017;7:271.
- Abduljabbar HS, Bukhari YA, Al Hachim EG, Alshour GS, Amer AA, Shaikhooon MM, *et al.* Review of 244 cases of ovarian cysts. *Saudi Med J* 2015;36:834-8.
- Yildiz A, Erginel B, Akin M, Karadağ CA, Sever N, Tanik C, *et al.* A retrospective review of the adnexal outcome after detorsion in premenarchal girls. *Afr J Paediatr Surg* 2014;11:304-7.
- Claudio S, Irene B, Valentina P, Josephine L, Elisabetta A, Luca N, *et al.* Adnexal torsion in children and adolescents: New trends to conservative surgical approach – Our experience and review of literature. *Gynecol Endocrinol* 2013;29:54-8.
- Lourenco AP, Swenson D, Tubbs RJ, Lazarus E. Ovarian and tubal torsion: Imaging findings on US, CT, and MRI. *Emerg Radiol* 2014;21:179-87.
- Oelsner G, Shashar D. Adnexal torsion. *Clin Obstet Gynecol* 2006;49:459-63.
- Fuchs N, Smorgick N, Tovbin Y, Ben Ami I, Maymon R, Halperin R, *et al.* Oophoropexy to prevent adnexal torsion: How, when, and for whom? *J Minim Invasive Gynecol* 2010;17:205-8.
- Blitz MJ, Appelbaum H. Management of isolated tubal torsion in a premenarchal adolescent female with prior oophoropexy: A case report and review of the literature. *J Pediatr Adolesc Gynecol* 2013;26:e95-7.