

Available online at [www.sciencedirect.com](http://www.sciencedirect.com)

ScienceDirect

journal homepage: [www.elsevier.com/locate/radcr](http://www.elsevier.com/locate/radcr)

## Case Report

# Post-traumatic cysts detected by ultrasound in infant presented with first-time seizures: Case report ☆☆☆

Yara AlGoraini, MBBS<sup>a,\*</sup>, Haya AlJohani, MBBS<sup>a</sup>, Alaa AlSaegh, MBBS<sup>b</sup>, Nehal AlSadhan, MBBS<sup>a</sup>

<sup>a</sup> Pediatric Emergency Department, King Fahad Medical City, Riyadh, Saudi Arabia

<sup>b</sup> Family Medicine Department, King Fahad Medical City, Riyadh, Saudi Arabia

## ARTICLE INFO

## Article history:

Received 3 August 2022

Revised 8 August 2022

Accepted 13 August 2022

## Keywords:

Case report

Post-trauma

Porencephaly

Ultrasonography

Seizures

## ABSTRACT

In children at risk of neurological damage, such as those delivered prematurely or with history of birth asphyxia, cranial ultrasonography is frequently employed. Cranial ultrasonography also detects cysts, asymmetrical ventricles, periventricular white matter echogenicity, and hemorrhage, among other features. We report the case of an 8-month-old boy who was brought to the emergency department with a history of head trauma followed by seizures. Bedside cranial ultrasonography revealed multiple bilateral intracranial cysts, consistent with porencephalic cysts. Brain magnetic resonance imaging is the gold standard for identifying porencephaly and distinguishing it from other cysts. However, because of time restrictions in emergencies, cranial ultrasonography for a quick assessment in neonates and infants can be appropriate, as was the case in our encounter.

© 2022 The Authors. Published by Elsevier Inc. on behalf of University of Washington.

This is an open access article under the CC BY-NC-ND license

(<http://creativecommons.org/licenses/by-nc-nd/4.0/>)

## Introduction

Porencephalic cysts in the brain are rare congenital or acquired CNS conditions that may be secondary to infarcts or other destructive cerebral lesions [1]. Porencephaly can be caused by various factors such as trauma, infarction, hemorrhage, and focal encephalitis [2]. Porencephalic cysts are often associated with various neurological deficit symptoms,

including visual field defects, abnormal pupillary responses, decreased vision, nystagmus, strabismus, seizures, and cerebrospinal fluid otorrhea or rhinorrhea [3].

Magnetic resonance imaging (MRI), cranial ultrasonography (USG), and brain computed tomography (CT) are used to diagnose porencephalic cyst. The most sensitive and specific imaging tool for children and adults is brain MRI [4]. As time is essential in emergency situations, cranial USG and brain CT are usually faster than MRI. USG uses sound waves to create

Abbreviations: USG, ultrasonography; MRI, magnetic resonance imaging; CT, computed tomography.

☆ Competing Interests: The authors declare that they have no competing interests.

☆☆ Funding: None.

\* Corresponding author. Saudi Arabia, Riyadh

E-mail address: [y.algoraini@hotmail.com](mailto:y.algoraini@hotmail.com) (Y. AlGoraini).

<https://doi.org/10.1016/j.radcr.2022.08.042>

1930-0433/© 2022 The Authors. Published by Elsevier Inc. on behalf of University of Washington. This is an open access article under the CC BY-NC-ND license (<http://creativecommons.org/licenses/by-nc-nd/4.0/>)

images, resulting in less radiation exposure than other imaging modalities [2]. The introduction of cranial ultrasound as a standard tool in neonatology and infancy has substantially increased our understanding of the presence and incidence of brain lesions in newborns and infants. Cranial USG is frequently employed for children at risk of neurological damage, such as those with history of premature birth or birth asphyxia [5]. It can also detect cysts, asymmetrical ventricles, periventricular white matter echogenicity, and hemorrhage, among other features [5]. Hence, we report this interesting case due time is essential in an emergency and cranial USG in neonates and infants can be considered an appropriate modality for a quick assessment and less radiation exposure. In addition, due to its varied clinical presentation and the paucity of pediatric literature on the subject, emergency physicians should be aware of this rare disease, especially since porencephaly can be detected by cranial USG.

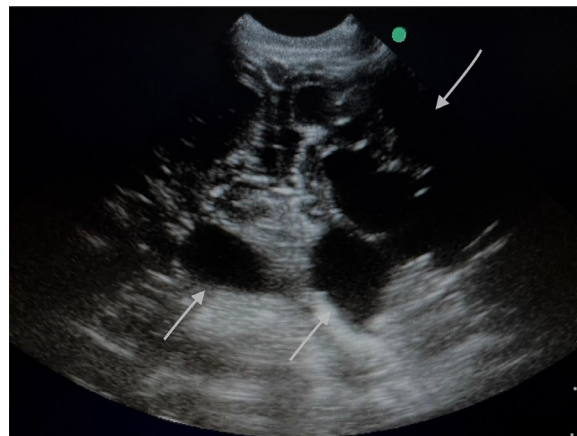
### Case presentation

Our patient was an 8-month-old boy who was brought to the emergency department (ED) by his mother with a history of head trauma due to a one-meter fall from the bed an hour before presentation to the ED. The mother reported that, after the fall, the child displayed abnormal movement, such as upward rolling of the eyes, upper limb spasticity, and jerky movements of the lower limbs that lasted for less than a minute. This was followed by non-projectile vomiting of milk and associated unilateral nose bleed that stopped spontaneously. After the event, the child appeared to be tired and slept.

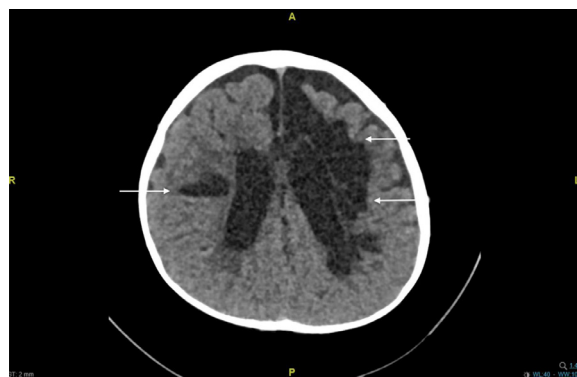
Past medical and family history were negative for seizures or similar episodes. He was not on any medications, nor had he received any vaccinations recently. There was no history of loss of consciousness or change in behavior. He was born spontaneously and vaginally at term, with a birth weight of 3.5 kg and a history of neonatal intensive care unit admission for 7 days due to respiratory distress requiring nasal cannula oxygenation. Perinatal history was unremarkable. He was not born of a consanguineous marriage.

Upon examination, the child was alert, active, and conscious, without dysmorphic features. His vital signs were as follows: temperature, 36.5°C; heart rate, 90 bpm; blood pressure, 90/60 mmHg; respiratory rate, 30 bpm; and glucose, 4.5 mmol. His oxygen saturation was 96% on ambient air. He was not pale, jaundiced, or cyanotic. Initial physical exam was unremarkable; head and cervical examination showed no palpable fractures or step-offs; no signs of basilar skull fracture or point of tenderness were detected. Eyes were equally and bilaterally reactive, and no bleeding from any orifice was found. Extremities, genitalia, abdomen, and back were unremarkable. The results of cardiorespiratory and neurological examinations were unremarkable.

The child's cognitive and language skills were appropriate for his age, but his gross motor skills were delayed due to head lag and he could not sit without support; he could hold the feeding bottle with his hands. All the other domains were normal. Upper- and lower-limb examinations revealed hypotonia with normal reflexes and power.



**Fig. 1 – Transcranial ultrasonography (USG) demonstrated multiple bilateral intracranial cysts that communicate with the ventricular system in the left side of the brain more extensively than the right.**



**Fig. 2 – Computed tomography (CT) brain without contrast demonstrating multiple well-defined intra-axial cysts, mainly left-sided.**

A bedside cranial USG was performed (Fig. 1).

Multiple bilateral intracranial cysts that communicate with the left half of the ventricular system more extensively than the right were found; the finding was confirmed by brain CT without contrast, showed multiple bilateral, mainly left-sided, well-defined intra-axial cysts with cerebrospinal fluid (CSF) attenuation predominantly on the left frontal lobe, with communication to the frontal horn of the left lateral ventricle with associated exvacuodilatation (Fig. 2).

The clinical features and imaging findings were consistent with those of porencephalic cysts which most likely congenital and turned to be an accidental finding.

The child was kept under observation in the ED for 4 hours for possible further head trauma sequelae before referral to the neurosurgery and neurology team for follow-up.

---

## Discussion

We presented an interesting case of an infant with post-traumatic head trauma followed by seizures. Upon bedside cranial USG, multiple porencephalic cysts, mainly on the left side of the brain, were detected. The diagnosis was confirmed by brain computed tomography (CT).

Porencephalic cysts of the brain are rare. They are pseudocysts secondary to infarct or other destructive cerebral lesions [1]. Posttraumatic porencephalic cyst have been reported in multiple adult cases worldwide [3,6,7] but only a few cases have been observed in pediatric patients [1,7,8]. No singular clinical presentation profile was established, but brain CT was the imaging modality for confirmation in all pediatric cases.

Porencephaly can occur in any lobe. Although most cases are unilateral, bilateral porencephaly has been reported [9]. The clinical manifestations of porencephaly vary and may be related to the site and size of the lesion [9]. In this report, we describe an 8-month-old infant who presented with seizures post a traumatic head injury. A diagnosis of multiple porencephaly cysts was made using bedside cranial USG. Our report is similar to one from Kashmir, India, where a 12-year-old boy presented to the emergency department with diplopia on the 15th day after head trauma. A CT brain scan confirmed the diagnosis of porencephaly, which was managed by a cyst peritoneal shunt [1]. Another similar case in India discusses the delayed diagnosis of a 15-year-old boy presenting with multiple episodes of seizures and hemiplegia, for which he was managed with multiple antiepileptics since the age of 8 months [8]. Furthermore, a report of 45 cases of porencephaly showed that only 9 pediatric cases were preceded by head trauma, and the main symptoms were speech defects, intracranial hypertension, hydrocephalus, seizures, ataxia, or paralysis. All patients underwent a CT brain scan, which confirmed the diagnosis of porencephaly, and a shunt was placed as soon as the diagnosis was made [8]. A study in Italy showed 12 cases of neonatal porencephaly due to asphyxia insult diagnosed by USG [10]. Most of the cases reported above were managed with shunts and were followed up. However, currently, there is no known cure for porencephaly. Treatment options are still being researched [4].

Currently, treatment is primarily supportive and consists of administering anticonvulsant drugs to manage seizures. To remove extra fluid from the brain of newborns with hydrocephalus caused by porencephaly, a ventriculoperitoneal shunt is recommended. The porencephalic cysts can also be surgically removed from the cerebral hemisphere [4].

---

## Conclusion

The gold standard for identifying porencephaly and distinguishing it from other cysts is brain MRI. However, because time is essential in an emergency, cranial USG in neonates and infants can be considered an appropriate modality for a quick assessment.

---

## Ethics approval and consent to participate

Case report was approved by King Fahad medical city IRB no. 00010471. The study was performed in accordance with the ethical standards as laid down in the 1964 Declaration of Helsinki and its later amendments or comparable ethical standards. Also, a written informed consent was obtained from all participants or, if participants are under 16, from a parent and/or legal guardian.

---

## Patient consent

Written informed consent was obtained from the patient for publication of this case report and accompanying images.

---

## Availability of data and materials

The datasets used and/or analyzed during the current study are available from the corresponding author on reasonable request.

---

## Authors' contributions

Y.G: Concepts, design, literature search, case preparation and review. H.J: Case review, concept, design. A.S: Case preparation, concept. N.S: Case review, design, preparation, case editing. All authors read and approved the final manuscript.

---

## Acknowledgments

We thank Dr Haya and Dr Nehal for their support in this case report.

---

## REFERENCES

- [1] Sarmast AH, Showkat HI, Farooq Mir S, Masood O, Kirmani AR, Bhat AR. Traumatic porencephaly with strabismus: a case report. *Iran Red Crescent Med J* 2012;14(7):457–8.
- [2] Novakov Mikic A, Koprivsek K, Zocic D. Ultrasound and magnetic resonance in prenatal diagnosis of congenital anomalies. *Reprod Dev Toxicol* 2011;971–82. doi:10.1016/B978-0-12-382032-7.10074-8.
- [3] Yang DN, Townsend JC, Ilsen PF, Bright DC, Welton TH. Traumatic porencephalic cyst of the brain. *J Am Optom Assoc* 1997;68(8):519–26.
- [4] Alghazali M, Abdelaziz I, Alabdeen HZ. Porencephalic cyst. *Int J Case Rep Images* 2017;8(9):620–2.
- [5] Haataja L, Mercuri E, Cowan F, Dubowitz L. Cranial ultrasound abnormalities in full term infants in a postnatal ward: outcome at 12 and 18 months. *Arch Dis Child Fetal Neonatal Ed* 2000;82(2):F128–33. doi:10.1136/fn.82.2.f128.

- 
- [6] Al Thafar AI, Al Rashed AS, Al Matar BA, Al-Sharydah AM, Al-Abdulwahhab AH, Al-Suhibani SS. An atypical porencephalic cyst manifesting as a simple partial seizure: a case report and literature review. *Case Rep Neurol Med* 2017;2017:2174045. doi:[10.1155/2017/2174045](https://doi.org/10.1155/2017/2174045).
- [7] Zhu SG. Porencephaly. A report of 45 cases. *Zhonghua Wai Ke Za Zhi* 1991;29(4):244–5 271Chinese. PMID: 1874115.
- [8] Devi SB, Singh NB, Singh TB, Singh MK, Singh KC. Unilateral porencephaly. *Indian Pediatr* 2002;39(5):495–7.
- [9] Alzahrani RA, Alghamdi AF, Alzahrani MA, Alghamdi MA, Alghamdi MF, Alzahrani AA, et al. A giant porencephaly: a rare etiology of pediatric seizures. *Cureus* 2021;13(11):e19623. doi:[10.7759/cureus.19623](https://doi.org/10.7759/cureus.19623).
- [10] Tonni G, Ferrari B, Defelice C, Centini G. Neonatal porencephaly in very low birth weight infants: ultrasound timing of asphyxial injury and neurodevelopmental outcome at two years of age. *J Matern Fetal Neonatal Med* 2005;18(6):361–5. doi:[10.1080/14767050400029574](https://doi.org/10.1080/14767050400029574).