

## Intraoperative ultrasound evidence of accidental simultaneous cannulation of the common carotid artery and internal jugular vein: illustrative case

Aditya M. Mittal, BS,<sup>1</sup> Kamil W. Nowicki, MD, PhD,<sup>1</sup> Ricardo J. Fernández-de Thomas, MD,<sup>1</sup> Jessica Mayor, MD,<sup>2</sup> Ryan M. McEnaney, MD,<sup>2</sup> and Peter C. Gerszten, MD, MPH<sup>1</sup>

<sup>1</sup>Department of Neurological Surgery, University of Pittsburgh Medical Center, Pittsburgh, Pennsylvania; and <sup>2</sup>Division of Vascular Surgery, University of Pittsburgh Medical Center, Pittsburgh, Pennsylvania

**BACKGROUND** Establishing central venous access is important to provide fluid resuscitation or medications intravenously to patients.

**OBSERVATIONS** Although accidental cannulation of the internal carotid artery has been reported in the literature, to our knowledge this report is the first documented intraoperative ultrasound video demonstrating accidental and simultaneous common carotid artery and internal jugular cannulation during central line placement in the internal jugular vein.

**LESSONS** Ultrasound use minimizes accidental carotid cannulation during central line placement in the internal jugular vein. Carotid artery puncture can be managed by external application of pressure or surgical reexploration.

<https://thejns.org/doi/abs/10.3171/CASE22286>

**KEYWORDS** common carotid artery; central venous line; ultrasound

Central venous access is paramount to the management of the critically ill patient. Previous studies estimate close to 7 million central lines are placed each year in the United States, with common sites being the internal jugular, subclavian, and femoral veins.<sup>1</sup> Some of the indications for a central venous line include the need for fluid resuscitation, infusing certain medications such as vaso-pressors, central venous pressure monitoring, emergency venous access, and transvenous pacing wire placement. Each of the different anatomical locations is associated with advantages, disadvantages, and a defined set of potential complications. Particularly, internal jugular vein cannulation is usually performed with the aid of ultrasound imaging to visualize both the internal carotid artery and the internal jugular vein to be cannulated. Unfortunately, accidental cannulation of the internal carotid artery has been reported.<sup>2</sup> To the best of our knowledge, this report is the first documented intraoperative ultrasound video (Video 1) demonstrating accidental and simultaneous common carotid artery and internal jugular cannulation during central line placement in the internal jugular vein.

**VIDEO 1.** Clip showing intraoperative ultrasound of accidental simultaneous cannulation of the common carotid artery and jugular vein. IJ = internal jugular vein, CA = carotid artery, C = catheter. [Click here to view.](#)

### Illustrative Case

A 69-year-old male presented with a past surgical history of an L2–S1 laminectomy with L2–3 discectomy, both complicated by a pulmonary embolism, and a 3-vessel coronary artery bypass graft surgery. The patient's past medical history was also significant for hypertension, hyperlipidemia, type 2 diabetes mellitus, coronary artery disease, and stage III chronic kidney disease. The patient had experienced recurrence of symptoms after the initial laminectomy a year later with a recurrent L2–3 disc herniation. The patient was evaluated by the Department of Neurosurgery and was found to have suffered from worsening severe right lower extremity (RLE) pain affecting his quality of life. On physical examination, the patient

**ABBREVIATIONS** EEG = electroencephalography; MRI = magnetic resonance imaging; PaO<sub>2</sub> = partial pressure of oxygen; RLE = right lower extremity; SSEP = somatosensory evoked potentials; TLIF = transforaminal lumbar interbody fusion.

**INCLUDE WHEN CITING** Published September 5, 2022; DOI: 10.3171/CASE22286.

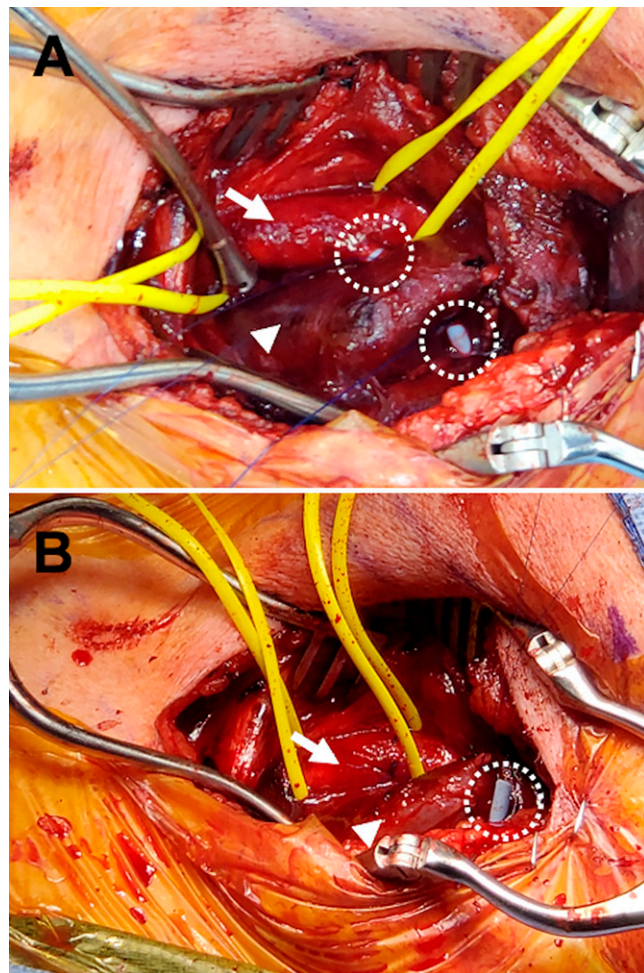
**SUBMITTED** July 1, 2022. **ACCEPTED** July 27, 2022.

© 2022 The authors, CC BY-NC-ND 4.0 (<http://creativecommons.org/licenses/by-nc-nd/4.0/>).

was found to be in obvious discomfort, wheelchair bound, and have profound distal weakness bilaterally, right greater than left. His distribution of RLE pain was nondermatomal and appeared more proximal than distal. Magnetic resonance imaging (MRI) was ordered and revealed evidence of a prior laminectomy from L2–S1 with L2–3 discectomy. MRI also revealed recurrent progressive severe stenosis, especially on the right side from L2–5 and severe central canal stenosis. The patient was scheduled for an L2–5 transforaminal lumbar interbody fusion (TLIF).

After induction of anesthesia in the operating room, an 8-Fr double-lumen central venous catheter was accidentally placed through the internal jugular vein and into the left common carotid artery despite the use of ultrasound guidance by the anesthesia team. This was discovered after manometry and confirmed with arterial tracing. Vascular surgery was emergently consulted intraoperatively for primary repair of the carotid artery injury. The initially planned spine surgical intervention was aborted. The patient then underwent removal of the transcarotid-and-jugular catheter with primary repair of the common carotid artery and internal jugular vein. The neurophysiology team that was originally present for the case was asked to monitor somatosensory evoked potentials (SSEPs) and electroencephalography (EEG) throughout the case, which is standard for an endarterectomy case at our institution. First, a portable ultrasound machine was used to mark out the cannulation site of internal carotid artery and internal jugular vein. A longitudinal incision along the medial border of the sternocleidomastoid muscle was marked out. A standard dissection for carotid exposure was then undertaken with care not to dislodge the catheter. Detailed description of technique and approach have been described previously.<sup>3</sup> Upon dissecting down the sternocleidomastoid and identifying the catheter, a small hematoma and jugular venous bleeding was found. The hematoma was easily and gently evacuated using a Yankauer suction aspirator. Using a 5/0 Prolene suture a purse string suture was applied around the catheter site and that allowed for hemostasis. A hematoma was also found within the carotid sheath and the catheter was found to be entering the proximal portion of the common carotid artery (Fig. 1). The carotid artery was dissected away from the surrounding tissues and the patient was given a total of 9,000 U of intravenous heparin. The common carotid artery was cross-clamped distally first, then proximally, and then the catheter was cut and slowly retrieved from the common carotid artery and allowed to flush upon removal. The arteriotomy caused by the catheter was widened transversely to facilitate careful inspection. The carotid lumen was flushed with heparinized saline to remove any thrombus, and finally closed in an interrupted fashion with 5/0 Prolene. No changes in SSEPs or EEG were reported throughout the case.

The patient was taken to the surgical intensive care unit postoperatively and underwent a computed tomography angiogram of the head and neck and computed tomography perfusion, which were negative for acute stroke or any other acute pathology. He was noted to have facial asymmetry and mild transient right upper extremity weakness that resolved over the subsequent days concerning for transient ischemic attack. He was started on aspirin and was monitored with frequent neck circumference checks every 8 hours. Subsequently, he was started on a heparin drip on postoperative day 3 and bridged to his home Eliquis (Pfizer). He was transferred to the floor and discharged home in stable condition with plans to follow up to discuss next steps regarding his TLIF.



**FIG. 1.** Intraoperative view of accidental simultaneous cannulation of the common carotid artery and jugular vein. After initial exposure (A) and after removal of the catheter and primary closure (B). Arrows indicate the common carotid artery; arrowheads, the internal jugular vein; and dotted circles, the catheter.

The patient was seen for follow-up 1 week after the attempted L2–5 TLIF. At the follow-up visit, the patient was found to have bilateral deep vein thromboses and a provoked pulmonary embolism attributed to immobility from chronic pain and foot drop. It was recommended that the patient remain on lifelong anticoagulation and full hypercoagulation workup returned negative. At that point, his regimen included Eliquis and aspirin 81 mg daily. Six weeks later he underwent a successful L2–5 TLIF without any complication. Aspirin was held 5 days prior to his planned surgery. Eliquis was held 3 days preoperatively, and he was transitioned to a 3-day Lovenox (Sanofi-Aventis) anticoagulation regimen.

## Discussion

Complications after central venous line cannulation can be severe and vary depending on the anatomical location of the line. Complications can include severe bleeding, bacteremia, pneumothorax, arterial dissection, cerebrovascular accidents,<sup>4</sup> and death<sup>5</sup> (Table 1). Prior literature has documented the various complications caused by cannulation or trauma to the carotid artery.<sup>6</sup>

**TABLE 1. Advantages and disadvantages of different access sites of central lines**

Approach	Advantages	Common Complications
External jugular	Head-of-table access, easier to access in older adult patients, rapid venous access	Air embolism, high rate of malposition
Internal jugular	Head-of-table access, lower failure rates w/ novice operators, targeted well w/ ultrasound guidance	Carotid artery puncture, air embolism, damage to neck & chest structures, thoracic duct injury on the left
Subclavian	More comfortable for patients, better for patients w/ obesity, accessible when airway control is being established	Risk of pneumothorax, catheter malposition more common
Femoral	No interference w/ CPR, no interference w/ intubation, rapid access & high success rate	Risk of infection, risk of iliofemoral thrombosis

CPR = cardiopulmonary resuscitation.

### Observations

Anesthesia providers are typically responsible for placement of central venous lines. Most catheters are placed bedside using external anatomical landmarks. The use of external landmarks may be problematic especially when considering the proximity of the internal jugular vein to the common carotid artery (Table 2). In a computed tomography evaluation by Lim et al.,<sup>7</sup> the internal jugular vein was less than 1 mm from the carotid artery in 69.5% of cases. Additionally, the external landmark technique was also reported to be more likely to intersect the carotid artery in obese patients.<sup>8</sup> These findings support the use of ultrasound during catheter placement. Ultrasound guidance has been suggested to be more efficient based on several prospective, randomized studies comparing external landmark use to ultrasound use, and has become the gold standard practice.<sup>9–16</sup> These studies reported decreased complications and higher initial success rates in the ultrasound guidance group compared to the external landmark group. Awareness of potential complication severity and proper training for catheter placement including ultrasound use may decrease the incidence of accidental common carotid artery cannulation.

### Lessons

Detection of arterial cannulation can primarily be suspected by pulsatile or high-pressure backflow following catheter placement, as well as the return of bright red blood after cannulation. To confirm cannulation various techniques can be used. Commonly used are comparisons of blood color and partial pressure of oxygen (PaO<sub>2</sub>).<sup>2,17</sup> More accurate blood color and PaO<sub>2</sub> comparison is largely dependent on the patient's oxygenation and fluid volume status.<sup>18</sup> Therefore, solely relying on blood color and PaO<sub>2</sub> comparisons may be inaccurate to detect cannulation. Simple pressure

waveform transduction could also be used to confirm arterial versus venous cannulation.

There are two options when it comes to management of accidental carotid cannulation: surgical exploration versus removal and external application of pressure. Prior studies suggest that the best approach is to leave the catheter in place and undertake an open approach to remove the catheter under direct visualization.<sup>19</sup> Shah et al.<sup>8</sup> reported removal of the catheter followed by external pressure led to severe complications including hematoma, pseudoaneurysm, and cerebrovascular accident. However, patients who underwent open surgical exploration developed no sequelae after catheter removal. In our case, the catheter was placed in the operating room under ultrasound guidance. The double cannulation likely occurred due to a combination of patient's body habitus, close proximity of the vessels, and poor visualization despite ultrasound use. Once the accidental cannulation was identified the original L2–5 TLIF surgery was aborted, and vascular surgery was consulted immediately for removal and vascular repair secondary to accidental cannulation. Our patient was discharged in stable condition with no complications after removal of the catheter.

Surgical management of accidental cannulation can range from open surgery to endovascular techniques to simple removal with local pressure applied at the site. Endovascular techniques with covered stent placement or percutaneous arterial closure device have been reported to be as efficacious as open surgery for treatment of accidental cannulation.<sup>20</sup> Endovascular techniques are less invasive and reportedly more expeditious compared to open surgery; however, endovascular treatment has not been recommended to treat all iatrogenic carotid artery injuries.<sup>20</sup> Use of an arterial stent graft, while offering expeditious hemorrhage control from the puncture, results in a permanent arterial implant which carries its own long-term risks. In addition, an arterial stent would

**TABLE 2. Advantages and disadvantages of different approaches to place an internal jugular central line based on anatomical landmarks**

Technique	Advantages	Disadvantages
Central approach	Commonly used, may decrease the chance of pleural or carotid arterial puncture	Higher risk of carotid puncture <sup>21</sup>
Anterior approach	Performed w/ patient in supine position	Lower success rate compared to posterior approach, higher rates of carotid artery puncture
Posterior approach	Better for obese patients & patients w/ neck masses, <sup>22</sup> less risk of carotid puncture <sup>21</sup>	Associated w/ higher rates of flow obstruction, <sup>22</sup> higher rates of catheter insertion failure rates <sup>22</sup>

not immediately address the double venotomy. Such endovascular strategies may be better reserved for arterial injuries that are difficult to expose surgically.

## References

1. Guilbert MC, Elkouri S, Bracco D, et al. Arterial trauma during central venous catheter insertion: Case series, review and proposed algorithm. *J Vasc Surg.* 2008;48(4):918–925.
2. Maietta PM. Accidental carotid artery catheterization during attempted central venous catheter placement: a case report. *AANA J.* 2012; 80(4):251–255.
3. Sundt TM. *Occlusive Cerebrovascular Disease: Diagnosis and Surgical Management.* Saunders; 1986.
4. Anagnou J. Cerebrovascular accident during percutaneous cannulation of internal jugular vein. *Lancet.* 1982;2(8294):377–378.
5. Heath KJ, Woulfe J, Lowrie S, Pelz D, Munoz DG, Mezon B. A devastating complication of inadvertent carotid artery puncture. *Anesthesiology.* 1998;89(5):1273–1275.
6. Sekharan J, Dennis JW, Veldenz HC, Miranda F, Frykberg ER. Continued experience with physical examination alone for evaluation and management of penetrating zone 2 neck injuries: results of 145 cases. *J Vasc Surg.* 2000;32(3):483–489.
7. Lim CL, Keshava SN, Lea M. Anatomical variations of the internal jugular veins and their relationship to the carotid arteries: a CT evaluation. *Australas Radiol.* 2006;50(4):314–318.
8. Shah PM, Babu SC, Goyal A, Mateo RB, Madden RE. Arterial misplacement of large-caliber cannulas during jugular vein catheterization: case for surgical management. *J Am Coll Surg.* 2004;198(6):939–944.
9. Denys BG, Uretsky BF, Reddy PS, Ruffner RJ, Sandhu JS, Breishlatt WM. An ultrasound method for safe and rapid central venous access. *N Engl J Med.* 1991;324(8):566.
10. Mussa FF, Towfigh S, Rowe VL, Major K, Hood DB, Weaver FA. Current trends in the management of iatrogenic cervical carotid artery injuries. *Vasc Endovascular Surg.* 2006;40(5):354–361.
11. Koroglu M, Demir M, Koroglu BK, et al. Percutaneous placement of central venous catheters: comparing the anatomical landmark method with the radiologically guided technique for central venous catheterization through the internal jugular vein in emergent hemodialysis patients. *Acta Radiol.* 2006;47(1):43–47.
12. Leung J, Duffy M, Finckh A. Real-time ultrasonographically-guided internal jugular vein catheterization in the emergency department increases success rates and reduces complications: a randomized, prospective study. *Ann Emerg Med.* 2006;48(5):540–547.
13. Sulek CA, Blas ML, Lobato EB. A randomized study of left versus right internal jugular vein cannulation in adults. *J Clin Anesth.* 2000; 12(2):142–145.
14. Troianos CA, Jobes DR, Ellison N. Ultrasound-guided cannulation of the internal jugular vein. A prospective, randomized study. *Anesth Analg.* 1991;72(6):823–826.
15. Gilbert TB, Seneff MG, Becker RB. Facilitation of internal jugular venous cannulation using an audio-guided Doppler ultrasound vascular access device: results from a prospective, dual-center, randomized, crossover clinical study. *Crit Care Med.* 1995;23(1):60–65.
16. Hayashi H, Amano M. Does ultrasound imaging before puncture facilitate internal jugular vein cannulation? Prospective randomized comparison with landmark-guided puncture in ventilated patients. *J Cardiothorac Vasc Anesth.* 2002;16(5):572–575.
17. Lim WY, Raghavan KC. Identification and confirmation of suspected unintended peripheral arterial cannulation during anaesthesia. *Proceedings of Singapore Healthcare.* 2016;26(3):203–205.
18. Weekes AJ, Johnson DA, Keller SM, et al. Central vascular catheter placement evaluation using saline flush and bedside echocardiography. *Acad Emerg Med.* 2014;21(1):65–72.
19. Pikwer A, Acosta S, Kölbl T, Malina M, Sonesson B, Åkeson J. Management of inadvertent arterial catheterisation associated with central venous access procedures. *Eur J Vasc Endovasc Surg.* 2009;38(6):707–714.
20. Bechara CF, Barshes NR, Pisimisis G, Koungias P, Lin PH. Management of inadvertent carotid artery sheath insertion during central venous catheter placement. *JAMA Surg.* 2013;148(11):1063–1066.
21. Kedareshvara K, Chopra N, Patil MC. Posterior approach to internal jugular vein cannulation is superior to central approach in terms of ease of insertion and less complication - A one year hospital based randomised controlled trial. *J Evol Med Dent Sci.* 2020;9(51): 3846–3851.
22. Mathur M, D'Souza AVL, Prasad D, et al. A comparative study of central versus posterior approach for internal jugular hemodialysis catheter insertion. *Indian J Nephrol.* 2015;25:256–268.

## Disclosures

The authors report no conflict of interest concerning the materials or methods used in this study or the findings specified in this paper.

## Author Contributions

Conception and design: Gerszten, Nowicki, Fernandez-de Thomas. Acquisition of data: Gerszten, Nowicki, Major, McEnaney. Analysis and interpretation of data: Gerszten, Nowicki, McEnaney. Drafting the article: Mittal, Nowicki, Fernandez-de Thomas. Critically revising the article: Gerszten, Nowicki, Fernandez-de Thomas, McEnaney. Reviewed submitted version of manuscript: Mittal, Nowicki, Fernandez-de Thomas, Major, McEnaney. Approved the final version of the manuscript on behalf of all authors: Gerszten. Study supervision: Gerszten, Nowicki.

## Supplemental Information

Video

Video 1. <https://vimeo.com/734374698>.

## Correspondence

Peter C. Gerszten: University of Pittsburgh Medical Center, Pittsburgh, PA. [gerspc@upmc.edu](mailto:gerspc@upmc.edu).