



Case report

Macular corneal dystrophy with isolated peripheral Descemet membrane deposits



Wenlin Zhang^a, Austin Connor Kassels^a, Alice Barrington^a, Shaukat Khan^b, Shunji Tomatsu^b, Turad Alkadi^c, Anthony Aldave^{a,*}

^a Stein Eye Institute, UCLA, Los Angeles, CA, 90095, USA

^b Nemours/Alfred I duPont Hospital for Children, Wilmington, DE, 19803, USA

^c Al Imam Mohammad Ibn Saud Islamic University, Riyadh, Saudi Arabia

ARTICLE INFO

Keywords:

Corneal dystrophy
Macular corneal dystrophy
Corneal endothelial disease

ABSTRACT

Purpose: Macular Corneal Dystrophy (MCD, MIM #217800) is a category 1 corneal stromal dystrophy as per the current IC3D classification. While characterized by macular stromal deposits, we report a case of MCD type II with isolated bilateral peripheral Descemet membrane opacities, describing the clinical features and results of screening the *CHST6* gene and serum sulfated keratan sulfate levels.

Observations: A 68-year-old man with an unremarkable past medical and family history presented with bilateral progressive decrease in vision. Ocular exam revealed bilateral clear corneas with the exception of peripheral, round, gray-white discrete deposits at the level of Descemet membrane and decreased central corneal thickness in both eyes. The morphology of the corneal deposits, decreased corneal thickness and the absence of a family history were consistent with MCD, prompting screening of the *CHST6* gene. Sanger sequencing followed by allele specific cloning revealed compound heterozygous *CHST6* mutations in *trans* configuration: c.-26C > A, which created a new upstream open reading frame (uORF), predicted to attenuate translation efficiency of the downstream main ORF; and c.803A > G (p.(Tyr268Cys)), previously associated with MCD. Serum keratan sulfate was reduced but detectable, consistent with the diagnosis of macular corneal dystrophy type II.

Conclusions: Although macular corneal dystrophy is classified as a corneal stromal dystrophy with endothelial involvement, we report a case of MCD with dystrophic deposits confined to the peripheral Descemet membrane, indicating that MCD may be associated with isolated endothelial involvement.

1. Introduction

Macular corneal dystrophy (MCD) is an autosomal recessive corneal stromal dystrophy characterized by bilateral diffuse stromal haze and scattered focal stromal opacities that predominantly involve the anterior stroma in the center of the cornea and the posterior stroma in the peripheral cornea.¹ Mutations in the carbohydrate sulfotransferase 6 gene (*CHST6*) are causative of MCD, with both coding region and promoter mutations identified.² *CHST6* protein in human cornea is responsible for the enzymatic sulfation of keratan sulfate (KS),³ a key process in collagen matrix assembly and homeostasis.⁴ While sulfated KS is not detectable in the cornea of individuals with MCD, and serum levels are either absent (type I) or decreased (type II), unsulfated KS is, depositing both in keratocytes and the stroma, as well as in endothelial cells and Descemet membrane.^{1,5} Here we report a case of MCD type II, confirmed by genetic analysis and serum KS measurement, with

isolated peripheral Descemet membrane deposits without the characteristic diffuse stromal haze and anterior stromal opacities.

2. Materials and methods

A complete ophthalmic examination was performed, and after informed consent was obtained (UCLA IRB # 11-000020), saliva and serum samples were collected. Sanger sequencing of the *CHST6* gene was performed on genomic DNA extracted from the saliva sample using previously described primers and reaction conditions.² Sequences were compared to the wild type *CHST6* transcript (NM_021615.4) and minor allele frequencies (MAF) of identified variants were obtained from the Exome Aggregation Consortium (ExAC) and 1000 Genomes Project databases. Allele-specific cloning followed by sequencing was performed to determine the phase (*cis* or *trans*) of identified heterozygous mutations. In brief, a DNA fragment containing both mutation sites and

* Corresponding author. Stein Eye Institute, UCLA, 200 Stein Plaza, Los Angeles, CA, 90095, USA.

E-mail address: aldave@jsei.ucla.edu (A. Aldave).

<https://doi.org/10.1016/j.ajoc.2019.100571>

Received 28 January 2019; Received in revised form 2 September 2019; Accepted 5 November 2019

Available online 13 November 2019

2451-9936/© 2019 Published by Elsevier Inc. This is an open access article under the CC BY-NC-ND license (<http://creativecommons.org/licenses/by-nc-nd/4.0/>).

a single SacII digestion site was amplified (primers: 5'-GATCCGTTGGG TGATGTTATGGA-3' and 5'-CAGGTGCTGAGGAACCTCTAA-3'), ligated into pCR™4-TOPO® TA vector using TOPO® TA Cloning Kit (Thermo Fisher Scientific), and expanded in competent *E. coli* HST08 cells (Takara Bio USA) with carbenicillin selection. Plasmids containing the desired DNA fragment were purified, digested by SacII restriction enzyme, size-selected on electrophoresis and sequenced. *In silico* prediction of non-canonical 5' untranslated region (5' UTR) translation initiation sites and determination of the predicted initiation confidence was performed with PreTIS software.⁶ Serum glycosaminoglycans (GAG), including dermatan sulfate (DS), heparan sulfate (HS), and keratan sulfate (KS), were measured by liquid chromatography with tandem mass spectrometry (LC-MS/MS) as described previously and compared with four age-matched controls.⁷

3. Case report

A 68-year-old Asian male with an unremarkable past medical history noted a progressive decrease in visual acuity of both eyes. He was diagnosed with an unknown corneal dystrophy and referred to one of the authors (AJA) for molecular genetic analysis. The patient denied a family history of corneal disorders or corneal transplantation. Corrected visual acuities measured 20/40 OD and 20/50 OS. Slit lamp and OCT examination revealed bilateral clear corneas with the exception of peripheral, round, gray-white discrete deposits at the level of Descemet membrane (Fig. 1). Other than 2 + nuclear sclerotic cataracts, the remainder of the ocular exam was unremarkable in both eyes. Serial

central corneal pachymetry measurements ranged from 479 to 517 μm OD and 519 to 531 μm OS. Corneal topography was unremarkable, with average keratometry values of 42.1 D OD and 43.1 D OS. Similarly, endothelial cell density was within normal limits in each eye, measuring 2381 cells/ mm^2 OD and 2083 cells/ mm^2 OS. Based on the morphology of the corneal opacities, the decreased central corneal thickness and the absence of a family history, a presumptive diagnosis of MCD was made, prompting screening of *CHST6* for confirmation of the diagnosis.

Two heterozygous variants in *CHST6* were identified, c.-26C > A in the 5' UTR and c.803A > G p.(Tyr268Cys) (Fig. 2A), which were confirmed to be located on separate alleles by allele-specific cloning (in *trans*, Fig. 2B, D). The c.-26C > A variant is novel and is located in *CHST6* non-coding exon 2 in a "Kazak consensus", a favorable sequence context for translation preinitiation complex assembly.⁸ This variant is predicted to create a novel transcription initiation site followed by a 60-bp upstream open reading frame (uORF') in mutant *CHST6* mRNA (Fig. 2E). *In silico* analysis predicted that the uORF' will be used as alternative translation ORF with 73.8% confidence (Fig. 2C). The alternative usage of the new uORF' is expected to attenuate translation of the wild-type *CHST6* main ORF (mORF), with the predicted mutant protein being only 19 amino acid in length, distinct from the *CHST6* wild-type protein (Fig. 2E and F). The c.803A > G variant, located in *CHST6* coding exon 3 and predicted to result in a missense amino acid substitution (p.(Tyr268Cys)), is a rare variant (rs72547539; MAF 0.0002 (1000 Genome) and 0.000009 (ExAC)), that has been previously reported in four probands with MCD.^{9,10} Measurement of serum sulfated KS and other GAG revealed decreased serum levels of all GAG compared to four aged-matched controls (Table 1). The serum total sulfated KS level (134.6 ng/ml) was only 30% of that in age-matched controls.

4. Discussion

We report a unique phenotype of MCD associated with isolated peripheral Descemet membrane opacities without the characteristic diffusely distributed cornea stromal maculae. In contrast to the belief that abnormalities of corneal endothelium and Descemet membrane in MCD are secondary to diffused and/or phagocytosed pathological materials from the stroma, this report provides support for the alternative hypothesis that MCD primarily involves the corneal endothelium in addition to stromal keratocytes.¹¹ Snip et al. reported that in MCD, the fibrillogranular material in vacuoles in the corneal endothelium contained the same acid mucopolysaccharide as in the vacuoles in the stromal keratocytes, and concluded that given the physical barrier of Descemet membrane, it was unlikely that the material in the endothelial vacuoles was phagocytosed.¹¹ Additionally, the authors reasoned that the fact the posterior non-banded zone of Descemet membrane, which is produced by the corneal endothelium, is abnormal in MCD is evidence of corneal endothelial dysfunction in MCD.¹¹ Quantock et al. also reported an unremarkable anterior banded zone but abnormal posterior non-banded zone of Descemet membrane with guttae and corneal endothelium demonstrating intracytoplasmic inclusions in a cornea of an individual with macular corneal dystrophy type II.¹²

In silico analysis of the identified non-coding *CHST6* mutation that we report predicted the creation of a new uORF' reducing *CHST6* mRNA translation efficiency from the mORF. Mutation-introduced uORF have been associated with many human diseases with experimental data showing reduced translational efficiency, and a 30–80% decrease in protein levels.¹³ Evidence for the potential pathogenicity of the identified c.-26C > A mutation is provided by the fact that it demonstrates two of the four uORF properties associated with greater inhibition of downstream mORF translation: creation in a strong Kozak consensus context and location at a significant distance (> 99 nt) from the mRNA 5' cap.¹³ Therefore, the result is predicted to be an attenuation of

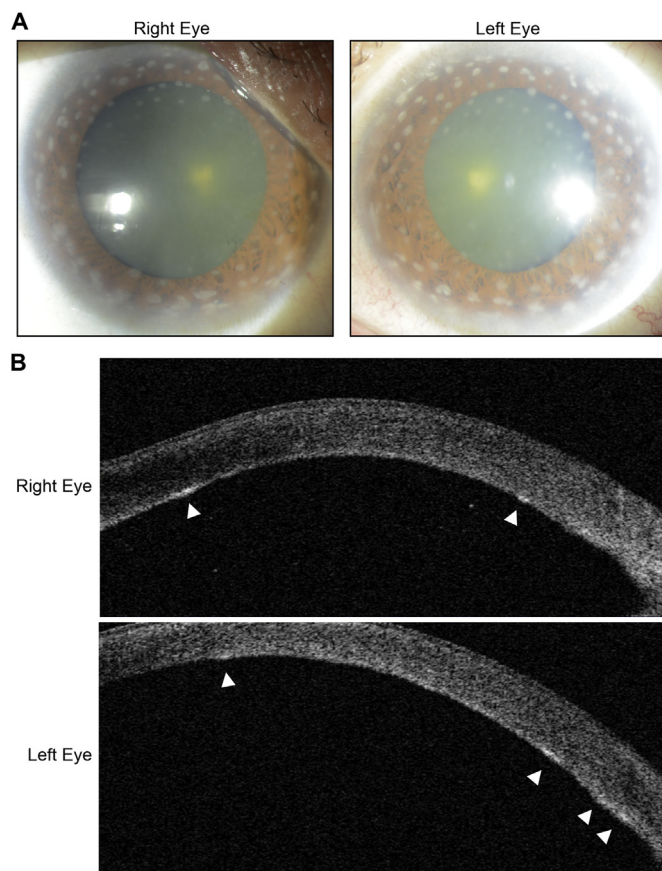


Fig. 1. Macular corneal dystrophy associated with peripheral Descemet membrane opacities. A. Slit-lamp photographs of the right and left eyes of an individual with macular corneal dystrophy demonstrating bilateral peripheral posterior stromal opacities. B. Anterior segment OCT images of the right and left eyes demonstrating that the deposits were located at the level of Descemet membrane (arrowheads).

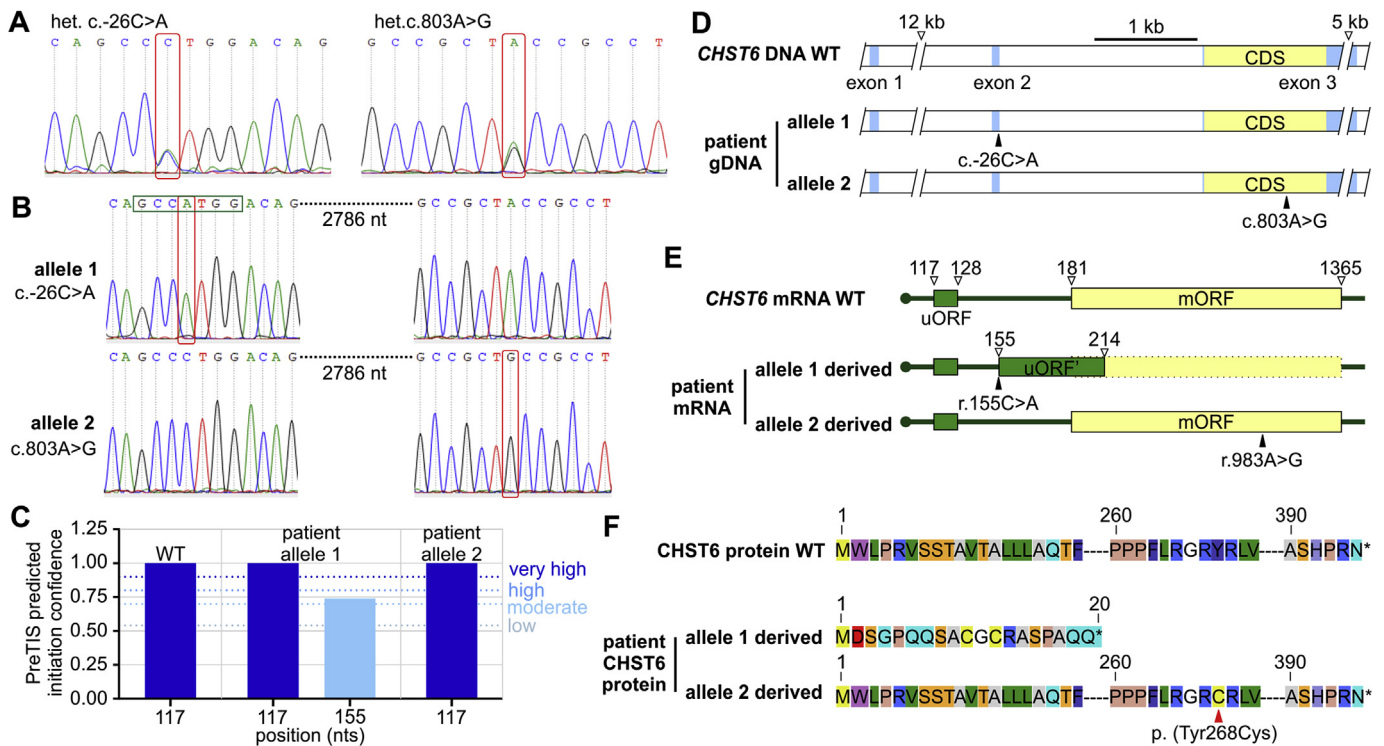


Fig. 2. *CHST6* mutations and associated mRNA and protein changes in individual with macular corneal dystrophy. A. Chromatograms showing identified heterozygous mutations c.-26C > A and c.803A > G (red rectangles). B. Allele specific cloning results showing c.-26C > A and c.803A > G (red rectangles) on separate alleles. Mutation c.-26C > A is located in a Kozak sequence (green rectangle) (nt = nucleotide). C. *In silico* analysis showing the c.-26C > A mutation creates a new translation initiation site at position 155 nt with moderate to high predicted initiation confidence. (The initiation site at 117 nt was seen in both wild type and mutant alleles.) (WT = wild-type) D. Schematic illustration of identified mutations *in trans*. (gDNA = genomic DNA) E. Schematic illustration of identified mutations in *CHST6* mRNA. Mutation c.-26C > A induced r.155C > A change in *CHST6* mRNA creating a new uORF (uORF = upstream open reading frame, green solid rectangle; mORF = main open reading frame, yellow solid rectangle). F. Schematic illustration of predicted protein changes in proband *CHST6* protein. (For interpretation of the references to colour in this figure legend, the reader is referred to the Web version of this article).

production of the wild-type *CHST6* protein and the production of a mutant, truncated *CHST6* protein. In combination with the missense mutation previously associated with MCD on the opposite allele, these two mutations likely result in a decrease in both corneal and serum sulfated KS and the development of the peripheral Descemet membrane opacities that in this case, are the sole clinical manifestation of MCD.

of Descemet membrane, providing evidence that corneal endothelial involvement is a primary manifestation of this autosomal recessive corneal dystrophy. Screening of the *CHST6* gene and measurement of serum keratan sulfate are useful means to confirm or exclude the diagnosis of MCD in cases with an atypical phenotype, which is necessary prior to reporting an expansion of the clinical phenotype associated with MCD.

5. Conclusions

Macular corneal dystrophy may present with isolated involvement

Table 1
Serum glycosaminoglycan levels in individual with macular corneal dystrophy.

	Age (yrs)	KS (ng/ml)			DS (ng/ml)		HS (ng/ml)	
		Di-S KS ^a	Mono-S KS ^b	Total sulfated KS	ΔDi-4S ^c	ΔDiHS-NS ^d	ΔDiHS-oS ^e	
Control	A	62	150.9	301.4	452.3	17.9	6.0	36.8
	B	57	122.0	325.3	447.4	13.1	7.0	56.8
	C	59	158.7	317.2	475.9	15.0	8.2	57.9
	D	60	120.4	282.2	402.5	21.2	12.9	74.3
	Mean (SD)	60 (2)	138.0 (19.7)	306.5 (19.0)	444.5 (30.7)	16.8 (3.5)	8.5 (3.1)	56.5 (15.4)
Proband	68	58.5	76.1	134.6	4.6	3.6	32.0	

KS: keratin sulfate; DS: dermatan sulfate; HS: heparan sulfate.

^a Di-S KS: di-sulfated KS, Gal(6S)β1 → 4GlcNAc(6S).

^b Mono-S KS: mono-sulfated KS, Galβ1 → 4GlcNAc(6S).

^c ΔDi-4S [ΔHexUAα1-4GlcNAc(4-O-sulfate)]: 2-acetamido-2-deoxy-4-O-(4-deoxy-a-L-threo-hex-4-enopyranosyluronic acid)-4-O-sulfo-D-glucose.

^d ΔDiHS-NS [ΔHexUAα1-4GlcN(2-N-sulfate)]: 2-deoxy-2-sulfamino-4-O-(4-deoxy-a-L-threo-hex-4-enopyranosyluronic acid)-D-glucose.

^e ΔDiHS-oS (ΔHexUAα1-4GlcNAc): 2-acetamido-2-deoxy-4-O-(4-deoxy-a-L-threo-hex-4-enopyranosyluronic acid) -D-glucose.

Patient consent

This report does not contain any personal information that could lead to the identification of the patient.

Funding

National Eye Institute grants R01EY022082 (A.J.A.) and P30EY000331 (core grant to the Stein Eye Institute), an unrestricted grant from Research to Prevent Blindness (Stein Eye Institute).

Authorship

All authors attest that they meet the current ICMJE criteria for authorship.

Declaration of competing interest

All authors have no conflicts of interest to report.

Acknowledgements

None.

Appendix A. Supplementary data

Supplementary data to this article can be found online at <https://doi.org/10.1016/j.ajoc.2019.100571>.

References

- Weiss JS, Moller HU, Aldave AJ, et al. IC3D classification of corneal dystrophies—edition 2. *Cornea*. 2015;34:117–159.
- Akama TO, Nishida K, Nakayama J, et al. Macular corneal dystrophy type I and type II are caused by distinct mutations in a new sulphotransferase gene. *Nat Genet*. 2000;26:237–241.
- Akama TO, Fukuda MN. Carbohydrate (N-Acetylglucosamine 6-O) sulfotransferase 5 and 6 (CHST5,6). In: Taniguchi N, Honke K, Fukuda M, Narimatsu H, Yamaguchi Y, Angata T, eds. *Handbook of Glycosyltransferases and Related Genes*. Tokyo: Springer Japan; 2014:1005–1014.
- Hayashida Y, Akama TO, Beecher N, et al. Matrix morphogenesis in cornea is mediated by the modification of keratan sulfate by GlcNAc 6-O-sulfotransferase. *Proc Natl Acad Sci U S A*. 2006;103:13333–13338.
- Lewis D, Davies Y, Nieduszynski IA, et al. Ultrastructural localization of sulfated and unsulfated keratan sulfate in normal and macular corneal dystrophy type I. *Glycobiology*. 2000;10:305–312.
- Reuter K, Biehl A, Koch L, Helms V. PreTIS: a tool to predict non-canonical 5' UTR translational initiation sites in human and mouse. *PLoS Comput Biol*. 2016;12:e1005170.
- Tomatsu S, Shimada T, Mason RW, et al. Establishment of glycosaminoglycan assays for mucopolysaccharidoses. *Metabolites*. 2014;4:655–679.
- Hinnebusch AG, Ivanov IP, Sonenberg N. Translational control by 5'-untranslated regions of eukaryotic mRNAs. *Science*. 2016;352:1413–1416.
- Liu Z, Tian X, Iida N, et al. Mutation analysis of CHST6 gene in Chinese patients with macular corneal dystrophy. *Cornea*. 2010;29:883–888.
- Ha NT, Chau HM, Cung le X, et al. Mutation analysis of the carbohydrate sulfotransferase gene in Vietnamese with macular corneal dystrophy. *Investig Ophthalmol Vis Sci*. 2003;44:3310–3316.
- Snip RC, Kenyon KR, Green WR. Macular corneal dystrophy: ultrastructural pathology of corneal endothelium and Descemet's membrane. *Investig Ophthalmol*. 1973;12:88–97.
- Quantock AJ, Fullwood NJ, Thonar EJMA, et al. Macular corneal dystrophy type II: multiple studies on a cornea with low levels of sulphated keratan sulphate. *Eye*. 1997;11:57–67.
- Calvo SE, Pagliarini DJ, Mootha VK. Upstream open reading frames cause widespread reduction of protein expression and are polymorphic among humans. *Proc Natl Acad Sci U S A*. 2009;106:7507–7512.