

Available online at www.sciencedirect.com

ScienceDirect

journal homepage: www.elsevier.com/locate/radcr

Case Report

Sebaceous carcinoma of the chest wall: A case report

Soh C, BA^{a,*}, Moyle P, MBCChB, MRCP, FRCR^b, Scott-Balgrave J, MBBS^c, Benson J, MA, DM, FRCS, FRCS^d

^a University of Cambridge School of Clinical Medicine, Addenbrooke's Hospital, CB2 0SP

^b Consultant Radiologist Cambridge University Hospital NHS Trust, Cambridge, UK

^c Radiologist Cambridge University Hospital NHS Trust, Cambridge, UK

^d Consultant Breast Surgeon Cambridge University Hospital NHS Trust, Cambridge and Anglia Ruskin School of Medicine, Cambridge, UK

ARTICLE INFO

Article history:

Received 8 April 2021

Revised 23 April 2021

Accepted 25 April 2021

ABSTRACT

Sebaceous carcinoma is a rare, malignant tumor of the sebaceous glands. This is a case report of a 75-year-old man who presented with a right lower axillary mass which initially was considered to be a benign sebaceous cyst from sonography. The lesion rapidly changed in clinical and sonographic appearances and on histology was a sebaceous carcinoma. This unusual tumor accounts for less than 1% of all cutaneous malignant tumors, and the chest wall is a rare extraocular site with only nine cases described in the literature. Immunohistochemistry was negative for MSH2 and MSH6, and positive for MLH1 and PMS2, raising the possibility of Lynch or Muir-Torre Syndrome which is a known association with this rare tumor.

Crown Copyright © 2021 Published by Elsevier Inc. on behalf of University of Washington.

This is an open access article under the CC BY-NC-ND license

(<http://creativecommons.org/licenses/by-nc-nd/4.0/>)

Introduction

Sebaceous carcinomas (SC) is a rare but aggressive tumor of the sebaceous glands, accounting for less than 1% of all cutaneous malignant tumors. Although SC can arise from a sebaceous gland within any part of the skin, these are usually confined to the eyelid with extra-ocular presentations in

only one quarter of reported cases. Moreover, there are only 9 reported cases of axillary presentation of SC and in these circumstances a diagnosis of Muir-Torre syndrome should be considered in patients diagnosed with a primary SC. [1–2] Furthermore, surgical excision is the recommended primary treatment modality and this includes Moh's micrographic surgery [3]. An unusual case of SC is presented with accompanying imaging that is crucial for differential diagnosis of

* Corresponding author.

E-mail address: chien.soh@addenbrookes.nhs.uk (S. C).

<https://doi.org/10.1016/j.radcr.2021.04.060>

1930-0433/Crown Copyright © 2021 Published by Elsevier Inc. on behalf of University of Washington. This is an open access article under the CC BY-NC-ND license (<http://creativecommons.org/licenses/by-nc-nd/4.0/>)

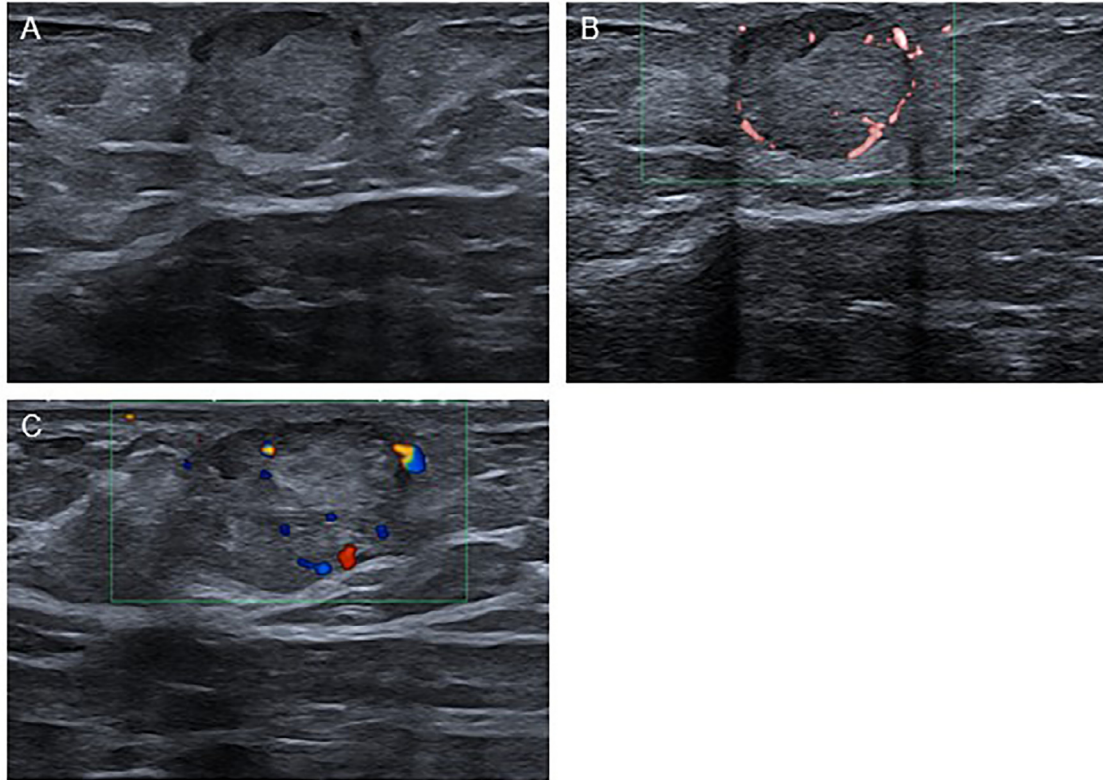


Fig. 1 – Initial ultrasound of right axillary lesion. (A) A well-circumscribed heterogeneous mass measuring 10 × 13 mm. Peripheral (B), and internal (C) vascularity on power Doppler and color Doppler respectively.

this entity. Recognition of suspicious clinical and radiological features that are not typical of a benign epidermoid cyst is pertinent for making a correct diagnosis.

Case report

A 75-year-old man presented to his general practitioner with a 3-month history of a painless lump in the right axilla. Examination revealed a discrete 3 cm soft mass within the skin of the chest wall in the mid-axillary line. There was some red discoloration of the overlying skin but no punctum and no signs of acute inflammation. There was no ipsilateral axillary lymphadenopathy. The differential diagnosis was between a sebaceous cyst or lipoma and an ultrasound examination was requested by the general practitioner. This showed a well-defined but heterogeneous mass in the skin measuring 10 × 13 mm with peripheral and central vascularization on color Doppler scanning (Fig. 1). As the lesion lay within the skin and had clinical features consistent with a sebaceous cyst, this was the presumed diagnosis. Nonetheless, on account of enhanced vascularity of the lesion on imaging, further radiological opinion was sought; the degree of vascularity was not considered typical of a benign sebaceous cyst and repeat sonographic assessment was arranged and undertaken after a COVID-19 related delay of 12 weeks. This revealed an increase in size of the mass that now measured 21 × 15 mm and displayed lobulations with marked internal vascularity

on Doppler. Moreover, the lesion encroached into the subcutaneous tissues but no axillary lymphadenopathy was seen. These appearances were concerning for a malignant lesion either of primary origin or a secondary deposit. Ultrasound-guided core biopsy was undertaken with a 16 G needle and 3 passes (Fig. 2).

The patient was subsequently referred for urgent assessment in the Cambridge Breast Unit where further enquiry revealed the patient to be otherwise well with no evidence of weight loss, back pain or cough and no history of previous skin cancer. He was a non-smoker with minimal alcohol intake and had non-insulin dependent diabetes mellitus. On further examination, there was a hard, irregular but mobile mass lying in the skin and subcutaneous tissues of the lateral chest wall in the region of the low axilla. This measured 3 cm in maximum diameter and was clinically suspicious with incipient ulceration of the overlying skin (Fig. 2). There was no axillary lymphadenopathy nor other chest wall lesions.

The case was reviewed at the breast multidisciplinary team meeting and histology revealed a malignant tumor comprised of sheets of basaloid cells with zones of overt sebaceous gland differentiation. There was prominent mitotic activity along with some apoptotic debris and moderate cellular pleomorphism within the basaloid cells. The sebaceous cells were seen to merge into squamous epithelium with keratinization and giant cells with fibrosis were present in the adjacent connective tissue. These features were consistent with a sebaceous carcinoma that was confirmed on subsequent immunohistochemistry (negative staining for MSH2 and MSH6 and positive

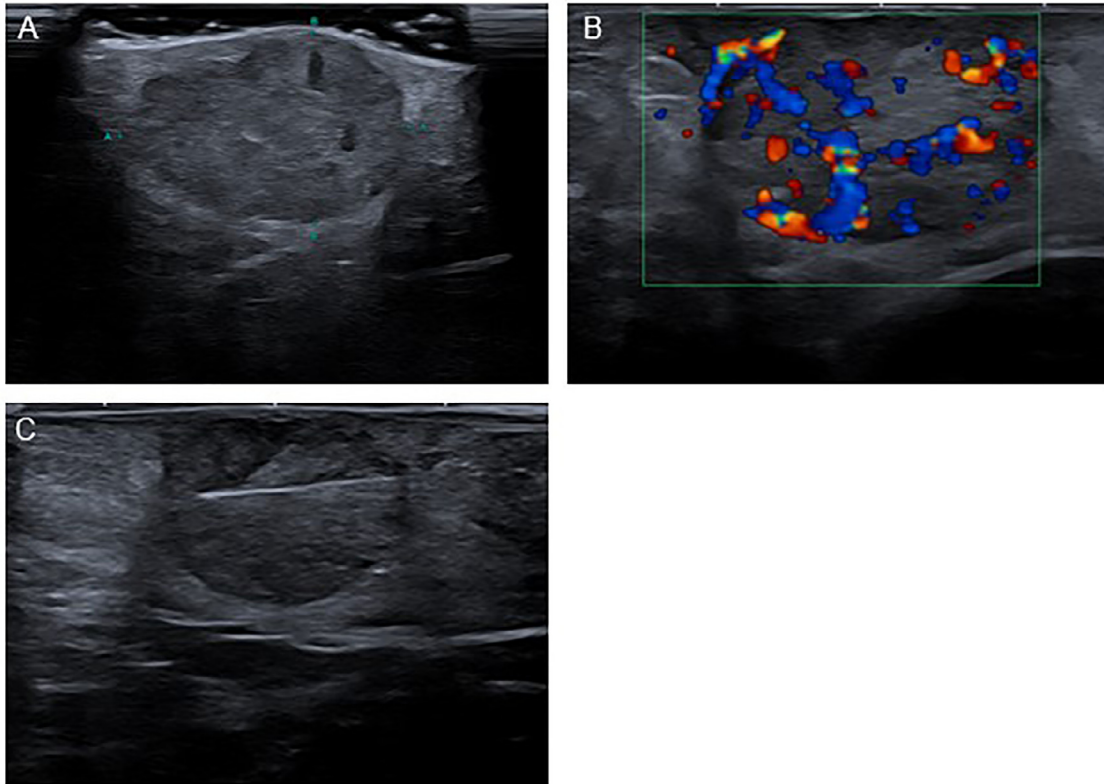


Fig. 2 – Repeat ultrasound of right axillary lesion after 12 wk. (A) Lobulated heterogenous mass measuring 15 x 21 mm within the subcutaneous tissue extending to the skin. (B) Marked internal vascularity on color Doppler imaging. (C) Ultrasound-guided core biopsy.

staining for MLH1 and PMS2). This immune-profile also raised the possibility of Lynch or Muir-Torre syndromes. A contrast-enhanced CT staging scan of the chest, abdomen and pelvis revealed no evidence of regional nodal nor distant metastatic disease.

The patient was referred to the skin and plastics multi-disciplinary teams for further management of this rare cutaneous malignancy. It was recommended the lesion be excised widely with a minimum surgical margin of clearance of 10 mm and ideally 20 mm. The location of the lesion permitted primary closure without excessive mobilization of tissues. No axillary surgical staging procedure was undertaken due to normality of nodes on imaging with both ultrasound and CT scan, but regular clinical follow up with an initial interval CT scan was arranged (Fig. 3).

Discussion

Sebaceous carcinoma is a rare malignant tumor of the sebaceous glands and extra-ocular lesions typically present as a painless skin lesion often involving the subcutaneous tissues. [4]. SC is referred to as the ‘great masquerader’ and differential diagnosis includes several inflammatory conditions as well as other tumors [5]. The differential diagnosis of a sebaceous carcinoma includes benign sebaceous (epidermoid) cysts, and the very rare skin malignancies of dermatofibrosarcoma protuber-

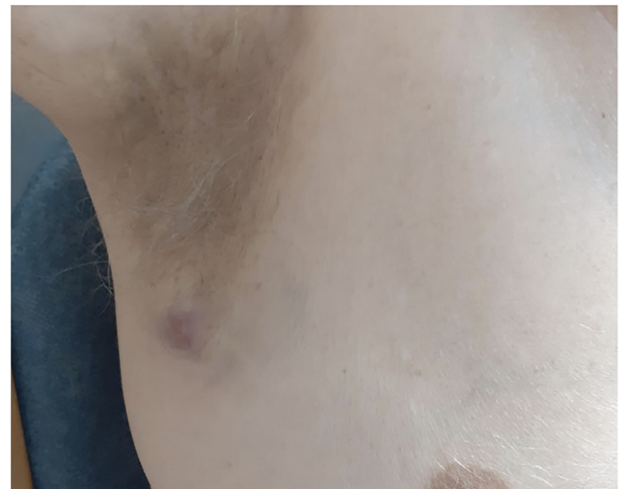

Fig. 3 – Clinical photography of the right axillary lesion prior to surgery.

ans and cutaneous B-cell lymphoma. [6–8] These lesions all can present with nodules in the skin with or without skin discoloration and as originate in the dermis, have similar appearances on ultrasound which are often non-specific.

In particular, SC may be clinically indistinguishable from a benign sebaceous (epidermoid) cyst, but suspicious should be raised when such a lesion is growing, is recurrent or has any

atypical features. A benign epidermoid cyst is a smooth, well-defined lesion contained within the skin and without demonstrable internal vascularity on Doppler scanning. As sebaceous cysts are very common, it is possible for clinicians to be diagnostically complacent; they should maintain an index of suspicion for other benign and malignant skin lesions and ensure that biopsy (needle or excision) is performed when tissue acquisition is warranted for diagnostic uncertainty. Nonetheless, there can be variable histological as well as clinical and radiological features of SC that may delay definitive diagnosis and commencement of treatment. When a benign diagnosis is made initially, patients must be informed that any increase in size of the lesion or change in the overlying skin is a reason for further clinical review. However, patients should not be routinely following up for an otherwise typical benign sebaceous cyst.

SC is associated with the Muir-Torre syndrome linked to mutations in the MLH1 or MSH2 genes with an autosomal dominant pattern of inheritance. The syndrome is associated with sebaceous skin tumors (including adenoma and carcinoma) together with internal malignancy most commonly of the gastrointestinal and genitourinary tracts [9–10]. In this patient, microsatellite instability was found in the MLH1 and PMS2 genes with immunohistochemistry, but with negative findings for the MSH-6 genes. Details of the molecular pathogenesis of SC remains to be elucidated, and further research will provide additional insights into molecular mechanisms underlying this rare malignancy of the skin. Interestingly, there are variable histological patterns described for SC associated with Muir-Torre syndrome and these lesions can either precede or follow malignancy of the internal organs [11]. Early diagnosis and recognition of SC can raise suspicion for a diagnosis of Muir-Torre syndrome and ultimately improve both morbidity and mortality for patients affected by this syndrome. The latter should undergo regular and long-term surveillance for other malignancies (most commonly colorectal and renal tract tumors) that can be detected at an earlier stage with dramatic improvements in prognosis [12].

The primary treatment approach for SC is wide local excision or more targeted Moh's micrographic surgery. Overall rates of local recurrence range from 12%–32% with a broad range of follow up (5–71 mo) in reported series. Rates of local recurrence are generally higher following wide local excision (11%–36%) than micrographic surgery (6.4%–11%), although have fallen in the past 15 years for widely excised ocular SC [13]. When the SC occurs in the axillary region, sentinel lymph node biopsy may be offered for surgical staging of the axilla when nodal metastases are suspected on imaging (despite normal needle biopsy of axillary nodes) [9].

Conclusion

This case report illustrates how a rare form of skin cancer can initially present with clinical features that mimic a common

skin lesion with suspicion raised on subsequent ultrasound examination. Delayed investigation in this case due to COVID-19 permitted clinical progression of the lesion. Atypical clinical features such as rapidly changing size or skin changes should prompt ultrasound examination with assessment of vascularity. Once a diagnosis of SC is established histologically, syndromes such as Muir-Torre should be considered as these are associated with potentially life-threatening malignancies that can be screened for with improvement in prognosis.

Patient consent

The patient has given signed consent for the use of his medical records and imaging to be used in education and in publication of this case report.

REFERENCES

- [1] Wick MR, Goellner JR, Wolfe JT 3rd, Su WP. Adnexal carcinomas of the skin II. Extraocular sebaceous carcinomas. *Cancer* 1985;56(5):1163–72.
- [2] Shalin SC, Lyle S, Calonje E, Lazar AJ. Sebaceous neoplasia and the Muir-Torre syndrome: important connections with clinical implications. *Histopathology* 2010;56(1):133–47.
- [3] Xu Y, Li F, Jia R, Fan X. Updates on the clinical diagnosis and management of ocular sebaceous carcinoma: a brief review of the literature. *OncoTargets and Therapy* 2018;11:3713–20.
- [4] Kylo RL, Brady KL, Hurst EA. Sebaceous carcinoma: review of the literature. *Dermatol Surg* 2015;41(1):1–15.
- [5] Buitrago W, Joseph AK. Sebaceous carcinoma: the great masquerader. *Dermatol Ther* 2008;21(6):459–66.
- [6] Vitiello P, Sica A, Ronchi A, Caccavale S, Franco R, Argenziano G. Primary cutaneous B-Cell lymphomas: an update. *Front Oncol* 2020(10):1–7.
- [7] Zhou AY, Chin J, Strutin MD, Lomiguen CM. Unmasking dermatofibrosarcoma protuberans: Case report of an atypical presentation complicated by post-surgical excision. *Int J Surg Case Rep* 2020;69:101–4.
- [8] Allen A, Ahn C, Sangüeza OP. Dermatofibrosarcoma Protuberans. *Dermatol Clin* 2019;37(4):483–8.
- [9] Cieza-Díaz DE, Cano-Martínez N, Barchino-Ortiz L, Longo-Imedio I. Extraocular sebaceous carcinoma: a report of 2 cases. *Actas DermoSifiliogr* 2012;103(10):919–22.
- [10] Lazar AJF, Lyle S, Calonje E. Sebaceous neoplasia and Torre-Muir syndrome. *Curr Diagn Pathol* 2007;13(4):301–19.
- [11] De Leo A, Innocenzi D, Onesti MG, Potenza C, Toscani M, Scuderi N. Extraocular sebaceous carcinoma in muir-torre syndrome with unfavorable prognosis. *Cancer Chemother Pharmacol* 2006;58(6):842–4.
- [12] Harrington CR, Egbert BM, Swetter SM. Extraocular sebaceous carcinoma in a patient with muir-torre syndrome. *Dermatol Surg* 2004;30(5):817–19.
- [13] Xu Y, Li F, Jia R, Fan X. Updates on the clinical diagnosis and management of ocular sebaceous carcinoma: a brief review of the literature. *Onco Targets Ther* 2018;11:3713–20.