



Clinical Case Studies

Dual expandable interbody cage utilization for enhanced stability in vertebral column reconstruction following thoracolumbar corpectomy: A report of two cases [☆]

Michael Kwok ^{a,1,*}, Andrew S. Zhang ^{b,1}, Kevin J. DiSilvestro ^b, J. Andrew Younghein ^b, Eren O. Kuris ^b, Alan H. Daniels ^b

^a Alpert Medical School of Brown University, Providence, RI 02903, United States

^b Department of Orthopaedic Surgery, Brown University and Rhode Island Hospital, Providence, RI 02903, United States



ARTICLE INFO

Keywords:

Thoracic Corpectomy
Vertebral Body Replacement
Dual Expandable Interbody Cage
Burst Fracture
Plasmacytoma

ABSTRACT

Background: Thoracolumbar corpectomies require adequate anterior column spinal reconstruction, often achieved through a single static or expandable cage. Patients with larger vertebrae, or those who require a larger footprint of reconstruction placed via a posterior approach are technically challenging. The aim of this report was to describe a novel approach for reconstruction using two smaller expandable cages following corpectomy, in the setting of tumor and trauma.

Methods: These technical reports illustrate a novel intraoperative technique with reconstruction via dual expandable cages implanted posteriorly from a bilateral costotransversectomy and transpedicular approaches. Due to the smaller size of each cage, implantation in the vertebral column was achieved with minimal retraction of the spinal cord.

Results: Two patients underwent urgent corpectomy in the thoracolumbar spine using this technique. Clinical improvement was evident post-surgery and adequate spine stabilization was confirmed radiographically without cage migration or subsidence, at up to one year of clinical follow up. No iatrogenic neurological deficits were reported in each case as well.

Conclusion: To the authors' knowledge, this is the first report of a corpectomy where this surgical technique was implemented in the thoracolumbar spine. This technique created a large footprint of reconstruction with less retraction on the spinal cord during surgery, reducing the potential for neurological complications. An alternative strategy is to place a larger footprint reconstruction through an anterior or lateral approach; however, these techniques also have potential morbidity which require consideration.

Introduction

Corpectomy of the thoracolumbar spine is indicated for a multitude of reasons including trauma, tumor, deformity, advanced degenerative disease and infection which may manifest in cord compression, neurologic impairment and/or spinal instability [1,2].

Corpectomies may be accomplished through a multitude of approaches. Posterior approaches have been associated with less intraoperative blood loss, complications, shorter operative time, and better pulmonary function post-operation compared to anterior approaches [3]. Alternatively, anterior approaches create the most access to the verte-

bral body and allow for considerable anterior column manipulation with less risk of spinal cord injury [1]. The lateral extracavitary approach provides good visualization and circumferential reconstruction; however, early literature reported significant complication rates, long operative times, prolonged hospitalizations post-surgery and concerns for subsidence with expandable cages [4]. Ultimately, the approach chosen will be dictated by patient-specific anatomical considerations and surgeon preference.

Following successful corpectomy, conventional vertebral body reconstruction options include use of mesh cages, expandable cages, static spacers, strut grafts, plates and screw/rod fixation. While mesh cages were initially the mainstay for reconstruction, expandable cages now have become popularized as they help reduce subsidence, correct sagit-

[☆] Summary Sentence: @BrownUniversity spine surgeons develop novel posterior-only technique for reconstruction of three column involvement in tumor and trauma

* Corresponding author at: MS, 222 Richmond Street, Providence, RI 02912.

E-mail address: michael_kwok@brown.edu (M. Kwok).

¹ Co-First Author Designation.

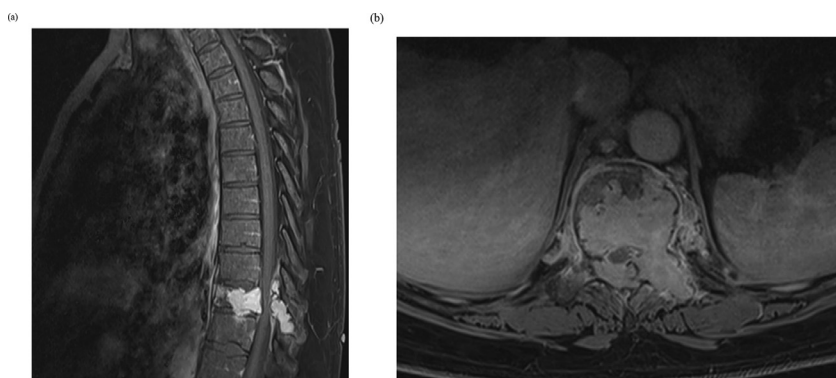


Fig. 1. Sagittal (a) and Axial (b) T1 Post Gadolinium MRI: Expansile lytic lesion involving the T10 vertebral body and posterior elements with pathologic fracture and epidural compression.

tal deformity, are often technically less challenging and create a tighter fit during posterior approaches [1,5].

If a posterior approach corpectomy is performed and an expandable cage is utilized for vertebral replacement, the use of a single cage is currently considered standard of care. The cases presented here highlight a novel posterior-approach surgical technique involving bilateral implantation of two mini expandable cages to optimize stabilization while potentially minimizing iatrogenic injury.

Materials and methods

We present two cases of vertebral body destruction with significant retropulsion requiring corpectomy with bilateral expandable cage implantation for vertebral canal reconstruction from the posterior approach. These two cases represent a novel surgical technique for patient care and consent from the institutional review board was not necessary. We evaluate the potential advantages and limitations of the technique, and the clinical presentation and radiographic data of both cases prior to the surgery in this report. We also describe the surgical technique completed in each individual case.

Results

Surgical techniques

Case 1: Oncology

A 48-year-old male with a history of acute on chronic low back pain, erythrocytosis and obstructive sleep apnea was evaluated for acute onset left-sided abdominal paresthesias and backache after an exertion injury a week prior. Screening cervical, thoracic, lumbar MRI and cervical CT scan revealed an expansile lytic lesion involving the T10 vertebral body and posterior elements with pathologic fracture (Figs. 1 and 2). Chest, abdomen, and pelvis CT revealed no solid tumor or metastasis. A CT-guided core biopsy of the T10 vertebral body was performed at the behest of the oncology team to guide treatment, with final pathology revealing solitary bone plasmacytoma (SBP). On spine evaluation, a Spinal Instability Neoplastic Score (SINS) of 13 out of 18, near total destruction of the vertebral body, and retropulsion of the posterior vertebral body with epidural compression warranted surgical intervention to restore spinal stability.

The patient was taken to the operating room where he underwent a single stage, posterior approach for T10 corpectomy, T9 – T11 laminectomy and anterior spinal fusion, and T8 – T12 posterior pedicle fixation. With neuromonitoring established with baseline somatosensory evoked potentials (SSEPs) and motor evoked potentials (MEPs) obtained without deficit, a standard subperiosteal dissection was carried out over T8-T12. Pedicle screws were inserted bilaterally into T8, T9, T11 and T12 and were augmented with cement vertebroplasty due to plans for post-operative adjuvant radiotherapy. Laminectomy was performed to excise the intraspinal extradural component of the neoplasm at the T10 level,

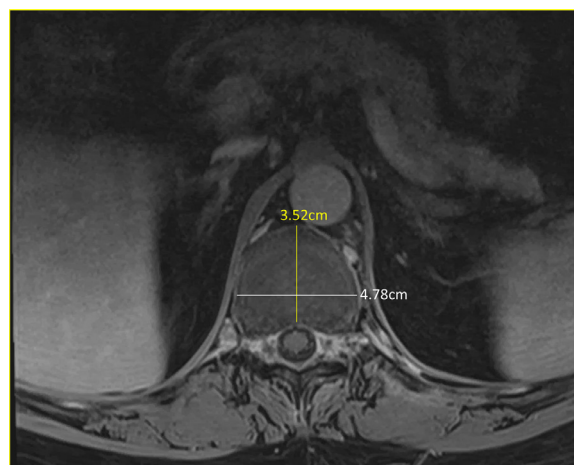

Fig. 2. Axial T1 MRI Thoracic Spine Post-Gadolinium: superior endplate of the caudal T11 vertebral body indicating larger footprint of reconstruction required during VBR.

which was collected and sent for pathology analysis. Next, the left T10 nerve root was ligated and divided to access the vertebral body. Vertebrectomy was completed via bilateral costotransversectomies and again sent to pathology. Discectomies of T9-10 and T10-11 were performed and endplates were prepared. Two 12mm inner diameter core expandable cages with 14mm diameter footprints were then placed adjacent to each other to reconstruct the anterior column. The cages were expanded to approximately 275mm. No temporary rods were placed. The anterior column was then prepared for bone grafting and fusion. Compression was performed across the T9-T11 segment secure the cage reconstruction and increase stability. Screws were final tightened. Allograft fibula struts were placed across the zones of decortication along the posterior column. The fibulas were then locked with cross-links and more bone graft placed across T8-T12 (Fig. 3). Final x-rays were obtained (Fig. 4). A standard multilayer closure was then achieved. The patient tolerated the procedure well and without complication.

At the one year follow-up, adequate thoracic spine stabilization was maintained without cage migration or subsidence observed radiographically (Fig. 5). No neurological deficits were reported at that time.

Case 2: Trauma

A 46-year-old female was involved in a motor vehicle collision, sustaining an L1 burst fracture with significant retropulsion (Figs. 6 and 7). Her presenting spine evaluation was concerning for an incomplete spinal cord injury as she had 0/5 strength throughout her right lower extremity, while her left lower extremity demonstrated 2/5 S1 function. She had limited pinprick sensation along the L1-S1 distributions bilaterally.

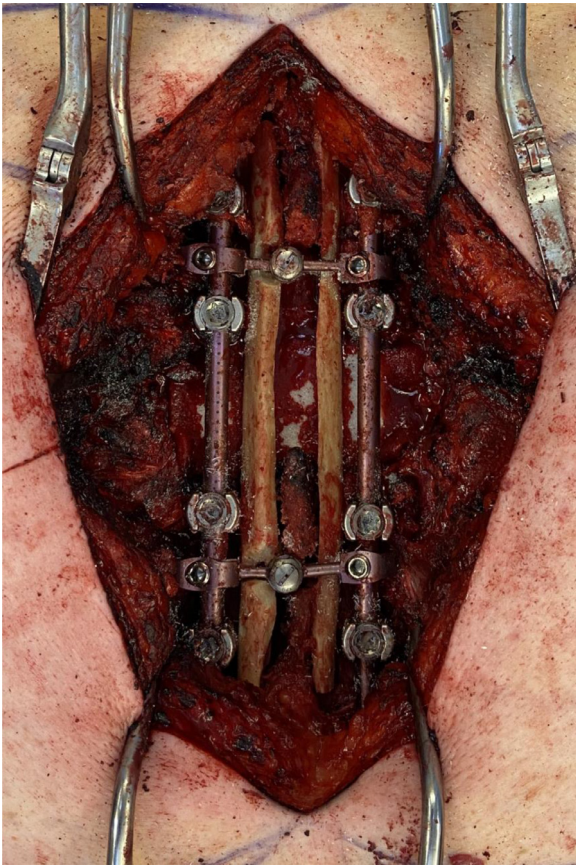


Fig. 3. Intra-operative view of the posterior approach for vertebral body reconstruction.

Her rectal tone and squeeze were markedly diminished and otherwise did not show any pathological reflexes.

The patient was taken to surgery with concern for conus medullaris syndrome. Neuromonitoring was established and baseline signals showed motor activity only to the left tibialis anterior intact within the bilateral lower extremities. After careful prone positioning, no changes were noted with neuromonitoring. A standard approach to the thora-

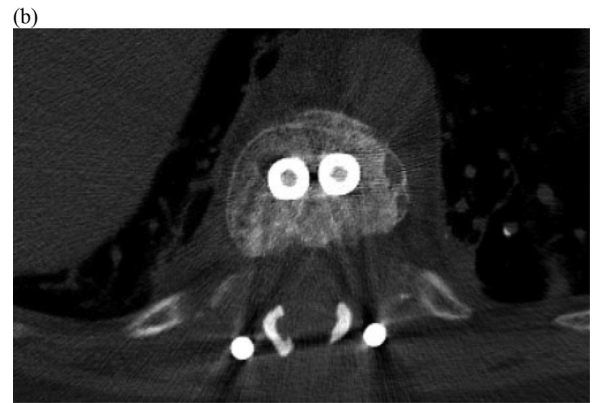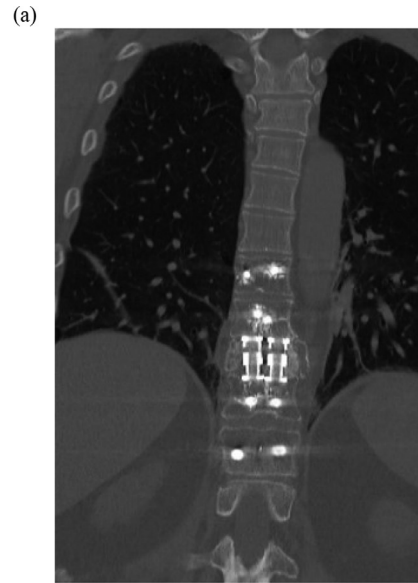


Fig. 5. Coronal (a) and axial (b) CT Thoracic Spine Without IV Contrast at 6-month follow up showing arthrodesis across the corpectomy defect

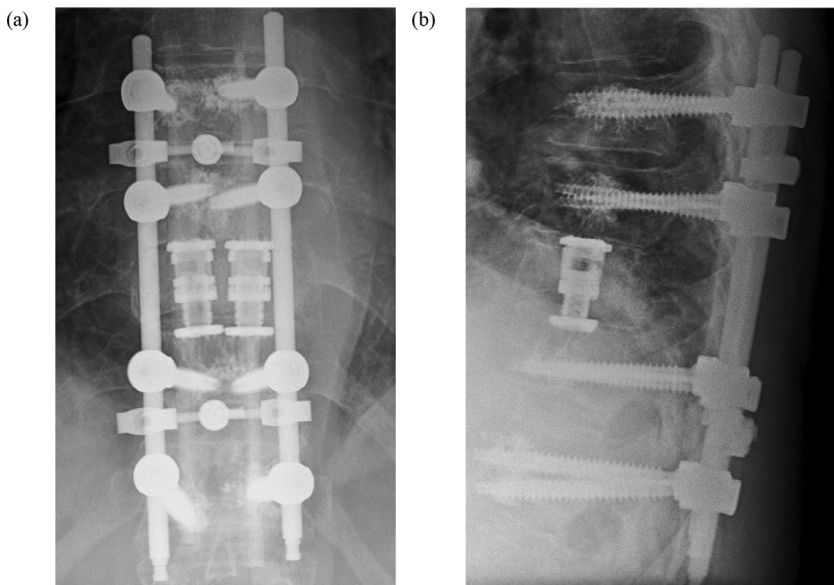


Fig. 4. AP (a) and lateral (b) radiographs of the thoracic spine showing bilateral expandable cage placement during vertebral body reconstruction.

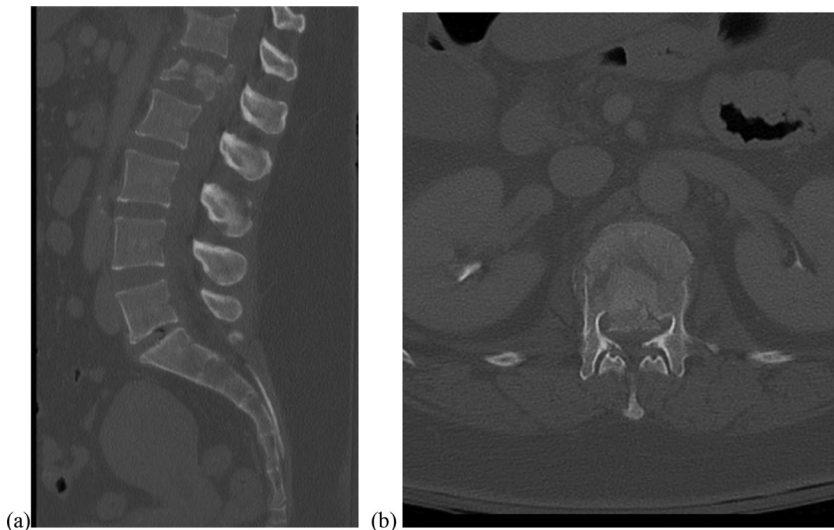


Fig. 6. Representative mid-sagittal (a) and axial (b) CT cuts of L1 burst fracture with significant bony retropulsion.

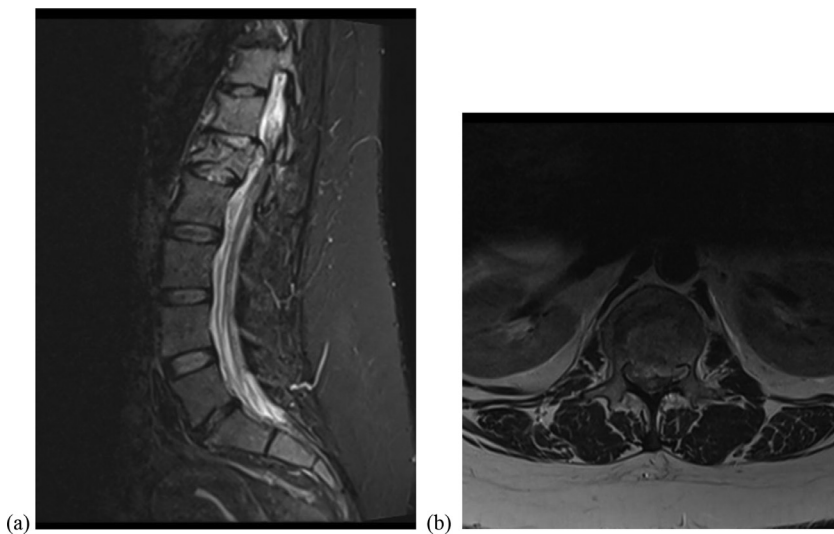


Fig. 7. Representative mid-sagittal STIR MRI (a) and T2 sequence MRI (b) of L1 burst fracture demonstrating cord compression.

columbar spine was carried out, centered on T11-L3. Freehand bilateral pedicle screws were placed at the T11, T12, L2 and L3 levels and subsequently confirmed with fluoroscopy. Laminectomies of T12 and L1 were then performed, and the T12 and L1 nerve roots were identified bilaterally. The dura appeared to be intact without a traumatic tear or leak, but there was tear of the left L1 dural root sleeve. The L1 pedicles were then subtracted bilaterally, and the retropulsed fragment was visualized directly and resected. Neuromonitoring immediately showed improved SSEPs and MEPs. The T12-L1 and L1-L2 intervertebral discs were also resected and the inferior endplate of T12 and superior endplate of L2 were prepared for fusion. At this time, the decision was made to place bilateral expandable cages (14mm diameter footprint, 12mm inner diameter cage core, expanded to approximately 340mm). No temporary rods were placed. After fluoroscopy confirmed excellent centered positioning on AP and lateral views, bone morphogenic protein and bone graft were placed anterior and lateral to the cages. Longitudinal rods were placed within the tulips of the pedicle screws and locked in place with set screws. Compression was performed across the corpectomy to enhance lordosis. Cross links were placed. Set screws were final tightened. An extensive posterolateral fusion bed was prepared and grafted. Final x-rays were obtained (Fig. 8). A standard multilayer closure was then achieved. The patient tolerated the procedure well and without complication, subsequently being discharged to an inpatient rehabilitation facility by postoperative day six.

At the five-month post-operative follow-up, the patient demonstrated return of motor function to the right lower extremity from the L1-

S1 nerve distributions with intact sensation. Radiographs did not show any hardware failure or subsidence at that time (Fig. 9).

Discussion

Vertebral body reconstruction (VBR) has been described for several etiologies in which anterior column support has been significantly compromised. This has conventionally been accomplished through an anterior approach with or without supplemental posterior instrumentation [6–9]. However, posterior-only approaches have been gaining traction recently, as they have been seen as reproducible, less morbid and equally efficacious [10–13].

In tumor surgery, posterior reconstructions previously involved the use of polymethylmethacrylate and Steinmann pins [6,14], and has since evolved to the use of cages due to concern for exothermic heat causing tissue and neural injury [10,13,15–17]. Shen et al. used a posterior-only extracavitary approach to address anterior vertebral body tumors to implant a large expandable cage for reconstruction of the anterior column [10]. In their technique, a large collapsed cage was implanted 90 degrees from the axial plane of the spine and in between nerve roots, and then turned 90 degrees to expand parallel to the vertebral endplates, to avoid neural injury [15]. This technique has been since modified by various surgeons with similar effectiveness [16,17].

In our case series, we were able to circumvent some of the challenging aspects of these previously-described techniques with use of our own novel method. Due to the extensive three-column involvement of the

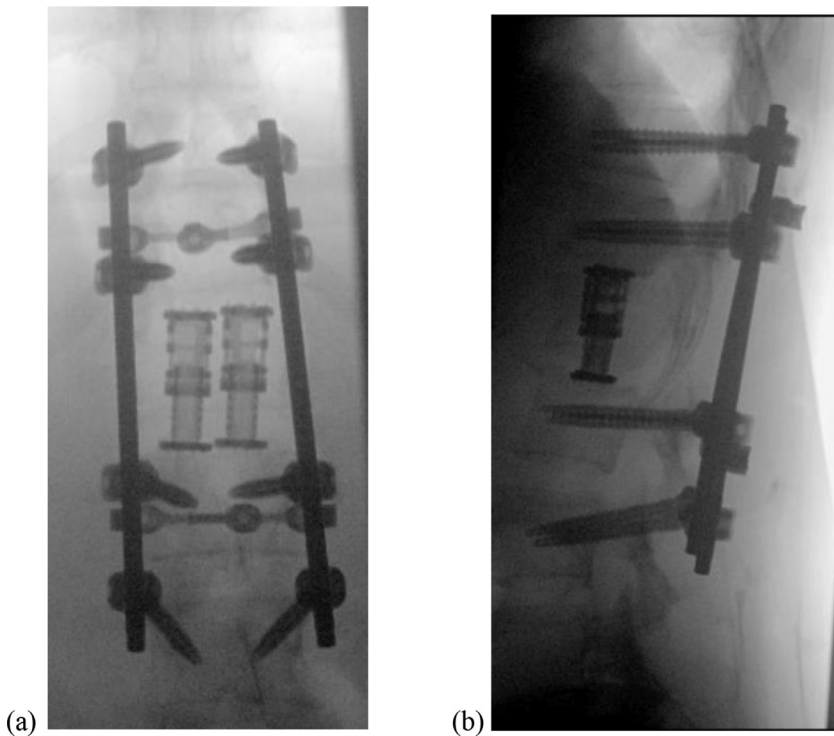


Fig. 8. Final intraoperative AP (a) and lateral (b) radiographs for L1 vertebral body reconstruction with bilateral expandable cages.

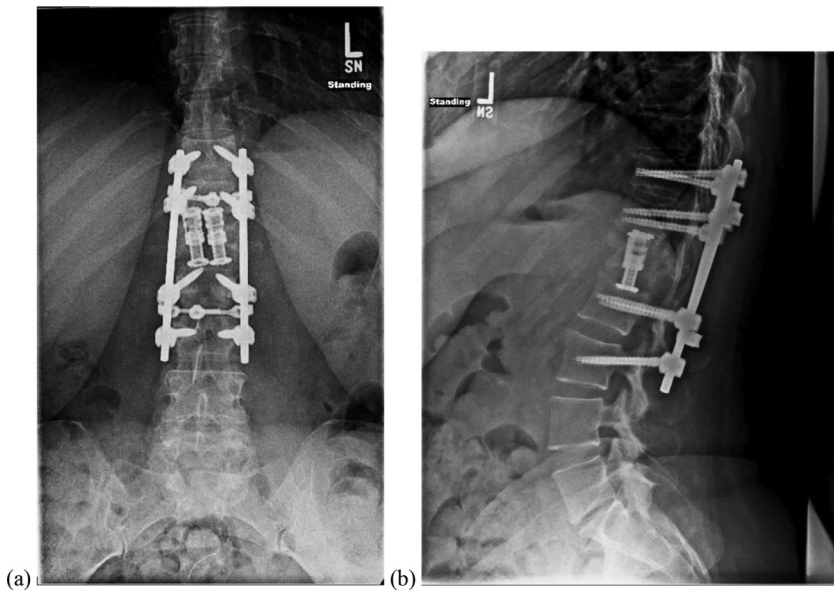


Fig. 9. Standing AP (a) and lateral (b) radiographs of Patient #2 at five-month follow-up outpatient visit, demonstrating no evidence of hardware failure or subsidence of dual cage construct.

SBP rendering the spine unstable in our patient, VBR was indicated. We report a successful posterior-approach corpectomy of our patient, who had a height of 188.8 cm and a BMI of 32.6. Fig. 2 shows the anatomy of the patient's superior endplate of the caudal T11 vertebral body. Because of this patient's anatomy, minimizing spinal cord retraction on cage implantation was paramount, while still attempting to maximize footprint of reconstruction. While use of a single cage with large footprints was a reconstructive option, we alternatively elected to sequentially implant two mini expandable cages bilaterally at T10 to achieve our goals of reducing neural manipulation while maintaining a substantial surface area for reconstruction (Fig. 4).

Single-stage posterior-only approaches have also been used to treat traumatic injuries to the thoracolumbar spine, reconstructing with large titanium mesh cages [18] and expandable cages [12]. The burst fracture presented in this report resulted in severe retropulsion, compromising the spinal cord and neurologic function. In order to adequately decom-

press the spinal cord and evacuate the retropulsed bone, a significant amount of the fractured vertebral body was excised, rendering the remaining body unviable and unstable. The decision was made to proceed with VBR. Again, to avoid the difficulties and potential morbidities with inserting larger, previously described implants, dual mini expandable cages were utilized to provide greater stability without provoking even more damage to an already-injured spinal cord.

Maximizing cage reconstruction should be carefully weighed against the amount of potential iatrogenic injury that can be caused during implantation. In both cases, retraction of the spinal cord was necessary bilaterally; however, the cumulative magnitude of retraction in each direction was less compared to installation of a single larger cage, which is an especially important consideration when operating at cord-level. Additionally, when larger cages are implanted, nerve roots are often ligated and sacrificed in order to obtain adequate exposure for the cage [19]. An alternative to placing a larger cage requiring manipulation of the dura

and nerve roots would be through a lateral or anterior approach; however, those techniques are inherently morbid as well and cannot achieve other objectives such as wide posterior decompression during the same exposure [1].

Overall, bilateral implantation of two cages may help reduce potential complications of VBR - implant migration, cage subsidence and pseudoarthrosis [20]. Risk of developing spinal instability, impingement of the spinal cord and vascular structures, or continued pain after surgery are theoretically reduced. Additionally, as implantation of two smaller expandable cages results in less cumulative retraction of the spinal cord and nerve roots in each direction, risk of damage to neurological structures or dural tear may be expectantly lower [17,21]. As a result, persistent pain, loss of sensation or function from iatrogenic injury would be potentially reduced.

There are certain limitations to this report. First, this technique was only performed on two patients. The technique itself of bilateral expandable cage implantation for VBR may also have some limitations. Surgeons and hospital administration may scrutinize the additional cost associated with a second cage as opposed to a single one. Additionally, while retraction of the neural elements is theoretically less overall and less forceful with this novel technique, the total magnitude is not easily quantified and may not be significantly less when compared with other posterior techniques. Bidirectional cord retraction is necessary and may be associated with bilateral functional or sensory deficits during implantation, and this technique may, in theory, double the risk of cord injury in the hands of less-experienced surgeons.

Conclusion

Bilateral expandable cage implantation for vertebral column reconstruction from the posterior approach should be considered in patients who require significant anterior column stabilization while minimizing thecal sac manipulation. Of the patients presented here, follow up revealed radiographic films confirming stabilization without cage migration or subsidence and no evidence of neurological deficit in both patients. In cases of similar complexity or with similar patient profiles, this technique has been shown to be a viable option and should be considered when planning reconstruction.

Informed Patient Consent

The authors declare that informed patient consent was taken from all the patients.

Declaration of Competing Interest

The authors declare that they have no known competing financial interests or personal relationships that could have appeared to influence the work reported in this paper

Conflicts of Interest (AHD):

EOS: Paid consultant

Medicrea: Paid consultant

Medtronic Sofamor Danek: Paid consultant

Novabone: Paid consultant

Orthofix, Inc.: Paid consultant; Research support

Southern Spine: IP royalties

Spineart: IP royalties; Paid consultant

Springer: Publishing royalties, financial or material support

Stryker: Paid consultant

Funding

This research did not receive any specific grant from funding agencies in the public, commercial, or not-for-profit sectors.

References

- [1] Puvanesarajah V, Lina IA, Liauw JA, et al. Systematic approach for anterior corpectomy through a transthoracic exposure. *Turk Neurosurg* 2016 Published online. doi:10.5137/1019-5149.JTN.15271-15.1.
- [2] Cappelletto B, Giorgiutti F, Balsano M. Evaluation of the effectiveness of expandable cages for reconstruction of the anterior column of the spine. *J Orthop Surg* 2020 Published online. doi:10.1177/2309499019900472.
- [3] Lin B, Chen Z, Guo Z, Liu H, Yi Z. Anterior approach versus posterior approach with subtotal corpectomy, decompression, and reconstruction of spine in the treatment of thoracolumbar burst fractures. *J Spinal Disord Tech* 2011 Published online. doi:10.1097/bsd.0b013e3182204c53.
- [4] Holland CM, Bass DI, Gary MF, Howard BM, Refai D. Thoracic lateral extracavitary corpectomy for anterior column reconstruction with expandable and static titanium cages: Clinical outcomes and surgical considerations in a consecutive case series. *Clin Neurol Neurosurg* 2015 Published online. doi:10.1016/j.clineuro.2014.11.022.
- [5] Papanastassiou ID, Gerochristou M, Aghayev K, Vrionis FD. Defining the indications, types and biomaterials of corpectomy cages in the thoracolumbar spine. *Expert Rev Med Devices* 2013 Published online. doi:10.1586/erd.12.79.
- [6] Gokaslan ZL, York JE, Walsh GL, et al. Transthoracic vertebrectomy for metastatic spinal tumors. *J Neurosurg* 1998;89:599-609.
- [7] Hall DJ, Webb JK. Anterior plate fixation in spine tumor surgery. Indications, technique, and results. *Spine* 1991;16:S80-3.
- [8] Hosono N, Yonenobu K, Fujii T, Ebara S, Yamashita K, Ono K. Vertebral body replacement with a ceramic prosthesis for metastatic spinal tumors. *Spine* 1995;20:2454-62.
- [9] Oprel P, Tuinebreijer P, Patka WE, den Hartog PD. Combined anterior-posterior surgery versus posterior surgery for thoracolumbar burst fractures: a systematic review of the literature. *Open Orthop J* 2010;4:93-100.
- [10] Shen FH, Marks I, Shaffrey C, Ouellet J, Arlet V. The use of an expandable cage for corpectomy reconstruction of vertebral body tumors through a posterior extracavitary approach: a multicenter consecutive case series of prospectively followed patients. *Spine J* 2008;8(2):329-39 Mar-AprEpub 2007 Jun 21. PMID: 17923442. doi:10.1016/j.spinee.2007.05.002.
- [11] Meyer M, Noudel R, Farah K, Graillon T, Prost S, Blondel B, Fuentes S. Isolated unstable burst fractures of the fifth lumbar vertebra: functional and radiological outcome after posterior stabilization with reconstruction of the anterior column: about 6 cases and literature review. *Orthop Traumatol Surg Res* 2020;106(6):1215-20 OctEpub 2020 Apr 27. PMID: 32354682. doi:10.1016/j.otsr.2020.03.014.
- [12] Sasani M, Ozer AF. Single-stage posterior corpectomy and expandable cage placement for treatment of thoracic or lumbar burst fractures. *Spine* 2009;34(1):E33-40 Jan 1PMID: 19127146. doi:10.1097/BRS.0b013e318189fcfd.
- [13] Lu DC, Lau D, Lee JG, Chou D. The transpedicular approach compared with the anterior approach: an analysis of 80 thoracolumbar corpectomies. *J Neurosurg Spine* 2010;12(6):583-91 JunPMID: 20515342. doi:10.3171/2010.1.SPINE09292.
- [14] Bilsky MH, Boland P, Lis E, Raizer JJ, Healey JH. Single-stage posterolateral transpedicle approach for spondylectomy, epidural decompression, and circumferential fusion of spinal metastases. *Spine*: 2000;25:2240-50.
- [15] Hunt T, Shen FH, Arlet V. Expandable cage placement via a posterolateral approach in lumbar spine reconstructions. Technical note. *J Neurosurg Spine* 2006;5(3):271-4 SepPMID: 16961091. doi:10.3171/spi.2006.5.3.271.
- [16] Morales Alba NA. Posterior placement of an expandable cage for lumbar vertebral body replacement in oncologic surgery by posterior simple approach: technical note. *Spine* 2008;33(23):E901-5 Nov 1PMID: 18978584. doi:10.1097/BRS.0b013e31818b8a06.
- [17] Jandial R, Kelly B, Chen MY. Posterior-only approach for lumbar vertebral column resection and expandable cage reconstruction for spinal metastases. *J Neurosurg Spine* 2013;19(1):27-33 JulEpub 2013 May 17. PMID: 23682809. doi:10.3171/2013.4.SPINE12344.
- [18] Alfaro-Micó J, Ramirez-Villaescusa J, Martinez-Lozano MD, Sanchez-Honrubia RM, Ruiz-Picazo D. Emergency stabilisation by single-stage posterior transpedicular approach for treatment of unstable lumbar spine fracture with neurological injury. *Trauma Case Rep* 2020;27:100300 Apr 16PMID: 32322650; PMCID: PMC7162966. doi:10.1016/j.tcr.2020.100300.
- [19] Joubert C, Adetchessi T, Peltier E, et al. Corpectomy and vertebral body reconstruction with expandable cage placement and osteosynthesis via the single stage posterior approach: a retrospective series of 34 patients with thoracic and lumbar spine vertebral body tumors. *World Neurosurg* 2015 Published online. doi:10.1016/j.wneu.2015.06.072.
- [20] Ramírez JJ, Chiquete E, Ramírez JJ, Gómez-Limón E, Ramírez JM. An expandable prosthesis with dual cage-and-plate function in a single device for vertebral body replacement: clinical experience on 14 cases with vertebral tumors. *Arch Med Res* 2010 Published online. doi:10.1016/j.arcmed.2010.08.013.
- [21] Baker GA, Cizik AM, Bransford RJ, et al. Risk factors for unintended durotomy during spine surgery: a multivariate analysis. *Spine J* 2012 Published online. doi:10.1016/j.spinee.2012.01.012.