

## Atlantoaxial Dislocation with Bony Fusion of C1/2 Facet Joints Treated with Posterior Joint Release, Distraction and Reduction

Zhenlei Liu<sup>1,2)</sup>, Qiang Jian<sup>1)</sup>, Wanru Duan<sup>1,2)</sup>, Jian Guan<sup>1,2)</sup>, Can Zhang<sup>1,2)</sup>, Boyan Zhang<sup>1)</sup>, Fengzeng Jian<sup>1,2)</sup> and Zan Chen<sup>1,2)</sup>

1) Department of Neurosurgery, Xuanwu Hospital, Capital Medical University, Beijing, China

2) Spine Center, China International Neuroscience Institute, Beijing, China

### Abstract:

**Introduction:** Atlantoaxial dislocation (AAD) is a complicated and challenging deformity with severe morbidities. Irreducible AAD with C1/2 bony fusion requires anterior (transoral or transnasal) odontoidectomy to decompress spinal cord or medulla, which is highly demanding technique that is risky for comorbidities. Here, we report our application of modified Goel's technique to reduce AAD with bony fusion through single-stage posterior approach surgery.

**Technical Note:** Our technique that can reduce AAD with bony fusion through single-stage posterior approach surgery is reported. Joint release, distraction, cage implantation, and atlantoaxial or occipitocervical fixation can successfully manage AAD with C1/2 bony fusion. Key points for the technique include pinpointing original joint space, thorough release of bony fusion, stepwise distraction, and cage implantation with autograft.

**Conclusions:** Joint release, distraction, cage implantation, and atlantoaxial or occipitocervical fixation can successfully manage bony irreducible AAD. This technique provided an option for bony fused AAD and improved safety and efficacy of its management.

### Keywords:

Atlantoaxial Dislocation, Basilar Invagination, Irreducible, Bony Fusion, Posterior Approach

Spine Surg Relat Res 2022; 6(2): 175-180

dx.doi.org/10.22603/ssrr.2021-0058

### Introduction

Atlantoaxial dislocation (AAD) with or without basilar invagination (BI) is a rare and complicated deformity with severe morbidities<sup>1)</sup>. Reconstruction of atlantoaxial stability and decompression of spinal cord or medulla oblongata are purposes of surgical management for the deformity<sup>2)</sup>. The concept of reducible or irreducible AAD is the determinant of surgical approach and is thus the topic of debate and in evolution for decades<sup>3-5)</sup>. With advances in the understanding of the AAD pathological mechanism and surgical instruments, some AADs that cannot be reduced by cranial traction before surgery can now be reduced by intraoperative traction under general anesthesia, after transoral odontoid release or posterior intra-articular release, which makes the boundary between "reducible" and "irreducible" indistinct.

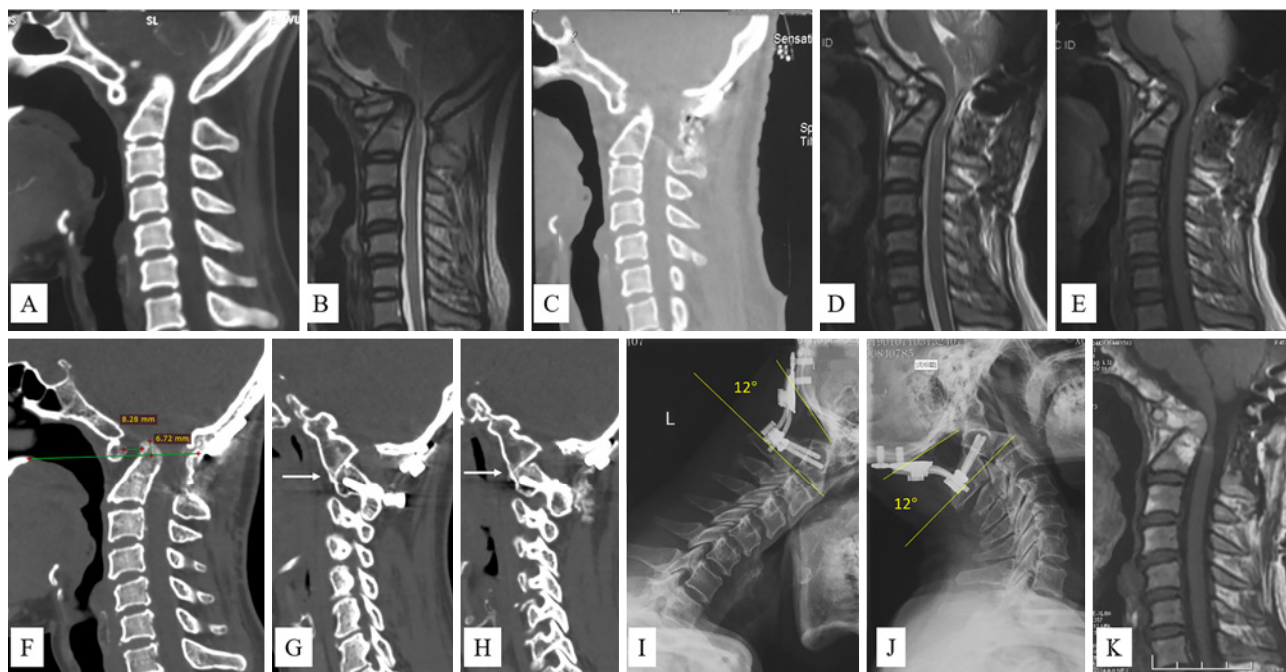
However, AAD with C1-2 bony union is truly irreducible with no reduction of the odontoid process even after traction and transoral release. For this fixed type of AAD, odontoid

resection with the anterior approach (transoral or transnasal) to decompress spinal cord or medulla is the first choice<sup>5,6)</sup>. Unfortunately, this surgery is a highly demanding technique that is risky for comorbidities, such as surgical site infection, dura laceration, and neural element injury<sup>7)</sup>.

In our practice on this entity for more than 10 years, we found Goel's technique, posterior intra-articular cage implantation, very powerful for reduction of odontoid<sup>8)</sup>. Here, we reported our application of modified Goel's technique to reduce fixed AAD with C1-2 bony fusion.

### Technical Note

Posterior midline approach C1/2 facet joints release, distraction with a cage and reduction of the odontoid process were implemented as below. After induction of general anesthesia and intubation, the patient was positioned prone with the head fixed with a Mayfield three-point head holder in a neutral position. Pressure points were well padded, and arms



**Figure 1.** Pre-revision surgery images of case 1.

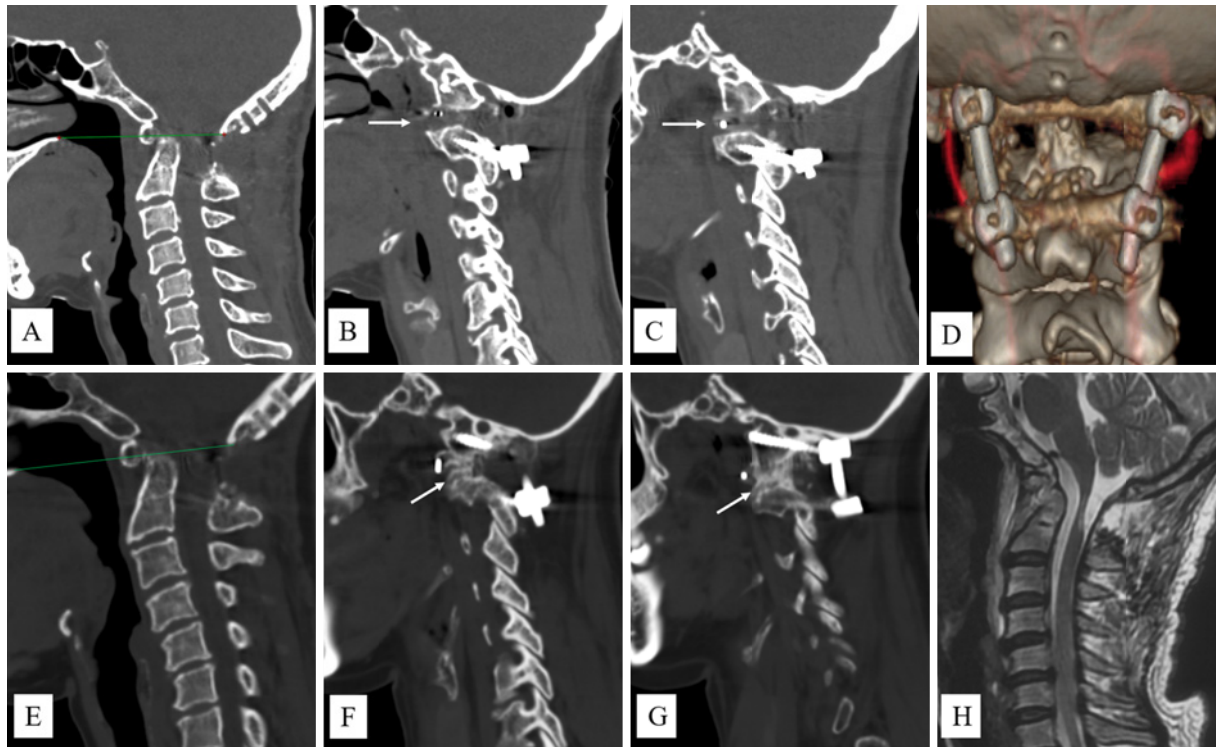
CT (A) and MRI (B) before index surgery showed BI and AAD compressing spinal cord. After the first surgery, insufficient reduction of dens (C) and minimal decompression of spinal cord (D, E) were achieved. CT (F) and MRI (K) before revision surgery BI and AAD compression spinal cord ventrally. Bilateral facet joints fused (G and H, arrows). Dynamic X-ray (I, J) showed no movement during flexion and extension.

were taped laterally. Neurophysiological monitoring was set if there was severe compression on the spinal cord or medulla. Midline incision was made from external occipital protuberance through the spinous process of C2 or C3. Soft tissue was dissected with monopolar cautery along the midline to expose occiput, posterior arch of atlas (occipitalization was common) and lamina of axis. Self-retractors were placed, and a microscope was brought into the surgical field. Caution should be taken when dissection along the posterior arch of atlas exceeding 1.5 cm lateral to midline to not injure vertebral arteries (VAs). Pre-operative CT angiography (CTA) is of paramount importance to identify the course of VA because the variation of VA is common in BI or AAD patients. Dissect along superolateral margin of C2 lamina to expose the C1/2 facet joint, and the C2 nerve root can be cauterized and disconnected for better exposure. C1/2 facet joint “space” was pinpointed under fluoroscopy or O-arm scan because it can be very difficult to discriminate the “space” when the joint is fused. Osteotome was used to release bony fusion of facet joint. A specifically designed rotating cutter<sup>8,9)</sup> was used to distract and prepare the facet joint space. Trials were used to determine inter-facet cage size. Proper cages with bone autograft were inserted bilaterally. Atlantoaxial fixation or occipitocervical fixation was conducted. Fluoroscopy or an O-arm scan was used to confirm reduction of the odontoid process. Posterior only bone graft was not needed. Wound was closed in multilayer fashion. Drainage was not mandatory. We provided an example video in the supplementary materials (Appendix A).

Three cases had been treated with the technique described above in the previous year.

Case 1 was a 45-year-old female patient who reported left lower limb weakness, unstable gait, and neck pain for 15 years. Eight years earlier, occipitocervical fusion had been performed. Her neck pain was relieved with no improvement of limb weakness. She experienced progressively aggravated weakness of the left lower limb and unstable gait for 3 years and was referred to us. On physical examination, her left lower limb muscle strength graded 4/5 with increased muscle tone and tendon reflexes, as well as positive Hoffmann and Babinski signs. There was no incontinency, dysphagia or hoarseness. Image work-up revealed AAD with insufficient reduction of the odontoid process after previous surgery and compression of the spinal cord (Fig. 1). Revision surgery was planned and implemented uneventfully (Appendix A). Post-operative images demonstrated complete reduction of the odontoid process and decompression of the spinal cord. Bony fusion of bilateral facet joints was seen at post-op. 3 months (Fig. 2). On 1-year follow-up, the patient reported apparent improvement on gait. Physical exam indicated muscle strength grade 4+/5, improved muscle tone, and tendon reflexes.

Case 2 was a 66-year-old female patient who presented with worsening nuchal pain and dysphagia for 3 months. Physical exam revealed decreased gag reflex and poor coordination. Imaging evaluation found BI and atlas occipitalization (Fig. 3). Medulla oblongata was compressed ventrally by the tip of dens protruding into foramen magnum and ex-



**Figure 2.** Post-revision surgery images.

Complete reduction of odontoid process (A) was achieved after bilateral distraction and cage implantation in facet joints (B and C, arrows indicate cages in joint space). Vertebral arteries were perfectly preserved (D). At post-op. 3 months, reduction of the dens was sustained (E) and bony fusion of facet joints was achieved (F, G). The spinal cord was decompressed ventrally (H).

ceeding the chamberlain line by 9 mm. Posterior facet joint distraction was mandatory, to reduce the odontoid process caudally. Surgery was completed with no complications, and the patient experienced continued relief of her symptoms during 3-month follow-up. The tip of dens was reduced to 3.5 mm above the chamberlain line and maintained 4 mm after occipitocervical bony fusion.

Case 3 (Fig. 4) received the same procedures and was followed up for more than 6 months with favorable outcomes.

## Discussion

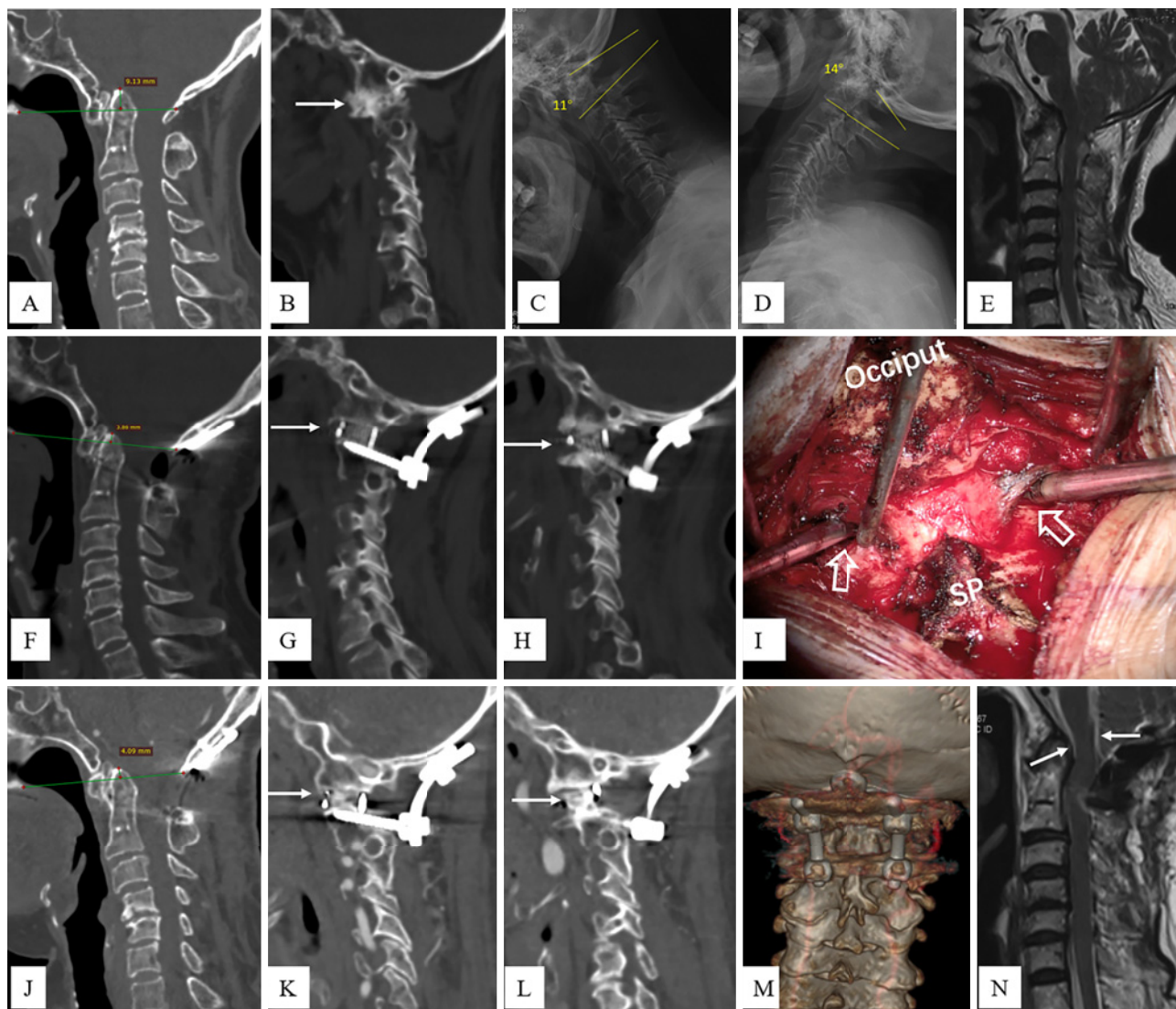
Management of AAD with or without BI is challenging because of its high morbidity and mortality rate. Anterior (transoral, transnasal, and submandibular), posterior, and combined anterior and posterior approaches are under practice nowadays<sup>10-13</sup>. For most spine or neural surgeons, posterior approach is the first choice for its accessibility and lower infection rate. Unfortunately, transoral decompression of the spinal cord or medulla is typically mandatory for bony irreducible AAD<sup>6,14</sup>. Our practice of the single-stage posterior approach to reduce bony fused AAD will change the traditional algorithm in which transoral odontoidectomy can increase risk of surgical complications such as surgical site infection.

Bony fusion of C1/2 can occur in traumatic, rheumatoid, and congenital AAD<sup>15</sup>. Malunion of the fractured odontoid

process with axial body located anterior to the spinal cord, which is better dealt with through the transoral approach. Otherwise, most bony fusions occur at the lateral facet joints. Direct access to the fusion site is easier from the posterior approach than from the anterior approach. In our cohort, two out of three cases are congenital AAD patients with spontaneous C1/2 facet joint fusion, and the other case is iatrogenic fusion induced by previous surgery.

Key points for the success of this surgery are summarized as follow. First, pre-operative CTA is imperative to identify the course of VA because variation of VA is common in these patients, and injury of VA can be lethal. Normally and ideally, VAs are lateral to C1/2 facet joints. If a VA impedes direct access to facet joint, mobilization of VA is needed and can be conducted with caution and proper techniques<sup>16</sup>. Second, joint release can introduce great instability to the craniovertebral junction (CVJ). Three-point head fixation is preferred. Temporary fixation with a screw and a rod may be needed on the contralateral side. Osteotomy should be conducted meticulously with a sharp osteotome to avoid oscillation that results in neural injury. Ultrasonic bone scalpel may increase safety of the procedure. Neurophysiological monitoring is of great help to recognize neural injury once it happens. Third, thorough lysis of joint bony fusion is of paramount importance. The disconnection should be along the original joint space, which is weaker connection compared to other parts of facets and which will leave cortical





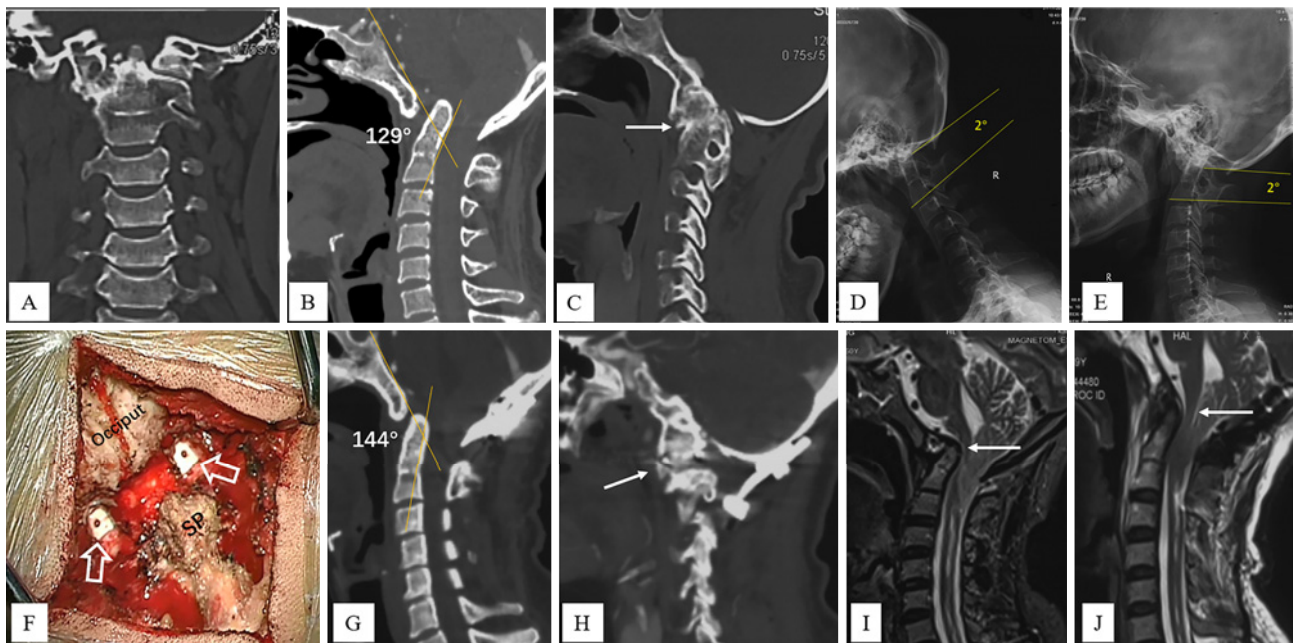
**Figure 3.** Case 2 with bony fusion of facet joint treated with joint distraction, cage implantation, and occipitocervical fusion. BI with left C1/2 facet joint fusion (A, B). Dynamic X-ray (C, D) showed 3-degree movement during flexion and extension. MRI showed compression of medulla by tip of dens (E). During operation, bilateral facet joint was successfully released and distracted with cages (I, arrows). Post-op. CT revealed reduction of dens caudally (F, 3.5 mm above chamberlain line) and good position of implants (G, H). Vertebral arteries were of no injury (M). Cerebrospinal fluid signal (N, arrow) around the medulla indicated decompression. Odontoid reduction was sustained (J) after bony fusion of facet joints (K and L, arrows) 3 months postoperatively. SP, spinous process of axis

bone on both sides. This facilitates distraction without facet collapse. High-speed drill is not used considering that it may decorticate articular surfaces bilaterally and cause facet collapse during distraction. To pinpoint the original joint space, fluoroscopy or an O-arm scan was used during the procedure. Fourth, joint distraction should be executed stepwisely. AAD in essence causes instability of CVJ; thus, soft tissues in this region, such as anterior longitudinal ligament and capsules of facet joints, become hypertrophic and contracted in compensation<sup>2)</sup>. Resistance when distracting intra-articular space can be expected. Stepwise and gradual distraction with a properly designed instrument can solve this problem. Usually, we can implant at least a 7-mm cage bilaterally. Fifth, autograft bone is preferred for cage filling. Bone marrow drawn from iliac can increase the bony fusion rate. All

three cases in this cohort achieved bony fusion at 3-month follow-up.

Limitations of this technique are as follows: First, if VA impedes facet joint access posteriorly, mobilization of VA can be highly risky for injury. Second, vibratory motion during joint release with osteotome can lead to catastrophic injury to spinal cord or medulla, especially in severe stenosis cases. Sharp osteotomes or an ultrasonic bone scalpel, temporary fixation, and neurophysiological monitoring can increase safety of the procedure. Third, only three cases have undergone this surgery until now. Large case series are warranted to further substantiate the safety and efficacy of this technique.

**Conflicts of Interest:** The authors declare that there are



**Figure 4.** Case 3 with BI, AAD, and Klippel-Feil syndrome.

(A–C) pre-operative CT showed BI, AAD, atlas occipitalization, fusion of C2 and C3 vertebral bodies, fusion of right C1/2 facet joint (arrow in panel C). Dynamic X-ray (D, E) showed no movement during flexion and extension. MRI (I) revealed Chiari malformation, syringomyelia and ventral impingement on brain stem by the tip of dens (arrow). Intra-operation cage implantation (F, H) distracted facet joints and reduced odontoid process (G). Clivo-axial angle improved to 144 degree (G) and ventral impingement on brain stem was relieved (J, arrow). *SP*, fused spinous processes of C2 and C3

no relevant conflicts of interest.

**Sources of Funding:** This work was supported by the Beijing Municipal Health Commission (Beijing Health Commission Independent Innovation Fund 2018-2-2014); the Beijing Municipal Excellent Talents Training Fund, 2018000020124G142; and the Science and Technology Innovation Capacity Building—advanced discipline construction project, 1192070315.

**Author Contributions:** Conception and revision of the manuscript: Zan Chen and Fengzeng Jian

Data analysis and drafting and revision of manuscript: Zhenlei Liu and Qiang Jian

Data acquisition and analysis and revision of the manuscript: Wanru Duan, Jian Guan, Can Zhang, and Boyan Zhang. Zhenlei Liu and Qiang Jian contributed equally to this work.

**Ethical Approval:** The study was approved by the institutional review board of Xuanwu Hospital, Capital Medical University (XW2020-102).

**Informed Consent:** Written informed consent was obtained from all participants in this study.

## References

- Menezes AH, Ahmed R, Dlouhy BJ. Youmans & Winn neurological surgery. 7th ed. Philadelphia: Elsevier; c2017. Winn HR, ed.
- Goel A. Principles of neurological surgery. Philadelphia: Elsevier; c2018. Ellenbogen RG, Sekhar LN, Kitchen N, eds. Craniovertebral junction, a reappraisal; p. 532-48.
- Greenberg AD. Atlanto-axial dislocations. *Brain*. 1968;91:655-84.
- Yin QS, Liu JF, Xia H, et al. [Clinical typing and surgical treatment and curative effect evaluating for atlantoaxial dislocation]. *Zhong-guo Ji Zhu Ji Sui Za Zhi*. 2003;13:38-41. Chinese.
- Tan MS, Zhang GB, Wang WJ, et al. [Surgical typing and treatment strategy for atlantoaxial dislocation]. *Zhong-guo Ji Zhu Ji Sui Za Zhi*. 2007;17:111-5. Chinese.
- Guan J, Chen Z, Wu H, et al. Effectiveness of posterior reduction and fixation in atlantoaxial dislocation: a retrospective cohort study of 135 patients with a treatment algorithm proposal. *Eur Spine J*. 2019;28(5):1053-63.
- Amelot A, Terrier LM, Lot G. Craniovertebral junction transoral approach: predictive factors of complications. *World Neurosurg*. 2018;110:568-74.
- Duan WR, Liu ZL, Guan J, et al. [Reduction of the atlantoaxial dislocation associated with basilar invagination through single-stage posterior approach: using Xuanwu occipital-cervical reduction surgical suite]. *Zhonghua Wai Ke Za Zhi*. 2019;57(10):63-8. Chinese.
- Duan W, Chou D, Jiang B, et al. Posterior revision surgery using an intraarticular distraction technique with cage grafting to treat atlantoaxial dislocation associated with basilar invagination. *J Neurosurg Spine*. 2019;31(4):1-9.
- Jian F-Z, Chen Z, Wrede KH, et al. Direct posterior reduction and fixation for the treatment of basilar invagination with atlantoaxial dislocation. *Neurosurgery*. 2010;66(4):678-87.
- Tong H, Yu X-G, Guo S. Distraction, compression, and extension

- reduction of basilar invagination and atlantoaxial dislocation. *Neurosurgery*. 2015;76(2):E239-40.
12. Yin QS, Li XS, Bai ZH, et al. An 11-year review of the TARP procedure in the treatment of atlantoaxial dislocation. *Spine*. 2016; 41(19):E1151-8.
  13. Hao D, He B, Zheng Y, et al. Single-stage anterior release and sequential posterior fusion for irreducible atlantoaxial dislocation. *Clin Spine Surg*. 2016;29(5):E240-5.
  14. Wang S, Wang C, Yan M, et al. Novel surgical classification and treatment strategy for atlantoaxial dislocations. *Spine*. 2013;38(21): E1348-56.
  15. Menezes AH. Craniovertebral junction database analysis: incidence, classification, presentation, and treatment algorithms. *Childs Nerv Syst*. 2008;24(10):1101-8.
  16. McDowell MM, Venteicher A, Goldschmidt E, et al. Vertebral artery mobilization for C1-2 reduction and fixation. *Neurosurg Focus: Video*. 2020;2(1):V8.

Spine Surgery and Related Research is an Open Access journal distributed under the Creative Commons Attribution-NonCommercial-NoDerivatives 4.0 International License. To view the details of this license, please visit (<https://creativecommons.org/licenses/by-nc-nd/4.0/>).