

Dural-Based Cavernoma of the Posterior Cranial Fossa Mimicking a Meningioma: A Case Report

Aurora S. Cruz^{1,2}, Shiveindra Jeyamohan³, Marc Moisi³, R. Shane Tubbs⁴, Jeni Page³, Parthasarathi Chamiraju⁵, Lara Tkachenko⁶, Steven Rostad⁷, David W. Newell⁸

1. Neurological Surgery, University of Louisville 2. Neurological Surgery, University of California, Irvine
3. Neurosurgery, Swedish Neuroscience Institute 4. Neurosurgery, Seattle Science Foundation 5.
Neurosurgery, Wayne State University School of Medicine 6. Neurological Surgery, Swedish Ne
7. Pathology, CellNetix 8. Swedish Neuroscience Institute

✉ **Corresponding author:** Marc Moisi, marc.moisi@swedish.org

Disclosures can be found in Additional Information at the end of the article

Abstract

Cavernous angiomas usually occur in the parenchyma of both the supra and infratentorial compartments. At times, they can both clinically and radiologically mimic other dural-based lesions. We present a case of a patient with chronic occipital headaches, initially thought to have a meningioma, but proven to be a cavernoma with histological analysis.

Categories: Neurosurgery

Keywords: cavernoma, meningioma, posterior fossa lesion, cavernous malformation

Introduction

Cavernous angiomas, also known as cavernous malformations or cavernomas, are benign vascular lesions usually found in the brain parenchyma. With no gender predisposition, they affect between 0.4% to 0.6% of the population [1]. Parenchymal cavernomas present differently both clinically and radiologically, and can mimic other dural-based lesions such as meningioma. This ambiguity may lead to unexpected gross or histologic results in the operating room. Our report details the case of a patient with a suspected meningioma who underwent resection and was unexpectedly found to have a dural-based cavernous angioma. Informed consent was obtained from the patient for this study.

Case Presentation

A 42-year-old man presented with longstanding occipital headaches since childhood, which progressively worsened over the preceding six months. He denied diplopia, ataxia, nausea, or weakness in his arms or legs. On physical exam he was neurologically intact. Evaluation included computed tomography (CT) scan as well as magnetic resonance imaging (MRI) of the brain. The MRI revealed a 2.8 cm, enhancing, extra-axial mass along the floor of the right posterior cranial fossa that is demonstrated in Figures 1-3.

Received 03/20/2016

Review began 03/22/2016

Review ended 03/29/2016

Published 04/06/2016

© Copyright 2016

Cruz et al. This is an open access article distributed under the terms of the Creative Commons Attribution License CC-BY 3.0., which permits unrestricted use, distribution, and reproduction in any medium, provided the original author and source are credited.

How to cite this article

Cruz A S, Jeyamohan S, Moisi M, et al. (April 06, 2016) Dural-Based Cavernoma of the Posterior Cranial Fossa Mimicking a Meningioma: A Case Report. Cureus 8(4): e560. DOI 10.7759/cureus.560

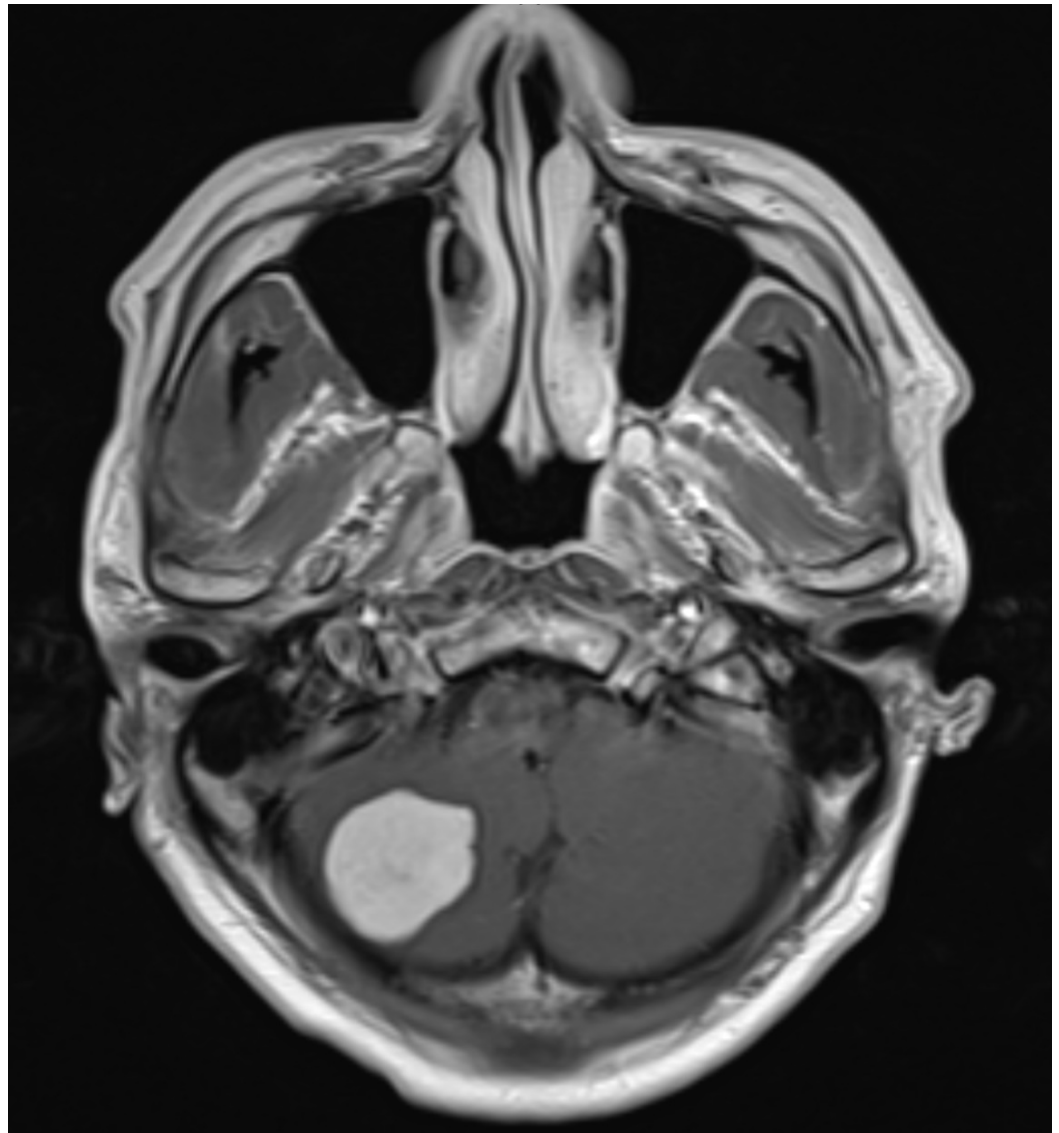


FIGURE 1: Axial View - MRI

Enhanced T1-weighted axial view illustrating the lesion in the right cerebellum.

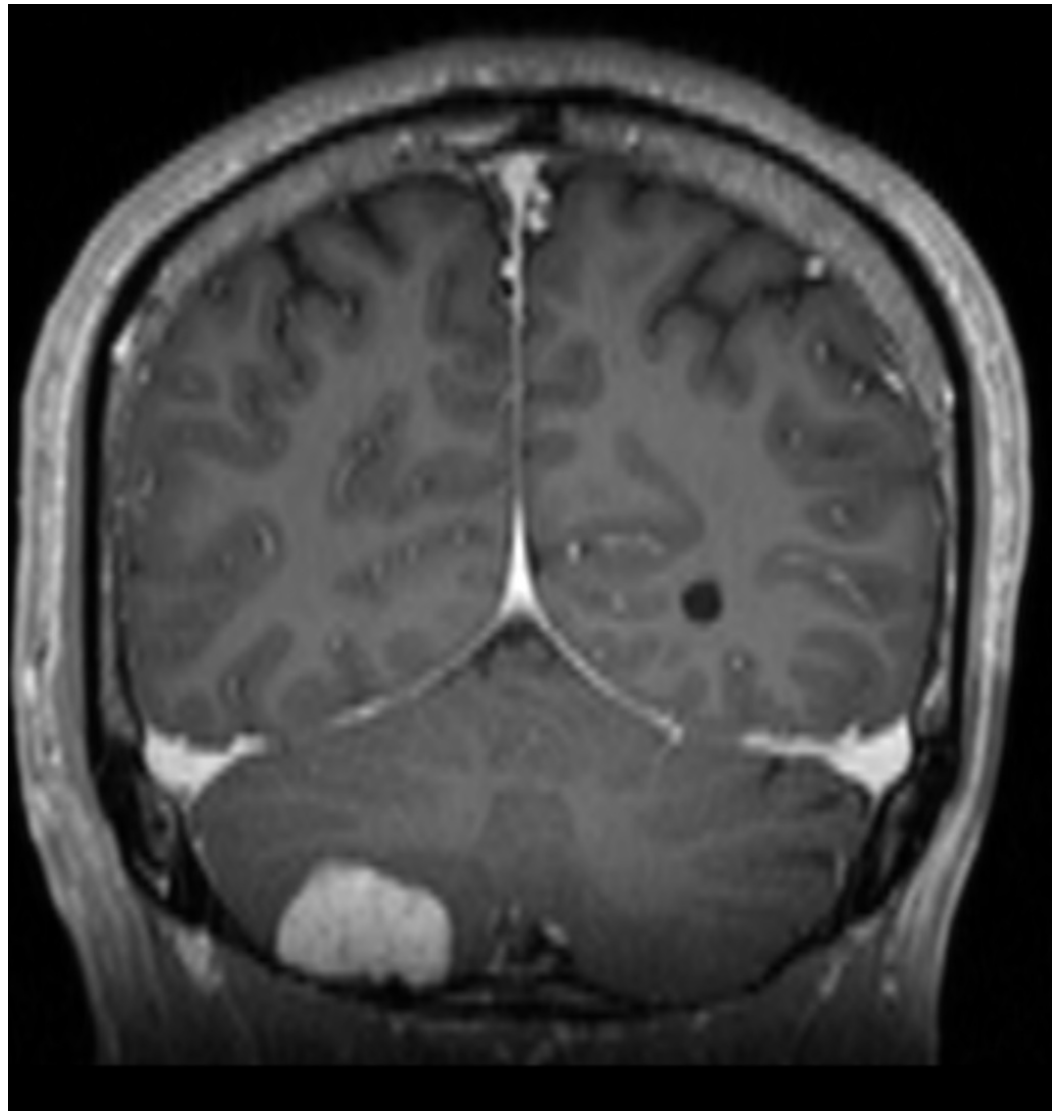


FIGURE 2: Coronal View - MRI

Enhanced T1-weighted coronal view illustrating the lesion.

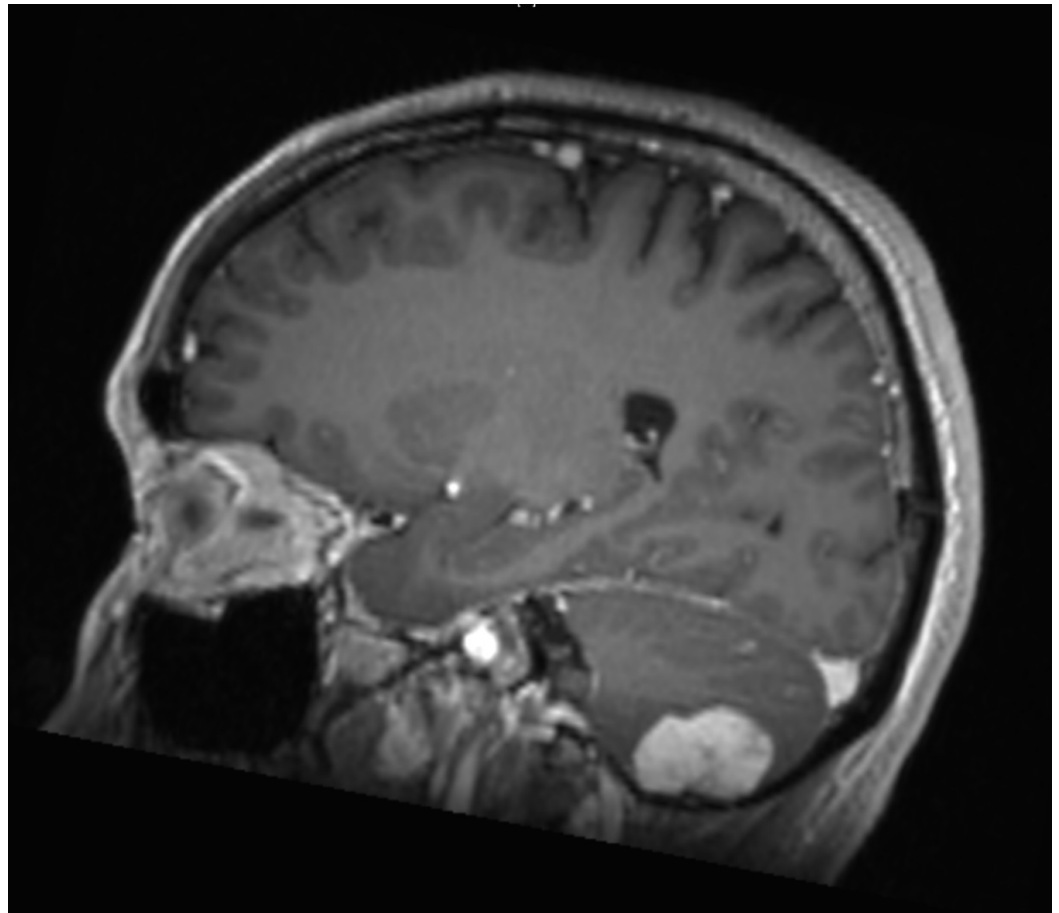


FIGURE 3: Sagittal View - MRI

Enhanced T1-weighted sagittal view illustrating the lesion.

It was recommended to the patient that he undergo elective craniotomy and resection.

Following a right suboccipital craniotomy, the lesion was noted to be encapsulated and crimson in color. There were no significant adhesions or evidence of invasion of the brain parenchyma and the lesion was easily removed en bloc and without complications.

Histological analysis of the tumor demonstrated back-to-back, thick-walled, endothelial-lined, venous channels consistent with a dural-based cavernous angioma shown in the hematoxylin and eosin stain in Figure 4. Thick walls composed of markedly hyperplastic smooth muscle cells consistent with arterialization were also found and shown in Figure 5. Focal whorl-like structures were seen; however, these lacked somatostatin receptor 2A and progesterone receptor staining typical of meningiomas and were instead positive for smooth muscle actin.

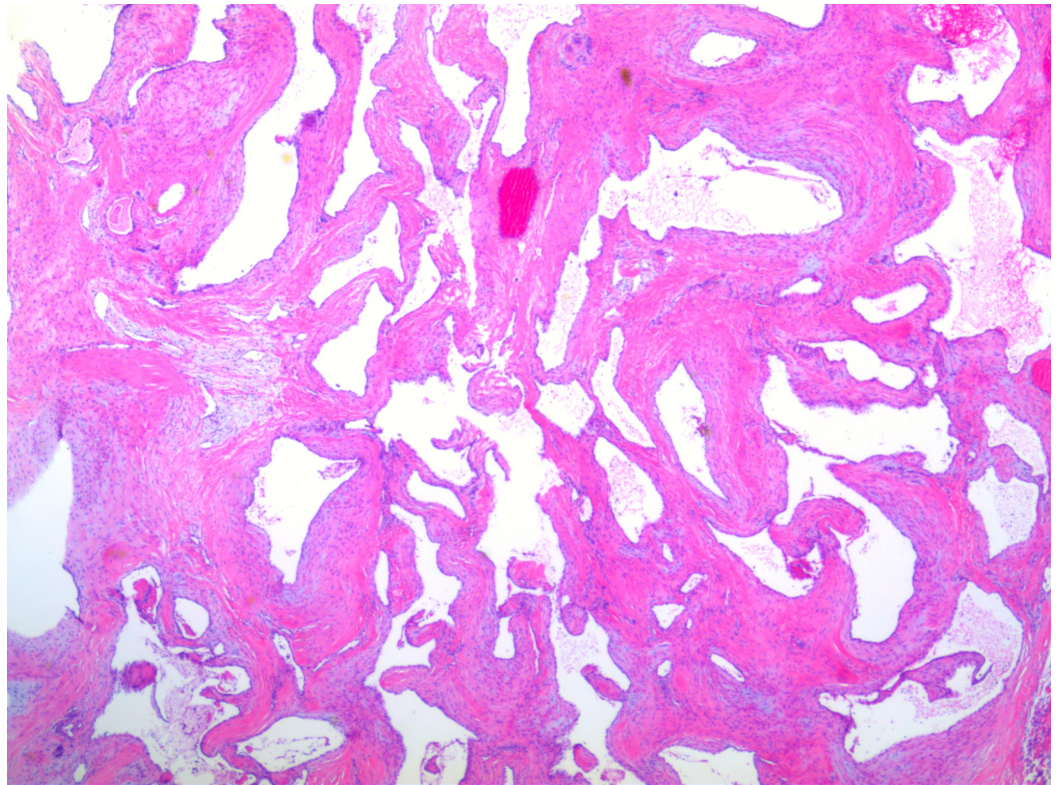


FIGURE 4: Hematoxylin and Eosin Stain

Slide demonstrating multiple back-to-back vascular channels. Each vessel is lined by endothelial cell layer and smooth muscle.

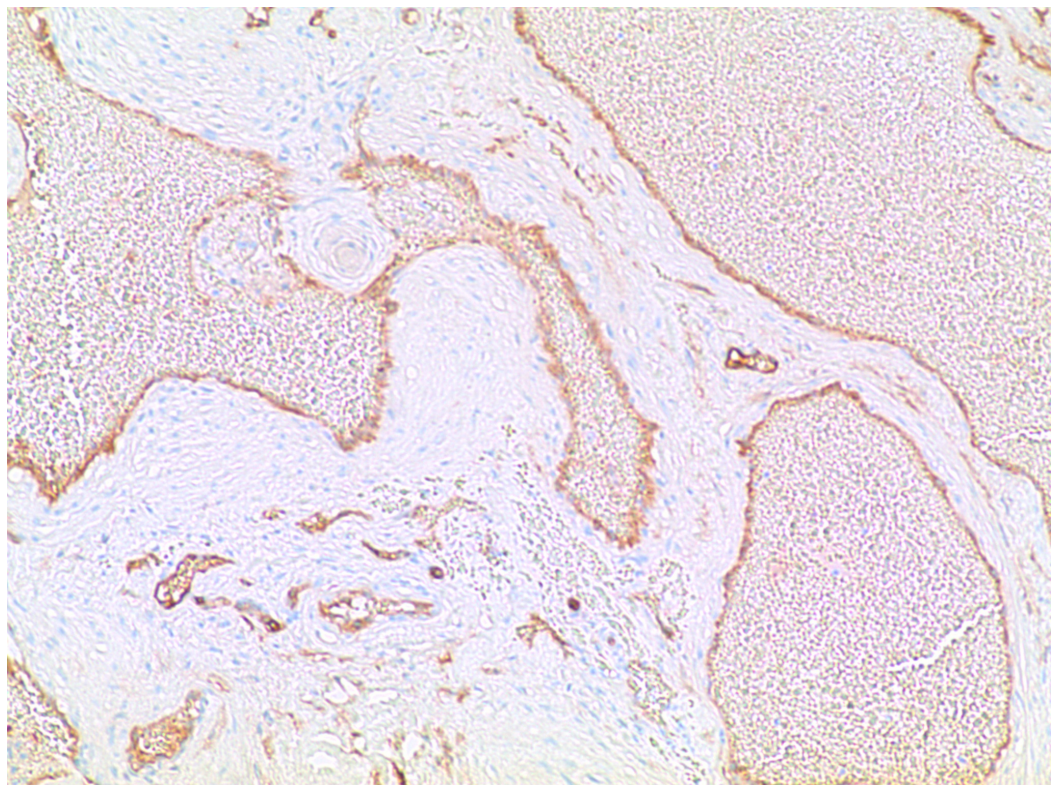


FIGURE 5: CD 31 Immunostain

CD 31 immunostain decorates the endothelial lining of vascular channels.

Postoperatively, the patient did very well and was discharged home on postoperative day two. At three months follow-up, he continues to do well and has complete resolution of his preoperative symptoms.

Discussion

Cavernous angiomas are benign vascular lesions comprised of enlarged, clustered, sinusoidal vessels without intervening parenchymal tissue and that are lined with epithelium [2]. Cavernous angiomas are most commonly found in the brain parenchyma but they may also be found in the spinal cord or in an extra-axial location [2-3]. The most common presenting symptoms are seizures (37%), hemorrhage (36%), headaches (23%), and focal neurological deficits (22%) [3]. The hemorrhage rate for cavernous angiomas varies among different authors but a recent review of the literature found that the annual risk of hemorrhage was between 2.4 to 3.1% per year, with a significantly higher risk of repeat bleeding for previously hemorrhaged lesions [3]. Histologically, cavernous angiomas appear as a cluster of irregular, hyalinized sinusoidal and vascular spaces resembling a mulberry [2]. Lack of neural tissue between these vascular spaces is a defining characteristic and histologically differentiates them from telangiectasias [2, 4]. Macrophages and hemosiderin staining from asymptomatic microhemorrhages are also a common finding. Full excision of surrounding epileptogenic hemosiderin staining has been found to decrease postoperatively [5-6].

Cavernous angiomas have a very distinctive appearance on MRI and on CT, often have punctate calcifications [7]. The characteristic “popcorn” lesion on both T1 and T2-weighted MRI appears as lobulated, vascular spaces with a mixed signal density representing breakdown products of numerous microhemorrhages [8-9]. A peripheral ring of hypointensity seen on MRI represents hemosiderin deposited in the surrounding parenchyma [4, 7, 10]. Susceptibility Weighted Imaging (SWI) MRI sequences are more sensitive and reliable than regular MRI sequences in detecting microhemorrhages and calcifications [7].

A few cases of dural-based cavernous malformations mimicking meningiomas or other neoplastic processes have been reported in the literature [11-13]. The differential diagnosis is wide, and can include hemangiopericytomas, hemangioblastomas, solitary fibrous tumors, dural-based metastases, and angiomatous meningiomas. Dural-based meningiomas have been reported in the cavernous sinus and middle cranial fossa, and tend to be more vascular with a more aggressive clinical course when compared to convexity or infratentorial cavernomas [14]. Unlike parenchymal lesions, dural-based cavernous angiomas most commonly present with headaches, rather than seizures or hemorrhage [14]. Dural-based cavernous angiomas are histologically nearly identical to their intraparenchymal counterparts although they tend to lack calcification [15]. Radiologic interpretation, however, proves very different from intraparenchymal cavernomas. As noted in the literature, these lesions tend to be iso- to hypointense on T1-weighted images, mixed to hyperintense on T2-weighted images, contrast enhancing, and hyperdense on CT [4, 10]. These characteristics are also typical for meningiomas, thereby clouding the differential diagnosis based on history and radiologic analysis. This distinction is further clouded by the presence of dural tails, hyperostotic reactions, and perilesional edema noted with some dural-based cavernous angiomas [2, 11, 13, 16]. Grossly, the lesion in our case was well encapsulated with the fibrous consistency of a meningioma. Until proven by pathology, we were convinced, based on imaging and

intraoperative visualization, that the tumor was a meningioma.

Previous cases have described lesions similar to ours with cavernous angiomas being mistaken for neoplastic lesions such as meningiomas and also neoplastic lesions mistaken preoperatively for cavernous angiomas [11-13, 16]. This lack of radiologic and clinical distinction can lead to unexpected findings in the operating room and may alter treatment plans, especially in the case of misidentified meningiomas. Given the lack of differentiable factors, it is important intraoperatively for the neurosurgeon to keep in mind the possibility of dural-based cavernous angiomas when formulating a differential diagnosis and choosing the appropriate excision technique and postoperative treatment plan. These dural-based cavernomas tend not to recur, and can safely be monitored without adjunct therapy [1, 3].

Conclusions

With the advancement of radiological techniques, the preoperative diagnosis of intracranial lesions continues to improve. However, as in the case reported herein, the definitive diagnosis continues to be the pathological specimen.

Additional Information

Disclosures

Human subjects: Consent was obtained by all participants in this study.

References

1. Gross BA, Du R: Cerebral cavernous malformations: natural history and clinical management. *Expert Rev Neurother*. 2015, 15:771-777. [10.1586/14737175.2015.1055323](https://doi.org/10.1586/14737175.2015.1055323)
2. Simard MJ, Garcia-Bengochea F, Ballinger WE, Jr., Mickle PJ, Quisling RG: Cavernous angioma: a review of 126 collected and 12 new clinical cases. *Neurosurgery*. 1986, 18:162-172.
3. Gross BA, Lin N, Du R, Day AL: The natural history of intracranial cavernous malformations. *Neurosurg Focus*. 2011, 30:E24.
4. Vogler R, Castillo M: Dural cavernous angioma: MR features. *AJNR Am J Neuroradiol*. 1995, 16:773-775.
5. Kondziolka D, Lunsford LD, Kestle JR: The natural history of cerebral cavernous malformations. *J Neurosurg*. 1995, 83:820-824.
6. Ruan D, Yu XB, Shrestha S, Wang L, Chen G: The role of hemosiderin excision in seizure outcome in cerebral cavernous malformation surgery: a systemic review and meta-analysis. *PLoS One*. 2015, 10:e0136619. [10.1371/journal.pone.0136619](https://doi.org/10.1371/journal.pone.0136619)
7. Zhu WZ, Qi JP, Zhan CJ, Shu HG, Zhang L, Wang CY, Xia LM, Hu JW, Feng DY: Magnetic resonance susceptibility weighted imaging in detecting intracranial calcification and hemorrhage. *Chin Med J (Engl)*. 2008, 121:2021-2025.
8. Hegde AN, Mohan S, Lim CC: CNS cavernous haemangioma: "popcorn" in the brain and spinal cord. *Clin Radiol*. 2012, 67:380-388. [10.1016/j.crad.2011.10.013](https://doi.org/10.1016/j.crad.2011.10.013)
9. Rivera PP, Willinsky RA, Porter PJ: Intracranial cavernous malformations. *Neuroimaging Clin N Am*. 2003, 13:27-40.
10. Rigamonte D, Drayer BP, Johnson PC, Hadley MN, Zabramski J, Spetzler RF: The MRI appearance of cavernous malformations (angiomas). *J Neurosurg*. 1987, 67:518-524. [10.3171/jns.1987.67.4.0518](https://doi.org/10.3171/jns.1987.67.4.0518)
11. Hwang SW, Pfannl RM, Wu JK: Convexity dural cavernous malformation with intradural and extradural extension mimicking a meningioma: a case report. *Acta Neurochir*. 2009, 151:79-83. [10.1007/s00701-008-0175-3](https://doi.org/10.1007/s00701-008-0175-3)
12. Jadik S, Stan AC, Dietrich U, Pietila TA, Elsharkawy AE: Intraparenchymal meningioma mimicking cavernous malformation: a case report and review of the literature. *J Med Case Rep*. 2014, 8:467. [10.1186/1752-1947-8-467](https://doi.org/10.1186/1752-1947-8-467)
13. Perry JR, Tucker WS, Chui M, Bilbao JM: Dural cavernous hemangioma: an under-recognized lesion mimicking meningioma. *Can J Neurol Sci*. 1993, 20:230-233.

14. Lewis AI, Tew JM, Payner TD, Yeh HS: Dural cavernous angiomas outside the middle cranial fossa: a report of two cases. *Neurosurgery*. 1994, 35:498-504.
15. Biondi A, Clemenceau S, Dormont D, Deladoeuille M, Ricciardi GK, Mokhtari K, Sichez JP, Marsault C: Intracranial extra-axial cavernous (HEM) angiomas: tumors or vascular malformations?. *J Neuroradiol*. 2002, 29:91-104.
16. Di Vitantonio H, De Paulis D, Ricci A, Marzi S, Dehcordi SR, Galzio RJ: Cavernous hemangioma of the dura mater mimicking meningioma. *Surg Neurol Int*. 2015, 6:S375-378.