

Letter to the Editor (Case report)

Rheumatology Advances in Practice 2019;0:1–2
doi: 10.1093/rap/rkz019

Digital ulcers in systemic sclerosis and insulin-dependent diabetes mellitus type 2

Key message

- We intend to raise awareness of the management of co-morbidities in SSc, given its complexity.

SIR, SSc is an autoimmune disease of the connective tissue characterized by small vessel vasculopathy, production of autoantibodies, dysfunction of fibroblasts and increased deposition of extracellular matrix [1, 2]. The clinical manifestations of SSc are variable, but most patients have RP, which can lead to complications of digital skin ulcers, skin thickening (usually in the fingers) and fibrosis of internal organs [1, 2]. The Rodnan score, based on the patient's skin thickness (using a scale from zero to three) for each of the anatomical areas of the body (20 areas, with a maximal score of 60), is the most frequently used disease activity score [2].

Skin ulcers affect $\leq 50\%$ of patients with SSc [3] and are usually located at the fingertips, finger creases and over the extensor surfaces of the joints [2, 3]. These are associated with high morbidity, pain and loss of functional capacity to perform activities of daily living [2, 3] and can lead to infection, gangrene, osteomyelitis and amputation (up to 11%) [3]. The SSc-related vasculopathy plays a pivotal role in the aetiology of skin ulcers, but other mechanisms, such as micro-trauma and sclerodactyly, also seem to be related [3]. Although the trigger factors are still unknown, it is acknowledged that the initial endothelial injury is followed by an increase in the levels of ET-1 receptor [3].

An association between diabetes mellitus and SSc is rarely reported. There are a few reported cases of patients with type 1 diabetes mellitus who have developed SSc, which gave rise to the hypothesis of common pathophysiological pathways in the autoimmune process, although these are still unclear [4]. The differential diagnosis with scleredema diabeticorum should always be present, but clinical features such as the anatomical skin thickening pattern and response to SSc therapy should help to determine the final diagnosis. It is also known that endothelial dysfunction contributes to the development of microvascular disease in diabetes mellitus [5], although skin ulcers located on the hands are less frequent than those on the legs (1 and 9.7%, respectively) [5]. In clinical practice, glycaemic monitoring of these patients may be complicated by the presence of digital skin ulcers attributable to SSc.

We report a case of a 46-year-old woman with hypertension stage 1 and type 2 diabetes mellitus for

≥ 6 years with micro- and macrovascular involvement (including eye and kidney diabetic disease) who maintained poor metabolic control. Fourteen years previously, she had been diagnosed with SSc using the ACR/EULAR classification criteria. She was receiving metformin 2500 mg, sitagliptin 100 mg, acarbose 90 mg and nifedipine 30 mg. The patient was a non-smoker, and there was no significant family history.

Upon physical examination, she had facial telangiectasia, RP, bilateral skin sclerosis on the distal half of the forearm and skin ulcers in the first, second and fifth fingers of both hands (Rodnan score 12), with no signs of acute ischaemia. Laboratory findings showed stage 2 chronic kidney disease (estimated glomerular filtration rate of 65 ml/min/1.73 m²), with microalbuminuria, glycosylated haemoglobin (HbA_{1c}) 8.4%, no autoantibody positivity, immunoglobulin levels within the normal range and no virological serology positivity. Nailfold capillaroscopy showed an active scleroderma pattern (Fig. 1). Pulmonary CT scan showed apical fibrosis, and cardiac ultrasound showed a dilated left atrium; upper endoscopy was normal.

Given that she did not achieve the target HbA_{1c} with three oral anti-diabetic agents, she was started on intermediate-acting insulin (10 I.U. in the morning and 6 I.U. in the evening), while maintaining metformin 2000 mg daily. Bosentan 125 mg daily, an endothelin antagonist, was added to nifedipine for treatment of SSc, to help improve the signs of skin sclerosis and tolerance to capillary glucose self-monitoring.

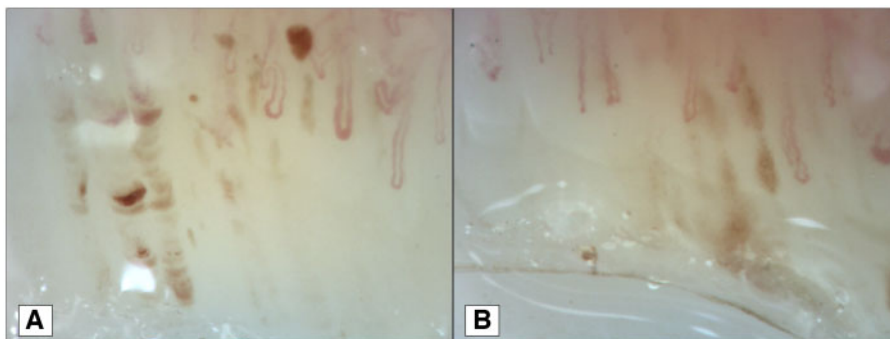
After 9 months of treatment with bosentan, the patient presented skin sclerosis only up to the metacarpophalangeal joints, with almost complete remission of the skin ulcers (Rodnan score 4) and good tolerance towards capillary blood glucose tests. The metabolic control also improved (HbA_{1c} 6.7%) after 9 months of treatment with insulin, with dose titration up to 36 I.U. in the morning and 28 I.U. in the evening.

In this case, it became imperative to improve glycaemic control with insulin and capillary glucose monitoring. However, the presence of skin ulcers would hinder treatment monitoring.

The skin ulcers improved greatly after the patient started therapy with an ET-1 receptor antagonist, and this improvement allowed capillary glucose monitoring. ET-1 receptor antagonists are effective for preventing the development of cutaneous ulcers [6] in SSc or after failure of treatment with dihydropyridine calcium channel blockers or prostanoids [6]. They also improve endothelial function in patients with diabetes mellitus and albuminuria [7].

Calcium channel blockers and prostanoids are the first-line agents for treatment of patients with SSc-related digital ulcers and RP. They are vasodilators with

Fig. 1 Videocapillaroscopy pictures



(A) Minor dystrophies, enlarged capillary, tortuosities and palisade haemorrhages. (B) Minor dystrophies, tortuosities and ramifications and megacapillary.

proven efficacy in reducing ischaemia [3, 6]. Calcium channel blockers, such as nifedipine, reduce the frequency and severity of exacerbations, whereas i.v. prostanooids (e.g. ilomedin) are used in more severe cases, such as cutaneous ulcers and acute ischaemia [3, 6]. The 2015 EULAR recommendations also include phosphodiesterase type 5 inhibitors for the treatment of SSc-related RP and DUs and consideration of the use of fluoxetine in treatment of SSc RP attacks, neither of which was necessary in this patient [8].

Funding: No specific funding was received from any funding bodies in the public, commercial or not-for-profit sectors to carry out the work described in this manuscript.

Disclosure statement: The authors have declared no conflicts of interest.

Bernardo Marques¹, Margarida Antunes^{2,3}, Sara Guerreiro Castro², Inês Rego de Figueiredo², Rita Vieira Alves² and Heidi Gruner^{2,3}

¹Endocrinology Department, Instituto Português de Oncologia de Coimbra FG, EPE, Coimbra, ²Internal Medicine Department 7.2, Hospital Curry Cabral – Centro Hospitalar Universitário Lisboa Central, EPE, Lisbon and, ³Clinical Medicine Department, NOVA Medical School, Lisbon, Portugal

Accepted 22 July 2019

Correspondence to: Bernardo Marques, Endocrinology Department, Instituto Português de Oncologia de Coimbra FG, EPE, Avenida Bissaya Barreto 98 Aptd. 2005, Coimbra, Portugal. E-mail: ber.marques89@gmail.com

References

- 1 Van den Hoogen F, Khanna D, Fransen J *et al.* 2013 classification criteria for systemic sclerosis: an American college of rheumatology/European league against rheumatism collaborative initiative. *Ann Rheum Dis* 2013;72:1747–55.
- 2 Czirájk L, Foeldvari I, Müller-Ladner U. Skin involvement in systemic sclerosis. *Rheumatology* 2008;47:v44–5.
- 3 Steen V, Denton P, Pope JE, Matucci-Cerenic M. Digital ulcers: overt vascular disease in systemic sclerosis. *Rheumatology* 2009;48(Suppl 3):iii19–24.
- 4 Koumakis E, Dieudé P, Avouac J, Kahan A, Allanore Y. Familial autoimmunity in systemic sclerosis — results of a French based case-control study. *J Rheumatol* 2012; 39:532–8.
- 5 Wang C, Lv L, Wen X *et al.* A clinical analysis of diabetic patients with hand ulcer in a diabetic foot centre. *Diabet Med* 2010;27:848–51.
- 6 Kowal-Bielecka O, Landewe R, Avouac J *et al.* EULAR recommendations for the treatment of systemic sclerosis: a report from the EULAR Scleroderma Trials and Research group (EUSTAR). *Ann Rheum Dis* 2009;68:620–8.
- 7 Rafnsson A, Böhm F, Settergren M *et al.* The endothelin receptor antagonist bosentan improves peripheral endothelial function in patients with type 2 diabetes mellitus and microalbuminuria: a randomised trial. *Diabetologia* 2012;55:600–7.
- 8 Kowal-Bielecka O, Fransen J, Avouac J *et al.* Update of EULAR recommendations for the treatment of systemic sclerosis. *Ann Rheum Dis* 2017;76:1327–39.