



# True Aneurysm of the Common Coronary Button in a Marfan Patient with an Anomalous Right Coronary Artery after a Bentall Procedure: A Case Report

Jeong Jun Jo, M.D.<sup>1</sup>, Yun Seok Kim, M.D., Ph.D.<sup>1</sup>, Gun-Jik Kim, M.D., Ph.D.<sup>2</sup>, Jae Hyun Kim, M.D., Ph.D.<sup>3</sup>

<sup>1</sup>Department of Thoracic and Cardiovascular Surgery, Keimyung University Dongsan Hospital, Keimyung University School of Medicine; <sup>2</sup>Department of Thoracic and Cardiovascular Surgery, Kyungpook National University Hospital, School of Medicine, Kyungpook National University, Daegu; <sup>3</sup>Department of Thoracic and Cardiovascular Surgery, Konyang University Hospital, Konyang University College of Medicine, Daejeon, Korea

## ARTICLE INFO

**Received** February 3, 2022

**Revised** March 14, 2022

**Accepted** April 10, 2022

## Corresponding author

Jae Hyun Kim

**Tel** 82-42-600-9424

**Fax** 82-42-600-9251

**E-mail** 200701@kyuh.ac.kr

## ORCID

<https://orcid.org/0000-0002-0940-5253>

True aneurysms of the coronary artery after aortic root replacement in Marfan syndrome patients are very rare. An anomalous origin of the right coronary artery (RCA) from the left sinus of Valsalva adds complexity during aortic root surgery. We present a case of a 37-year-old male patient with Marfan syndrome who had an RCA anomaly and a 4.5-cm true aneurysm of the common coronary button 14 years after a previous Bentall procedure. A redo Bentall operation and hemi-arch replacement were successfully performed. The anomalous origin of the RCA from the left sinus of Valsalva was safely divided and anastomosed as separate coronary buttons to the prosthetic composite valve graft. To prevent coronary button aneurysms after aortic root surgery in Marfan patients, the coronary buttons and the corresponding side holes on the prosthetic graft must be reduced to the maximum possible extent.

**Keywords:** Coronary artery pathology, Aneurysm, Aortic root, Reoperation, Marfan syndrome, Case report

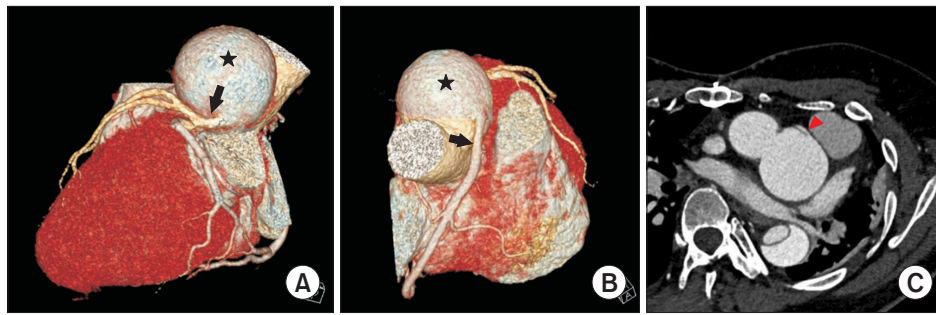
## Case report

A 37-year-old man with Marfan syndrome was referred to Keimyung University Dongsan Hospital after being diagnosed with acute type B aortic dissection. He had a surgical history of Bentall procedure and mitral valve repair, performed at another hospital, for acute type A aortic dissection and mitral regurgitation at the age of 23 years. Computed tomography angiography revealed a 4.5-cm aneurysm of the common coronary button (Fig. 1A) and a combined anomalous origin of the right coronary artery (RCA) from the left coronary sinus of Valsalva (Fig. 1B). Although an examination revealed RCA ostial stenosis due to the proximal intramural course (Fig. 1C), he had no angina. His cardiac enzyme levels and electrocardiograms were normal. The previous Bentall procedure records revealed that a single coronary button containing both the left and right coronary ostia was anastomosed to the prosthetic aortic graft because the right coronary ostium was

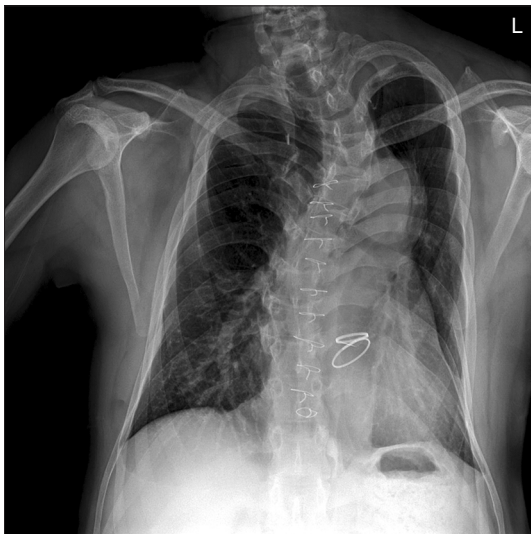
very close to the left coronary ostium. Considering the risk of aneurysm rupture and the patient's young age, we planned elective surgical treatment for coronary button aneurysm 3 months after the convalescence period of acute type B aortic dissection. A preoperative echocardiogram showed mild left ventricular dysfunction (ejection fraction, 48%); the mitral valve and prosthetic aortic valve were functioning normally.

Despite several obstacles, such as pectus excavatum and left deviation of the heart and great vessels (Fig. 2), redo median sternotomy and adhesiolysis could be performed safely. After direct ascending aortic cannulation and single 2-stage venous cannulation in the right atrium, cardiopulmonary bypass was performed. The ascending aorta was clamped during systemic cooling, and Custodiol cardioplegic solution (Koehler Chemi, Alsbach-Haenlien, Germany) was infused directly through the coronary ostium. Hypothermic circulatory arrest was induced at a nasopharyngeal temperature of 26°C, and unilateral antegrade cerebral

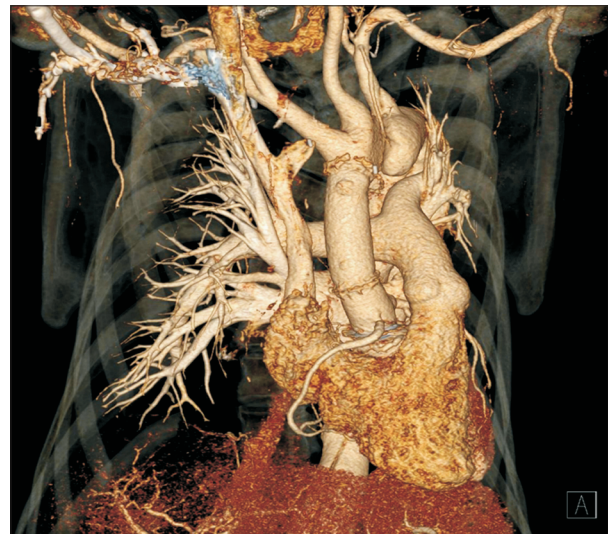



**Fig. 1.** (A) Aneurysm of the coronary button (asterisk) and the left coronary artery (arrow). (B) Computed tomography angiography (3-dimensional reconstructed view) revealed a large (4.5 cm) aneurysm of the coronary button (asterisk) and combined anomalous origin of the right coronary artery from the left coronary sinus of Valsalva (arrow). (C) Stenotic right coronary ostium due to the proximal intramural course (arrowhead).



**Fig. 2.** Chest X-ray revealed left deviation of the heart and great vessels combined with pectus excavatum and scoliosis.



**Fig. 3.** Postoperative computed tomography angiography shows 2 well-enhancing separate coronary arteries and the absence of the root aneurysm.

perfusion through the innominate artery was maintained during total circulatory arrest (TCA). Hemi-arch replacement was performed using a 24-mm Gelweave 1-branched graft (Vascutek, Inchinnan, UK). After completing distal aortic anastomosis, cardiopulmonary bypass was restarted using the branched graft as an arterial inflow site. The patient was subsequently rewarmed. After removing the old graft and mechanical valve, which contained a thrombus and subvalvular pannus, the coronary arteries and aneurysms were examined. Since the aneurysmal change was in the common coronary button, the anomalous RCA had sufficient length for a separate anastomosis, excluding the stenotic intramural ostium. A 23-mm composite valve conduit (St. Jude Medical Inc., St. Paul, MN, USA) was used for the modified Bentall procedure. The left coronary button was prepared and anastomosed to the prosthetic com-

posite graft. The anomalous RCA from the left sinus of Valsalva was safely divided and anastomosed to the prosthetic composite graft as a separate coronary button. To prevent kinking or tension, the RCA was mobilized sufficiently. Weaning from cardiopulmonary bypass was not challenging. The TCA, cardiac ischemic, and cardiopulmonary bypass times were 25, 181, and 220 minutes, respectively. The patient's postoperative recovery was uneventful. Before discharge, computed tomography angiography revealed good enhancement of 2 separate coronary arteries and the absence of the root aneurysm (Fig. 3).

The requirement for informed consent was waived, and this study was approved by the institutional Review Board of Keimyung University Dongsan Hospital (IRB approval no., 2022-01-054).

## Discussion

Due to the inherent weakness of connective tissue in Marfan syndrome, mild to moderate dilatation in one or both coronary origins is frequently detected during routine angiography or magnetic resonance imaging angiography [1, 2]. However, the clinical course is usually stable [3] and surgical reintervention for true aneurysms of the coronary button after aortic root replacement in patients with Marfan syndrome is rare. Including the first operative report of a true aneurysm of the coronary artery by Onoda et al. [4] in 2001, we found only several case reports related to this complication [5-7].

The definite cause of a true aneurysm at the coronary anastomosis site remains unknown. In addition to inherent connective tissue weakness, a large amount of remnant tissue while creating the coronary button might be responsible for this complication. In our case, due to the anomalous origin of the RCA from the left sinus of Valsalva, the coronary button was large enough during the initial Bentall operation to contain both coronary arteries. This extremely unusual case report adds to the evidence on the importance of the size of the coronary buttons during aortic root surgery in patients with Marfan syndrome to prevent a true aneurysm of the coronary button.

According to Kazui et al. [5], the indications for surgery for coronary aneurysms are angina pectoris, progressive enlargement of the aneurysm, and aneurysms in patients requiring distal aortic repair. In this case, we performed elective surgery for a 4.5-cm-diameter coronary aneurysm considering the risk of aneurysm rupture and the patient's young age in the absence of related symptoms. Although there are no size-specific surgical indications for coronary aneurysms, resection of coronary aneurysms larger than 4 cm is reasonable to prevent complications such as obstruction, arrhythmia, and rupture [8].

Various techniques for coronary reconstruction during reoperation, including the coronary button technique, the Cabrol and Piehler methods, coronary artery bypass grafting, and bovine patch closure with reattachment, have been used according to previous reports [4-7]. In our case, the large amount of redundant tissue from the true aneurysm made it possible to reattach the coronary arteries without tension. Considering that a true aneurysm of the coronary artery could have less adhesion around the coronary artery and redundant native tissues, the coronary

button technique could be considered as a useful option.

To prevent coronary button aneurysms after aortic root surgery in Marfan patients, the coronary buttons and corresponding side holes on the prosthetic graft must be reduced to the maximal possible extent. Close surveillance of the coronary arteries after aortic root surgery is required for patients with Marfan syndrome.

## Conflict of interest

No potential conflict of interest relevant to this article was reported.

## ORCID

Jeong Jun Jo: <https://orcid.org/0000-0001-5376-2533>

Yun Seok Kim: <https://orcid.org/0000-0002-2817-557X>

Gun-Jik Kim: <https://orcid.org/0000-0002-8051-2131>

Jae Hyun Kim: <https://orcid.org/0000-0002-0940-5253>

## References

1. Savunen T, Inberg M, Niinikoski J, Rantakokko V, Vanttinen E. *Composite graft in annulo-aortic ectasia: nineteen years' experience without graft inclusion*. Eur J Cardiothorac Surg 1996;10:428-32.
2. Meijboom LJ, Nollen GJ, Merchant N, et al. *Frequency of coronary ostial aneurysms after aortic root surgery in patients with the Marfan syndrome*. Am J Cardiol 2002;89:1135-8.
3. Haroun RR, Chu LC, Fishman EK. *Prevalence and natural history of coronary ostial aneurysms in Marfan patients*. J Comput Assist Tomogr 2019;43:115-8.
4. Onoda K, Tanaka K, Yuasa U, Shimono T, Shimpo H, Yada I. *Coronary artery aneurysm in a patient with Marfan syndrome*. Ann Thorac Surg 2001;72:1374-7.
5. Kazui T, Yamashita K, Terada H, et al. *Late reoperation for proximal aortic and arch complications after previous composite graft replacement in Marfan patients*. Ann Thorac Surg 2003;76:1203-8.
6. Okamoto K, Casselman FP, De Geest R, Vanermen H. *Giant left coronary ostial aneurysm after modified Bentall procedure in a Marfan patient*. Interact Cardiovasc Thorac Surg 2008;7:1164-6.
7. Bruschi G, Cannata A, Botta L, Martinelli L. *Giant true aneurysm of the right coronary artery button long after aortic root replacement*. Eur J Cardiothorac Surg 2013;43:e139-40.
8. Chalkley RA, Roberts WC, Patlolla S, et al. *Giant right coronary artery aneurysms*. Am J Cardiol 2020;125:1599-601.