



ORIGINAL ARTICLE

Repair of post-laryngectomy pharyngocutaneous fistulas using a pectoralis major flap[☆]



Anna Sumarroca¹ ^{a,*}, Elena Rodríguez-Bauzá^b, Joan Lop-Gros^a, Jacinto García^a, Montserrat López^a, Miquel Quer^a, Xavier León^a

^a *Universitat Autònoma de Barcelona, Hospital de la Santa Creu i Sant Pau, Otorhinolaryngology Department, Barcelona, Spain*

^b *Universitat Autònoma de Barcelona, Hospital de la Santa Creu i Sant Pau, Plastic Surgery Department, Barcelona, Spain*

Received 8 August 2017; accepted 1 March 2018

Available online 5 April 2018

KEYWORDS

Total laryngectomy;
Pharyngocutaneous fistula;
Pectoralis major flap;
Bypass salivary tube;
Pharynx closure

Abstract

Introduction: The pectoralis major flap is a reconstructive option to consider in the treatment of pharyngocutaneous fistula after a total laryngectomy. There are not large studies assessing variables related to pharyngocutaneous fistula recurrence after removal of the larynx. Our objectives were to review the results obtained with this type of treatment when pharyngocutaneous fistula appears in laryngectomized patients, and to evaluate variables related to the results.

Methods: We retrospectively reviewed our results using either a myocutaneous or fasciomuscular pectoralis major flap to repair pharyngocutaneous fistula in 50 patients.

Results: There were no cases of flap necrosis. Oral intake after fistula repair with a pectoralis major flap was restored in 94% of cases. Fistula recurrence occurred in 22 cases (44%), and it was associated with a lengthening of the hospital stay. Performing the flap as an emergency procedure was associated with a significantly higher risk of fistula recurrence. Hospital stay was significantly shorter when a salivary tube was placed.

Conclusions: The pectoralis major flap is a useful approach to repair pharyngocutaneous fistula. Placing salivary tubes during fistula repair significantly reduces hospital stay and complication severity in case of pharyngocutaneous fistula recurrence.

© 2018 Associação Brasileira de Otorrinolaringologia e Cirurgia Cérvico-Facial. Published by Elsevier Editora Ltda. This is an open access article under the CC BY license (<http://creativecommons.org/licenses/by/4.0/>).

^{☆☆} Please cite this article as: Sumarroca A, Rodríguez-Bauzá E, Lop-Gros J, García J, López M, Quer M, et al. Repair of post-laryngectomy pharyngocutaneous fistulas using a pectoralis major flap. Braz J Otorhinolaryngol. 2019;85:351–6.

* Corresponding author.

E-mail: annasumarroca@gmail.com (A. Sumarroca).

Peer Review under the responsibility of Associação Brasileira de Otorrinolaringologia e Cirurgia Cérvico-Facial.

PALAVRAS-CHAVE

Laringectomia total;
Fístula
faringocutânea;
Retalho do músculo
peitoral maior;
Tubo de derivação
salivar;
Fechamento da
faringe

Reparo de fístulas faringocutâneas pós-laringectomia utilizando retalho do músculo peitoral maior**Resumo**

Introdução: O retalho do músculo peitoral maior é uma opção a ser considerada no fechamento de fístula faringocutânea pós-laringectomia total. Não há grandes estudos que avaliem as variáveis relacionadas à recorrência da fístula faringocutânea após esse procedimento. Nossos objetivos foram avaliar os resultados obtidos com esse tipo de tratamento em pacientes laringectomizados com fístula faringocutânea e as variáveis relacionadas aos resultados.

Método: Revisamos retrospectivamente os nossos resultados em 50 pacientes nos quais um retalho mio-cutâneo ou fasciomuscular do músculo peitoral maior foram utilizados para reparar a fístula faringocutânea.

Resultados: Não houve casos de necrose de retalho. Após o reparo da fístula com um retalho do músculo peitoral maior, a ingestão oral foi restaurada em 94% dos casos. Houve recorrência da fístula em 22 casos (44%), a qual foi associada à duração da hospitalização. O uso do retalho como procedimento de emergência foi associado a um risco significativamente maior de recorrência da fístula. A permanência hospitalar foi significativamente menor quando utilizado um tubo de derivação salivar.

Conclusões: O uso do retalho do músculo peitoral maior é uma abordagem útil para reparar a fístula faringocutânea. A colocação de tubos de derivação salivar durante o reparo da fístula reduz significativamente o tempo de hospitalização e a gravidade das complicações em caso de recorrência da fístula faringocutânea.

© 2018 Associação Brasileira de Otorrinolaringologia e Cirurgia Cérvico-Facial. Publicado por Elsevier Editora Ltda. Este é um artigo Open Access sob uma licença CC BY (<http://creativecommons.org/licenses/by/4.0/>).

Introduction

The appearance of a pharyngocutaneous fistula (PCF) remains one of the most common and difficult postoperative complications in patients undergoing total laryngectomy. This complication increases morbidity, length of hospitalization, and costs associated with treatment. The reported incidence of pharyngocutaneous fistulas after total laryngectomy is highly variable, ranging between 4% and 65%.¹

Several studies have evaluated the risk factors associated with the appearance of PCF after total laryngectomy: previous treatment with radiotherapy²⁻⁸ or chemoradiotherapy⁹; a shorter interval between the end of radiotherapy and laryngectomy^{7,8,10}; hemoglobin levels below 125 g/L preoperative⁴ as well as postoperative^{5,6,11}; comorbidities such as diabetes, liver disease, or hypothyroidism^{2-4,12}; and surgical aspects such as neck dissection,^{2,7,8} prior tracheotomy,⁶ resection of the pharynx,^{8,13} or the use of nonirradiated tissue to reinforce the pharyngeal suture.¹⁴ The results of a meta-analysis of 26 studies conducted by Paydafar et al.¹⁵ showed that risk factors significantly associated with the appearance of PCF were hemoglobin level less than 125 g/L, prior tracheostomy, preoperative radiotherapy, and concurrent neck dissection. The results also showed that PCF was more severe in patients with previous radiotherapy. In a case-control study conducted in laryngectomized patients by Venegas et al.,¹⁶ no significant differences were found in the percentage of PCF between non-irradiated and irradiated patients (12% vs. 18%, $p > 0.05$). However, patients with previous radiotherapy and PCF required more surgical

repair procedures and the length of hospitalization was increased.

Treatment for PCF is usually conservative. It consists of medical treatment with antibiotics, enteral nutrition with a nasogastric tube, and daily local wound care including removal of all necrotic tissue, cleaning with an antiseptic solution, and placement of a compressive dressing. Between 62%³ and 86%¹⁷ of PCF spontaneously close with medical treatment, particularly those in non-irradiated patients with small fistulas. Surgical closure of the fistula is indicated when conservative treatment fails, but there is no consensus about waiting time. Several authors consider there is no reason to wait any longer if PCF closure is not obtained in one month with medical management; surgical closure should be considered in these patients.^{2,11,18}

Many surgical techniques are used in the treatment of the PCF: direct closure^{2,11}; endoscopic repair with a platysmal flap¹⁹; axial fasciocutaneous flaps such as the deltopectoral flap^{18,20} or the internal mammary artery perforator flap²¹; musculocutaneous flaps such as the sternocleidomastoid,²² pectoralis major flap,^{18,20,23-25} trapezius²⁶ or latissimus dorsi²² flaps; and free flaps such as the jejunum,^{23,27} radial forearm^{5,12,25,28} and anterolateral thigh flaps.²⁹

In our center, the method of choice to treat a PCF that does not respond adequately to conservative treatment is fistula closure using a pectoralis major flap (PMF). Since 1994 we have systematically added placement of a bypass salivary tube (Montgomery[®] Salivary Bypass Tube; Boston Medical Products) in combination with the PMF.

The aims of this study were to review the results obtained with this type of treatment when PCF appears in

Table 1 Characteristics of patients included in the study (n = 50).

Age, years (average, standard deviation)	61.4 (9.1)
Sex	
Male	47 (94%)
Female	3 (6%)
Location	
Larynx	35 (70%)
Hypopharynx	15 (30%)
Prior radiotherapy	
No	11 (22%)
Yes	39 (78%)
Previous flap	
No	44 (88%)
Yes	6 (12%)
Preoperative Hb g/L (average, standard deviation)	109.9 (18.7)
Fistula period in days (average, range)	32 (5–300)

laryngectomized patients and to evaluate variables related to the results.

Methods

Data were obtained retrospectively from a registry that prospectively collects information from reconstructive procedures performed in our center since 1990. From 1990 to 2014, a total of 50 patients were treated with a PMF to close post-laryngectomy PCF. Table 1 shows the characteristics of patients included in this study.

In one case, the fistula appeared due to necrosis of a radial free skin flap used in reconstruction of the hypopharynx. In two patients a PMF was used after the previous failure of a repair attempt with an internal mammary artery perforator flap. In six patients treated with a total laryngectomy and a partial or total pharyngectomy a PMF was used in the reconstruction of the hypopharynx at the primary surgery.

The decision for elective surgical closure of PCF with a PMF was carried out after a failed conservative management of at least four weeks duration and was based on clinical parameters such fistula size and cervical soft tissue status.

Treatment involved the use of a myocutaneous or fasciomuscular flaps. The criteria to use a myocutaneous flap or a fasciomuscular flap depended basically on the size of the defect to be reconstructed and the morphology of the patient. We chose a muscle flap without skin paddle when fistula repair required reconstruction of less than a third of the hypopharynx, or when the thickness of the skin paddle was considered excessive. In these cases, we directly sutured the superficial fascia of the pectoralis muscle to the defect margins. In the case of large pharyngocutaneous fistulas requiring reconstruction of more than a third of the hypopharynx, we used myocutaneous flaps, suturing the skin paddle to the margins of the pharyngeal defect. Since 1994, we routinely place a bypass salivary tube simultaneously with pharyngocutaneous fistula repair.

Full oral intake restoration after PCF repair using the PMF was considered as a successful outcome, as long as no new further PCF repair procedures were needed. Analysis of the results included the percentage of complications at the cervical surgical wound site and thoracic donor site, and the period of hospitalization after performing the pectoralis flap repair.

Qualitative variables were compared using the Chi-square test or Fisher's exact test. The relationship between qualitative and continuous variables was performed using the nonparametric Mann-Whitney test. A logistic regression was used in the multivariate analysis.

This study was approved by the institutional oncological scientific committee of our center, and conducted in accordance with the Declaration of Helsinki.

Results

A pectoralis myocutaneous flap was performed in 12 cases (24.0%), and a fasciomuscular flap without a skin paddle in 38 cases (76.0%). No signs of flap necrosis were observed in any case.

The flap was performed within 14 days post-laryngectomy in 13 patients with a pharyngocutaneous fistula and cervical bleeding. In these cases, the flap was used in an emergency context to protect the vascular axis and to reconstruct the pharyngeal defect, performing the suture on a contaminated area. In the remaining patients, the fistula was repaired electively, and no evidence of cervical wound infection was noted during surgery.

One patient with a PCF had a hemorrhage of the internal jugular vein on the 12th postoperative day. Following vein ligation we repaired the fistula using a myocutaneous pectoralis flap. The patient died eight days later due to septic shock associated with complications of the cervical wound; the fistula persisted at the time of death. Two patients required a second surgery to repair the recurrence of PCF after treatment with the PMF. In the two cases, surgical treatment consisted of the use of a second PMF to repair the defect.

Restoration of full oral intake is considered the goal of treatment. Post-laryngectomy PCF surgical repair using CPM was successful in 94% of patients (47/50). PCF recurrence occurred in 22 of the 50 procedures (44%). Table 2 shows the percentage of patients with fistula recurrence in relation to patient age, hemoglobin levels, the number of days before repair, the location of the primary tumor, previous radiotherapy, the use of PMF at the primary surgery, the type of flap, the use of a salivary bypass tube, and the context of the repair surgery (elective or emergency with a cervical bleeding). There were no significant differences in fistula recurrence after completion of the pectoralis flap for any of the analyzed variables. We found a correlation for fistula recurrence when surgery was carried out as an emergency procedure. Two of the patients operated in an emergency situation needed a second reconstructive procedure with a contralateral PMF in order to a close recurrent PCF.

We performed a multivariate study considering fistula recurrence as the dependent variable and including those variables with a $p < 0.20$ in the univariate analysis as the

Table 2 Fistula recurrence after repair with a pectoral flap in relation to clinical and operative variables.

	Fistula recurrence		p
	No	Yes	
Age in years (median)	60.8	62.7	0.453
Period of previous fistula days (median)	32.0	33.0	0.692
Preoperative Hb in g/L (median)	114.1	106.0	0.140
Location			
Larynx	21 (57%)	16 (43%)	0.757
Hypopharynx	8 (53%)	7 (47%)	
Radiotherapy			
No	6 (55%)	5 (45%)	0.927
Yes	23 (56%)	18 (44%)	
Previous flap			
No	26 (57%)	20 (43%)	0.762
Yes	3 (50%)	3 (50%)	
Flap			
Myocutaneous	8 (67%)	4 (33%)	0.386
Fasciocutaneous	21 (53%)	19 (47%)	
Salivary			
No	8 (42%)	11 (58%)	0.132
Yes	21 (64%)	12 (36%)	
Emergency			
No	25 (64%)	14 (37%)	0.054
Yes	4 (31%)	9 (69%)	

Table 3 Results of multivariate analysis considering fistula recurrence as a dependent variable.

	HR	95% CI	p
Salivary			
Yes	1		
No	3.42	0.94–12.37	0.060
Emergency			
No	1		
Yes	4.68	1.05–20.83	0.043
Preoperative Hb	0.984	0.951–1.01	0.356

independent variables (Table 3). The only variable associated with a significant risk of fistula recurrence was undergoing flap surgery as an emergency procedure. In this situation, the risk of fistula recurrence was 4.68 times higher (95% CI 1.05–20.83, $p=0.043$). Patients in whom salivary tube bypass was not used had an increased risk of recurrence, but in this case the hazard ratio did not reach statistical significance (HR = 3.42, 95% CI 0.94–12.37, $p=0.060$).

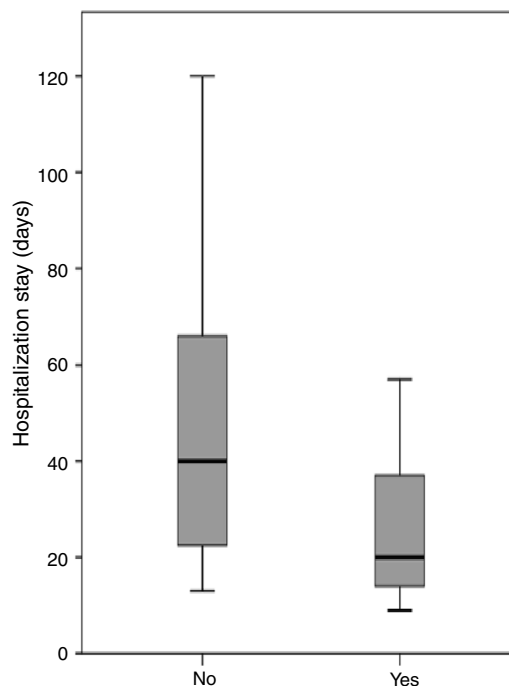


Figure 1 Length of hospitalization stay in days in relation to the use of salivary bypass tube.

Three patients were discharged from hospital with a nasogastric tube due to the persistence of a small fistula that was resolved on an outpatient basis. With the exception of the patient who died during the postoperative period, all patients achieved successful oral intake. The median length of hospitalization after completion of the pectoralis flap was 24.5 days (range 9–120 days). Length of hospitalization after completion of a pectoralis flap differed significantly depending on fistula recurrence ($p=0.001$). The median hospitalization for patients who were treated with the pectoralis flap was 16.0 days (range 9–31 days) for those who achieved primary closure of the fistula, and 45 days (range 13–120 days) for patients with fistula recurrence. Periods of hospitalization after completion of the PMF were analyzed considering the location of the primary tumor, previous radiotherapy, type of flap, the use of a shunt salivary tube, and whether the flap was performed as elective or emergency surgery. Placement of a salivary bypass tube was the only variable significantly related to the length of stay (Fig. 1). The median hospitalization was 20.5 days (range 9–90 days) for patients in whom a salivary tube was placed, and 40.0 days (range 13–120) for patients in whom no tube was placed ($p=0.013$). Considering only patients with fistula recurrence ($n=22$), the median length of hospitalization was 41.5 days (range 13–90 days) for patients in whom a salivary tube was placed ($n=12$) and 66 days (range 40–120 days) for patients in whom no tube was placed ($n=10$) ($p=0.036$).

Five patients (9.6%) had a chest wound infection in the donor area and 2 (3.8%) had a hematoma. All 7 cases of chest level complication resolved with local wound care.

Discussion

Several studies have shown the efficiency of the PMF in closing the pharynx during a laryngectomy and hence reducing the frequency of postoperative PCF.^{30,31} However, to our knowledge no studies have been performed in a large series of patients to examine the usefulness of PMF to treat postoperative PCFs or to determine the variables related to the appearance of fistula recurrence.

According to our results, fasciomuscular and myocutaneous pectoralis flaps for the closure of post-laryngectomy PCF are safe and effective. With the exception of the patient who died due to complicated postoperative wound infection and secondary septic shock, oral intake was restored in all patients, although a second procedure using contralateral PMF was needed in two of them. Despite the usefulness and efficacy of this technique, 44% of patients developed fistula recurrence. Performing this surgery in an emergency situation due to postoperative local bleeding was the variable most strongly associated with the recurrence of PCF, with a 67% rate of fistula recurrence. In contrast, when surgery was performed as elective non-emergency surgery, the frequency of fistula recurrence was 37%, a rate similar to that reported by other authors. McLean et al.²³ analyzed the results obtained in 17 cases of post-laryngectomy PCF repaired with PMF in a group of patients in which 82.4% had received pre-operative irradiation. These patients had 58.8% of complications associated with PMF reconstruction, with a 35.3% rate of fistula recurrence. In Magdy et al.²⁵ study, the rate of fistula recurrence in 10 patients using PMF to repair post-laryngectomy PCF was 30%.

The results of a multivariate analysis showed that the use of the PMF in an emergency situation increased the risk of fistula recurrence almost nine-fold. In our opinion, the increased risk of fistula recurrence when PMF reconstruction is carried out in an emergency background is justified by the precarious systemic and local context in which surgery is performed. When cervical bleeding is associated with pharynx and cervical dehiscence the pectoralis flap is sutured on infected tissue. Cervical bleeding means, furthermore, that we are working on hemodynamically unstable patients. Given these results, unless a flap is required to protect the vascular axis, in the emergency situation we now prefer to perform a pharyngostoma, suturing the margins of the pharyngeal dehiscence to cervical skin, and to defer the reconstruction of the PCF with a PMF until local and systemic conditions improve.

In an attempt to reduce the incidence of fistula recurrence, since 1994 we have been systematically placing a salivary bypass tube during PCF closure. Our results showed a trend to reduce the percentage of fistula recurrence (56% in cases without a bypass tube versus 37% in cases with a bypass tube), the differences not reaching statistical significance. However, we observed a significant decrease in the length of hospitalization in patients with a salivary bypass tube, even in patients with fistula recurrence.

The main advantages in using the pectoralis flap in the repair of PCF are that it is a technically simple procedure, and that it provides a well-vascularized tissue with a pedicle that easily reaches the cervical region. Disadvantages of this flap are the morbidity caused at the donor site, and

excessive bulk depending on the phenotype of the patient, especially in cases where a myocutaneous flap is used. It should be kept in mind, however, that as all our patients were operated by the same surgical team, the learning curve using the PMF in the closure of PCF could have played a role in the better results achieved over time.

An alternative to pectoralis flaps are microanastomosed free flaps.²⁷ The advantages of this type of repair are the availability of different donor sites and their adaptability to the specific requirements of each type of defect. Free flaps, however, also have disadvantages. These include increased complexity of the microsurgical technique and problems arising from a lack of viable vascular neck structures in patients with a history of neck dissection, radiotherapy, or cervical infection. In the series of Bohannon and cols²⁷ in which free flaps were used to repair 20 cases of PCF, the authors chose to use recipient vessels from areas other than the neck in 45.5% of cases, anastomosing the free flap to the internal mammary vessels.

Conclusions

The myocutaneous or fasciomuscular PMF is a useful reconstructive tool for the repair of PCFs after laryngectomy. Placing salivary by-pass tubes during fistula repair significantly reduces hospital stay and the severity of complications of PCF recurrence.

Conflicts of interest

The authors declare no conflicts of interest.

References

1. Sarra LD, Rodríguez JC, García Valea M, Bitar J, Da Silva A. Fistula following total laryngectomy. Retrospective study and bibliographical review. *Acta Otorrinolaringol Esp.* 2009;60:186–9.
2. Galli J, De Corso E, Volante M, Almadori G, Paludetti G. Postlaryngectomy pharyngocutaneous fistula: incidence, predisposing factors, and therapy. *Otolaryngol Head Neck Surg.* 2005;133:689–94.
3. White HN, Golden B, Sweeny L, Carroll WR, Magnuson JS, Rosenthal EL. Assessment and incidence of salivary leak following laryngectomy. *Laryngoscope.* 2012;122:1796–9.
4. Erdag MA, Arslanoglu S, Onal K, Songu M, Tuylu AO. Pharyngocutaneous fistula following total laryngectomy: multivariate analysis of risk factors. *Eur Arch Otorhinolaryngol.* 2013;270:173–9.
5. Boscolo-Rizzo P, De Cillis G, Marchiori C, Carpenè S, Da Mosto MC. Multivariate analysis of risk factors for pharyngocutaneous fistula after total laryngectomy. *Eur Arch Otorhinolaryngol.* 2008;265:929–36.
6. Benson EM, Hirata RM, Thompson CB, Ha PK, Fakhry C, Saunders JR, et al. Pharyngocutaneous fistula after total laryngectomy: a single-institution experience, 2001–2012. *Am J Otolaryngol.* 2015;36:24–31.
7. Basheeth N, O'Leary G, Sheahan P. Pharyngocutaneous fistula after salvage laryngectomy: impact of interval between radiotherapy and surgery, and performance of bilateral neck dissection. *Head Neck.* 2014;36:580–4.

8. Virtaniemi JA, Kumpulainen EJ, Hirvikoski PP, Johansson RT, Kosma VM. The incidence and etiology of postlaryngectomy pharyngocutaneous fistulae. *Head Neck*. 2001;23:29–33.
9. Furuta Y, Homma A, Oridate N, Suzuki F, Hatakeyama H, Suzuki K, et al. Surgical complications of salvage total laryngectomy following concurrent chemoradiotherapy. *Int J Clin Oncol*. 2008;13:521–7.
10. Nixon IJ, Pezier TF, Cobb R, Urbano TG, Oakley R, Jeannon JP, et al. Time interval between primary radiotherapy and salvage laryngectomy: a predictor of pharyngocutaneous fistula formation. *Eur Arch Otorhinolaryngol*. 2014;271:2277–83.
11. Redaelli de Zinis LO, Ferrari L, Tomenzoli D, Premoli G, Parrinello G, Nicolai P. Postlaryngectomy pharyngocutaneous fistula: incidence, predisposing factors, and therapy. *Head Neck*. 1999;21:131–8.
12. Bohannon IA, Carroll WR, Magnuson JS, Rosenthal EL. Closure of post-laryngectomy pharyngocutaneous fistulae. *Head Neck Oncol*. 2011;3:29.
13. Palomar-Asenjo V, Sarroca Capell E, Tobias Gomez S, Perez Hernandez I, Palomar-Garcia V. Pharyngocutaneous fistula following total laryngectomy. A case-control study of risk factors implicated in its onset in Spanish. *Acta Otorrinolaringol Esp*. 2008;59:480–4.
14. Guimarães AV, Aires FT, Dedivitis RA, Kulcsar MA, Ramos DM, Cernea CR, et al. Efficacy of pectoralis major muscle flap for pharyngocutaneous fistula prevention in salvage total laryngectomy: a systematic review. *Head Neck*. 2016;38 Suppl 1:E2317–21.
15. Paydarfar JA, Birkmeyer NJ. Complications in head and neck surgery: a meta-analysis of postlaryngectomy pharyngocutaneous fistula. *Arch Otolaryngol Head Neck Surg*. 2006;132:67–72.
16. Venegas MP, León X, Quer M, Matión E, Montoro V, Burgués J. Complications of total laryngectomy in relation to the previous radiotherapy. *Acta Otorrinolaringol Esp*. 1997;48:639–46.
17. Mäkitie AA, Niemensivu R, Hero M, Keski-Säntti H, Bäck L, Kajanti M, et al. Pharyngocutaneous fistula following total laryngectomy: a single institution's 10 year experience. *Eur Arch Otorhinolaryngol*. 2006;263:1127–30.
18. Papazoglou G, Doundoulakis G, Terzakis G, Dokianakis G. Pharyngocutaneous fistula after total laryngectomy: incidence, cause and treatment. *Ann Otol Rhinol Laryngol*. 1994;103:801–5.
19. Fink DS, Peña S, Hanby D, Kunduk M, McWhorter AJ. Repair of pharyngocutaneous fistula after total laryngectomy: a novel endoscopic approach. *Head Neck*. 2015;37:E81–4.
20. Natvig K, Boysen M, Tausjo J. Fistulae following laryngectomy in patients treated with irradiation. *J Laryngol Otol*. 1993;107:1136–9.
21. Mirghani H, Leymarie N, Amen F, Qassemyar Q, Leclère FM, Kolb F. Pharyngotracheal fistula closure using the internal mammary artery perforator island flap. *Laryngoscope*. 2014;124:1106–11.
22. Rees R, Cary A, Shack RB, Harris PF. Pharyngocutaneous fistulas in advanced cancer: closure with musculocutaneous or muscle flaps. *Am J Surg*. 1987;154:381–3.
23. McLean JN, Nicholas C, Duggal P, Chen A, Grist WG, Losken A, et al. Surgical management of pharyngocutaneous fistula after total laryngectomy. *Ann Plast Surg*. 2012;68:442–5.
24. Cordova A, Corradino B, Pirrello R, Di Lorenzo S, Dispenza C, Moschella F. Surgical treatment of pharyngostomes in irradiated patients. Our experience with musculocutaneous pectoralis major flap and hyperbaric oxygen therapy. *Acta Otolaryngol*. 2005;125:759–64.
25. Magdy EA. Surgical closure of postlaryngectomy pharyngocutaneous fistula: a defect based approach. *Eur Arch Otorhinolaryngol*. 2008;265:97–104.
26. McInnis WD, Kaaber EG, Pers M. The trapezius myocutaneous flap used for closure of pharyngeal fistulas. *Scand J Plast Reconstr Surg*. 1980;14:197–200.
27. Nakatsuka T, Harii K, Ebihara S, Saikawa M, Kato H, Tachimori Y, et al. Closure of large pharyngoesophageal fistulas with free Xap transfer after resections for cancer. *Scand J Plast Reconstr Surg Hand Surg*. 1998;32:163–70.
28. Min Yoo W, Suk Pae N, Pio Hong J, Kyung Lee H. Treatment of pharyngocutaneous fistulae with a cork-design radial forearm free flap. *J Reconstr Microsurg*. 2006;22:483–7.
29. Iteld L, Yu P. Pharyngocutaneous fistula repair after radiotherapy and salvage total laryngectomy. *J Reconstr Microsurg*. 2007;23:339–45.
30. Gilbert MR, Sturm JJ, Gooding WE, Johnson JT, Kim S. Pectoralis major myofascial onlay and myocutaneous flaps and pharyngocutaneous fistula in salvage laryngectomy. *Laryngoscope*. 2014;124:2680–6.
31. Patel UA, Moore BA, Wax M, Rosenthal E, Sweeny L, Militsakh ON, et al. Impact of pharyngeal closure technique on fistula after salvage laryngectomy. *JAMA Otolaryngol Head Neck Surg*. 2013;139:1156–62.