

A Retrospective Look at Integrating a Novel Regenerative Medicine Approach in Plastic Limb Reconstruction

Edgardo R. Rodriguez Collazo,
DPM*†
Christopher R. Rathbone, PhD‡
Brian R. Barnes, PhD‡

Full-thickness wounds that have rendered patients candidates for amputation may require techniques that may include a combinatorial approach above traditional standard of care. The purpose of this retrospective study was to evaluate the effectiveness of an innovative approach whereby several therapies were combined to avoid amputation. Patients with full-thickness wounds who were previously recommended for amputation and were treated with the combinatorial approach of muscle flap reconstruction and concentrated bone marrow aspirate, platelet-rich plasma, INTEGRA Wound matrix, vacuum-assisted closure, and split-thickness skin grafts were assessed retrospectively. The mean age of the patients identified was 48 years (range, 34–66 years). The average size of the defects was 19.6 cm². All defects were successfully covered with medial hemisoleus, lateral hemisoleus, or peroneus brevis muscle flaps combined with split-thickness skin grafts, concentrated bone marrow aspirate, and platelet-rich plasma. All flaps healed with an average time to fixator removal of 8.3 weeks; there was 1 above-knee amputation that occurred approximately after successful wound closing and fixator removal. The combinatorial approach described here including several regenerative medicine tools is an effective means of lower limb reconstruction to avoid amputation. (*Plast Reconstr Surg Glob Open* 2017;5:e1214; doi: 10.1097/GOX.0000000000001214; Published online 30 January 2017.)

Both the growing incidence of diabetes and the increase in the elderly population have contributed to the growing number of chronic wounds, creating a substantial societal, economic, and emotional burden.¹ The risk for amputation and subsequent mortality provides the impetus for directing efforts toward developing better treatments to treat high-risk nonhealing wounds.¹ Based on the sheer number of chronic wounds present in the medical system, the biological differences among patients, and the significant comorbidities inherent to this population, a subset of these wounds will fall outside

of what can be successfully treated by traditional medical care. The development and implementation of novel treatment strategies will be required to decrease morbidity and mortality in this population.

For nonhealing wounds, these novel treatment strategies will come in the form of advanced regenerative medicine strategies and reconstructive techniques and potentially an innovative implementation of the reconstructive ladder.² Ideally, as the number of treatments available increases, clinicians will be provided with the opportunity to combine approaches to facilitate their efforts in improving patient care. For example, muscle flaps are growing in use as a surgical option for soft tissue coverage, especially in the context of exposed hardware, when other wound healing methodologies have failed.^{3,4} Despite the robust cellular contribution provided by skeletal muscle, many flaps commonly used for soft tissue coverage lack

From the *Department of Surgery, Presence Health Saint Joseph Hospital, Chicago, Ill.; †Adult & Pediatric Ilizarov Lower Limb Deformity Correction and Peripheral Nerve & Muscular Microsurgical Reconstruction; Chicago Foot and Ankle Deformity Correction Center, Chicago, Ill. and ‡Arteriocyte Medical Systems, Hopkinton, Mass.

Received for publication May 13, 2016; accepted December 2, 2016. Copyright © 2017 The Authors. Published by Wolters Kluwer Health, Inc. on behalf of The American Society of Plastic Surgeons. This is an open-access article distributed under the terms of the Creative Commons Attribution-Non Commercial-No Derivatives License 4.0 (CCBY-NC-ND), where it is permissible to download and share the work provided it is properly cited. The work cannot be changed in any way or used commercially without permission from the journal.

DOI: 10.1097/GOX.0000000000001214

Disclosure: The authors have no financial interest to declare in relation to the content of this article. This work was supported in part by Arteriocyte Medical Systems. Arteriocyte Medical Systems provides support for a Hospital Based Observational Peer Education Program under the leadership of ERRC. CRR and BRB are employees of Arteriocyte Medical Systems. The Article Processing Charge was paid for by funds from the Hospital Based Observational Peer Education Program.

the subcutaneous layers required for definitive closure. Skin substitutes that supply both dermal and epidermal layers are encouraging; however, given the challenging microenvironment present in the most extreme of chronic wounds and the surgical and financial implications of a failed procedure, augmentation with cellular biologics may be warranted. Preclinical studies have already demonstrated the benefit of combining stem cells with a dermal skin substitute, such as INTEGRA Wound matrix (Integra, Plainsboro, N.J.) to enhance vascularization, collagen synthesis, and cellular infiltration.^{5,6} Today, point-of-care devices for the creation of autologous cellular therapies rich in stem cells and growth factors provide an easy bedside option for clinical utilization.⁷⁻⁹ The use of these devices is certainly logical and practical given the documented ability of their output in improving wound healing.^{10,11} Even with the potential of these therapies as stand alone, it is yet to be determined whether their full potential is realized in combination with other traditional therapies.

Substantial preclinical and increasing clinical evidence highlight the clinical efficacy of several wound strategies as stand-alone therapies. Unfortunately, strategies such as muscle flaps, wound vacuum, and dermal skin substitutes all have challenges that are not always surmountable. Although it is logical to take advantage of each of their attributes in a combinatorial approach, such clinical documentation is scarce. We describe herein the successful use of muscle flaps (peroneus brevis, lateral hemisoleus, and medial hemisoleus), skin substitutes (INTEGRA Wound matrix), concentrated bone marrow aspirate (cBMA), and the wound vacuum, and as an integrated means to treat difficult wounds that rendered patients candidates for amputation.

PATIENTS AND METHODS

All study procedures were approved by the Institutional Review Board at Presence Saint Joseph Hospital Institutional Review Board (Protocol #2016-11). Patients were identified by retrospective review of medical records of patients who were recommended for amputation before referral. All patients had been previously treated for greater than 11 months with palliative modalities, had full-thickness wounds in the distal 1/3 leg or hind foot to the level of bone and tendon, and were treated between March 2014 and November 2015. Before surgical procedures described herein, all cases were treated at other wound care centers with debridement and vacuum-assisted closure (VAC) therapy. Four of the 17 patients had active superficial infections and osteomyelitis (verified with biopsies and magnetic resonance imaging) being treated with systemic antibiotics at the time of surgery; each of whom continued antibiotics treatment of superficial infection for 6 weeks after the flap procedure.

Patients had an arteriogram to ensure sufficient vascular supply and to locate distal perforating vessels before surgery. Bone debridement was performed to the level of bleeding bone. In 4 cases, further debridement was required to account for osteomyelitis, and tissue cultures were taken to verify the absence of infection.

cBMA and platelet-rich plasma (PRP) were collected similar to that described previously.¹² Preoperatively, 52 mL of peripheral blood from the antecubital vein was drawn into a syringe containing 8 mL anticoagulant citrate dextrose solution (ACD-A, Arteriocyte Medical Systems, Hopkinton, Mass.), and the 60 mL of anticoagulated blood was placed in the Magellan System (Arteriocyte Medical Systems) to obtain 10 mL of PRP and approximately 12 mL platelet-poor plasma (PPP).

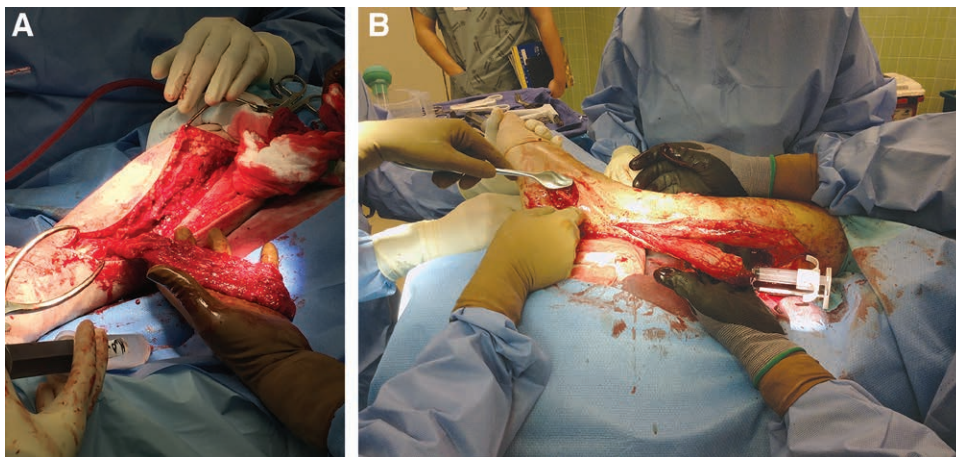


Fig. 1. Representative images of treatment strategy. Patient presents with nonhealing wound, which have failed traditional care strategies, and amputation has been recommended. A, Under general anesthesia, surgical exposure is made over the lateral compartment or medial aspect for soleus or peroneus brevis flaps. B, After blunt dissection to separate muscles containing the most distal perforator, a subcutaneous tunnel is created from the distal portion of the muscle flap incision to the proximal wound and flap is passed through the soft tissue tunnel. The cBMA and PRP is then applied to the wound bed and muscle flap as a thrombin-activated gel (not shown). The PPP, also as a gel, is used for hemostasis of the harvest site as seen with dual syringe applicator.

Intraoperatively, the medial aspect of the tibia was aspirated to obtain 60 mL of bone marrow aspirate. Briefly, a 15-gauge Jamshidi needle was used to access the marrow cavity. Fifty-two milliliters of bone marrow aspirate was drawn into a syringe containing 8 mL ACD-A under negative pressure. After filtration, the bone marrow aspirate was placed in the Magellan System (Arterioocyte Medical Systems) to obtain 10 mL of cBMA. cBMA, PRP, and PPP were all combined with calcified thrombin (5,000 units/5 mL CaCL) at application.

While under general anesthesia, surgical exposure was made over the lateral compartment or medial aspect for soleus and peroneus brevis flaps, with care taken to avoid associated nerves (Fig. 1). The deep fascia was incised to expose the peroneal compartment, and a linear fasciotomy of the lateral compartment was performed. After blunt dissection to separate muscles, intraoperative Doppler was used to identify the most distal perforator. For tunneled flaps, a subcutaneous tunnel was created from the distal portion of the muscle flap incision to the proximal wound. After the flap was passed through the soft tissue tunnel, Doppler was again used to ensure that adequate blood flow was maintained during transfer. The entire wound bed was secured with 5-0 vicryl at 4 locations 90 degrees apart. The cBMA and PRP (10 mL each) were injected into the wound bed before flap transfer and applied over the muscle bed before INTEGRA application. The PPP was used for hemostasis of the harvest site.

A 0.4-mm INTEGRA Bilayer Wound Matrix (Integra) was then applied over the muscle flap (Fig. 2). Negative-pressure wound therapy was applied for 7 to 10 days using the VAC device (Kinetic Concepts, San Antonio, Tex.), with a negative pressure of 75 mm Hg.¹³ To allow for offloading of the surgical site and to limit motion across the flap site, a static circular external fixator device was placed onto the lower extremity (Fig. 3). Approximately 17 days later, a split-thickness skin graft (0.018 inches) was applied over the INTEGRA Bilayer Wound Matrix for definitive closure. INTEGRA Thin Skin Wound Matrix was placed on the donor skin graft site.

RESULTS

A retrospective review was completed on 17 patients (all male; mean age, 48 years; range, 34–66 years). There were 17 ulcers in 17 limbs. Eleven patients were diabetic, 9 had a history of smoking, and all had chronic osteomyelitis and were treated with intravenous antibiotic for 6 weeks (Table 1). Wound covering was achieved using a reverse peroneus brevis flaps (7 cases) or soleus flaps (10 cases). The average wound size was 19.6 cm².

The fixator was removed at the time of healing. At the time of fixator removal, the limb was considered stable; the wound is fully healed and is not a risk to the limb. An example of the progression of healing up to the time of fixator removal can be seen in Figure 4. The average time to fixator removal was 8.3 weeks (Table 1). At the harvest site, there were hematomas present in 2 patients; 1 hematoma required evacuation. Of the 17 cases, there was 1

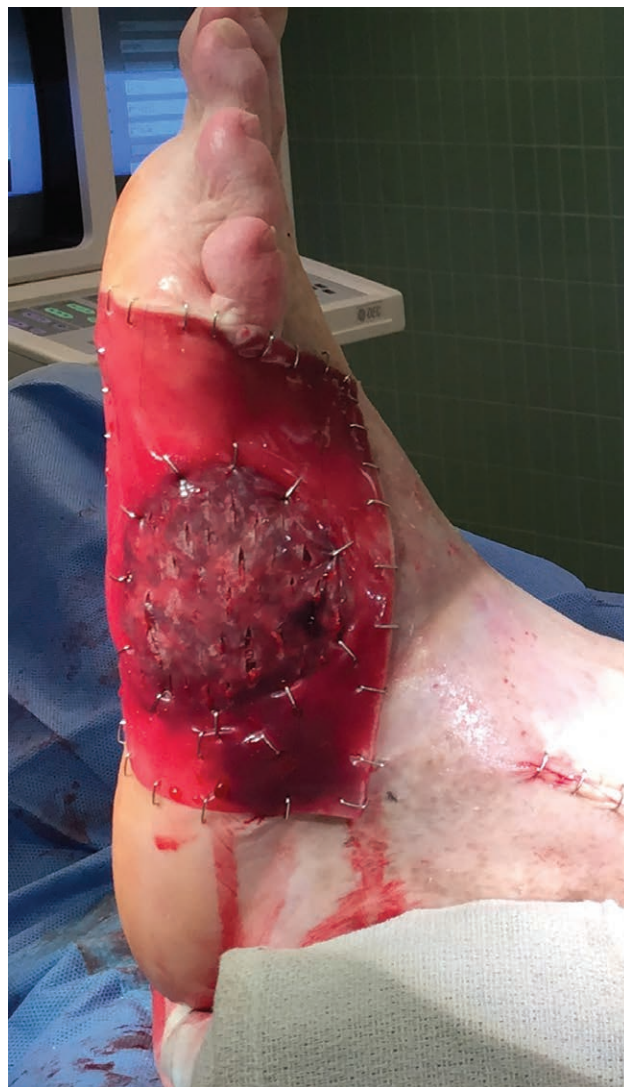

Fig. 2. Representative image of treatment strategy. After the preparation of the muscle flap as a wound cover, a 0.4-mm INTEGRA Bilayer Wound Matrix is applied over the muscle flap. A static circular external fixator is placed onto the lower extremity to allow for offloading of the surgical site and to limit motion across the flap site. Negative pressure wound therapy is applied for 7 to 10 days. Approximately 17 days later, a split-thickness skin graft (0.018 inches) is applied over the INTEGRA Bilayer Wound Matrix for definitive closure. INTEGRA Thin Skin Wound Matrix was placed on the donor skin graft site (not shown).

above-knee amputation that occurred approximately 1.5 months after successful wound closing and fixator removal. The likely cause was due to muscle necrosis of anterior compartment subsequent to compartment syndrome.

DISCUSSION

A large variety of synthetic, biologic, and surgical strategies can treat chronic open wounds. Unfortunately, amputation is sometimes required for patients who fail to heal with some of these therapies, presumably due to the challenges inherent to the wound environment in these

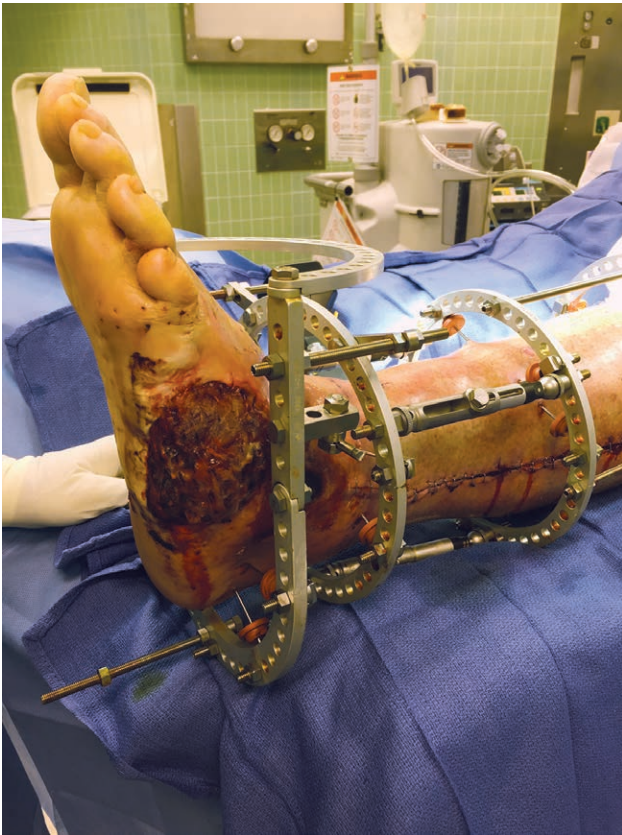


Fig. 3. Wound bed before skin graft is displayed.

patients. Herein, a multifaceted strategy for healing to overcome the deficiencies inherent to any one methodology through their synergistic combination was described. Specifically, the novel combination of muscle flaps, skin substitutes (INTEGRA), and autologous cell-based therapies (cBMA and PRP) were used for successful limb salvage. This approach was used previously in a 2-patient case series as a means of limb salvage.¹⁴ In the current case series, we have further provided validity to this integrated

approach and successfully treated wounds in 17 patients who were referred for amputation.

Given the dramatic consequences of amputation, it is appropriate to consider all options that are available. For example, more advanced surgical reconstructive techniques, ie, muscle flaps, are increasing for treating chronic wounds. Specifically, peroneus brevis, lateral hemisoleus, and medial hemisoleus have all been utilized depending on the wound location.^{3,4,13} Although their benefits include wound coverage and a wound bed that is supportive of the generation of new tissue, the potential for flap failure, or the need for revision, is still a concern and can lead to disastrous consequences.^{15,16} It should be noted that it is rare for the soleus to be advocated for distal 1/3 of leg; normally the soleus flap is reserved for usually only middle or proximal tibia coverage. In this study, both soleus muscle flaps and peroneus brevis flaps and the wound bed were augmented with cBMA and PRP. A logical speculation is that the bone marrow-derived stem cells and growth factors within the cBMA and PRP were useful in the prevention of muscle necrosis. Although the mechanisms are not yet fully understood, the beneficial effects of autologous wound coverage are many. Despite the advantages they hold, flaps alone do not fully satisfy the need for a dermal and epidermal barrier.

The INTEGRA Wound matrix, a dermal layer consisting of collagen and glycosaminoglycan in combination with a polysiloxane epidermal layer, was applied over the muscle flap. A concern when grafting or applying skin substitutes in this environment is the host microenvironment, especially given such a challenging patient population. A likely possibility is that the cBMA and PRP provided a more suitable environment for the INTEGRA Wound matrix. Whether the additional stem cells and growth factors improved the ability of negative-pressure wound therapy to increase angiogenesis is not known; however, a logical speculation is that the regenerative elements within cBMA and PRP initiated a healing cascade that was further sustained with the wound vacuum. We have previously applied skin graft on the day of surgery. A delayed skin graft protocol utilizing the autologous

Table 1. Patient Demographics

Patient	Age (y)	Comorbidity	Wound Type	Wound Size (cm × cm)	Muscle Flap Type	Preoperative Infection	Postflap Complications	Time to Fixator Removal (wk)
1	37	DM/S	FT	3×5	PB	Active osteomyelitis	SI (Abx 6wk)	6
2	42	DM/S	FT	2×3	PB	None	None	10
3	36	DM/S	FT	2×4	S	Active osteomyelitis	SI (Abx 6wk)	3
4	53	None	FT	5×5	PB	None	None	8
5	61	None	FT	7×2	PB	None	None	7
6	45	DM/S	FT	4×9	S	None	None	2
7	65	DM/S	FT	9×5	S	Active osteomyelitis	Hematoma	12
8	34	DM	FT	3×3	S	None	None	14
9	34	None	FT	4×4	PB	None	None	6
10	56	DM/S	FT	7×5	PB	None	None	5
11	51	None	FT	6×3	S	None	Hematoma	9
12	45	None	FT	3×2	S	None	None	11
13	66	DM/S	FT	5×3	PB	None	None	16
14	43	DM/S	FT	4×7	S	Active osteomyelitis	SI (Abx 6wk)	10
15	39	None	FT	7×3	S	None	None	9
16	54	DM/S	FT	3×9	S	None	Amp (AK)	7
17	55	DM	FT	5×2	S	None	None	6

Abx, antibiotics; AK, above knee; Amp, amputation; DM, diabetes mellitus; FT, full thickness; PB, peroneus brevis; S, smoking; SI, superficial infection.

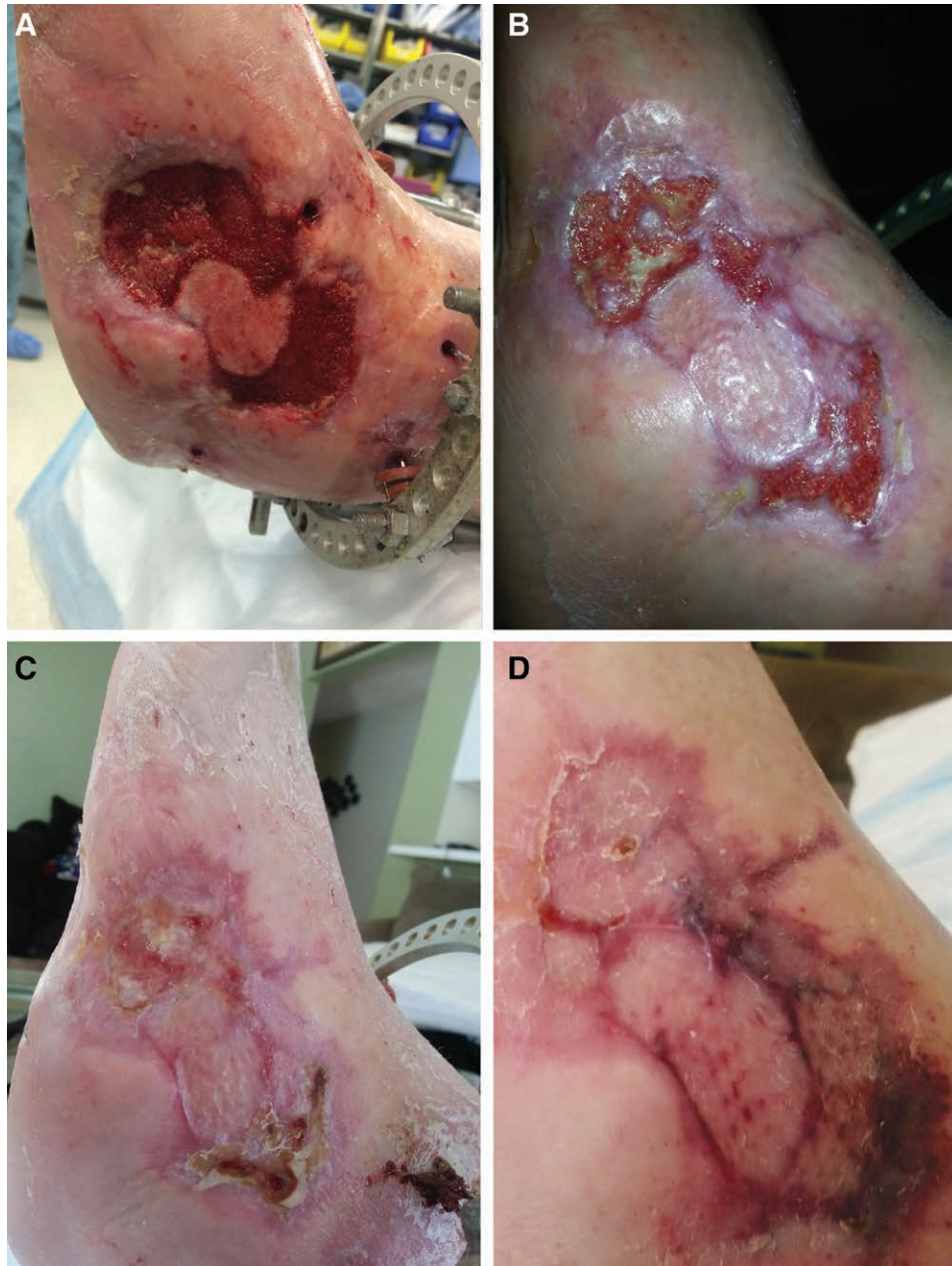

Fig. 4. Images of wound healing progression: (A) 18, (B) 25, (C) 38, and (D) 45 days after surgery.

therapies described here is preferred to ensure sufficient site preparation to allow for better graft take. Nonetheless, given that the wound bed was sufficient for 100% graft take 17 days later, it is likely that this combinatorial approach was effective.

In addition to the biological factors employed, careful consideration to the external parameters was given, namely, the use of external fixation. It was our intention to allow micromotion to allow for the lining up of myofibrils and improve angiogenesis, as opposed to macromotion where shear forces may inhibit these processes. At the time of the removal of the fixator, the limb was no longer considered to be in a state of limb salvage, and the procedure

was deemed successful. Also, although much emphasis has been placed on the wound, it is also important to point out that the donor site was also given consideration. To take full advantage of the many opportunities that autologous cell processing, the platelet-poor plasma fraction was also collected and used as a means of hemostatic control of the donor site.

The combinatorial approach used herein prevents the objective evaluation of the relative contribution of each of these approaches. Similarly, the extent to which each of these methods is additive cannot be determined. Also, the extent to which combining any 2 of these approaches is superior to any 1 approach alone will require randomized,

controlled, double-blinded trial for definitive conclusions to be made. Regardless, given the urgency to prevent amputation, the integrative approach used here is warranted. An optimistic view is that eventually the use of the described or a similar approach will be entirely predictive of closure, and the next obstacle to be overcome will be decreasing the time to complete healing. Preclinical studies employing a reductionist approach where each method is removed in a stepwise strategy and healing outcomes are evaluated are warranted. However, given the relative ease of employing each of these methods and the limited morbidity expressed here, their inclusion seems warranted. When making the decision to include the combination of these techniques, it is also important to take into consideration the increased costs associated with this approach. However, when considering the initial costs incurred during the procedure, it is also important to take into consideration the cost savings from potentially bypassing the need for future invasive procedures. It is critical to emphasize that all the patients consented were headed for amputation. Although it is difficult to ascertain the collective benefit of employing the approaches simultaneously, the high success rate provides the impetus for further consideration and investigation.

CONCLUSIONS

The challenge of treating difficult wounds may require approaches that exceed the ability of any one given therapy. The data herein support the combinatorial use of muscle flaps, cBMA, PRP, INTEGRA wound matrix, VAC, and split-thickness skin grafts to treat difficult wounds. The relative contribution of any one of these therapies with this approach remains to be determined.

Edgardo R. Rodriguez Collazo, DPM

Department of Surgery
Presence Health Saint Joseph Hospital
2900 N Lakeshore Drive
Chicago, IL 60657
E-mail: erodriguez@cfaas.com

REFERENCES

- Greer N, Foman NA, MacDonald R, et al. Advanced wound care therapies for nonhealing diabetic, venous, and arterial ulcers: a systematic review. *Ann Intern Med.* 2013;159:532–542.
- Levin LS. The reconstructive ladder. An orthoplastic approach. *Orthop Clin North Am.* 1993;24:393–409.
- Ceran C, Demirseren ME, Aksam E, et al. Lateral malleolar region defects with exposed implants: proximally based peroneus brevis muscle flap. *J Wound Care.* 2015;24:372–377.
- Schirmer S, Ritter RG, Fansa H. Vascular surgery, microsurgery and supramicrosurgery for treatment of chronic diabetic foot ulcers to prevent amputations. *PLoS One.* 2013;8:e74704.
- Meruane MA, Rojas M, Marcelain K. The use of adipose tissue-derived stem cells within a dermal substitute improves skin regeneration by increasing neoangiogenesis and collagen synthesis. *Plast Reconstr Surg.* 2012;130:53–63.
- Fierro FA, O'Neal AJ, Beegle JR, et al. Hypoxic pre-conditioning increases the infiltration of endothelial cells into scaffolds for dermal regeneration pre-seeded with mesenchymal stem cells. *Front Cell Dev Biol.* 2015;3:68.
- Wehberg KE, Answini G, Wood D, et al. Intramyocardial injection of autologous platelet-rich plasma combined with transmyocardial revascularization. *Cell Transplant.* 2009;18:353–359.
- Zavadil DP, Satterlee CC, Costigan JM, et al. Autologous platelet gel and platelet-poor plasma reduce pain with total shoulder arthroplasty. *J Extra Corpor Technol.* 2007;39:177–182.
- Podesta L, Crow SA, Volkmer D, et al. Treatment of partial ulnar collateral ligament tears in the elbow with platelet-rich plasma. *Am J Sports Med.* 2013;41:1689–1694.
- de Leon JM, Driver VR, Fylling CP, et al. The clinical relevance of treating chronic wounds with an enhanced near-physiological concentration of platelet-rich plasma gel. *Adv Skin Wound Care.* 2011;24:357–368.
- Rogers LC, Bevilacqua NJ, Armstrong DG. The use of marrow-derived stem cells to accelerate healing in chronic wounds. *Int Wound J.* 2008;5:20–25.
- Rodriguez-Collazo ER, Urso ML. Combined use of the Ilizarov method, concentrated bone marrow aspirate (cBMA), and platelet-rich plasma (PRP) to expedite healing of bimalleolar fractures. *Strategies Trauma Limb Reconstr.* 2015;10:161–166.
- Park CA, Defranzo AJ, Marks MW, et al. Outpatient reconstruction using integra* and subatmospheric pressure. *Ann Plast Surg.* 2009;62:164–169.
- Collazo ERR, Weiland J, Manson TS, Jones A. Peroneus brevis muscle flap with the use of INTEGRA Wound matrix and split thickness skin graft in the treatment of full thickness ulcerations: case reports and technique guide. *Ortho & Rheum Open Access J.* 2015;1:555567.
- Keys KA, Daniali LN, Warner KJ, et al. Multivariate predictors of failure after flap coverage of pressure ulcers. *Plast Reconstr Surg.* 2010;125:1725–1734.
- Ensat F, Hladik M, Larcher L, et al. The distally based peroneus brevis muscle flap-clinical series and review of the literature. *Microsurgery* 2014;34:203–208.