

Amelioration of nitrobenzene-induced nephrotoxicity by the ethanol extract of the herb *Euphorbia hirta*

Subramanian Suganya¹, Dominic Sophia², Chinthamony Arul Raj², Muthaiyan Ahalliya Rathi¹, Lakshmanan Thirumoorthi², Periyasamy Meenakshi¹, Dugganaboyana Guru Kumar¹, Velliyur Kanniyapan Gopalakrishnan^{1,2}

¹Department of Biochemistry, Karpagam Arts and Science College, ²Department of Biochemistry, Karpagam University, Coimbatore – 641 021, Tamil Nadu, India

Submitted: 19-01-2011

Revised: 02-05-2011

Published: 16-09-2011

ABSTRACT

Background: *Euphorbia hirta* (L.) (Euphorbiaceae) is a very popular herb amongst practitioners of traditional medicine and used in the treatment of female disorders, respiratory ailments, tumors, jaundice, digestive problems, wounds, etc. We aimed to evaluate the protective effect of *E. hirta* against nitrobenzene-induced nephrotoxicity in albino rats. **Materials and Methods:** The nephroprotective activity of the ethanol extract of *E. hirta* (400 mg/kg body weight) was studied in nitrobenzene-induced albino rats (1000 mg/kg body weight). The activities of antioxidant enzymes superoxide dismutase (SOD), catalase (CAT), glutathione peroxidase (GPx), glutathione-S-transferase (GST), and the levels of reduced glutathione (GSH), total thiols and vitamin C in the kidney tissues were determined. Histopathologic investigation was performed in the kidney tissue samples. **Results:** Nitrobenzene administration significantly ($P < 0.01$) enhanced the lipid peroxidation and significantly ($P < 0.05$) depleted the levels of SOD, CAT, GPx, GST, GSH, total thiols and vitamin C. Treatment with the ethanol extract of *E. hirta* significantly normalized the antioxidant levels. The nephroprotective activity was also supported by histopathologic studies of kidney tissue. **Conclusion:** The results indicate that the ethanol extract of *E. hirta* ameliorates renal dysfunction and could be used as an effective protector against nitrobenzene-induced nephrotoxicity, primarily through its antioxidant capacity.

Key words: Antioxidant, *Euphorbia hirta*, histopathology, nephrotoxicity, nitrobenzene

INTRODUCTION

Nephrotoxicity is a major complication characterized by morphological destruction of intracellular organelles, cellular necrosis, loss of microvilli, alterations in the number and size of the lysosomes and mitochondrial vacuolization, followed by functional alterations including inhibition of protein synthesis, reduced glutathione (GSH) depletion, lipid peroxidation (LPO) and mitochondrial damage.^[1] Oxidative damage is thought to be one of the main mechanisms involved in nearly all chronic renal pathologies.^[2]

Nitrobenzene induces tumorigenicity in liver, kidney,

thyroid, alveola and mammary gland. It causes functional and morphological changes in the cell membrane, leading to the accumulation of lipid derived oxidants causing liver injury and also induces nephrotoxicity.^[3] Nitrobenzene is considered a hazardous air pollutant and has proven to be an animal carcinogen. It is classified as a group B2 chemical according to the 1986 Cancer guidelines,^[4] that is, a likely human carcinogen. Metabolism of nitrobenzene produces intermediates such as nitrosobenzene and phenyl hydroxylamine that play an important role in the process of nitrobenzene carcinogenesis.^[5]

Several animal models have been used to study the possible role of antioxidants of natural origin in alternative drug-induced nephropathy and other renal diseases. Studies are going on throughout the world for the search of protective molecules that would provide maximum protection to the liver, kidney as well as other organs and

Access this article online

Website:

www.phcogres.com

DOI:

10.4103/0974-8490.85009

Quick Response Code:**Address for correspondence:**

Dr. Velliyur Kanniyapan Gopalakrishnan, Department of Biochemistry, Karpagam University, Coimbatore – 641 021, Tamil Nadu, India. E-mail: vk.gopalakrishnan@karpagam.ac.in

that would practically exert very little or no side effects during their function in the body.^[6,7] A number of herbs are traditionally used in different countries for treating drug- or toxin-induced hepatic and renal disorders.^[8] Many herbs and medicinal plants are rich natural sources of antioxidants.^[9] The fact that antioxidants have several preventative effects against different diseases, such as cancer, coronary diseases, inflammatory disorders, neurologic degeneration, and aging, has led to a search for foods rich in antioxidants.^[10]

According to World Health Organization (WHO), because of poverty and lack of access to modern medicine, about 65–80% of the world's population living in developing countries depends essentially on plants for primary health care.^[11] Drug of plant origin is known to play a vital role in the management of kidney diseases^[12] and as a source of safe antioxidants. Kidney failure shall be managed by similar means of non-pharmacological and pharmacological therapeutic interventions.^[13]

Euphorbia hirta is frequently seen growing in open waste spaces, grasslands, roadsides and pathways. It is slender-stemmed, annual, hairy plant with many branches from the base to top, spreading up to 40 cm in height, and is reddish or purplish in color. It is widely used to treat a variety of disease conditions including asthma, boils, sores, skin and wound infections.^[14] In addition, it has been used as antispasmodic, antipruritic, carminative, depurative, diuretic, febrifuge, galactagogue, pugnitive and vermifuge.^[15] The aqueous extract of *E. hirta* showed an antioxidant effect and a free radical scavenging activity.^[16] Earlier studies reported that the extract of *E. hirta* contains tannins, flavonoids and alkaloids.^[17] Afzelin (I), quercitrin (II), and myricitrin (III) have been isolated from the methanol extract of *E. hirta*.^[18] Various phytochemicals reported in *E. hirta* are ellagic, gallic, chlorogenic and caffeic acid, kaempferol, quercitol, quercitrin and a number of amino acids.^[19] Recently, it has been reported that the ethylacetate fraction of *E. hirta* has a protective effect against ethanol-induced gastric ulcer.^[20] With this background, the present study was designed to investigate the nephroprotective efficacy of the whole plant of *E. hirta*.

MATERIALS AND METHODS

Plant Collection

The whole plant of *E. hirta* (Linn.) (Family: Euphorbiaceae) in the blossomed stage was collected in the month of December 2008 from Pollachi, Tamil Nadu, India. The plant was authenticated by Dr. G. V. S. Moorthy, Botanical Survey of India, TNAU campus, Coimbatore, with the voucher number BSI/SC/5/23/8-9/Tech/766. Fresh plant

material was washed under running tap water, air-dried, finely powdered and stored in airtight bottles.

Chemicals

Nitrobenzene was purchased from E. Merck Limited (Mumbai, India). 5,5'-Dithio-bis(2-nitrobenzoic acid) (DTNB), 1-chloro-2,4-dinitrobenzene (CDNB), 2,4-dinitrophenylhydrazine (DNPH), epinephrine, and GSH were obtained from Sisco Laboratories, Mumbai, India. All other chemicals used were of analytical grade.

Preparation of Different Plant Extracts

About 50 g of the powdered plant material *E. hirta* was extracted with 250 ml petroleum ether, chloroform, ethyl acetate, ethanol, and water by using a separating funnel with occasional shaking for 48 hours. The extract was filtered using Whatman No. 1 filter paper and the supernatant was evaporated using rotary evaporator at 45°C. Each time before extracting with the next solvent, the supernatant was filtered and the residue was dried thoroughly to remove the solvent used.^[21] Phytochemical screening of the ethanol extract indicates the presence of alkaloids, steroids, tannins and flavonoids, and it also shows the high percentage of yield (10.18%) than the other extracts and thus it is chosen for the present study. The yield of the various extracts is given in Table 1. The ethanol extract was dissolved in 0.5 ml of distilled water and administered orally by gavage to animals.

Phytochemical Analysis

Preliminary phytochemical analysis of various extracts was performed to identify various phytoconstituents.^[22] Results of phytochemical screening are shown in Table 2.

Animals Used

Female albino rats of Wistar strain weighing between 140 and 160 g were obtained from Animal house of Karpagam University, Coimbatore. The animals were housed in large spacious cages and were given food and water *ad libitum* during the course of the experiment. The animal room was well ventilated and the animals had a 10 ± 1 hour night schedule throughout the experimental period. The study was approved by Institutional Animal Ethical Committee (IAEC) constituted for the purpose of CPCSEA, Government of India.

Table 1: Percentage of yield of various extracts of *Euphorbia hirta*

Solvents	% Yield in mg/g
Petroleum ether	6.62
Chloroform	4.85
Ethyl acetate	3.14
Ethanol	10.18
Water	6.13

Table 2: Phytochemical screening of *Euphorbia hirta*

Extracts	AL	SA	TP	FL	ST	CG	OF	TN	AP	CH
Petroleum ether	-	+	-	-	+	+	-	+	-	-
Chloroform	-	-	-	-	-	-	-	+	-	+
Ethyl Acetate	-	+	-	-	-	-	-	-	-	-
Ethanol	+	+	+	+	-	-	+	+	+	+
Water	-	-	+	-	+	+	-	-	+	-

AL = Alkaloids; SA = Saponin; TP = Tannin and phenolic compounds; FL = Flavonoids; ST = Steroids; CG = Cardioglycosides; OF = Oils and fats; TN = Terpenoids; AP = Amino acids and proteins; CH = Carbohydrates, "+", Present; "-", absent

Experimental Design

The animals were divided into four groups of six rats each. The grouping is as follows.

Group I: Control animals treated with distilled water and kept as normal; group II: nephrotoxicity was induced in Wistar albino rats by oral administration of nitrobenzene (E. Merck) (1000 mg/kg body weight) in normal saline as vehicle (0.89% sodium chloride) at a single dose and this dose is known to cause nephrotoxicity in rats;^[3] group III: nitrobenzene-administered animals treated with ethanol extract of *E. hirta* (400 mg/kg body wt) in distilled water as vehicle orally for a period of 7 days; group IV: *E. hirta* ethanol extract treated animals (400 mg/kg body wt).

After the experimental period of 7 days, the animals were sacrificed under light chloroform anesthesia. The kidneys were excised immediately, cleaned free of extraneous material, homogenized in chilled Tris buffer (10 mM, pH 7.4), centrifuged and the supernatant was used for the antioxidant studies. A portion of kidney tissues which was immediately stored in 10% formalin was used for the histopathologic studies.

Determination of Tissue Protein

Protein was estimated by method of Folin–Lowry.^[23] The blue color developed by reduction of the phosphomolybdic–phosphotungstic components of Folin–Ciocalteu reagent by the amino acids tyrosine and tryptophan present in protein plus the color developed by biuret reaction of the protein with alkaline cupric tartarate are measured in Lowry's method.

Lipid Peroxidation

LPO was assayed by the method of Hogberg *et al.*^[24] Malondialdehyde (MDA) has been identified as the product of LPO that reacts with thiobarbituric acid to give a red color. The amount of MDA formed in each of the samples was assessed by measuring the optical density of the supernatant at 535 nm against a blank that contained the entire reagent without the sample. The results were expressed as nmoles of MDA formed/mg protein.

Determination of Enzymatic Renal Antioxidants

Superoxide dismutase (SOD) was assayed in the tissue

supernatant by the method of Misra and Fridovich^[25] based on the oxidation of epinephrine to adrenochrome transition by the enzyme SOD. SOD activity was recorded at 480 nm and expressed as units/mg protein. One unit of enzyme was defined as the amount of enzyme giving a change in optical density/minute at 50% inhibition of epinephrine to adrenochrome transition. Catalase (CAT) activity was assayed in the tissue supernatant by the method of Lueck.^[26] It causes rapid decomposition of hydrogen peroxide to water. The green color developed was read at 570 nm using a photochem colorimeter. CAT activity was expressed as μ moles of H₂O₂ consumed/min/mg protein under incubation conditions. Glutathione peroxidase (GPx) activity was assayed in the tissue supernatant by the method of Rotruck *et al.*^[27] This procedure is based on the reaction between leftover glutathione in the following reaction with the DTNB to form a compound which absorbs maximally at 420 nm and measured using a photo-colorimeter. Graded concentrations of the standard were also treated similarly. GPx activity was expressed as μ g of glutathione utilized min/mg protein under incubation conditions. Glutathione-S-transferase (GST) activity was assayed by the method of Habig *et al.*^[28] GST catalyzes the reaction of CDNB with sulfhydryl group of glutathione. The conjugate, CDNB–glutathione, absorbs light at 340 nm and was calculated as nmol CDNB conjugate formed/min/mg protein.

Determination of Non-Enzymatic Renal Antioxidants

GSH content in the tissue supernatant was measured following the method described by Moran *et al.*^[29] GSH is measured by its reaction with DTNB (Ellman's reaction) to give a compound that absorbs at 420 nm. The amount of glutathione was expressed as μ g of GSH/mg protein. Total thiol in the tissue homogenate was measured using DTNB as the coloring agent, as described by Sedlack and Lindsay.^[30] The yellow color developed was read immediately at 412 nm in a spectrophotometer. The total thiol content was calculated by using a molar extinction co-efficient of 13.6×10^3 /M/cm. Vitamin C content was assayed in the tissue homogenate by the method of Omaye *et al.*^[31] Vitamin C is oxidized by copper to form dehydroascorbic acid and diketoglutaric acid. These products are treated with DNPH to form the derivative of bis(2,4-dinitrophenylhydrazine). The color developed was read at 520 nm using a photochem colorimeter. Vitamin C level was expressed as mg/g tissue.

Histopathologic Analysis

The renal tissues were fixed in 10% formalin immediately after removal from the animal to avoid decomposition. Blocks from tissues were routinely processed and embedded in paraffin. Thin sections were cut using rotary microtome and stained with hematoxylin and eosin for histomorphology evaluation.

Statistical Analysis

The results obtained were expressed as mean \pm SD. The statistical comparisons among the groups were performed with Student's *t*-test using a Statistical Package Program (SPSS 10.0 for Windows) at $P < 0.05$ and $P < 0.01$ levels.

RESULTS

Effect of *E. hirta* extract on lipid peroxidation

Table 1 shows the level of MDA in the kidney homogenates of group I, II, III and IV animals. The MDA levels in nitrobenzene-induced group (group II) were found to be significantly ($P < 0.01$) elevated compared to the normal animals (group I). Group III animals treated with the ethanol extract of *E. hirta* showed significant ($P < 0.01$) reduction in MDA level. MDA level in ethanol extract alone treated animals (group IV) was almost close to normal animals (group I).

Effect of *E. hirta* Extract on Antioxidant Status

Effect on enzymatic antioxidants

The activities of enzymatic antioxidants in the kidney homogenates of all the groups of animals are shown in Table 3. The SOD activity in nitrobenzene-induced group (group II) was significantly ($P < 0.01$) reduced compared to normal animals (group I). Treatment with the ethanol extract of *E. hirta* (group III) showed a significant ($P < 0.01$) increase in SOD activity compared to nitrobenzene-induced group (group II). The activity of CAT in nitrobenzene-induced group (group II) was significantly ($P < 0.01$) decreased when compared to normal group (group I). Treatment with the ethanol extract of *E. hirta* (group III) significantly ($P < 0.01$) prevented the decrease in the activity of CAT compared with the nitrobenzene-induced group (group II). The decreased GPx activity as a result of treatment with nitrobenzene (group II) was also restored by the ethanol extract of *E. hirta* (group III) as compared with the normal animals (group I). Likewise, the nitrobenzene treatment significantly ($P < 0.01$) diminished the levels of GST. Treatment with the ethanol extract of *E. hirta* (group III) resulted in a significant ($P < 0.01$) recovery of the reduced levels of GST. The enzymatic antioxidant activity in the ethanol extract alone treated group (group IV) was almost close to that of normal animals (group I) and there was no significant difference.

Table 3: The concentration of protein, lipid peroxidation and antioxidant enzymes in kidney of control and experimental groups

Particulars	Control (group I)	Nitrobenzene control (group II)	Nitrobenzene + plant extract treated (1 ml) (group III)	Plant extract treated (1 ml) (group IV)
Protein (mg/g)	51.1 \pm 2.5	35.0 \pm 1.6 ^{a**}	45.5 \pm 1.93 ^{b**}	51.8 \pm 2.8 ^{cNS}
Lipid peroxidation (nmoles of MDA formed/mg protein)	3.2 \pm 0.15	5.12 \pm 1.58 ^{a**}	2.5 \pm 0.79 ^{b**}	3.00 \pm 0.94 ^{cNS}
Superoxide dismutase (units/mg protein)	52.8 \pm 0.18	35.0 \pm 0.31 ^{a**}	45.3 \pm 0.17 ^{b**}	53.5 \pm 0.22 ^{cNS}
Catalase (μ moles of H ₂ O ₂ utilized/min/mg protein)	5.8 \pm 0.36	4.0 \pm 0.19 ^{a**}	4.8 \pm 0.22 ^{b**}	5.31 \pm 0.29 ^{cNS}
Glutathione peroxidase (μ moles of GSH utilized/min/mg protein)	2.4 \pm 0.16	0.9 \pm 0.015 ^{a**}	1.4 \pm 0.25 ^{b**}	2.1 \pm 0.14 ^{cNS}
Glutathione-S-transferase (nmoles of CDNB conjugate/min/mg protein)	0.45 \pm 0.03	0.33 \pm 0.02 ^{a**}	0.4 \pm 0.15 ^{b**}	0.48 \pm 0.01 ^{cNS}

Values are expressed as Mean \pm SD; values are taken as a mean of five individuals experiments; ^aGroup II compared with group I, ^bGroup III compared with group II, ^cGroup IV compared with group I; *Significance at $P < 0.05$; **significance at $P < 0.01$; NS, not significant

Table 4: The concentration of non-enzymatic antioxidants in kidney of control and experimental groups

Particulars	Control (group I)	Nitrobenzene control (group II)	Nitrobenzene + plant extract treated (1 ml) (group III)	Plant extract treated (1 ml) (group IV)
Glutathione (μ g of GSH/mg protein)	3.4 \pm 0.51	2.2 \pm 0.25 ^{a**}	2.8 \pm 0.32 ^{b**}	3.0 \pm 0.45 ^{cNS}
Total thiol (μ g of GSH/mg protein)	7.13 \pm 0.32	5.18 \pm 0.23 ^{a**}	6.52 \pm 0.49 ^{b**}	7.00 \pm 0.22 ^{cNS}
Vitamin C (mg/g tissue)	1.3 \pm 0.15	0.64 \pm 0.01 ^{a**}	0.98 \pm 0.02 ^{b**}	1.37 \pm 0.16 ^{cNS}

Values are expressed as Mean \pm SD; values are taken as a mean of five individuals experiments; ^aGroup II compared with group I; ^bGroup III compared with group II; ^cGroup IV compared with group I; *Significance at $P < 0.05$; **significance at $P < 0.01$; NS, not significant

Effect on non-enzymatic antioxidants

GSH, total thiols and vitamin C levels of nitrobenzene-induced and ethanol extract treated groups (group II and group III) are shown in Table 4. The levels of GSH, total thiols and vitamin C were significantly ($P < 0.01$) decreased in the nitrobenzene-induced group (group II) as compared to the normal group (group I). On treatment with the ethanol extract of *E. hirta* (group III), GSH, total thiols and vitamin C levels were found to be enhanced significantly ($P < 0.01$). There was no significant difference between the ethanol extract alone treated group (group IV) and normal group (group I).

Histopathology

Histopathologic studies also provided a supportive evidence for biochemical analysis. In case of control (group I), the kidney section showed normal glomeruli, Bowman's tubules and blood vessels. The kidney section of the animals induced with nitrobenzene (group II) showed glomerular degeneration with loss of surrounding Bowman's capsule and tubular necrosis. Treatment with the ethanol extract of *E. hirta* (group III) showed a glomerulus with an intact Bowman's capsule, and all the renal cells which were damaged due to nitrobenzene appeared to be regenerated and almost showed normal histology. The kidney section of the animals that received the ethanol extract of *E. hirta* alone (group IV) showed normal morphology [Figure 1].

DISCUSSION

Blood urea nitrogen (BUN), serum urea, uric acid and

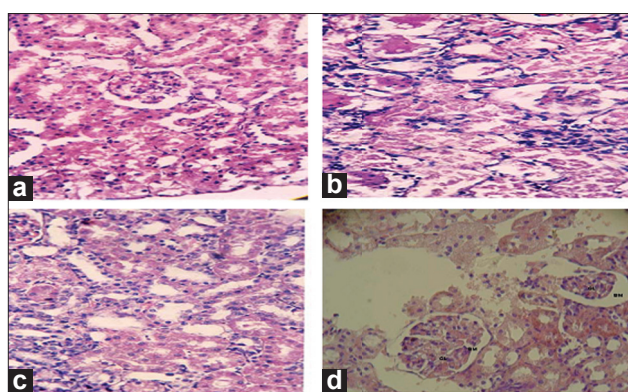


Figure 1: Histopathology of kidney. (a) Kidney section of the normal rat (group I) showing normal tubular brush borders and intact glomerulus and surrounding Bowman's capsule; (b) kidney section of the rat induced with nitrobenzene (group II) showing a glomerulus with loss of surrounding Bowman's capsule and tubular necrosis with swelling and vacuolation; (c) kidney section of the rat induced with nitrobenzene and treated with ethanol extract of *Euphorbia hirta* (group III) showing a glomerulus with an intact Bowman's capsule and mildly swollen tubules and almost showing normal morphology; (d) kidney section of rat treated with extract alone showing normal glomerulus and Bowman's capsule

creatinine are considered as the indicators of kidney damage, and their abnormal levels indicate marked renal injury. In our previous basic study, nitrobenzene induction produced an elevation in the concentrations of BUN, serum urea, and creatinine and significant reduction in the level of uric acid. Treatment with *E. hirta* significantly restored the levels to normalcy.^[32] In the present study, nitrobenzene increased the level of renal tissue MDA production, which suggested involvement of free radicals in nitrobenzene-induced nephrotoxicity. Nitrobenzene produces a number of free radicals during its reactive metabolism in the gut as well as at the cellular level and generates superoxide anion as a by-product during oxidative metabolism. The reactive species generated during nitrobenzene metabolism are considered candidates for carcinogenicity. Furthermore, several lines of evidence suggest that nitrobenzene exerts its carcinogenicity through a non-DNA reactive (epigenetic) fashion, such as a strong temporal relationship between non-, pre- and neoplastic lesions leading to carcinogenesis.^[33]

The elevated levels of LPO in nitrobenzene-induced animals might be due to the renal damage caused by nitrobenzene-induced free radical generation. LPO, an index of oxidative stress, leads to deterioration of biological system^[34] and is ascribed to a free radical mediated chain reaction that damages cell membrane and implicates renal oxidative stress.^[35] Oxidative stress is believed to be a primary factor in various diseases.^[36] Oxidative stress could also be involved in other inflammatory glomerular lesions caused by a series of mediators including cytokines and chemokines, which leads to leukocyte activation, production of reactive oxygen species (ROS) and increased glomerular damage.^[37] Different studies have shown that free radicals are responsible for oxidative damage to different molecules (lipids, proteins, nucleic acid) and thus are involved in the initiation phase of some degenerative illnesses.^[38] The elevated level of lipid peroxides in nitrobenzene-induced group would be a transient phenomenon of cellular damage.^[39] In animals treated with ethanol extract of *E. hirta*, the rise in lipid peroxides was prevented significantly. The decrease in lipid peroxides may be due to the antioxidant effect of the extract.

The generation of ROS in kidney has been proposed as a mechanism by which many chemicals can induce nephrotoxicity.^[40] The ROS generation in tissues is efficiently scavenged by the enzymatic and non-enzymatic antioxidants. The decrease in the activities of antioxidant enzymes is in close relationship with the induction of LPO.^[41] Thus, the mechanism of nephrotoxicity is related to the depletion of the antioxidant defense system.^[1] The reduced activity of SOD, CAT, GPx and GST could be

due to enhanced LPO or inactivation of the antioxidative enzymes.^[42] The present work confirms that the observed decrease in the antioxidant activity was presumably associated with the increased LPO and oxidative stress caused by nitrobenzene. The ethanol extract administration restored the depleted renal antioxidants. This recovery to near normalcy reveals that oxidative stress induced by nitrobenzene has been nullified due to the antioxidant potential effect of *E. hirta*.

The antioxidant activity may be due to the inhibition of the formation of radicals or scavenging of the formed radical.^[43] Supplementation of plant material improves all these parameters. Similar results have been reported by a number of investigators.^[44,45] The biochemical findings were also supported by the histopathologic studies which showed a glomerulus with loss of surrounding Bowman's capsule and diffuse tubular necrosis in the renal section of rats induced with nitrobenzene. These histopathologic changes almost disappeared in the renal tissue of rats treated with the ethanol extract of *E. hirta*. Numerous studies have also shown that medicinal plants protect the kidney against nephrotoxicity induced by various chemicals.^[46,47] Thus, the ethanol extract of *E. hirta* at a dosage of 400 mg/kg body weight showed a significant change against nitrobenzene-induced nephrotoxicity. Preliminary phytochemical screening of the ethanol extract of *E. hirta* showed a higher concentration of flavonoid. Literature has shown medicinal plants with nephroprotective properties to mediate their protection via antioxidant and/or free radical scavenging activities due to the high concentration of flavonoids and alkaloids that they contain.^[48,49] Thus, in the present study, nephroprotection offered by the ethanol extract of *E. hirta* could be due to the presence of higher concentration of flavonoids present in it.

CONCLUSION

Thus, the results of this investigation suggest that the ethanol extract of *E. hirta* can prevent the toxic effects of nitrobenzene and can be used in the treatment of nephrotoxicity. The protective action of the ethanol extract of *E. hirta* was probably due its antioxidant nature which protects the kidney against nephrotoxicity induced by nitrobenzene.

ACKNOWLEDGMENT

We, the authors, are thankful to Chancellor, Advisor, Vice Chancellor and Registrar of Karpagam University for providing facilities and encouragement.

REFERENCES

- Joy J, Nair CK. Amelioration of cisplatin induced nephrotoxicity in Swiss albino mice by *Rubia cordifolia* extract. J Can Res Ther 2008;4:111-5.
- Wojcikowski K, Stevenson L, Leach D, Wohlmuth H, Gobe G. Antioxidant capacity of 55 medicinal herbs traditionally used to treat the urinary system: A comparison using a sequential three solvent extraction process. J Altern Complement Med 2007;13:103-9.
- James W, Joint J, Siegel C, Singh D, Velazquez S. Nitrobenzene carcinogenicity, National Center for Environmental Assessment. 1998; EPA/600/R-95/100.
- Cattley RC, Everitt JI, Gross EA, Moss OR, Hamm TE Jr, Popp JA. Carcinogenicity and toxicity of inhaled nitrobenzene in B6C3F1 mice and F344 and CD rats. Fundam Appl Toxicol 1994;22:328-40.
- Howard PC, Beland FA, Cerniglia CE. Reduction of the carcinogen 1-nitropyrene to 1-aminopyrene by the rat intestinal bacteria. Carcinogenesis 1983;4:985-90.
- Montilla P, Barcos M, Munoz MC, Bujalance I, Munoz-Castaneda JR, Tunez I. Red wine prevents brain oxidative stress and nephropathy in streptozotocin-induced diabetic rats. J Biochem Mol Biol 2005;38:539-44.
- Mansour HH, Hafez HF, Fahmy NM. Silymarin modulates cisplatin-induced oxidative stress and hepatotoxicity in rats. J Biochem Mol Biol 2006;39:656-61.
- El-Beshbishy HA. Hepatoprotective effect of green tea (*Camellia sinensis*) extract against tamoxifen-induced liver injury in rats. J Biochem Mol Biol 2005;38:563-70.
- Umamaheswari M, Chatterjee TK. Effect of the fractions of *Coccinia grandis* on Ethanol-Induced cerebral oxidative stress in rats. Phcog Res 2009;1:25-34.
- Samarghandian S, Afshari JT, Davoodi S. Honey induces apoptosis in renal cell carcinoma. Phcog Mag 2011;7:46-52.
- Shirwaikar A, Verma R, Lobo R. Phytotherapy - Safety aspects. Natural Product Radiance, 2009;8:55-63.
- Shanmugam KR, Ramakrishna CH, Mallikarjuna K, Reddy KS. Protective effect of ginger against alcohol-induced renal damage and antioxidant enzymes in male albino rats. Indian J Exp Biol 2010;48:143-9.
- Chidrawar VR, Ushir YV, Sudarshan S, Patel KN, Patel NJ, Vadalia KR. Possible Role of Natural Nephroprotective; *Hemidesmus indicus* in Congestive Heart Failure. Phcog Res 2009;1:367-74.
- Abubakar EM. Antibacterial activity of crude extracts of *Euphorbia hirta* against some bacteria associated with enteric infections. J Med Plants Res 2009;3:498-505.
- Ogbulie JN, Ogueke CC, Okoli IC, Anyanwu BN. Antibacterial activities and toxicological potentials of crude ethanol extracts of *Euphorbia hirta*. Afr J Biotechnol 2007;6:1544-8.
- Sharma NK, Dey S, Prasad R. *In vitro* antioxidant potential evaluation of *Euphorbia hirta*. Pharmacol Online 2007;1:91-8.
- Kumar S, Malhotra R, Kumar D. *Euphorbia hirta*: Its chemistry, traditional and medicinal uses, and pharmacological activities. Phcog Rev 2010;4:58-61.
- Liu Y, Murakami N, Ji H, Abreu Pedro, Zhang S. Antimalarial flavonol glycosides from *Euphorbia hirta*. Pharm Biol 2007;45:278-81.
- Adedapo AA, Abatan MO, Idowu SO, Olorunsogo OO. Effects of chromatography fractions of *Euphorbia hirta* on the rat serum biochemistry. Afr J Biomed Res 2005;8:185-9.
- Kandalkar A, Patel A, Darade S, Baviskar D. Free radical scavenging activity of *Euphorbia hirta* Linn. leaves and

- isolation of active flavonoid myricitrin. *Asian J Pharm Clin Res* 2010;3:234-37.
21. Khan MR, Rizvi W, Khan GN, Khan RA, Shaheen S. Carbon tetrachloride-induced nephrotoxicity in rats: Protective role of *Digera muricata*. *J Ethnopharmacol* 2009;122:91-9.
 22. Trease GE, Evans, WC. A textbook of Pharmacognosy. London: Bacilliere Tinnall Ltd; 1989.
 23. Lowry OH, Roseberg NJ, Farr AL, Randell RJ. Protein measurement with Folin phenol reagent. *J Biol Chem* 1951;193:265-75.
 24. Hogberg J, Larson RE, Kristoferson A, Orrhenices S. NADPH-dependent reductase solubilised from microsomes by peroxidation and its activity. *Biochem Biophys Res Commun* 1974;56:836-42.
 25. Misra HP, Fridovich I. The role of superoxide anion in the antioxidant epinephrine and a single assay of superoxide dismutase. *J Biol Chem* 1972;247:3170-5.
 26. Lueck H. *Methods of enzymatic analysis*. London: Academic Press; 1965.
 27. Rotruck JT, Pope AL, Ganther HS. Selenium: Biochemical role as a component of glutathione peroxidase purification and assay. *Science* 1973;179:588-90.
 28. Habig WH, Pabst MJ, Jakoby WB. Glutathione-S-transferases. The first enzymatic step in mercapturic acid formation. *J Biol Chem* 1974;249:7130-9.
 29. Moran MS, Diferre JW, Manneruik B. Levels of glutathione reductase glutathione-s-transferase in rat lung and liver. *Biochim Biophys Acta* 1979;582:67-78.
 30. Sedlack J, Lindsay RH. Estimation of total protein bound non protein bound sulphhydryl group in the tissue with Ellmann's reagent. *Anal Biochem* 1968;25:192-205.
 31. Omaye ST, Turabull JD, Sauberlich HE. Selected method for the determination of ascorbic acid in animal cells tissues and fluids. *Methods Enzymol* 1979;62:3-11.
 32. Suganya S, Ragavendran P, Rajalakshymenon B, Rathi MA, Thirumoorathi L, Meenakshi P, et al. Potential effect of *Euphorbia hirta* against nitrobenzene-induced nephrotoxicity. *Pharmacol Online* 2010;2:963-70.
 33. Hsu CH, Stedeford T, Okochi-Takada E, Ushijima T, Noguchi H, Muro-Cacho C, et al. Framework analysis for the carcinogenic mode of action of nitrobenzene. *J Environ Sci Health C Environ Carcinog Ecotoxicol Rev* 2007;25:155-84.
 34. Ray S, De K, Sengupta C, Roy K. QSAR study of lipid peroxidation-inhibition potential of some phenolic antioxidants. *Indian J Biochem Biophys* 2008;45:198-205.
 35. Noori S, Mahboob T. Antioxidant effect of carnosine pretreatment on cisplatin induced renal oxidative stress in rats. *Indian J Clin Biochem* 2010;25:86-91.
 36. Bhujbal SS, Kewatkar SM, More LS, Patil MJ. Antioxidant Effects of Roots of *Clerodendrum serratum* Linn. *Phcog Res* 2009;1:294-8.
 37. Ragheb A, Attia A, Eldin WS, Elbarbry F, Gazarin S, Shoker A. Protective effect of thymoquinone, an anti-oxidant, an anti-inflammatory agent against renal injury: A review. *Saudi J Kidney Dis Transpl* 2009;20:741-52.
 38. Stef DS, Gergen I, Trasea TI, Harmanescu M, Lavinia S, Ramona MB, et al. Total antioxidant and radical scavenging capacities for different medicinal herbs. *Rom Biotechnol Lett* 2009;14:4704-9.
 39. Bhartiya US, Raut YS, Joseph L. Protective effect of *Ocimum sanctum* L after high dose of ¹³¹Iodine exposure in mice as *in vivo* study. *Indian J Exp Biol* 2006;44:647-52.
 40. Somani SM, Husain K, Whitworth C, Trammell GL, Malafa M, Rybak LP. Dose-dependent protection by lipoic acid against cisplatin-induced nephrotoxicity in rats: Antioxidant defense system. *Pharmacol Toxicol* 2000;86:234-41.
 41. Chandra Jagetia G, Rajanikant GK, Rao SK, Shrinath Baliga M. Alteration in glutathione, glutathione peroxidase, superoxide dismutase, and lipid peroxidation by ascorbic acid in the skin of mice exposed to fractionated gamma radiation. *Clin Chim Acta* 2003;332:111-21.
 42. Rahman I, MacNee W. Lung glutathione and oxidative stress: Implications in cigarette smoking-induced airway disease. *Am J Physiol* 1999;277:1067-88.
 43. Gutierrez RMP, Navarro YTG. Antioxidant and hepatoprotective effects of the methanol extract of the leaves of *Satureja macrostema*. *Phcog Mag* 2010;6:125-31.
 44. Devi DG, Lija Y, Cibin TR, Biju PG, Devi VG, Abraham A. Evaluation of the protective effects of *Emilia sonchifolia* Linn. (DC.) on perchlorate induced oxidative damage. *J Biol Sci* 2006;6:887-92.
 45. Nwanjo HU, Oze G, Okafor MC, Nwosu D, Nwankpa P. Oxidative stress and non-enzymatic antioxidant status in hypertensive patients in Nigeria. *Afr J Biotechnol* 2001;6:1681-4.
 46. Priya R, Vasudha KC. Antioxidant vitamins in chronic renal failure. *Biomed Res* 2009;20:67-70.
 47. Sinha M, Manna P, Sil PC. Amelioration of galactosamine-induced nephrotoxicity by a protein isolated from the leaves of the herb *Cajanus indicus* L. *BMC Complement Altern Med* 2007;7:11.
 48. Ajamia M, Eghtesadia S, Pazoki-Toroudib H, Habibeyb CR, Ebrahimid SA. Effect of *Crocus sativus* on gentamicin induced nephrotoxicity. *Biol Res* 2010;43:83-90.
 49. Ghosh A, Sil PC. Anti-oxidative effect of a protein from *Cajanus indicus* L. against acetaminophen-induced hepato-nephro toxicity. *J Biochem Mol Biol* 2007;40:1039-49.

Cite this article as: Suganya S, Sophia D, Raj CA, Rathi MA, Thirumoorathi L, Meenakshi P, Kumar DG, Gopalakrishnan VK. Amelioration of nitrobenzene-induced nephrotoxicity by the ethanol extract of the herb *Euphorbia hirta*. *Phcog Res* 2011;3:201-7.

Source of Support: Nil, **Conflict of Interest:** None declared.